



ELSEVIER

Contents lists available at ScienceDirect

Respiratory Medicine Case Reports

journal homepage: www.elsevier.com/locate/rmcr

Case report

Exacerbation of chronic renal failure because of inhaled tobramycin in a lung transplant patient

Víctor M. Mora Cuesta^{*}, Noelia Borja Vargas, David Iturbe Fernández, Sandra Tello Mena, José M. Cifrián Martínez

Marqués de Valdecilla University Hospital, Pneumology department, Lung Transplant Unit, Avda. Valdecilla n° 25, ZP: 39008, Santander, Cantabria, Spain

ARTICLE INFO

Keywords:

Lung transplantation
Renal failure
Inhaled tobramycin

ABSTRACT

61-year-old man, with a history of years of unknown etiology bronchiectasis, with chronic bronchial infection by *Burkholderia multivorans*, who received treatment with a double lung transplant on 08/20/2020. Persistent positive cultures of *Burkholderia multivorans* after transplant in respiratory samples was observed, and treatment with inhaled tobramycin 300 mg/12 hours was started. One month after treatment, a significant worsening of renal function was observed, which was already altered, and toxic levels of tobramycin were measured in blood samples 12 hours after the last inhaled administration. After stopping treatment, kidney function returned to its baseline values.

1. Case report

Lung transplantation is a therapeutic option for patients with non-neoplastic, severe, and irreversible chronic respiratory disease, if all available therapeutic resources have been exhausted. Lung transplantation continues to grow as a field, with more than 4500 transplants performed worldwide in 2019 at over 260 lung transplant centers [1]. Cystic fibrosis represents the 13% of the total lung transplants performed according to the International Society of Heart and Lung Transplantation (ISHLT) [2].

We present a case of 61-year-old man, with a history of years of unknown etiology bronchiectasis, who have been ruled out cystic fibrosis, with chronic bronchial infection by *Burkholderia multivorans*, on treatment with nebulized ceftazidime 2 g/12 hours. He received treatment with a double lung transplant in August 2020 without relevant complications, continuing treatment with nebulized ceftazidime. Several months after transplantation, he began with kidney failure, probably due to nephrotoxicity because of different drugs (anticalcineurics, valganciclovir, etc ...), with serum creatinine levels around 2–3 mg/dl, although with not hydro electrolyte or acid-base balance alterations. Given the persistence of positive cultures of *Burkholderia multivorans* in respiratory samples of sputum cultures and bronchoscopic aspirates taken by bronchoscopy, in August 2021 treatment with inhaled tobramycin 300 mg/12 hours was

; ISHLT, International Society for Heart and Lung Transplantation.

^{*} Corresponding author. Marqués de Valdecilla University Hospital, Pneumology department, Lung Transplant Unit, Avda. Valdecilla n° 25, ZP: 39008, Santander, Cantabria, Spain.

E-mail addresses: victormanuel.mora@scsalud.es (V.M. Mora Cuesta), noelia.borja@scsalud.es (N. Borja Vargas), david.iturbe@scsalud.es (D. Iturbe Fernández), sandra.tello@scsalud.es (S. Tello Mena), josemanuel.cifrian@scsalud.es (J.M. Cifrián Martínez).

<https://doi.org/10.1016/j.rmcr.2022.101584>

Received 4 December 2021; Received in revised form 4 January 2022; Accepted 12 January 2022

Available online 22 January 2022

2213-0071/© 2022 Published by Elsevier Ltd. This is an open access article under the CC BY-NC-ND license

(<http://creativecommons.org/licenses/by-nc-nd/4.0/>).

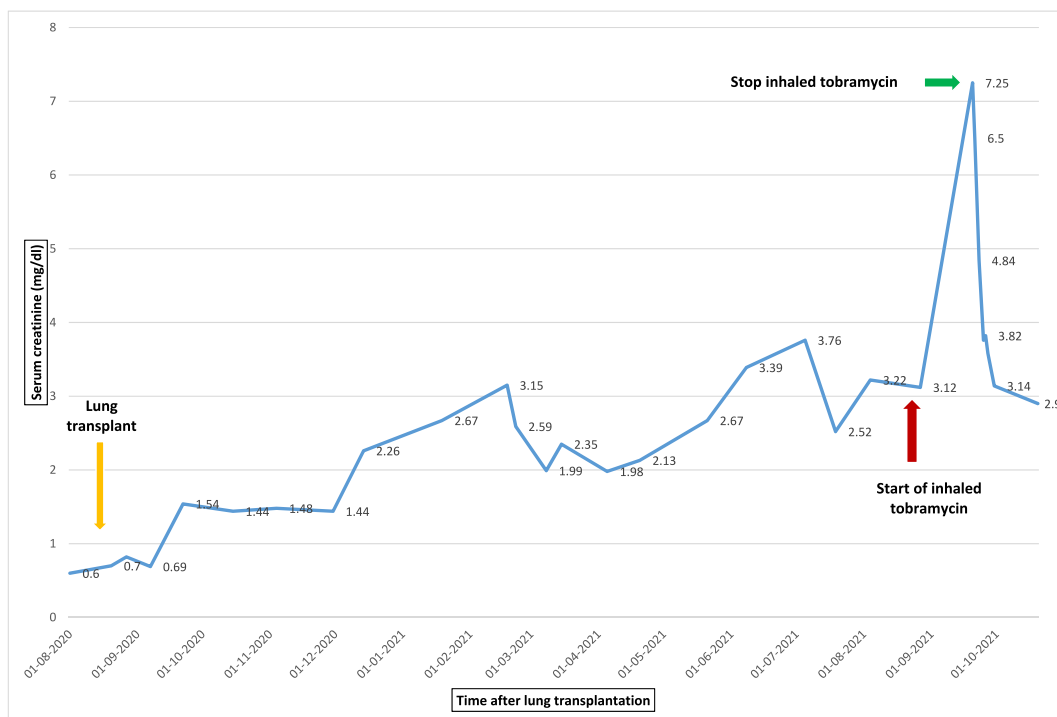


Fig. 1. Renal function measured by creatinine (mg/dl) across the time after transplant. The arrows indicate when the inhaled tobramycin was started and removed.

started, alternating with ceftazidime 2 gr/12 hours, in cycles of 28 days. After two weeks of treatment with inhaled tobramycin, a significant worsening of baseline renal function was observed with an increase in creatinine to 7.25 mg/dl (Fig. 1). After ruling out other causes of worsening kidney function after multiple complementary tests, a serum tobramycin levels were made that revealed levels in the toxic range of 2.70 mg/liter, and then, inhaled tobramycin was stopped, with subsequent recovery of previous renal function. The patient did not present symptoms of vestibular toxicity, although no specific complementary examinations were performed.

2. Discussion

The use of inhaled antibiotic therapy after lung transplantation is a common clinical practice that aims to administer high concentrations of drugs into the airway for the prophylaxis and treatment of different microorganisms, thereby trying to reduce systemic toxicity. One of the most widely used drugs is inhaled liposomal amphotericin B for the prophylaxis of *Aspergillus* infections, which has been shown to reduce the number of infections by this fungus without systemic toxic effects, with serum levels measured after a nebulization in non-toxic range [3]. Another antibiotic also frequently used in lung transplantation is nebulized colistin for the treatment of *Pseudomonas aeruginosa*, because the eradication of this bacteria has been shown to prolong the time free from chronic graft dysfunction [4].

Inhaled tobramycin is an approved drug for the treatment of *Pseudomonas aeruginosa* infection in patients with cystic fibrosis [5]. There are few cases reported of renal toxicity secondary to inhaled tobramycin in patients with lung transplantation, some of them being associated with vestibular toxicity, and at least one other case of vestibular toxicity without renal failure [6–13]. Table 1 summarizes the most relevant cases of systemic toxicity due to inhaled tobramycin.

A proposed mechanism is that, in these indications different than cystic fibrosis, with a lower density of bronchial mucus, there is a higher risk of absorption and, therefore, of systemic toxicity. For this reason, it is necessary to closely monitor renal function and other potential side effects of this inhaled drug in different indications than cystic fibrosis, and even more so in patients with underlying renal failure.

Table 1
Summary of relevant clinical cases.

Author and year	Age and condition	Microorganism	Doses of inhaled tobramycin	Serum creatinine before inhaled tobramycin (mg/dl)	Peak of creatinine (mg/dl)	Tobramycin trough serum concentration	Other toxicity	Outcome
Hoffmann et al., 2000 [6]	20-year-old-female with cystic fibrosis	<i>Pseudomonas aeruginosa</i>	300 mg/12 hours	0.6	9	2.8 mg/L	Vestibulotoxicity	Recover normal renal function and resolution of vestibulotoxicity after discontinuation
Kahler et al., 2003 [7]	19-year-old-female with heart transplantation	<i>Acinetobacter baumannii</i>	300 mg/12 hours	–	–	2.5 µg/ml	None	Improvement after adjustment dose of inhaled tobramycin
Edson et al., 2004 [8]	41-year-old woman with chronic renal failure requiring hemodialysis due to Wegener granulomatosis	<i>Pseudomonas aeruginosa</i>	300 mg/12 hours	9.2	–	19.5 mg/L	Vestibulotoxicity	Improvement after discontinuation
Ahya et al., 2005 [9]	59-year-old woman with single lung transplant	<i>Pseudomonas aeruginosa</i>	300 mg/12 hours	1.3–1.8	3.5	8.7 mg/ml	Vestibulotoxicity	Creatinine dropped to 2.6 mg/dl after cessation. Vestibulotoxicity never fully resolved
Laporta et al., 2005 [10]	63-year-old man with bilateral lung transplant	<i>Pseudomonas aeruginosa</i>	300 mg/12 hours	2.5	3.5	No available	Unknown	Baseline creatinine 1 week after discontinuation
Laporta et al., 2005 [10]	63-year-old man with lung transplant	<i>Pseudomonas aeruginosa</i>	Non reported	1.4–1.6	4	No available	Unknown	Required temporary hemodialysis
Cannella et al., 2006 [11]	62-year-old woman. Nosocomial pneumoniae	<i>Pseudomonas aeruginosa</i>	300 mg/12 hours	2	4.5	0.7 µg/ml	Unknown	Renal function was never regained.
Kaufman et al., 2020 [12]	75-year-old man with interstitial lung disease and bronchiectasis	<i>Pseudomonas aeruginosa</i>	300 mg/12 hours	0.95–1.28	1.26	No available	Vestibulotoxicity	Improvement but no complete resolution of vestibular symptoms after discontinuation
Miller et al., 2021 [13]	57-year-old male with cystic fibrosis	<i>Pseudomonas aeruginosa</i>	300 mg/12 hours	1.5–1.6	4.08	3.6 µg/ml	Vestibulotoxicity	Kidney function did not completely return to his chronic baseline.

Declaration of competing interest

None of the authors has any conflict of interest for this manuscript. There are no funding sources for the preparation of this document.

References

- [1] L.E. Leard, A.M. Holm, M. Valapour, A.R. Glanville, S. Attawar, M. Aversa, et al., Consensus document for the selection of lung transplant candidates: an update from the International Society for Heart and Lung Transplantation, *J. Heart Lung Transplant.* 40 (11) (2021) 1349–1379, <https://doi.org/10.1016/j.healun.2021.07.005>.
- [2] H. Jr, E. Hsich, K.K. Khush, B. Meiser, Focus theme : donor and recipient size match, *J. Heart Lung Transplant.* 38 (10) (2019) 1042–1055.
- [3] S. Husain, B. Capitano, T. Corcoran, S.M. Studer, M. Crespo, B. Johnson, et al., Intrapulmonary disposition of amphotericin B after aerosolized delivery of amphotericin B lipid complex (Abelcet; ABLC) in lung transplant recipients, *Transplantation* 90 (11) (2010) 1215–1219.
- [4] B De Muynck, A Van Herck, A Sacreas, T Heigl, J Kaes, A Vanstapel, SE Verleden, AP Neyrinck, LJ Ceulemans, DE Van Raemdonck, K Lagrou, BM Vanaudenaerde, GM Verleden, R Vos, Leuven Lung Transplant Group, Successful *Pseudomonas aeruginosa* eradication improves outcomes after lung transplantation: a retrospective cohort analysis, *Eur. Respir. J.* 156 (4) (2020 Oct) 2001720, <https://doi.org/10.1183/13993003.01720-2020>. PMID: 32471935.
- [5] F Ratjen, A Munck, P Kho, G Angyalosi, ELITE Study Group, Treatment of early *Pseudomonas aeruginosa* infection in patients with cystic fibrosis: the ELITE trial, *Thorax* 65 (4) (2010 Apr) 286–291, <https://doi.org/10.1136/thx.2009.121657>. Epub 2009 Dec 8. PMID: 19996339.
- [6] I.M. Hoffmann, B.K. Rubin, S.S. Iskandar, M.S. Schechter, S.K. Nagaraj, M.M. Bitzan, Acute renal failure in cystic fibrosis: association with inhaled tobramycin therapy, *Pediatr. Pulmonol.* 34 (5) (2002) 375–377.
- [7] D.A. Kahler, K.O. Schowengerdt, F.J. Fricker, M. Mansfield, G.A. Visner, A. Faro, Toxic serum trough concentrations after administration of nebulized tobramycin, *Pharmacotherapy* 23 (4) (2003) 543–545.
- [8] R.S. Edson, R.H. Brey, T.J. McDonald, C.L. Terrell, J.T. McCarthy, J.M. Thibert, Vestibular toxicity due to inhaled tobramycin in a patient with renal insufficiency, *Mayo Clin. Proc.* 79 (9) (2004) 1185–1191.
- [9] V.N. Ahya, A.M. Doyle, J.D. Mendez, D.A. Lipson, J.D. Christie, E.A. Blumberg, et al., Renal and vestibular toxicity due to inhaled tobramycin in a lung transplant recipient, *J. Heart Lung Transplant.* 24 (7) (2005) 932–935.
- [10] R. Laporta, P. Ussetti, M.C. Carreño, Renal toxicity due to inhaled tobramycin in lung transplant recipients, *J. Heart Lung Transplant. : Off Publ Int Soc Heart Transplant* 25 (2006) 608. United States.
- [11] C.A. Cannella, S.T. Wilkinson, Acute renal failure associated with inhaled tobramycin, *Am J Heal Pharm* 63 (19) (2006) 1858–1861.
- [12] A.C. Kaufman, S.J. Eliades, Vestibulotoxicity in a patient without renal failure after inhaled tobramycin, *Am J Otolaryngol - Head Neck Med Surg [Internet]* 40 (3) (2019) 456–458, <https://doi.org/10.1016/j.amjoto.2019.03.012>. Available from.
- [13] T. Miller, C. Pastuch, L. Garavaglia, K. Gannon, A. Parravani, Unknown renal impairment: a rare case of inhaled tobramycin induced acute kidney injury in a cystic fibrosis patient, *Antibiotics* (4) (2021) 10.