

# A Pilot Study on Cerebral Blood Flow and Mini-Mental State Examination to Predict Amyloid Deposition in Preclinical Alzheimer's Disease

Takumi Hirose<sup>1</sup>, Toshiki Takayama<sup>1</sup>, Nobuto Shibata<sup>1</sup>, Koji Murakami<sup>2</sup>, Heii Arai<sup>1,3</sup>

<sup>1</sup>Department of Psychiatry and Behavioral Science, Graduate School of Medicine, Juntendo University, Tokyo, Japan;

<sup>2</sup>Department of Radiology, Juntendo University School of Medicine, Tokyo, Japan; <sup>3</sup>Alzclinic Tokyo, Tokyo, Japan

## ABSTRACT

**Background:** Earlier differential diagnosis of dementia remains a major challenge. Although amyloid deposition by positron emission tomography is an emerging standard for the diagnosis of Alzheimer's disease, it is too expensive for routine use in clinical settings. We conducted a pilot study on the potential usefulness of single-photon emission computed tomography and the Mini-Mental State Examination to predict amyloid positron emission tomography positivity in preclinical Alzheimer's disease.

**Methods:** Eighteen subjects, including 11 with mild cognitive impairment and 7 with subjective cognitive decline, underwent <sup>18</sup>F-florbetapir positron emission tomography, <sup>99m</sup>Tc-ethylcysteinate dimer cerebral perfusion single-photon emission computed tomography, and the Mini-Mental State Examination. For the assessment of amyloid deposition, visual judgment as a qualitative method and a semiautomatic software analysis as a quantitative method were used.

**Results:** Six subjects were judged as amyloid positive, including 4 mild cognitive impairment and 2 subjective cognitive decline subjects. Compared to the amyloid positron emission tomography-negative group, this group showed a statistically significant difference in the Mini-Mental State Examination recall score [2 (1 : 3) vs. 3 (2 : 3),  $P = .041$ ] and single-photon emission computed tomography findings from the amyloid-negative group. In the mild cognitive impairment subgroup, correlations were found between amyloid deposition and single-photon emission computed tomography indicators, while in the subjective cognitive decline subgroup, only the Mini-Mental State Examination recall score correlated with amyloid deposition.

**Conclusion:** The Mini-Mental State Examination recall score and single-photon emission computed tomography indicators may be worthwhile for further evaluation as predictors of amyloid deposition in the preclinical stage.

## ARTICLE HISTORY

**Received:** September 24, 2022

**Accepted:** February 4, 2023

**Publication Date:** March 31, 2023

## INTRODUCTION

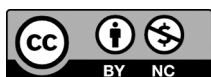Alzheimer's disease (AD) is the most common dementing illness. The first abnormal finding is related to amyloid biomarkers that appear 20 years before clinical onset, and then biomarkers for neuronal damage and degeneration become abnormal later.<sup>1</sup> Amyloid- $\beta$  (A $\beta$ ) pathology can be examined in vivo using cerebrospinal fluid (CSF) assays or positron emission tomography (PET). Using PET to image fibrillar amyloid is a less invasive approach than CSF. Several studies have recently addressed the efficacy of <sup>18</sup>F-florbetapir PET which can detect amyloid deposition with high sensitivity and specificity.<sup>2-5</sup> Although amyloid PET (aPET) offers great advantages to establish clinical evaluation of patients with cognitive dysfunction, it is

not yet well used in clinical practice due to the expensive costs.

In clinical practice, characteristic brain atrophy on magnetic resonance imaging (MRI), characteristic hypometabolism using <sup>18</sup>F-fluorodeoxyglucose uptake on PET, and characteristic cerebral blood flow reduction using single-photon emission computed tomography (SPECT) are useful for the diagnosis of AD. Recently, these examinations have been positioned as biomarkers of neuronal injury in the AD research criteria framework of the National Institute on Aging-Alzheimer's Association.<sup>6</sup> Regional cerebral blood flow (rCBF) imaging using SPECT enabled the evaluation of decreased regional neuronal

**Corresponding author:** Heii Arai, e-mail: heiiarai@gmail.com

**Cite this article as:** Hirose T, Takayama T, Shibata N, Murakami K, Arai H. A pilot study on cerebral blood flow and mini-mental state examination to predict amyloid deposition in preclinical Alzheimer's disease. *Psychiatry Clin Psychopharmacol.* 2023;33(1):1-7.



Content of this journal is licensed under a Creative Commons Attribution-NonCommercial 4.0 International License.

activity, and typical AD imaging patterns have been known as hypoperfusion in the posterior cingulate cortex and/or parietotemporal area and subjects with early-onset AD had a more severe rCBF reduction in the AD pattern area.<sup>7-10</sup> “Easy Z-score imaging system® (eZIS)” (Fujifilm RI Pharma Co., Ltd, Tokyo, Japan) is one of semiautomatic methods using <sup>99m</sup>Tc-ethylcysteinate dimer (ECD) for SPECT to obtain the objective evaluation of a typical AD pattern.<sup>11</sup>

In recent years, subjective cognitive decline (SCD), that is potentially at the preclinical stage of AD, has been suggested to possibly indicate subtle cognitive dysfunction that is not detectable with standardized cognitive tests.<sup>12</sup> Meta-analysis uncovered that people with SCD were at increased risk for AD.<sup>13</sup> One study reported that patients who have more complaints of SCD have more amyloid deposition.<sup>14</sup>

Early differential diagnosis of dementia remains a major challenge for clinical practice, and studies using cerebral perfusion SPECT and aPET are increasing. However, little is known about the association of amyloid imaging with <sup>18</sup>F-florbetapir PET and SPECT. Recently, semiautomated <sup>18</sup>F-florbetapir PET quantification method has been attracting attention, and using image analysis software makes it possible. However, very few studies have been conducted to evaluate the semiautomatic method of aPET. Taken together, predictors of amyloid pathology in preclinical AD would be particularly important in routine clinical practice in order to allow for earlier intervention. Therefore, we started a project to examine whether clinical markers can predict aPET positivity in mild cognitive impairment (MCI) and SCD. The present pilot study examined a possible usefulness of SPECT findings and/or Mini-Mental State Examination (MMSE) scores as such a clinical predictor.

## MATERIALS AND METHODS

### Design and Participants

This was an exploratory clinical study using <sup>18</sup>F-florbetapir PET. We enrolled 18 patients with a chief complaint of forgetfulness and who underwent MRI, SPECT, and MMSE. Clinical diagnosis of SCD or MCI was done according to consensus clinical diagnostic criteria after the tests.

#### MAIN POINTS

- Amyloid imaging is too expensive for clinical routine use.
- This is a pilot study on 18 preclinical Alzheimer’s disease (AD) subjects to examine the usefulness of single-photon emission computed tomography (SPECT) and Mini-Mental State Examination (MMSE) to predict amyloid positivity.
- Myloid-positive group showed a statistically significant difference in the MMSE recall score and SPECT findings from the amyloid-negative group.
- Further studies may be worthwhile even in the preclinical stage of AD.

Subjective cognitive decline was defined by the SCD-I working group and MCI was defined by Petersen criteria.<sup>15,16</sup> In this study, the neuropsychological test in these diagnostic criteria was MMSE.<sup>17</sup> Seven patients [3 (42.86%) men and 4 (57.14%) women; mean age 59.6 ± 6.9 years] were clinically diagnosed with SCD, and 11 [5 (45.45%) men and 6 (54.55%) women; mean age 59.8 ± 8.9 years] were diagnosed with MCI. Clinical data such as education years, family history of dementing illness, past history of major physical diseases and sleep apnea syndrome, and duration since the onset of cognitive decline were collected (Table 1). Patients with severe physical diseases such as cancer that affect cognitive dysfunction, severe abnormal findings on MRI such as brain infarction, and diffuse atrophy or psychiatric disorders such as depression, schizophrenia, or alcoholism were excluded.

We obtained written informed consent from all patients. The study was approved by the review board of University of Juntendo (approval number 17-099).

### Amyloid Positron Emission Tomography

Amyloid PET was performed using <sup>18</sup>F-florbetapir (AMYVID®, Fujifilm Toyama Chemical Co., Ltd, Tokyo, Japan), which is marketed as a drug in Japan. The method of administration was based on the protocol and standard imaging method by the Japan Nuclear Medicine Society. The dose of <sup>18</sup>F-florbetapir was 370 MBq, which was intravenously administered, and after waiting for 30 minutes, PET/CT (Biograph mCT Flow, Siemens Medical Solutions, Malvern, Pennsylvania, USA, Inc.) imaging was performed for 10 minutes.

### Amygo Neuro

A semiautomated analysis of brain amyloid beta images using Amygo Neuro® (Fujifilm Toyama Chemical Co., Ltd, Tokyo, Japan) was performed, enabling an objective, quantitative analysis. The software includes spatial normalization of each PET data to a standard MRI atlas, application of predefined volume of interest (VOI), and calculation of standardized uptake value ratio (SUVR) from 6 grey matter, as reported by Namiki et al.<sup>5</sup> We have created the <sup>18</sup>F-florbetapir template by using the reported data in the previous study of 15 cognitively normal (CN) and 11 AD patients.<sup>18</sup> Volume of interests had been defined as the region of significant difference between CN and AD groups based on a voxel-wise statistical map. Data of grey matter maps by MRI images of CN and <sup>18</sup>F-florbetapir uptake of grey matter in early perfusion of CN were used to the VOI making. Six cortical regions (medial orbitofrontal, anterior cingulate, lateral parietal, precuneus, posterior cingulate, and lateral temporal cortex) were studied. Global cortical SUVR (gSUVR) was also used by calculating the average across all 6 grey matter areas.<sup>19</sup>

As a qualitative assessment, 3 aPET readers judged each image as amyloid positive or negative. They were trained by the Japanese Society of Nuclear Medicine to judge the

**Table 1.** Clinical and Demographic Characteristics of All, SCD, and MCI Subjects

| Characteristic            | All (n=18), n (%), Mean ± SD, or Median (Minimum : Maximum) | SCD (n=7), n (%), Mean ± SD, or Median (Minimum : Maximum) | MCI (n=11), n (%), Mean ± SD, or Median (Minimum : Maximum) | <i>p</i> |
|---------------------------|---|--|---|----------|
| Sex                       |   |  |   | 1.000    |
| Male                      | 8 (44.44%)  | 3 (42.86%)   | 5 (45.45%)  |          |
| Female                    | 10 (55.56%)   | 4 (57.14%)   | 6 (54.55%)  |          |
| Age (years)               | 57.50 (50 : 78)   | 59.00 (51 : 70)  | 57.00 (50 : 78)   | .951     |
| Education                 | 15.78 ± 2.46  | 15.86 ± 2.04   | 15.73 ± 2.8   | .917     |
| Years of SCD or MCI       | 4.17 ± 2.68   | 4.71 ± 3.45  | 3.82 ± 2.18   | .507     |
| Family history            |   |  |   | .066     |
| Yes                       | 8 (44.44%)  | 1 (14.29%)   | 7 (63.64%)  |          |
| No                        | 10 (55.56%)   | 6 (85.71%)   | 4 (36.36%)  |          |
| Sleep apnea syndrome      |   |  |   | .137     |
| Yes                       | 2 (11.11%)  | 2 (28.57%)   | 0 (0%)  |          |
| No                        | 16 (88.89%)   | 5 (71.43%)   | 11 (100%)   |          |
| MMSE                      | 26.00 (25 : 30)   | 29.00 (28 : 30)  | 25.00 (25 : 27)   | <.001    |
| Amyloid PET               |   |  |   | 1.000    |
| Positive                  | 6 (33.33%)  | 2 (28.57%)   | 4 (36.36%)  |          |
| Negative                  | 12 (66.67%)   | 5 (71.43%)   | 7 (63.36%)  |          |
| Amyloid PET (global SUVr) | 0.98 (0.82 : 1.48)  | 0.98 (0.82 : 1.48)   | 0.97 (0.86 : 1.48)  | .659     |

Figures are mean ± SD for parametric tests and median (minimum : maximum) for non-parametric tests.

MCI, mild cognitive impairment; MMSE, Mini-Mental State Examination; PET, positron emission tomography; SCD, subjective cognitive decline; SUVr, standardized uptake value ratio.

binary classification of scans as either amyloid positive or negative according to the proposed methods for clinical examination.

### Single-Photon Emission Computed Tomography

<sup>99m</sup>Tc-ethylcysteinate dimer SPECT was used for measuring the rCBF, performed according to previous studies. Five minutes after intravenous injection of <sup>99m</sup>Tc-ethylcysteinate dimer (600 MBq, FUJIFILM Toyama Chemical Co., Ltd), SPECT images were scanned on a dual-head gamma camera (Symbia S; Simens AG, Munich, Germany).

### Easy Z-Score Imaging System

Automatic standardization of SPECT findings was done by using an original <sup>99m</sup>Tc-ECD template of eZIS (Fujifilm Toyama Chemical Co. Ltd). The eZIS program provides a statistical Z-score image that corresponds to the decrease in regional <sup>99m</sup>Tc-ECD uptake in each patient relative to that of the normal database. By comparison with SPECT findings of the age-matched normal data, we made averaged Z-score maps for SPECT. Anatomical standardization as well as voxel normalization to the global mean values was done as follows:  $Z\text{-score} = \frac{(\text{control mean}) - (\text{individual value})}{(\text{control SD})}$ . Then, the mean and SD values for every voxel were calculated.

Easy Z-score imaging system includes 3 indicators as follows:

1. Severity: The severity of rCBF decrease in a studied region was obtained from the averaged positive Z-score in the VOI.
2. Extent: The extent of rCBF decrease was calculated from the percentage rate of the coordinates, with a Z value exceeding the threshold value of 2 in the VOI.
3. Ratio: The ratio of the extent of a region with significant rCBF decrease in the VOI to that of a region with significant rCBF decrease in the whole brain was calculated from the percentage rate of the coordinates, with a Z value exceeding the threshold value of 2. The ratio means the specificity of the rCBF decrease in the VOI in comparison with that of the whole brain.<sup>11</sup>

### Statistical Analysis

All data used in the analysis were checked for normal distribution by Shapiro-Wilk test. As difference tests, independent *t*-tests, Welch's *t*-test, or Mann-Whitney *U*-tests were used depending on whether data's distribution is normal or not. We used the Levene's test for the assessment of the equality of variances for normally distributed samples, and the *t*-test was used when the 2 samples were equal variances. We used the Welch's *t*-test when they were unequal variances. Fisher's exact tests were used to determine whether or not there is a significant association between 2 categorical variables. Since in Shapiro-Wilk test, at least one of the data

was non-normally distributed, Spearman’s correlation coefficient was calculated.

$\alpha=0.05$  was taken as the significant level. There were no adjustments for multiplicity. Statistical analyses were conducted using IBM Statistical Package for Social Sciences version 25.0 (IBM SPSS Corp.; Armonk, NY, USA). Descriptive statistics are presented as n (%) and for non-normalized variables are presented as “median (minimum : maximum)” and for normalized variables are presented as “mean  $\pm$  SD” in texts and tables.

**RESULTS**

**Primary Outcomes**

Of the 18 patients, 6 (33.33%) patients were positive for aPET by the visual judgment. There were no cases of

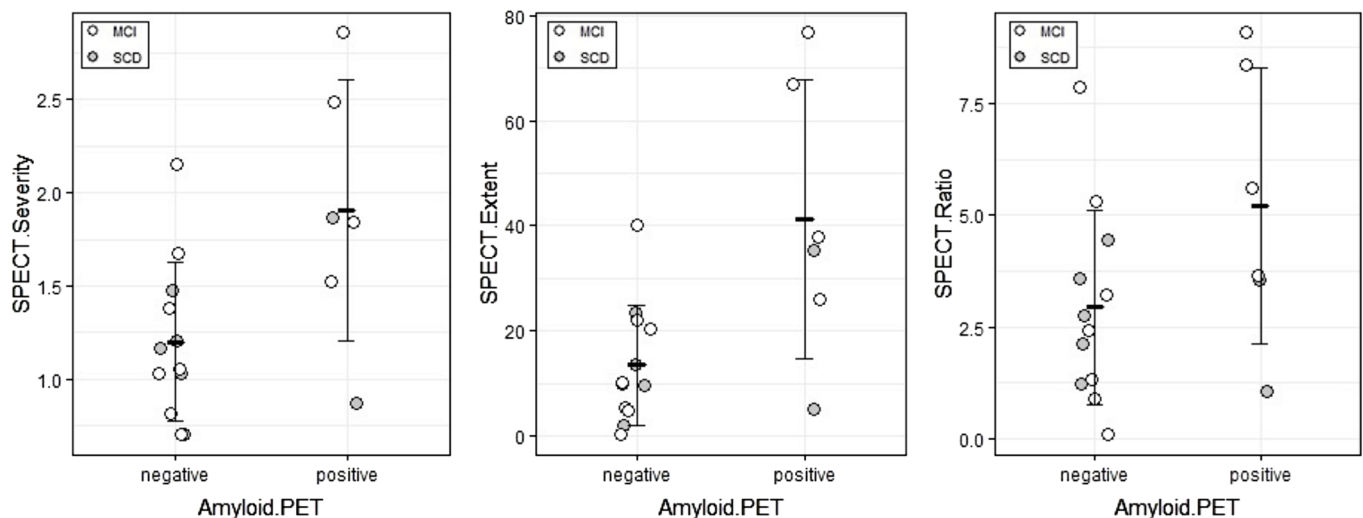
disagreement in reading. The mean of <sup>18</sup>F-florbetapir gSUVr for all 18 subjects was  $1.11 \pm 0.24$ . Of the 11 MCI patients, 4 (36.36%) patients were amyloid positive, and of the 7 SCD patients, 2 (28.57%) patients were amyloid positive by visual judgment. The mean of <sup>18</sup>F-florbetapir gSUVr for the SCD subjects was  $1.07 \pm 0.25$  and that of the MCI subjects was  $1.14 \pm 0.25$ . Table 1 summarizes the clinical and demographic characteristics, including MCI and SCD subgroups.

There was a significant difference in MMSE recall [positive: 2 (1 : 3), negative: 3 (2 : 3),  $P=.041$ , Table 2], SPECT severity [positive:  $1.91 \pm 0.70$ , negative:  $1.20 \pm 0.42$ ,  $P=.016$ ; Table 2], and SPECT extent (positive:  $41.31 \pm 26.50$ , negative:  $13.45 \pm 11.35$ ,  $P=.049$ ; Table 2) between amyloid PET-positive and -negative groups in all subjects (Figure 1). Table 3 summarizes the correlation coefficients for all subjects showing that SPECT severity, SPECT extent,

**Table 2.** Difference in Clinical Characteristics, MMSE, and SPECT Indicators

| Visual Diagnosis    | Positive (n=6), Mean $\pm$ SD or Median (Minimum : Maximum) | Negative (n=12), Mean $\pm$ SD or Median (Minimum : Maximum) | <i>p</i> |
|---------------------|---|--|----------|
| Age                 | 58.5 (53 : 70)  | 56.5 (50 : 78)   | .820     |
| Education           | $14.83 \pm 1.83$  | $16.25 \pm 2.67$   | .262     |
| Years of SCD or MCI | $4.83 \pm 2.48$   | $3.83 \pm 2.82$  | .473     |
| MMSE                | 25.50 (25 : 29)   | 26.5 (25 : 30)   | .335     |
| MMSE recall         | 2 (1 : 3)   | 3 (2 : 3)  | .041     |
| SPECT severity      | $1.91 \pm 0.70$   | $1.20 \pm 0.42$  | .016     |
| SPECT extent        | $41.31 \pm 26.50$   | $13.45 \pm 11.35$  | .049     |
| SPECT ratio         | $5.22 \pm 3.08$   | $2.94 \pm 2.16$  | .085     |

Figures are mean  $\pm$  SD for parametric tests and median (minimum : maximum) for non-parametric tests. MCI, mild cognitive impairment; MMSE, Mini-Mental State Examination; SCD, subjective cognitive decline; SPECT, single-photon emission computed tomography.



**Figure 1.** Scatterplots with error bars (mean  $\pm$  SD) for values of eZIS indicators between amyloid PET-positive and -negative groups in all subjects including SCD and MCI. The aPET-positive group showed a statistically significant difference in SPECT severity (positive:  $1.91 \pm 0.70$ , negative:  $1.20 \pm 0.42$ ,  $P=.016$ ) and SPECT extent (positive:  $41.31 \pm 26.50$ , negative:  $13.45 \pm 11.35$ ,  $P=.049$ ) from the amyloid-negative group. There was no statistically significant difference in SPECT ratio (positive:  $5.22 \pm 3.08$ , negative:  $2.94 \pm 2.16$ ,  $P=.085$ ). aPET, amyloid PET; eZIS, easy Z-score imaging system; MCI, mild cognitive impairment; PET, positron emission tomography; SCD, subjective cognitive decline; SPECT, single-photon emission computed tomography.

**Table 3.** Correlation of Visual Judgment and SUVr in All Subjects

|                     | Visual Diagnosis |          | Global Cortical SUVr |          |
|---------------------|------------------|----------|----------------------|----------|
|                     | <i>r</i>         | <i>P</i> | <i>r</i>             | <i>P</i> |
| Age                 | 0.068            | .788     | 0.508                | .031     |
| Education           | -0.151           | .549     | -0.037               | .884     |
| Years of SCD or MCI | 0.241            | .335     | 0.072                | .776     |
| MMSE                | -0.257           | .304     | -0.324               | .189     |
| MMSE recall         | -0.623           | .006     | -0.390               | .109     |
| SPECT severity      | 0.523            | .026     | 0.249                | .319     |
| SPECT extent        | 0.545            | .019     | 0.275                | .269     |
| SPECT ratio         | 0.409            | .092     | 0.126                | .618     |

Spearman's correlation coefficient was calculated.

MCI, mild cognitive impairment; MMSE, Mini-Mental State Examination; SCD, subjective cognitive decline; SPECT, single-photon emission computed tomography; SUVr, standardized uptake value ratio.

and MMSE recall were significantly correlated with aPET visual diagnosis (severity:  $r=0.523$ ,  $P=.026$ ; Extent:  $r=0.545$ ,  $P=.019$ ; MMSE recall:  $r=-0.623$ ,  $P=.006$ ). Only age was correlated with gSUVr of aPET ( $r=0.508$ ,  $P=.031$ ; Table 3), and no significant correlation was found between other factors and gSUVr (Table 3).

#### Subgroup Analyses

In the SCD subgroup, only amyloid-positive patients (2 subjects) showed 2 points for recall sub-score in MMSE, while all amyloid-negative patients scored 3 points. No significant difference between the positive and negative subgroups was observed for other factors including SPECT indicators (severity, positive:  $1.37 \pm 0.70$ , negative:  $1.12 \pm 0.28$ ,  $P=.495$ ; extent, positive:  $20.20 \pm 21.47$ , negative:  $11.75 \pm 7.81$ ,  $P=.434$ ; ratio, positive:  $2.31 \pm 1.76$ , negative:  $2.82 \pm 1.24$ ,  $P=.674$ ). No correlation was found except for MMSE recall in the SCD subgroup (age,  $r=0.474$ ,  $P=.282$ ; education,  $r=0.331$ ,  $P=.468$ ; years of SCD,  $r=0.241$ ,  $P=.251$ ; MMSE,  $r=-0.502$ ,  $P=.304$ ; severity,  $r=0.158$ ,  $P=.735$ ; extent,  $r=0.158$ ,  $P=.735$ ;

**Table 4.** Correlation of Visual Judgment in SCD and MCI

|                     | SCD      |          | MCI      |          |
|---------------------|----------|----------|----------|----------|
|                     | <i>r</i> | <i>P</i> | <i>r</i> | <i>P</i> |
| Age                 | 0.474    | .282     | -0.120   | .726     |
| Education           | 0.331    | .468     | -0.334   | .315     |
| Years of SCD or MCI | 0.241    | .251     | -0.037   | .776     |
| MMSE                | -0.502   | .304     | -0.335   | .314     |
| MMSE recall         | -1       | <.001    | -0.420   | .199     |
| SPECT severity      | 0.158    | .735     | 0.657    | .028     |
| SPECT extent        | 0.158    | .735     | 0.717    | .013     |
| SPECT ratio         | -0.316   | .490     | 0.657    | .028     |

Spearman's correlation coefficient was calculated.

MCI, mild cognitive impairment; MMSE, Mini-Mental State Examination; SCD, subjective cognitive decline; SPECT, single-photon emission computed tomography.

ratio,  $r=-0.316$ ,  $P=.490$ ; Table 4). For gSUVr, only MMSE recall was significantly correlated ( $r=-0.709$ ,  $P=.034$ ), and there was no correlation for MMSE total score and SPECT indicators (MMSE,  $r=-0.454$ ,  $P=.307$ ; severity,  $r=-0.179$ ,  $P=0.702$ ; extent,  $r=-0.143$ ,  $P=.760$ ; ratio,  $r=-0.607$ ,  $P=.138$ ).

In the MCI subgroup, there was a significant difference between the positive and negative groups in the severity and extent (severity, positive:  $2.18 \pm 0.60$ , negative:  $1.26 \pm 0.51$ ,  $P=.025$ ; extent, positive:  $51.86 \pm 23.89$ , negative:  $14.66 \pm 13.84$ ,  $P=.009$ ). There was not a significant difference in the ratio (positive:  $6.67 \pm 2.52$ , negative:  $3.01 \pm 2.74$ ,  $P=.057$ ). Significant correlations were also found between the visual judgments and severity, extent, and ratio (severity,  $r=0.657$ ,  $P=.028$ ; extent,  $r=0.717$ ,  $P=.013$ ; ratio,  $r=0.657$ ,  $P=.028$ ; Table 4). There were no correlations for other factors (age,  $r=-0.120$ ,  $P=.726$ ; education,  $r=-0.334$ ,  $P=.315$ ; years of MCI,  $r=-0.037$ ,  $P=.776$ ; MMSE,  $r=0.335$ ,  $P=.314$ ; MMSE recall,  $r=-0.420$ ,  $P=.199$ ; Table 4). For gSUVr, no correlation was observed with MMSE scores and SPECT indicators (MMSE,  $r=-0.488$ ,  $P=.128$ ; MMSE recall,  $r=-0.114$ ,  $P=.739$ ; severity,  $r=0.449$ ,  $P=.166$ ; extent,  $r=0.517$ ,  $P=.103$ ; ratio,  $r=0.453$ ,  $P=.162$ ).

#### DISCUSSION

This study examined the association of the results of  $^{18}\text{F}$ -florbetapir PET with routine clinical examinations in patients with SCD and MCI. The objective of our pilot research was to answer a clinical usefulness of whether cerebral blood flow and/or MMSE may predict amyloid deposition. We used  $^{18}\text{F}$ -florbetapir as a tracer and compared the correlation of eZIS-SPECT findings and amyloid deposition between visual judgment and gSUVr.

In the analysis of the total group, the positive group of aPET had a statistically significant difference in the MMSE recall score, SPECT severity, and SPECT extent from the amyloid-negative group. Moreover, a significant correlation was found between the positivity of aPET and MMSE recall score and SPECT severity and extent. It is of interest that the factors associated with aPET were MMSE recall, age, and SPECT indicators even in the preclinical stage of AD. It is well known that the recall score of MMSE was thought as a candidate marker of early symptoms of AD, which was reported by epidemiological studies and those using meta-analysis.<sup>20</sup> On the other hand, age-related A $\beta$  deposition is well documented.<sup>21,22</sup> There have been also several studies on the relationship between SPECT indicators and aPET, but the evidence is not yet established.<sup>23</sup> In a study on association  $^{11}\text{C}$ -Pittsburgh compound-B PET and eZIS of  $^{99\text{m}}\text{Tc}$ -ECD SPECT, MCI subjects with abnormal values in SPECT ratio, or all 3 indicators, were suggested to have a potential probability of amyloid deposition in the brain.<sup>24</sup> Another study also reported that the association between

typical hypoperfusion AD-pattern in  $^{123}\text{I}$ -iodoamphetamine SPECT by visual judgment may support positivity of aPET.<sup>25</sup> Taken together, including our results, cerebral perfusion SPECT may serve as a marker of amyloid deposition.

It is also interesting to note that the results of the correlation coefficient for aPET were different between the MCI and SCD subgroups. In the MCI subgroup, the amyloid-positive group had a statistically significant difference in the SPECT severity and SPECT extent from the amyloid-negative group, and there was a significant correlation between the positivity of aPET and the 3 indicators of SPECT. On the other hand, no difference was found in SPECT findings between the amyloid-positive and -negative subgroups in the SCD group. The negative results may be interpreted by a possibility that the SCD group defined by subjective memory loss was more heterogeneous compared to the MCI group. Moreover, it may be clinically reasonable that only short-term memory loss could be found in the SCD stage that may be related to the earliest stage of AD pathology, while any functional or morphological changes in SPECT or MRI are usually found in the later stage such as MCI. Accordingly, it is of interest that all amyloid-positive subjects in the SCD group had 1-point loss of MMSE recall score and all amyloid-negative subjects had no point loss. Regardless of the total MMSE score, even the loss of a single point in MMSE recall may be a risk of converting to AD. Our results are different from a previous paper that reported that scores of recall memory have no significant differences between aPET-positive and -negative SCD sub-groups.<sup>26</sup> However, further study with bigger number of SCD and MCI subjects will be able to find an answer.

On the other hand, the quantitative data, the gSUVR was not correlated with any factor other than age. The difference between the visual judgment and the semiautomated quantitative analysis found in the present study should be discussed. In the visual judgment, reduction or loss of the normally distinct gray-white contrast is common appearance of a positive scan. The contrast is located outer in the brain, and so inner in the brain are less focused on. If each SUVR of the inner area is high but that of the outer area is not strongly accumulated, visual judgment gives an amyloid-negative diagnosis. For another factor, as the cerebellar SUVR is used as the reference region of gSUVR in the quantitative analysis, it is possible that SUVR may be higher at other regions if relatively less cerebellum of the ligand is low due to cerebellar atrophy. For these reasons, quantitative judgments using image analysis software and visual judgments may be sometimes mismatched. In addition, the appropriate use criteria for aPET indicates that computer-aided analysis software for amyloid images provides more useful data than a binary visual read, but on the other hand, it needs further study.<sup>27</sup>

The pilot study has several limitations. First, the number of subjects was too small to perform logistic and multiple

regression analyses. Therefore, we were not able to adjust for major confounders and to show the utility of combining SPECT and MMSE recall in discriminating amyloid-positive from amyloid-negative subgroup. In addition, we did not set an age-matched control group with no subjective complaint of cognitive decline. Second, only MMSE was performed to evaluate cognitive function, which may not be enough for the assessment of subtle forgetfulness.<sup>28</sup> It was necessary to perform more cognitive tests including Montreal Cognitive Assessment which is considered to be highly accurate for MCI diagnosis.<sup>29</sup> Also, we needed to prepare the apolipoprotein E gene polymorphism to know the genetic background. Third, follow-up examinations on aPET were not available to study changes in amyloid deposition over time or during cognitive decline due to a short study period.

In summary, we performed a pilot study using aPET with  $^{18}\text{F}$ -florbetapir as a tracer to verify the associations of amyloid imaging with  $^{99\text{m}}\text{Tc}$ -ECD SPECT findings and MMSE score in MCI and SCD subjects. Also, this study compared the correlations of eZIS-SPECT findings and amyloid deposition between visual judgment and gSUVR. Although we should consider the research limitations such as small samples, this pilot study suggested a further investigation on the usefulness of MMSE recall, SPECT severity, and SPECT extent to predict amyloid pathology even in preclinical AD.

**Ethics Committee Approval:** Ethical committee approval was received from the Ethics Committee of University of Juntendo (Approval no: 17-099).

**Informed Consent:** Written informed consent was obtained from all participants who participated in this study.

**Peer-review:** Externally peer-reviewed.

**Author Contributions:** Concept - H.A.; Design - H.A., K.M.; Supervision - K.M.; Funding - H.A.; Materials - T.T., H.A.; Data Collection and/or Processing - T.H., T.T.; Analysis and/or Interpretation - T.H., T.T., N.S.; Literature Review - T.H., N.H.; Writing - T.H., T.T., H.A.; Critical Review - K.M.

**Declaration of Interests:** The authors declare that they have no competing interest.

**Funding:** This work was supported by “Private University Research Branding” Project (Ministry of Education, Culture, Sports, Science and Technology, Japan) 2018-2019.

## REFERENCES

1. Sperling RA, Aisen PS, Beckett LA, et al. Toward defining the preclinical stages of Alzheimer's disease: recommendations from the National Institute on Aging-Alzheimer's Association workgroups on diagnostic guidelines for Alzheimer's disease. *Alzheimers Dement.* 2011;7(3):280-292. [CrossRef]
2. Clark CM, Pontecorvo MJ, Beach TG, et al. Cerebral PET with florbetapir compared with neuropathology at autopsy for detection of neuritic amyloid-beta plaques: a prospective cohort study. *Lancet Neurol.* 2012;11(8):669-678. [CrossRef]

3. Clark CM, Schneider JA, Bedell BJ, et al. Use of florbetapir-PET for imaging beta-amyloid pathology. *JAMA*. 2011;305(3):275-283. [\[CrossRef\]](#)
4. Sperling RA, Johnson KA, Doraiswamy PM, et al. Amyloid deposition detected with florbetapir F 18 ((18)F-AV-45) is related to lower episodic memory performance in clinically normal older individuals. *Neurobiol Aging*. 2013;34(3):822-831. [\[CrossRef\]](#)
5. Namiki C, Takita Y, Iwata A, et al. Imaging characteristics and safety of florbetapir (<sup>18</sup>F) in Japanese healthy volunteers, patients with mild cognitive impairment and patients with Alzheimer's disease. *Ann Nucl Med*. 2015;29(7):570-581. [\[CrossRef\]](#)
6. Albert MS, DeKosky ST, Dickson D, et al. The diagnosis of mild cognitive impairment due to Alzheimer's disease: recommendations from the National Institute on Aging-Alzheimer's Association workgroups on diagnostic guidelines for Alzheimer's disease. *Alzheimers Dement*. 2011;7(3):270-279. [\[CrossRef\]](#)
7. Matsuda H. Cerebral blood flow and metabolic abnormalities in Alzheimer's disease. *Ann Nucl Med*. 2001;15(2):85-92. [\[CrossRef\]](#)
8. Chételat G, Desgranges B, de la Sayette V, Viader F, Eustache F, Baron JC. Mild cognitive impairment: can FDG-PET predict who is to rapidly convert to Alzheimer's disease? *Neurology*. 2003;60(8):1374-1377. [\[CrossRef\]](#)
9. Yeo JM, Lim X, Khan Z, Pal S. Systematic review of the diagnostic utility of SPECT imaging in dementia. *Eur Arch Psychiatry Clin Neurosci*. 2013;263(7):539-552. [\[CrossRef\]](#)
10. Minoshima S, Giordani B, Berent S, Frey KA, Foster NL, Kuhl DE. Metabolic reduction in the posterior cingulate cortex in very early Alzheimer's disease. *Ann Neurol*. 1997;42(1):85-94. [\[CrossRef\]](#)
11. Matsuda H, Mizumura S, Nagao T, et al. Automated discrimination between very early Alzheimer disease and controls using an easy Z-score imaging system for multicenter brain perfusion single-photon emission tomography. *AJNR Am J Neuroradiol*. 2007;28(4):731-736.
12. Reisberg B, Pritchard L, Mosconi L, et al. The pre-mild cognitive impairment, subjective cognitive impairment stage of Alzheimer's disease. *Alzheimers Dement*. 2008;4(1):S98-S108. [\[CrossRef\]](#)
13. Mitchell AJ, Beaumont H, Ferguson D, Yadegarfar M, Stubbs B. Risk of dementia and mild cognitive impairment in older people with subjective memory complaints: meta-analysis. *Acta Psychiatr Scand*. 2014;130(6):439-451. [\[CrossRef\]](#)
14. Amariglio RE, Becker JA, Carmasin J, et al. Subjective cognitive complaints and amyloid burden in cognitively normal older individuals. *Neuropsychologia*. 2012;50(12):2880-2886. [\[CrossRef\]](#)
15. Jessen F, Amariglio RE, van Boxtel M, et al. A conceptual framework for research on subjective cognitive decline in preclinical Alzheimer's disease. *Alzheimers Dement*. 2014;10(6):844-852. [\[CrossRef\]](#)
16. Petersen RC, Smith GE, Waring SC, Ivnik RJ, Tangalos EG, Kokmen E. Mild cognitive impairment: clinical characterization and outcome. *Arch Neurol*. 1999;56(3):303-308. [\[CrossRef\]](#)
17. Folstein MF, Folstein SE, McHugh PR. "Mini-mental state". A practical method for grading the cognitive state of patients for the clinician. *J Psychiatr Res*. 1975;12(3):189-198. [\[CrossRef\]](#)
18. Wong DF, Rosenberg PB, Zhou Y, et al. In vivo imaging of amyloid deposition in Alzheimer disease using the radioligand 18F-AV-45 (F 18 florbetapir). *J Nucl Med*. 2010;51(6):913-920. [\[CrossRef\]](#)
19. Joshi AD, Pontecorvo MJ, Lu M, Skovronsky DM, Mintun MA, Devous MD, Sr. A semiautomated method for quantification of F 18 florbetapir PET images. *J Nucl Med*. 2015 ;56(11):1736-1741. [\[CrossRef\]](#)
20. Bäckman L, Jones S, Berger AK, Laukka EJ, Small BJ. Cognitive impairment in preclinical Alzheimer's disease: a meta-analysis. *Neuropsychology*. 2005;19(4):520-531. [\[CrossRef\]](#)
21. Jansen WJ, Ossenkoppele R, Knol DL, et al. Prevalence of cerebral amyloid pathology in persons without dementia: a meta-analysis. *JAMA*. 2015;313(19):1924-1938. [\[CrossRef\]](#)
22. Jack CR, Jr, Wiste HJ, Weigand SD, et al. Age-specific population frequencies of cerebral  $\beta$ -amyloidosis and neurodegeneration among people with normal cognitive function aged 50-89 years: a cross-sectional study. *Lancet Neurol*. 2014;13(10):997-1005. [\[CrossRef\]](#)
23. Yokoyama S, Kajiyama Y, Yoshinaga T, Tani A, Hirano H. Imaging discrepancies between magnetic resonance imaging and brain perfusion single-photon emission computed tomography in the diagnosis of Alzheimer's disease, and verification with amyloid positron emission tomography. *Psychogeriatrics*. 2014;14(2):110-117. [\[CrossRef\]](#)
24. Takemaru M, Kimura N, Abe Y, Goto M, Matsubara E. The evaluation of brain perfusion SPECT using an easy Z-score imaging system in the mild cognitive impairment subjects with brain amyloid-beta deposition. *Clin Neurol Neurosurg*. 2017;160:111-115. [\[CrossRef\]](#)
25. Takahashi M, Tada T, Nakamura T, Koyama K, Momose T. Efficacy and limitations of rCBF-SPECT in the diagnosis of Alzheimer's disease with amyloid-PET. *Am J Alzheimers Dis Other Dement*. 2019;34(5):314-321. [\[CrossRef\]](#)
26. Funaki K, Nakajima S, Noda Y, et al. Can we predict amyloid deposition by objective cognition and regional cerebral blood flow in patients with subjective cognitive decline? *Psychogeriatrics*. 2019;19(4):325-332. [\[CrossRef\]](#)
27. Johnson KA, Minoshima S, Bohnen NI, et al. Appropriate use criteria for amyloid PET: a report of the Amyloid Imaging Task Force, the Society of Nuclear Medicine and Molecular Imaging, and the Alzheimer's Association. *Alzheimers Dement*. 2013;9(1):e1-16.
28. Mitchell AJ. A meta-analysis of the accuracy of the Mini-Mental State Examination in the detection of dementia and mild cognitive impairment. *J Psychiatr Res*. 2009;43(4):411-431. [\[CrossRef\]](#)
29. Nasreddine ZS, Phillips NA, Bédirian V, et al. The Montreal Cognitive Assessment, MoCA: a brief screening tool for mild cognitive impairment. *J Am Geriatr Soc*. 2005;53(4):695-699. [\[CrossRef\]](#)