

Clinico-Radiological Outcome of Single-Level and Hybrid Total Disc Replacement with Spineart Baguera®-C for Cervical Myeloradiculopathy: Minimum 2-Year Follow-Up Study in Indian Population

Abstract:

Context: Cervical radiculopathy and myelopathy is one of the most frequent ailments encountered by spine surgeon. Motion-preserving surgeries in cervical spine is a standard of care due to its certain advantages such as biomechanical anatomical conformity, reduced chances of adjacent segment degeneration, and revision surgeries. While there is abundant data from some centers, data from developing countries are still limited. **Aims:** The aim was to study the clinico-radiological outcome of single-level and hybrid total disc replacement (TDR) with Spineart Baguera®-C cervical prosthesis for cervical myeloradiculopathy. **Settings and Design:** Retrospective study. **Materials and Methods:** Retrospective analysis of the 29 consecutive patient undergoing single level TDR and hybrid fixation (i.e., TDR with anterior cervical discectomy and fusion) with Spineart Baguera®-C cervical prosthesis for myeloradiculopathy from January 1, 2014 to December 31, 2017, was done. Radiological features and outcome were studied from data collected on Insta-picture archiving and communication system. **Statistical Analysis Used:** SAS 9.4 was used for all computations. Results on continuous measurements were presented as mean and standard deviation (min-max) and results on categorical measurements were presented as numbers (*n*) and percentages. **Results:** Twenty-nine patients were included in the study. The mean age was 43.31 ± 9.04 years with 14 males and 15 females. The most common level of TDR was C5-C6 (72.41%). The mean follow-up duration was 3.14 years \pm 1.13 years (2–5 years). The mean hospital stay was 4.93 ± 2.12 days. The mean neck disability index (NDI) at admission was 27.24 ± 7.66 which decreased to 6.41 ± 4.29 at final follow-up. **Conclusions:** Two-year data on treatment with Spineart Baguera®-C cervical prosthesis shows significantly improved NDI, visual analog scale (arm) with maintenance of movement of the prosthesis.

Keywords: Cervical, myeloradiculopathy, Spineart Baguera®-C, total disc replacement

Introduction

The total disc replacement (TDR) has been in use since the late 1950 due to its proposed biomechanical and anatomical advantages.^[1] It offers advantages over fusion such as it maintains the operated segment's mobility and enables a better strain distribution on the contiguous disc levels as well as on the zygapophysis. Furthermore, it may aid in maintaining cervical lordosis and restoring the disc's height, which allows a good radicular decompression.^[2]

Anterior cervical discectomy and fusion (ACDF) has been considered gold standard since ages for cervical degenerative disorders who have failed conservative treatment.^[3,4] Recent understanding of adjacent segment degeneration and

pseudoarthrosis in some patients with fusion surgery with similar or even better outcome of TDR in same patients had led to rampant use and research in field of TDR in last decade.^[5-9] Various kinds of cervical prosthesis have been developed since then, one among which is Baguera® C cervical prosthesis.^[10,11] The Baguera® C cervical prosthesis is considered easier of cervical prosthesis as far as implantation is concerned.^[2] The authors have reported outcome of this device previously but no studies has been reported from the Indian subcontinent.^[12,13] In this manuscript, we report the clinico-radiological outcome of consecutively operated cases of TDR with Spineart Baguera®-C.

This is an open access journal, and articles are distributed under the terms of the Creative Commons Attribution-NonCommercial-ShareAlike 4.0 License, which allows others to remix, tweak, and build upon the work non-commercially, as long as appropriate credit is given and the new creations are licensed under the identical terms.

For reprints contact: WKHLRPMedknow_reprints@wolterskluwer.com

Jeevan Kumar
Sharma,
Tarush Rustagi,
Nandan Marathe,
Abhinandan Reddy
Mallepally,
Rajat Mahajan,
Harvinder Singh
Chhabra,
Kalidutta Das

Indian Spinal Injuries Center,
New Delhi, India

Address for correspondence:
Dr. Jeevan Kumar Sharma,
Indian Spinal Injuries Center,
Sector-C, Vasant Kunj,
New Delhi - 110 070, India.
E-mail: jeev208@gmail.com

Access this article online

Website: www.asianjns.org

DOI: 10.4103/ajns.AJNS_288_20

Quick Response Code:



How to cite this article: Sharma JK, Rustagi T, Marathe N, Mallepally AR, Mahajan R, Chhabra HS, *et al.* Clinico-radiological outcome of single-level and hybrid total disc replacement with spineart Baguera®-C for cervical myeloradiculopathy: Minimum 2-year follow-up study in Indian population. *Asian J Neurosurg* 2020;15:856-62.

Submitted: 11-Jun-2020

Revised: 08-Jul-2020

Accepted: 17-Sep-2020

Published: 21-Dec-2020

Materials and Methods

Retrospective analysis of clinical and radiological data of patients who underwent TDR or hybrid fixation (TDR with adjacent level ACDF) for cervical myeloradiculopathy from January 1, 2014 to December 31, 2017 was performed.

Inclusion criteria were symptomatic disc disease (radiculopathy/myelopathy) at one to two level in the subaxial cervical spine patients (18–80 years) with symptoms refractory to a thorough trial of conservative management (4–6 weeks).

Exclusion criteria for cervical TDR were pathology at more than two level, prior fusion at an adjacent level, instability on flexion–extension radiographs, inflammatory arthropathy, osteoporosis, infection and severe facet arthropathy at the affected level. History of prior cervical laminectomy and posterior compressive disease not amenable to decompression through an anterior approach were also excluded.

Details on preoperative, operative, and follow-up details of patients were retrieved from medical record section. Radiological data were retrieved and reviewed on Insta-PACS (picture archiving and communication system) version 4.0. Patients were followed up with X-rays in the preoperative, postoperative, 6 weeks, 3 months, 12 months, and final follow-up [Figure 1].

Surgical details included hospital stay, operative time, blood loss, and any intraoperative or postoperative

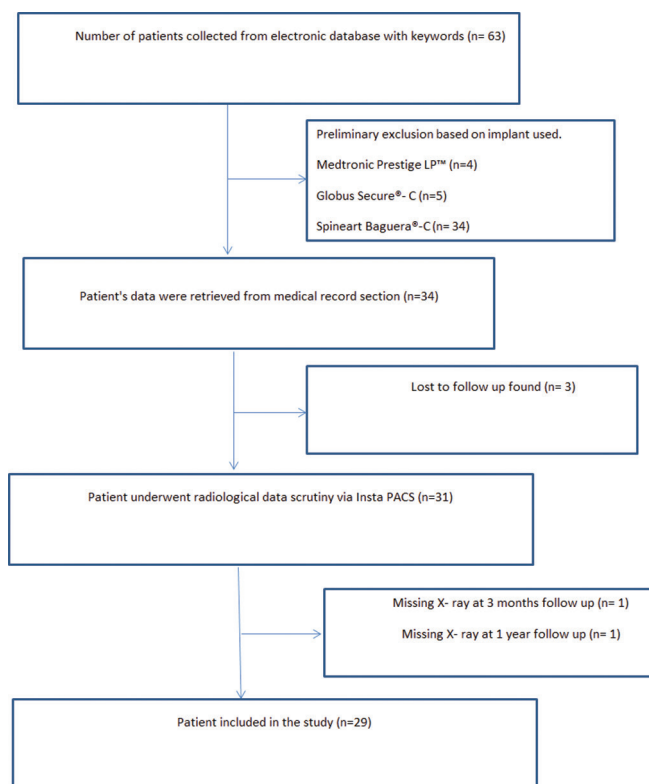


Figure 1: Flowchart depicting inclusion of patients in the study

complication. Clinical details included-Japanese Orthopaedic Association (JOA) score, visual analogue scale (VAS) arm, neck disability index (NDI). Radiological assessment included-range of motion (ROM) of prosthesis (The difference in the angular measurement between the lower endplate of upper vertebra and upper endplate of lower vertebra in flexion and extension X-rays), ROM of adjacent level (Difference in the angular measurement at the supra-adjacent level), C2-C7 alignment (Cobb angle between C2 inferior end plate and C7 superior end plate on neutral X-ray), Implant subsidence was measured in neutral X-ray. Middle disc height was measured at TDR level and upper adjacent level to quantify subsidence. All radiological measurements were done using Insta PACS version 4.0 (Meddiff Technologies Pvt. Ltd, Bengaluru, Karnataka, India). computed tomography scan was used to assess for heterotopic ossification (HO) at final follow up. HO were assessed according to the Mehren/Suchomel modification of McAfee scale.^[14] It consisted of zero to four grades. Grade 0: No HO present, Grade I: HO is detectable in front of the vertebral body but not in the anatomic interdiscal space, Grade II: HO is growing into the disc space with possible affection of the function of the prosthesis, Grade III: Bridging ossifications which still allow movement of the prosthesis, Grade IV: Complete fusion of the treated segment without movement in flexion. Radiological data set was blinded and assessed by a fellowship trained spine surgeon.

Surgical details

The patient was placed on the operating table in the supine position with the neck in the neutral position. The patient's head was secured in place with tape across the forehead to maintain a neutral position, and his or her shoulders are secured down with tape to allow for proper visualization with fluoroscopy. The endplates was examined on lateral fluoroscopy to visualize that they are positioned in a parallel position. The Smith–Robinson approach was used. Excessive exposure was avoided. Distraction pins were placed into the vertebral bodies directly superior and inferior to the disc space. The pins are placed in the midline of the vertebral body on the anteroposterior view. The discectomy and decompression was then performed. Once the discectomy was completed, release of the posterior longitudinal ligament to allow for a thorough assessment of the posterior and postero-lateral decompression. Care was taken to remove all osteophytes as required. Effort was given to minimize the use of high speed burr to prevent any bone debris. Abundant irrigation was done and all bleeding edges were meticulously bone waxed.^[5] Trials are then used to determine proper implant size in all dimensions (height, width, and depth) and ensure proper alignment with the guidance of fluoroscopic imaging. Largest possible size implant in the anteroposterior and mediolateral planes was chosen. Once the proper implant size has been selected, it was placed in the disc space on lateral fluoroscopy and confirmed on the AP view. The size of the implant was

based on a trial that occupies maximum width and depth with the posterior border of the trial flush to the posterior vertebral border [Figures 2-4].

Hybrid surgery, consisting of TDR at the mobile level, along with ACDF at the spondylotic level, was done for patients with multilevel cervical degenerative disc disease [Figure 5]. Postoperatively patients were mobilized on first postoperative day, advised soft cervical collar for 2 weeks. All cases were started on Indomethacin 150 mg for 14 days.

Implant feature

The Baguera® C cervical prosthesis (Spineart SA, Geneva, Switzerland) is a biomechanical device designed to be used for TDR. It consists of a high-density polyethylene (PE) nucleus that articulates between two titanium endplate components, with a porous coated exterior and a diamond-like carbon-coated interior. The implant allows a physiological rotation as well as translation in both the anterior-posterior (± 0.3 mm) and rotational ($\pm 2^\circ$) directions. The controlled mobility of the PE nucleus is designed to prevent excessive constraints on the facet joints, and its curve is designed to respect axial rotation movements. The inferior plate and PE design allow 0.15 mm elastic deformation to absorb shocks and vibrations.^[12]

Statistical analysis

SAS 9.4 was used for all computations. Results on continuous measurements are presented as mean, Standard deviation (min-max) and results on categorical

measurements are presented as numbers (n) and percentages. The significance is assessed at 5% level of significance. Student's *t*-test (2×1 tailed)/Mann-Whitney test has been utilized to find the significance of parameters on a continuous scale between two groups as per the distribution of data.

Results

Twenty-nine patients were included in the study. Eighteen patients underwent TDR while 11 patients underwent hybrid fixation. Twenty-seven patients were operated for symptoms of radiculopathy, while two patients were operated for radiculomyelopathy. The mean age was 43.31 ± 9.04 years with 14 males and 15 females [Table 1]. The most common level of TDR was C5–C6 (72.41%). The mean follow-up duration was 3.14 ± 1.13 years (2–5 years). The mean hospital stay was 4.93 ± 2.12 days. The average surgical time was 193.64 ± 28.73 min in hybrid group and 170.83 ± 46.15 min in TDR only group, and blood loss was $155.55 \text{ mL} \pm 60.96 \text{ mL}$.

Clinical outcome

The mean NDI improved from 27.24 ± 7.66 to 6.41 ± 4.29 at final follow up ($P < 0.0001$). The mean JOA (two patient) improved from 13 to 15.5. VAS (arm) improved from 7.17 ± 1.26 to 0.34 ± 0.55 ($P < 0.0001$) at final follow-up [Table 2]. Significant improvement was also seen in the VAS and NDI from preoperative to 3 months.

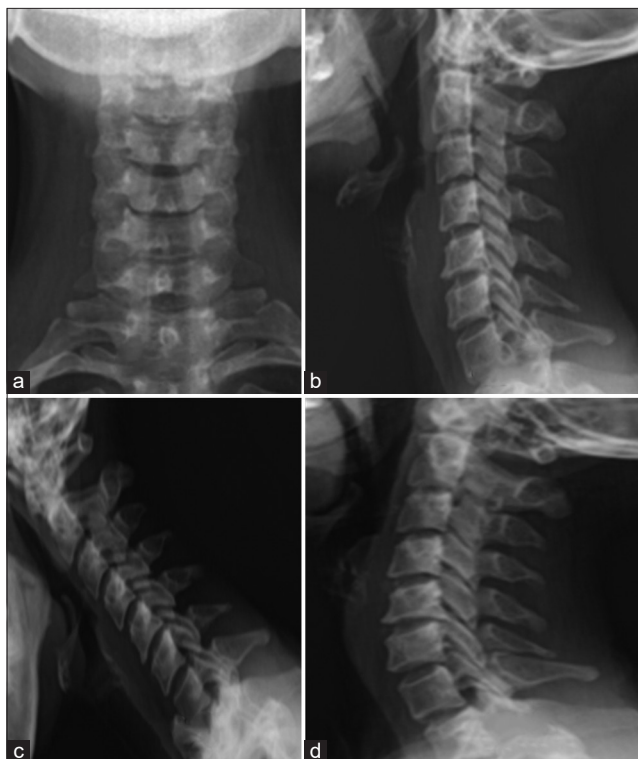

Figure 2: Preoperative X-ray – anterior-posterior view (a), lateral view – neutral (b), lateral view – flexion (c), lateral view – extension (d)

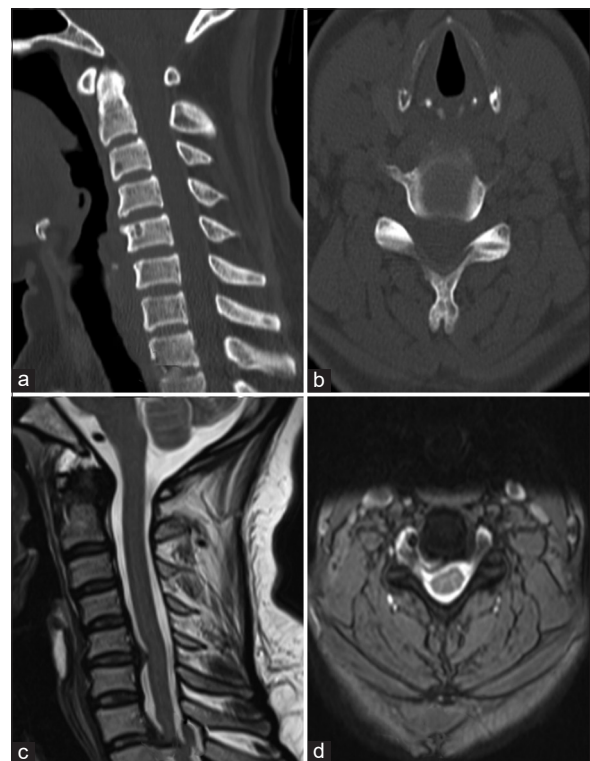


Figure 3: Preoperative computed tomography scan – sagittal view (a), axial view (b), preoperative magnetic resonance imaging sagittal view (c), axial view (d)

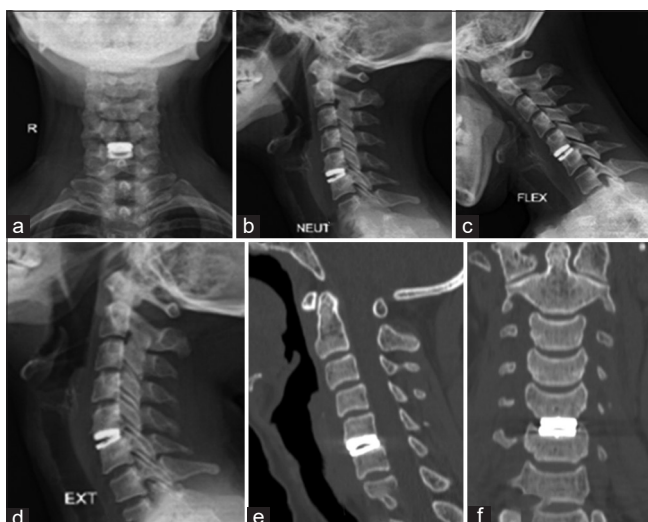

Figure 4: Postoperative X-ray of patient with total disc replacement – anterior-posterior view (a), lateral view-neutral (b), lateral view – flexion (c), lateral view – extension (d); Postoperative computed tomography scan of patient with total disc replacement -sagittal view (e), coronal view (f)

Table 1: Demographics of patients enrolled in the study	
Parameters	Observations
Sex distribution	
Male	14
Female	15
Mean age (years)	43.31±9.04
Symptom distribution	
Radiculopathy	27
Myeloradiculopathy	2
Surgical procedure	
TDR alone	18
Hybrid fixation	11
Level of TDR	
C3-C4	1
C4-C5	4
C5-C6	21
C6-C7	3

TDR – Total disc replacement

Radiological outcome

The mean ROM of prosthesis was 9.85 ± 0.86 (8.4–12.2) at 3-month follow-up which reduced to 8.47 ± 0.80 (7–10.4) at final follow-up ($P < 0.0001$). The mean ROM of adjacent level was 10.33 ± 0.81 which increased to 10.45 ± 0.81 at final follow-up ($P = 0.0001$). Mean C2-C7 alignment preoperatively was 52.34 ± 2.31 which was 51.46 ± 3.04 at final follow up ($P = 0.0001$) [Table 3]. Disc height at prosthesis level was 4.09 ± 0.39 mm which increased to 6.77 ± 0.33 mm at 3 months of follow-up ($P < 0.0001$) and reduced to 6.58 ± 0.28 at final follow up ($P = 0.0001$) [Figure 6]. Disc height at upper adjacent level was 4.17 ± 0.41 preoperatively, and 4.10 ± 0.39 at final follow up ($P = 0.0005$). At final follow-up HO was seen in 8 (27.6%) patients. There was Grade 0 HO in 21 (72.4%) patients, Grade I HO in 3 (10.34%), Grade II

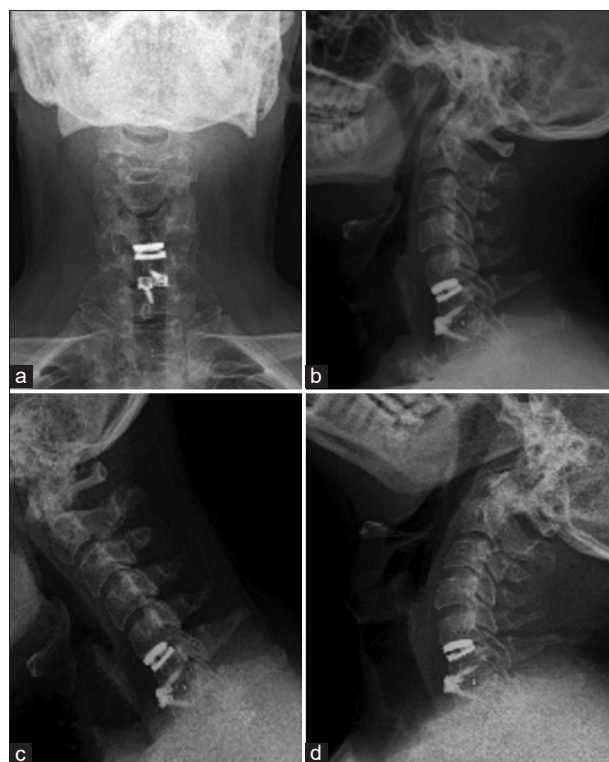

Figure 5: Postoperative X-ray of patient with hybrid fixation- anterior-posterior view (a), lateral view – neutral (b), lateral view – flexion (c), lateral view – extension (d)

HO in 2 (6.90%), Grade III HO in 2 (6.90%), Grade IV HO in 1 (3.45%) patient. HO restricting mobility was seen in 3 patients, Grade III HO in 2 (6.9%) patients and Grade IV HO in 1 (3.45%) patient. Hence at the final follow-up, mobility on prosthesis was seen in 89.65%.

Discussion

In our study using Baguera device with minimum 2-year follow-up, 89.65% cases had maintained mobility at the disc with an average movement of over 8° at final follow up. Significant improvement in VAS and NDI was seen. Heterotrophic ossification was seen in 27.6% of cases with severe (Grade 3 and Grade 4) grade in 10.34% cases.

ACDF, a safe and reliable technique, is regarded as the gold standard procedure for single or multilevel cervical spondylosis leading to radiculopathy and/or myelopathy.^[15,16] Over the years, cervical disc replacement has become an alternative in select cases over anterior cervical fusion. Fusion has been found to be associated with a risk of around 2.4% cumulative rate of symptomatic adjacent segment with 22.2% cases needing revision surgery at 10 years.^[17] Studies have shown significantly lesser re-operation rates and improved NDI after 10 years of disc replacement compared to fusion.^[18,19]

Over the past 40 years, there have been several designs for cervical disc prosthesis. Metal-on-metal prostheses

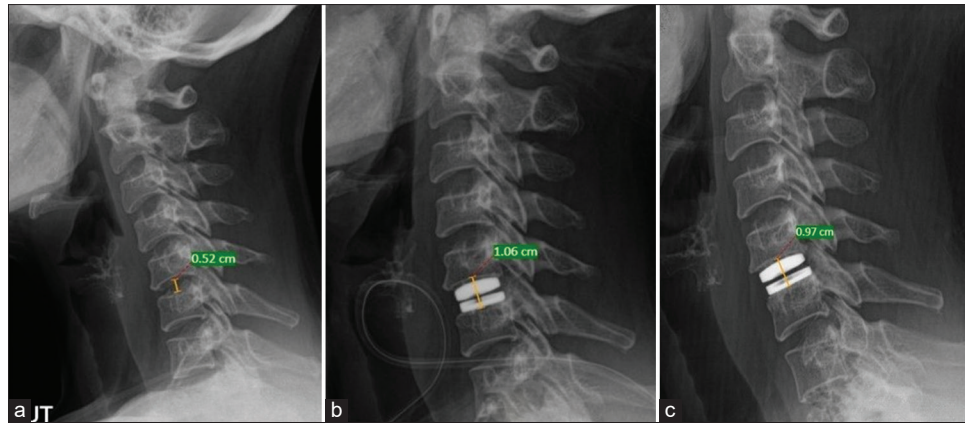


Figure 6: X-ray depicting disc height preoperatively-0.52 cm (a), immediate postoperatively-1.06 cm (b), 3 months postoperatively – 0.97 cm (c) in a patient with total disc replacement

Table 2: Clinical outcome of patients enrolled in the study

Clinical outcomes	Preoperatively	3 months	1 year	Final follow up	Preoperative to 3 months	3 months to final	Preoperative to final
Mean VAS (n=29)	7.17±1.26	3.69±1.31	1.73±0.62	0.34±0.55	S	S	S
Mean NDI (n=29)	27.24±7.66	11.17±5.0	8.31±4.27	6.41±4.29	S	S	S
Mean JOA (n=2)	13	13.5	14.5	15.5			

S – Significant ($P < 0.0001$); JOA – Japanese orthopaedic association; VAS – Visual Analogue Scale; NDI – Neck disability Index

Table 3: Radiological outcome of patients enrolled in the study

Radiological outcomes	Preoperative	3 months	1 year	Final follow up	Preoperative to 3 months (P)	3 months to final (P)	Preoperative to final (P)
ROM of prosthesis	10.11±0.88	9.85±0.86	9.47±0.85	8.47±0.80	<0.0001	<0.0001	<0.0001
ROM of adjacent level	10.33±0.81	10.02±0.82	9.53±0.87	8.64±0.77	0.0001	-	0.0001
C2-C7 alignment	52.34±2.31	51.42±2.33	50.81±2.79	51.46±3.04	0.377	-	0.0001
Disc height at prosthesis level	4.09±0.39	6.77±0.33	6.58±0.29	6.58±0.28	<0.0001	0.1616	0.0001
Disc height at upper adjacent level	4.17±0.41	4.17±0.40	4.12±0.32	4.10±0.39	0.2	0.422	0.0005

ROM – Range of motion

include the Bristol Disc, Cummins design, Prestige Disc (Medtronic Sofamor Danek, Memphis, Tennessee), and Cervicore (SpineCore, Stryker Spine, Allendale, New Jersey) system. Another commonly used design uses metal end plates with a “plastic” center. Prostheses using a PE center include the ProDisc-C (Synthes-Stratec) and the Porous-Coated Motion (PCM) cervical artificial disc (Cervitech, Inc., Rockaway, New Jersey). The Bryan Cervical Disc Prosthesis (Medtronic Sofamor Danek, Memphis, Tennessee) is another metal-polymer implant that uses a polyurethane center.^[20]

The Baguera®C cervical prosthesis (Spineart SA, Geneva, Switzerland) is a biomechanical device designed to be used for TDR. It consists of a high-density PE nucleus that articulates between two titanium endplate components, with a porous-titanium-coated exterior and a bio ceramic coated interior, in contact with the PE nucleus.^[13]

We found significant and sustained improvement in clinical results. Irrespective, of the device type, most studies report similar improvement in clinical parameters.^[13,18,19,21-23]

In a 2-year follow-up study using Baguera, Fransen *et al.* found decrease by around 2° in the ROM, Our study showed an average reduction on 1.64° at final follow up. Mobility at the treated level after 2 years of TDR using Baguera was evaluated by the ROM between flexion and extension; mobility is present when ROM value is at least 2°, or better 4° as suggested by Vital *et al.*^[24] The preserved ROM is from the semi-constraint design of the implant which consist of semi mobile nucleus that allows for near physiological cervical motion compared to a constraint device.^[12,13,25] The adjacent level ROM in the Fransen study was in contrast to ours, where they showed an increased ROM of the adjacent segment from 10.5° to 13.6° at 2 years.^[12,13] This could be from differences in the study cohort. Two years studies of other disc devices show an average of 6.5° of ROM with Prodisc C, 7.55° for Prestige and 8.1° for Bryan.^[21,22,26,27] These slight differences could be because of the cohort difference, difference in the pre-operative ROM, difference rate of occurrence of HO and the device design itself. Few devices need to have a keel prepared or some bony work done on the end plates

in order to place the device. This is in contrast to Baguera, which does not need any end plate preparation.

There was also a nonsignificant subsidence seen with the use of the implant in our study. Similar subsidence was also seen in study by Fransen *et al.*^[12,13] Though they did not discuss the reason for this late nonsignificant subsidence, it is perhaps from the sinking of the implant spikes into the end plates over time.[Figure 4] Other devices, that use a keel or screws for fixation, do not show subsidence.

We found advanced HO occurring in 10.35% of our cases and no or Grade I HO in 72.40% cases. Fransen *et al.* had 19.3% cases of Grade 3 and 4 HO in their 2-year follow-up study using Baguera device.^[13] Wide variation is seen in the occurrence of HO (7.3%–69.2%).^[14,28–30] Yi *et al.* found certain factors as significant such as male sex, and implant type. They reported Prodisc-C having the highest rate followed by Mobi-C then Bryan.^[28] Though, advanced stages of HO are associated with reduced movement of the prosthesis, its clinical significance is yet to be conclusively determined. A study looking at the impact of HO on patient outcomes showed no statistical difference in terms of VAS neck pain, VAS arm pain, and NDI score when compared to a control group, though ROM was less in patients who developed HO.^[31] With longer follow ups coming, presence of HO may be a rule rather than an exception in TDR. Its occurrence has been influenced by patient selection, type of implant and surgical technique. Noriega *et al.* in a comparative study found Grade 1 or no HO in 67% cases of Baguera compared to 10.5% with Prodisc C. Advanced HO (Grade 3 or 4) was seen in 18.5% cases using Baguera compared to 73.8% using Prodisc and 65% using PCM.^[32]

Certain factors have been implicated to reduce the occurrence of HO. Placement of the device as posterior as possible to allow maximum motion of the device, avoiding unnecessary bony exposure, liberal use of bone wax, avoiding use of drill helps to prevent release of bone growth factors.^[12,29,32] Additionally implant that are placed without the need of drilling or keel also help in reducing the incidence of HO due to reduction of release of bone growth factors from marrow. Baguera design avoids need of drilling and keel may assist in lesser incidence of higher grades of HO.^[12,13] Use of anti-inflammatory medication for prevention of HO has been looked in cervical disc and hip replacement surgery literature. Although, there is no conclusive evidence in support for this, we used Indomethacin in our series.^[33–35]

Hybrid constructs has become vogue currently for multilevel cervical spondylosis with adequate literature available on its efficacy and good clinical results. It has been considered safe, reliable and effective modality of treatment for multilevel spondylosis.^[36,37] Our results were also similar to other studies with significantly better clinical and radiological outcomes with none having any complications at 2 years follow up.

The limitation of this study was a small sample size. It was a retrospective and noncomparative study with no control arm. Our follow up period was also relatively small and we were not able to assess revision surgeries, however we did see relative preservation of adjacent segment ROM and disc height in our study. In spite of the limitations, we feel that our study might set up a benchmark of applicability of TDR and H-TDR in developing nation with good clinico-radiological outcome.

Conclusions

Spineart Baguera®-C cervical prosthesis used alone or as hybrid construct has good clinico-radiological outcome. Average ROM was maintained at over 8° and advanced heterotrophic ossification was seen in 10.35% cases. Significant improvement was seen in VAS (arm) and NDI.

Financial support and sponsorship

Nil.

Conflicts of interest

There are no conflicts of interest.

References

- Fernström U. Arthroplasty with intercorporeal endoprosthesis in herniated disc and in painful disc. *Acta Chir Scand Suppl* 1966;357:154-9.
- Benmekhbi M, Mortada J, Lungu G, Eichler D, Srour R, Vital JM. Baguera cervical disc prosthesis. *Interact Surg* 2008;3:201-4.
- Cloward R. The anterior approach for ruptured cervical discs. *J Neurosurg* 1958;15:602-14.
- Robinson R, Smith G. Anterolateral cervical disc removal and interbody fusion for cervical disc syndrome. *Bull John Hopkins Hosp* 1955;96:223-4.
- Matsumoto M, Okada E, Ichihara D, Watanabe K, Chiba K, Toyama Y, *et al.* Anterior cervical decompression and fusion accelerates adjacent segment degeneration: Comparison with asymptomatic volunteers in a ten-year magnetic resonance imaging follow-up study. *Spine (Phila Pa 1976)* 2010;35:36-43.
- Helgeson MD, Bevevino AJ, Hilibrand AS. Update on the evidence for adjacent segment degeneration and disease. *Spine J* 2013;13:342-51.
- Xu B, Ma JX, Tian JH, Ge L, Ma XL. Indirect meta-analysis comparing clinical outcomes of total cervical disc replacements with fusions for cervical degenerative disc disease. *Sci Rep* 2017;7:1740.
- Gao F, Mao T, Sun W, Guo W, Wang Y, Li Z, *et al.* An updated meta-analysis comparing artificial cervical disc arthroplasty (CDA) versus anterior cervical discectomy and fusion (ACDF) for the treatment of cervical degenerative disc disease (CDDD). *Spine (Phila Pa 1976)* 2015;40:1816-23.
- Hu Y, Lv G, Ren S, Johansen D. Mid-to long-term outcomes of cervical disc arthroplasty versus anterior cervical discectomy and fusion for treatment of symptomatic cervical disc disease: A systematic review and meta-analysis of eight prospective randomized controlled trials. *PLoS One* 2016;11:e0149312.
- Murtagh R, Castellvi AE. Motion preservation surgery in the spine. *Neuroimaging Clin N Am* 2014;24:287-94.
- Turel MK, Kerolus MG, Adogwa O, Traynelis VC. Cervical

- arthroplasty: What does the labeling say? *Neurosurg Focus* 2017;42:E2.
12. Fransen P, Pointillart V. Arthroplasty with the Baguera cervical disc prosthesis: A review of the scientific background, clinical and radiographic evidences. *J Spine Neurosurg*. 2016;05:1-5.
 13. Fransen P, Hansen-Algenstaedt N. Radiographic outcome and adjacent segment evaluation two years after cervical disc replacement with the Baguera®C prosthesis as treatment of degenerative cervical disc disease. *J Spine*. 2016;05:1-7.
 14. Mehren C, Suchomel P, Grochulla F, Barsa P, Sourkova P, Hradil J, et al. Heterotopic ossification in total cervical artificial disc replacement. *Spine (Phila Pa 1976)* 2006;31:2802-6.
 15. Suchomel P, Barsa P, Buchvald P, Svobodnik A, Vanickova E. Autologous versus allogenic bone grafts in instrumented anterior cervical discectomy and fusion: A prospective study with respect to bone union pattern. *Eur Spine J* 2004;13:510-5.
 16. Löfgren H, Engquist M, Hoffmann P, Sigstedt B, Vavruch L. Clinical and radiological evaluation of Trabecular Metal and the Smith-Robinson technique in anterior cervical fusion for degenerative disease: A prospective, randomized, controlled study with 2-year follow-up. *Eur Spine J* 2010;19:464-73.
 17. Lee JC, Lee SH, Peters C, Riew KD. Risk-factor analysis of adjacent-segment pathology requiring surgery following anterior, posterior, fusion, and nonfusion cervical spine operations: Survivorship analysis of 1358 patients. *J Bone Joint Surg Am* 2014;96:1761-7.
 18. Sasso WR, Smucker JD, Sasso MP, Sasso RC. Long-term clinical outcomes of cervical disc arthroplasty: A prospective, randomized, controlled trial. *Spine (Phila Pa 1976)* 2017;42:209-16.
 19. Lavelle WF, Riew KD, Levi AD, Florman JE. Ten-year outcomes of cervical disc replacement with the BRYAN cervical disc: Results from a prospective, randomized, controlled clinical trial. *Spine (Phila Pa 1976)* 2019;44:601-8.
 20. Durbhakula MM, Ghiselli G. Cervical total disc replacement, part I: Rationale, biomechanics, and implant types. *Orthop Clin North Am* 2005;36:349-54.
 21. Malham GM, Parker RM, Ellis NJ, Chan PG, Varma D. Cervical artificial disc replacement with ProDisc-C: Clinical and radiographic outcomes with long-term follow-up. *J Clin Neurosci* 2014;21:949-53.
 22. Mummaneni PV, Burkus JK, Haid RW, Traynelis VC, Zdeblick TA. Clinical and radiographic analysis of cervical disc arthroplasty compared with allograft fusion: A randomized controlled clinical trial. *J Neurosurg Spine* 2007;6:198-209.
 23. Vaccaro A, Beutler W, Peppelman W, Marzluff JM, Highsmith J, Mugglin A, et al. Clinical outcomes with selectively constrained SECURE-C cervical disc arthroplasty: Two-year results from a prospective, randomized, controlled, multicenter investigational device exemption study. *Spine (Phila Pa 1976)* 2013;38:2227-39.
 24. Vital J, Guérin P, Gille O, Pointillart V. Prothèses discales cervicales. *EMC* 2011:44-162.
 25. Hisey MS, Zigler JE, Jackson R, Nunley PD, Bae HW, Kim KD, et al. Prospective, randomized comparison of one-level Mobi-C cervical total disc replacement vs. anterior cervical discectomy and fusion: Results at 5-year follow-up. *Int J Spine Surg* 2015;10:1-10.
 26. Murrey D, Janssen M, Delamarter R, Goldstein J, Zigler J, Tay B, et al. Results of the prospective, randomized, controlled multicenter Food and Drug Administration investigational device exemption study of the ProDisc-C total disc replacement versus anterior discectomy and fusion for the treatment of 1-level symptomatic cervical disc disease. *Spine J* 2009;9:275-86.
 27. Heller JG, Sasso RC, Papadopoulos SM, Anderson PA, Fessler RG, Hacker RJ, et al. Comparison of BRYAN cervical disc arthroplasty with anterior cervical decompression and fusion: Clinical and radiographic results of a randomized, controlled, clinical trial. *Spine (Phila Pa 1976)* 2009;34:101-7.
 28. Yi S, Kim KN, Yang MS, Yang JW, Kim H, Ha Y, et al. Difference in occurrence of heterotopic ossification according to prosthesis type in the cervical artificial disc replacement. *Spine (Phila Pa 1976)* 2010;35:1556-61.
 29. Chen J, Wang X, Bai W, Shen X, Yuan W. Prevalence of heterotopic ossification after cervical total disc arthroplasty: A meta-analysis. *Eur Spine J* 2012;21:674-80.
 30. Wu JC, Huang WC, Tsai HW, Ko CC, Fay LY, Tu TH, et al. Differences between 1-and 2-level cervical arthroplasty: More heterotopic ossification in 2-level disc replacement: Clinical article. *J Neurosurg Spine* 2012;16:594-600.
 31. Zhou HH, Qu Y, Dong RP, Kang MY, Zhao JW. Does heterotopic ossification affect the outcomes of cervical total disc replacement? A meta-analysis. *Spine (Phila Pa 1976)* 2015;40:E332-40.
 32. Noriega DC, Medrano BG, Cortes JM, Martinez M, Hernandez R, Plata M, et al. Severity of heterotopic ossification in relation to cervical prosthesis type and surgery-related factors. *Spine J*. 2012;12:S133-4.
 33. Tu TH, Wu JC, Huang WC, Wu CL, Ko CC, Chen H. The effects of carpentry on heterotopic ossification and mobility in cervical arthroplasty: Determination by computed tomography with a minimum 2-year follow-up. *J Neurosurg Spine* 2012;16:601-9.
 34. Zhu XT, Chen L, Lin JH. Selective COX-2 inhibitor versus non-selective COX-2 inhibitor for the prevention of heterotopic ossification after total hip arthroplasty: A meta-analysis. *Medicine (Baltimore)* 2018;97:e11649.
 35. Joice M, Vasileiadis GI, Amanatullah DF. Non-steroidal anti-inflammatory drugs for heterotopic ossification prophylaxis after total hip arthroplasty: A systematic review and meta-analysis. *Bone Joint J* 2018;100-B: 915-22.
 36. Zhu Y, Fang J, Xu G, Ye X, Zhang Y. A hybrid technique for treating multilevel cervical myelopathy: Cervical artificial disc replacement combined with fusion. *Oncol Lett* 2019;17:360-4.
 37. Lee SB, Cho KS, Kim JY, Yoo DS, Lee TG, Huh PW. Hybrid surgery of multilevel cervical degenerative disc disease: Review of literature and clinical results. *J Korean Neurosurg Soc* 2012;52:452-8.