


# Single-Stage Pulmonary Resection via a Combination of Single Hookwire Localization and Video-Assisted Thoracoscopic Surgery for Synchronous Multiple Pulmonary Nodules

Technology in Cancer Research & Treatment  
 Volume 20: 1–9  
 © The Author(s) 2021  
 Article reuse guidelines:  
[sagepub.com/journals-permissions](https://sagepub.com/journals-permissions)  
 DOI: 10.1177/15330338211042511  
[journals.sagepub.com/home/tct](https://journals.sagepub.com/home/tct)  


Xianglan Jin, MD<sup>1,\*</sup>, Tiegong Wang, MD, PhD<sup>2,\*</sup>, Luguang Chen, MSc<sup>2</sup>, Pengyi Xing, MD, PhD<sup>2</sup>, Xiaoyun Wu, MD, PhD<sup>1</sup>, Chengwei Shao, MD, PhD<sup>2</sup>, Bingding Huang, PhD<sup>3</sup> , and Wangfu Zang, MD, PhD<sup>1</sup>

## Abstract

**Purpose:** To retrospectively analyze the incidence and predictors of complications related to hookwire localization in patients with single and multiple nodules, and to evaluate the usefulness of a single-stage surgical method of single hookwire localization combined with video-assisted thoracoscopic surgery (VATS) in synchronous multiple pulmonary nodules (SMPNs). **Methods:** A total of 200 patients who underwent computed tomography (CT)-guided hookwire localization and subsequent VATS resection were enrolled in this study. For each patient, only 1 indeterminate nodule was implanted with a hookwire. There were 145 patients in the single-nodule group (Group S) and 55 in the multiple-nodule group (Group M). Univariate and binary logistic regression analyses were used to assess incidence and predictors of complications associated with hookwire localization. **Results:** The technical success rate of hookwire implantation was 97.5%. The incidence of pneumothorax and hookwire dislodgement was 17.0% and 2.5%, respectively. Binary logistic regression analysis showed that 1 transpleural puncture through the pleura (odds ratio [OR] = 0.433,  $P = .033$ ) was the only independent protective factor for pneumothorax, and pneumothorax (OR = 26.114,  $P < .01$ ) was the only independent risk factor for dislodgement. The volume of blood loss during VATS was significantly higher in group M than in group S, and the time of postoperative hospitalization was significantly longer in group M than in group S. About 44 patients in group M with additional 58 nodules without localization had undergone direct surgical resection simultaneously, and bilateral surgery was performed in 13 patients (29.5%). The intrathoracic recurrence rate was 4.8% during follow-up CT. **Conclusion:** Single-stage surgery via an approach of single hookwire localization combined with VATS is feasible and safe for SMPNs.

## Keywords

multiple pulmonary nodules, thoracic surgery, video-assisted, computed tomography, intraoperative complications

<sup>1</sup> Shanghai Tenth People's Hospital, Tongji University School of Medicine, Shanghai, China

<sup>2</sup> Changhai Hospital, Naval Medical University (Second Military Medical University), Shanghai, China

<sup>3</sup> College of Big Data and Internet, Shenzhen Technology University, Shenzhen, China

\*These authors contributed equally to this work.

## Corresponding Authors:

Chengwei Shao, MD, PhD, Department of Radiology, Changhai Hospital, Naval Medical University (Second Military Medical University), No. 168 Changhai Road, Shanghai 200433, China.

Email: [cwshao@sina.com](mailto:cwshao@sina.com)

Bingding Huang, PhD, College of Big data and Internet, Shenzhen Technology University, No. 3002 Lantian Road, Shenzhen 518118, Shenzhen, China.

Email: [huangbingding@sztu.edu.cn](mailto:huangbingding@sztu.edu.cn)

Wangfu Zang, MD, PhD, Department of Cardiac Surgery, Shanghai Tenth People's Hospital, Tongji University School of Medicine, No. 301 Yanchang Middle Road, Shanghai 200072, China.

Email: [zangwfsy@163.com](mailto:zangwfsy@163.com)



## Abbreviations

CT, computed tomography; SMPN, synchronous multiple pulmonary nodule; pGGN, pure ground-glass nodule; MPLC, multiple primary lung cancer; VATS, video-assisted thoracoscopic surgery; OR, odds ratio; CI, confidence interval; MIA, minimally invasive adenocarcinoma; IAC, invasive adenocarcinoma

Received: March 10, 2021; Revised: August 9, 2021; Accepted: August 10, 2021.

## Introduction

With the increasing awareness of health checkups and the wide use of low-dose computed tomography (CT) in lung cancer screening increase, a growing number of pulmonary nodules are incidentally detected, of which some are solitary or synchronous multiple pulmonary nodules (SMPNs).<sup>1</sup> One study on the follow-up of pure ground-glass nodules (pGGNs) <6 mm in size found that ~10% would grow, and ~1% eventually developed into adenocarcinoma over years.<sup>2</sup>

Multiple primary lung cancers (MPLCs) account for 3.7% to 8.0% of all lung cancer patients.<sup>3</sup> Patients with multiple ground-glass nodules on CT images should be staged as having MPLCs rather than intrapulmonary metastases.<sup>4</sup> The treatment strategy for multiple nodules can be follow-up, lung biopsy, or surgery. The 2017 Fleischner guidelines suggest that multiple pGGNs <6 mm in size are mostly benign, but for high-risk patients, follow-up observations should be performed for at least 2 to 4 years.<sup>5</sup> However, long-term follow-up leads to increased mental stress in patients due to the fear of metastasis. Although lung biopsy is minimally invasive, the false-negative rate for lung nodules smaller than 10 mm in size is still high.<sup>6</sup> Therefore, surgical resection may be a superior option for patients with high-risk nodules.

Video-assisted thoracoscopic surgery (VATS) wedge resection of target lesions can achieve the goal of diagnosis and treatment simultaneously, which is a minimally invasive method compared to traditional thoracotomy. Nevertheless, the difficulty of palpating the target nodule accurately during surgery has limited the application of VATS in small pulmonary nodules and deeper lesions.<sup>7</sup> To overcome this issue, a variety of preoperative or intraoperative positioning methods have been developed in recent years.<sup>8</sup> Hookwire localization is the most common preoperative placement method and was first proposed in 1992.<sup>9</sup> However, a recent retrospective analysis showed that prospective localization utilizing a hookwire was associated with a higher risk of complications than the use of lipiodol and microcoils, among which air embolism could be a fatal serious complication.<sup>8</sup> Recently, several studies have reported the use of CT-guided hookwire or microcoil for preoperative localization of SMPNs, which showed a good success rate, but had various complication rate, including pneumothorax and pulmonary hemorrhage.<sup>10–17</sup>

Therefore, the aim of this study was to retrospectively analyze the incidence and predictors of complications related to hookwire localization both in patients with single and multiple nodules, as well as to evaluate the usefulness of a single-

stage surgical method of single hookwire localization combined with VATS in SMPNs.

## Methods

### Patients

This study was approved by the committee on ethics of Medicine, Naval Medical University (Second Military Medical University), and informed consent was waived due to its retrospective nature.

From December 2014 to December 2020, data from consecutive patients with CT-guided hookwire localization and subsequent VATS resection for lung nodules at our hospital were retrospectively collected. The decision to request CT-guided hookwire localization was based on the multidisciplinary discussion between surgeons and radiologists. For patients with multiple nodules, only 1 indeterminate nodule that was most unlikely to be palpated during VATS was implanted with a hookwire.

The criteria for hookwire localization included a pulmonary nodule with morphology and/or interval changes suspicious for malignancy, a nodule with the largest diameter <20 mm, the nearest distance to the visceral pleural surface <40 mm, and the number of lung nodules <5. Patients who had a known history of extrathoracic tumors were excluded. Demographic information such as the gender and age of patients, the number of preoperative CT examinations, and observation time were recorded.

### CT-Guided Hookwire Localization

The procedure was performed under CT guidance by 2 interventional radiologists, both of whom had more than 5 years of experience, using a 20-gauge hookwire (Pajunk, Medizintechnologie) with a length of 100 mm. CT scans were taken by a 16-row multidetector CT scanner (uCT 510, United Imaging Healthcare) or a 128-row multidetector CT scanner (Brilliance Intellispace iCT, Philips Healthcare). The parameters of the tube voltage, tube current, and section thickness were 120 kV, 150 to 300 mAs, and 3 mm, respectively. The procedure was as follows:

1. The patient laid on the board and then CT scans covering the area where the target nodule could be seen were performed.
2. The positioning grid was placed above the insertion region of interest.

3. The needle insertion pathway was designed according to the CT image, and the needle insertion point was indicated on the patient's skin by the use of a grid and a gantry laser light.
4. After sterilization of the puncture area and local anesthesia, a coaxial needle was inserted and advanced near the lesion within 10 mm under the guidance of the CT image.
5. A subsequent CT scan was taken to confirm the position of the needle, and adjustment might be needed if the position was not suitable.
6. The hookwire was ejected, and the needle was withdrawn gradually.
7. CT examination was performed to evaluate whether pneumothorax or pulmonary parenchyma hemorrhage ultimately occurred. After placement, the patients were sent to the operating room for VATS within an hour.

### Video-Assisted Thoracoscopic Surgery

The surgery was performed under double-lumen tracheal intubation and single-lung ventilation with general anesthesia. The patient was placed in the lateral position depending on the location of the nodule. Thoracoscopy was used to confirm the placement of the guidewire in the pleural cavity, and then wedge resection was performed with a stapler (60 mm, Echelon, Johnson) to remove the hookwire and the nodule. Intraoperative frozen section examination was performed for each patient. If the pathological result revealed primary lung invasive adenocarcinoma, lobectomy and dissection of the systemic lymph nodes were performed. For the remaining SMPNs that were not localized, wedge resection, segmentectomy, or lobectomy was conducted depending on both the surgeons' experience and the results of the intraoperative frozen specimen.

### Data Collection

Two radiologists with more than 10 years of experience reviewed all the preoperative CT images. The location and size of each localized nodule, the nearest distance to the visceral pleura, position during localization, the number of pleural punctures, the duration for localization procedure, and the localization-related complications were recorded. The size of the lesion was defined as the maximum diameter measured on the CT image. The nodules were divided into pGGNs, subsolid nodules, and solid nodules according to density. The type of resection, volume of intraoperative blood loss, and 24 h postoperative drainage, and postoperative hospitalization were obtained from the patients' electronic medical records. The pathological results of all surgically removed pulmonary nodules were noted. Benign tumors, inflammation, and granulomas were classified as benign lesions.

### Statistical Analysis

Statistical analysis was carried out using SPSS (version 18.0, SPSS Inc.). Quantitative variables were expressed as medians

(range), and categorical variables were expressed as counts and proportions. To compare the differences in clinical characteristics and imaging features between the single-nodule and multiple-nodule groups, the Chi-square test was used for categorical variables, and the Mann-Whitney test was used for continuous variables. Variables with  $P < .10$  in univariate analysis were selected for binary logistic regression analysis to determine the independent predictors of surgery-related complications. Odds ratios (ORs) and 95% confidence intervals (CIs) were calculated. The difference was considered statistically significant when the  $P$  value was  $< .05$ .

## Results

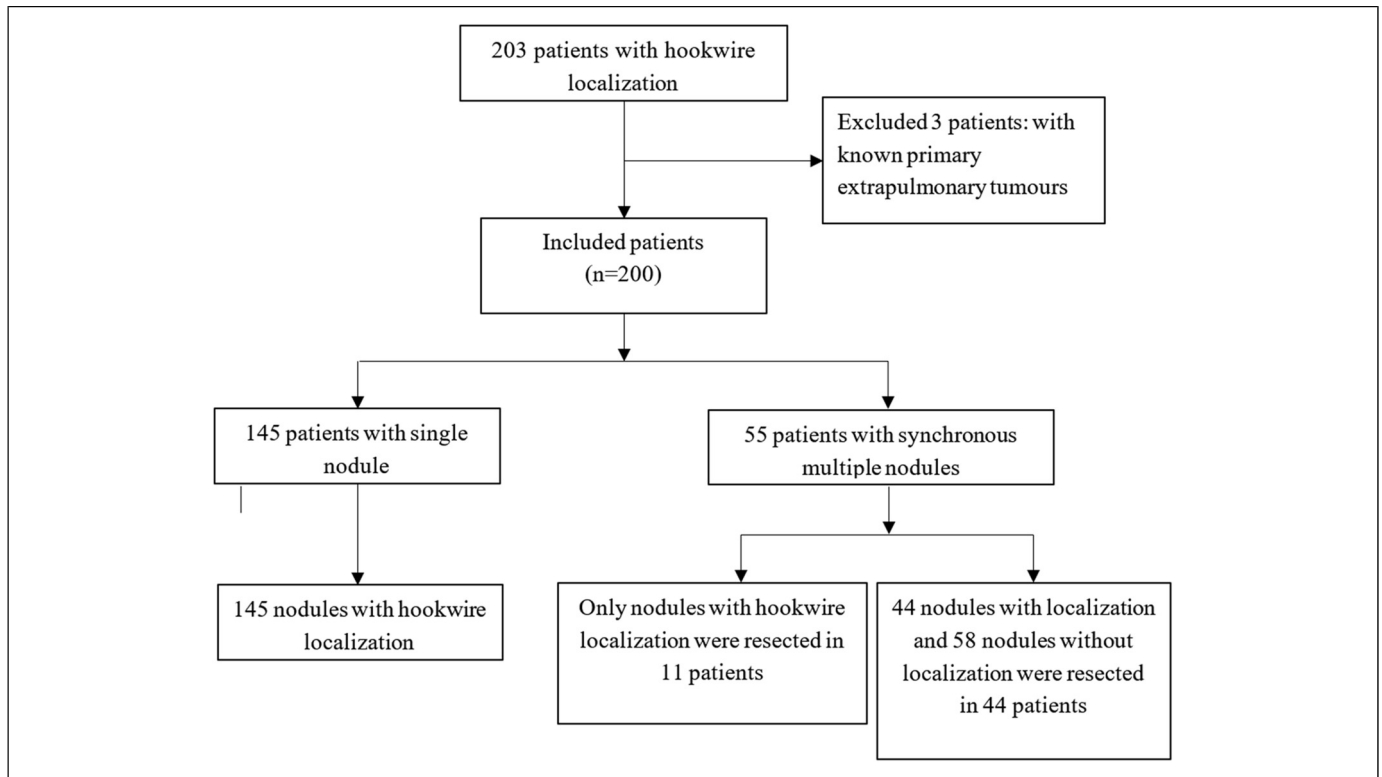
### Characteristics of the Patients and Nodules

The patient cohort is shown in Figure 1. All of 203 patients had undergone hookwire localization, 3 patients with primary extrapulmonary tumors were excluded, and a total of 200 patients were enrolled in this study. These 200 patients were divided into 2 groups based on the number of lung nodules preoperatively. There were 145 patients in the single-nodule group (group S) and 55 in the multiple-nodule group (group M). In group M, only 1 indeterminate nodule was localized in each patient.

The characteristics of the patients and nodules are shown in Table 1. There were no significant differences in the baseline data except the number of preoperative CT examinations in the 2 groups. In group M, 76.4% of the patients had undergone at least 2 preoperative CT examinations, which was significantly more than the number in group S. Of the 200 localized pulmonary nodules, 93 (46.5%) nodules were located in the left lung (Figure 2), while 107 (53.5%) were located in the right lung (Figure 3). About 127 (63.5%) nodules were  $< 10$  mm far from visceral pleura, 57 (28.5%) nodules were between 11 and 20 mm, while 16 (8.0%) nodules were between 21 and 35 mm, respectively. All of 200 nodules were successfully placed with a hookwire under the guidance of CT.

### Success Rate of Hookwire Localization

The technical success rate of hookwire implantation was 97.5% (195/200). There were 5 (2.5%) hookwire dislodgements before VATS surgery, with the distal tip of the hookwire in the pleural cavity (Figure 2b). The nearest distance from these 5 nodules to visceral pleura ranged from 0 to 8 mm, and pneumothorax occurred in 4 cases after hookwire localization. All of them were successfully resected eventually by the surgeons according to the focal bleeding spot on the visceral pleural surface and the nodule location on CT images. All margins of the specimens were negative. None of the patients had to undergo conversion to thoracotomy during the procedure.



**Figure 1.** The patients cohort of this study.

### Complications

Binary logistic regression analyses showed that 1 puncture through the pleura was the only independent protective factor for pneumothorax, with OR was 0.433 (95% CI: 0.210-0.938), and the  $P$  value was .033, respectively. Pneumothorax was the only independent risk factor for dislodgement, with OR was 26.114 (95% CI: 2.264-301.148),  $P$  value <.01, respectively. Pneumothorax occurred in 4 of 5 patients with hookwire dislodgement. No independent risk factors were found for pulmonary hematoma.

### Surgical Characteristics and Pathological Results

The surgical characteristics and pathological results are shown in Table 2. The volume of blood loss during VATS was significantly higher in group M than in group S, and the time of postoperative hospitalization was significantly longer in group M than in group S. Two patients were treated with blood transfusion after VATS. All 200 patients were discharged from the hospital without perioperative mortality. There were no significant differences in the type of resection, pathological results, or 24 h postoperative drainage volumes between the 2 groups.

### Single-Stage Surgery

In group M, 11 patients only underwent VATS excision of the localized nodule, and the other 44 patients underwent single-

stage VATS to remove all the target nodules simultaneously. Of the 44 patients, wedge resection combined with wedge resection was performed in 12 patients, wedge resection combined with segmentectomy (Figure 3) in 8 patients, wedge resection combined with lobectomy in 21 patients, segmentectomy combined with segmentectomy in 2 patients, and segmentectomy combined with lobectomy in 1 patient. Unilateral pulmonary nodule resection was performed in 31 patients (70.5%), and single-stage bilateral surgery was performed in 13 patients (29.5%) without bilateral lobectomy. Only 1 patient who underwent bilateral single-stage surgery via wedge resection and lobectomy experienced massive bleeding during VATS but was subsequently given blood transfusion treatment and was discharged in a stable condition 3 days later. Among the 44 patients who underwent VATS resection of all multiple nodules, 44 localized nodules and 58 nonlocalized nodules were found before surgery. There was no significant difference in the nodule location or pathological type between the localized and nonlocalized nodules, as shown in Table 3. Nonmalignant types included benign lesions and atypical adenomatous hyperplasia.

### Follow-up

Follow-up CT was performed in 84 patients with malignancy, with the median time interval was 7 (range 1-62) months. Recurrence occurred in 1 patient in group S and 3 in group M with minimally invasive adenocarcinoma (MIA) or invasive

**Table 1.** Characteristic of Patients and Nodules Requiring Localization.

Variables	All patients (n = 200)	Group S (n = 145)	Group M (n = 55)	P
Age, (year)	51.39 ± 11.61	50.49 ± 12.09	53.76 ± 9.92	.075
Gender				.166
Men	79(39.5)	53(36.6)	26(47.3)	
Women	121(60.5)	92(63.4)	29(52.7)	
Preoperative CT examinations >1	130(65.0)	88(60.7)	42(76.4)	.038
Preoperative observation time (month)	4(0-72)	3(0-72)	8(0-60)	.084
Nodule location				.148
Right upper lobe	79(39.5)	57(39.3)	22(40.0)	
Right middle lobe	5(2.5)	2(1.4)	3(5.5)	
Right lower lobe	23(11.5)	13(9.0)	10(18.2)	
Left upper lobe	64(32.0)	50(34.5)	14(25.5)	
Left lower lobe	29(14.5)	23(15.9)	6(10.9)	
Nodule size (mm)	8(3-19)	8(3-19)	7(3-16)	.062
Nearest distance to the visceral pleura (mm)	9(0-35)	9(0-32)	8(0-35)	.848
Nodule subtype				.454
pGGN	43(21.5)	30(20.7)	13(23.6)	
Subsolid	129(64.5)	97(66.9)	32(58.2)	
Solid	28(14.0)	18(12.4)	10(18.2)	
Position				.468
Supine position	156(78.0)	115(79.3)	41(74.5)	
Prone position	44(22.0)	30(20.7)	14(25.5)	
Number of pleural punctures				.116
1	132(66.0)	91(62.8)	41(74.5)	
≥2	68(34.0)	54(37.2)	14(25.5)	
Duration for localization procedure (min)	13(7-36)	13(7-36)	13(9-26)	.573
Localization-related complications				
Asymptomatic pneumothorax	34(17.0)	24(16.6)	10(18.2)	.784
Pulmonary hematoma	65(32.5)	48(33.1)	17(30.9)	.767
Dislodgement	5(2.5)	2(1.4)	3(5.5)	.254

Data are presented as median (range) or number (proportion).

Abbreviations: pGGN, pure ground glass nodule; CT, computed tomography; Group S, single-nodule group; Group M, multiple-nodule group.

adenocarcinoma. The time from surgery to recurrence was 4 to 33 months.

## Discussion

In this study, the overall technical success rate of hookwire localization before VATS was 97.5%. We found that 1 puncture through the visceral pleura was an independent protective factor for pneumothorax, while pneumothorax was an independent risk factor for dislodgement. There were significant differences in the volume of blood loss during the operation and the postoperative hospital stay between group M and group S. The approach utilizing a combination of hookwire localization and

VATS was feasible for single-stage resection of SMPNs with few serious complications. The postoperative recurrence rate was ~4.8%.

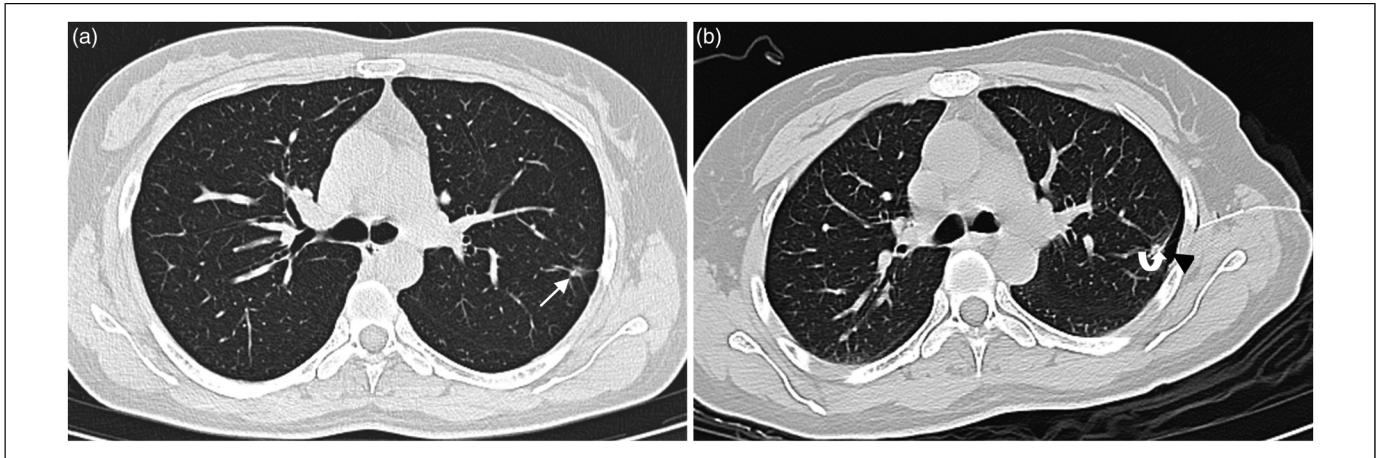
Several methods have been used to preoperative localization of pulmonary nodules, such as hookwire, microcoil, methylene blue, and so on. All of them yielded similarly and highly technical success rates, while microcoil localization had the lowest complication rate.<sup>8</sup> However, the microcoil was vulnerable to curl and retracted once ejected from out of the puncture needle, which might resulted in target failure.<sup>16</sup> The diffusion of methylene blue after injection leads to inaccurate localization and excessive resection.<sup>18</sup>

The success rate of hookwire localization in our study was consistent with that of previous studies.<sup>8</sup> Preoperative localization is mainly used for subcentimeter or ground-glass nodules that may be hard to palpate during VATS. The median size of the localized nodules in this study was 8 mm, and 86.0% were subsolid nodules. Preoperative localization of these nodules is helpful for the accurate and rapid localization of the target lesion.

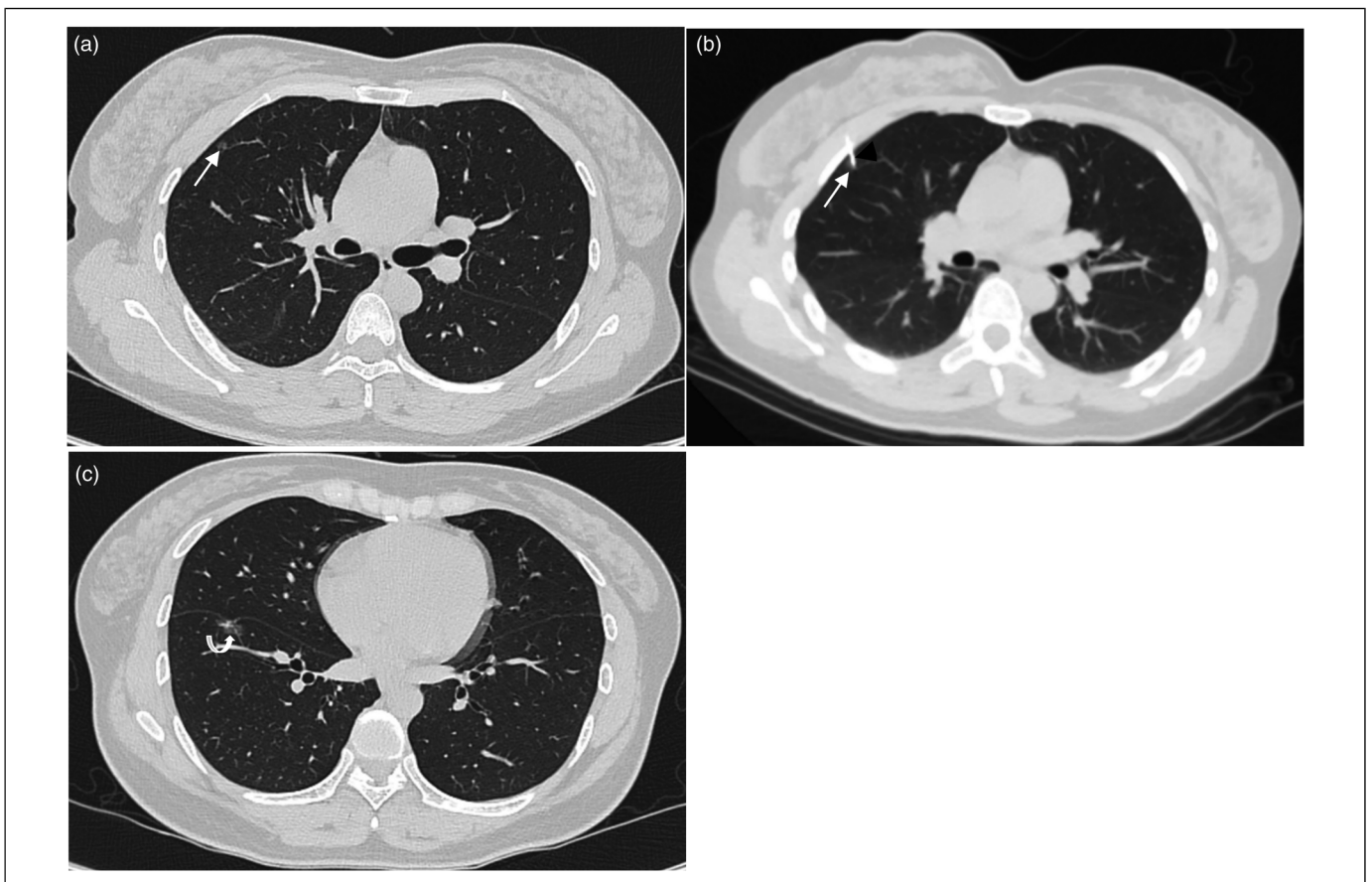
This study showed that the incidence of pneumothorax was 17.0%, which is higher than the 7.8% reported by Fan et al<sup>19</sup> but lower than the 22.0% reported by Kadeer et al.<sup>14</sup> We found that puncturing the visceral pleura once was a protective factor for pneumothorax. Similarly, Yao et al<sup>20</sup> assumed that a single pleural puncture was associated with a decreased pneumothorax rate, and Iguchi et al<sup>21</sup> showed that the transfissural pathway and a long localization time were independent predictors of pneumothorax. Despite the high incidence of localization-related pneumothorax, only up to 4.6% of patients need treatment for chest tube drainage.<sup>10</sup>

The mean pulmonary hemorrhage rate associated with hookwire localization in this study was 32.5%, which was comparable with the 27%<sup>22</sup> but higher than the 16%<sup>8</sup> reported previously. Because the patients were mostly asymptomatic and were sent to the operating room for subsequent VATS within 1 h after the completion of hookwire localization, no chest tube drainage was required before VATS.

According to a meta-analysis of 46 clinical studies, the successful targeting rates for hookwire, microcoil, and lipiodol localization were similarly high.<sup>8</sup> In the present study, 2.5% of cases of hookwire dislodgement occurred, which was comparable with previous studies (0.4%-2.4%).<sup>23-27</sup> However, Xu et al<sup>28</sup> reported that the rate of pleural marking failure was up to 10.0% (28/279) in microcoil localization due to small needle-pleura angle, pleura-microcoil distance, and the presence of pleural indentation. Another study yielded a 2.4% (8/331) technical failure rate in microcoil localization, which was similar to the incidence of hookwire dislodgement in this study.<sup>15</sup> In cases of dislodgement, surgeons can determine the area of resection according to the puncture bleeding point of the visceral pleura and the distance from the lesion to the surface of the pleura shown on CT images to achieve the goal of complete excision of the target nodule. Rare complications, such as air embolism and migration of a hookwire into the splenic artery, have been reported,<sup>25,26,29,30</sup> but similar serious complications were not observed in this study.



**Figure 2.** A 48-year-old female with a solitary 5 mm nodule in the left upper lobe was performed thoracoscopic wedge resection, and the pathological diagnosis is focal hyaline degeneration with peripheral fibrosis. (a) Computed tomography (CT) shows the lesion (arrow) in the left upper lobe. (b) CT shows tiny pneumothorax (arrowhead) after hookwire localization surgery, and (c) the positioning hookwire (curved arrow) was too shallow.



**Figure 3.** A 37-year-old female with 2 nodules in the right lung. The patient underwent a right upper wedge resection and a right lower segmentectomy synchronously, and the pathological diagnosis was adenocarcinoma in situ and invasive adenocarcinoma, respectively. (a) Computed tomography (CT) shows a 5 mm subsolid nodule (straight arrow) in the right upper lobe. (b) puncture needle (arrowhead) was inserted into the lung and placed near the lesion in the right upper lobe. (c) CT shows the other 13 mm subsolid nodule (curved arrow) in the right lower lobe.

**Table 2.** Surgical Characteristics and Pathological Results of Localized Nodules.

Variables	All patients (n = 200)	Group S (n = 145)	Group M (n = 55)	P
Type of resection				.282
Wedge resection	152(76.0)	106(73.1)	46(83.6)	
Segmentectomy	24(12.0)	19(13.1)	5(9.1)	
Lobectomy	24(12.0)	20(13.8)	4(7.3)	
Pathological results				.254
Benign lesions	22(11.0)	17(11.7)	5(9.1)	
AAH	24(12.0)	15(10.3)	9(16.4)	
AIS	82(41.0)	65(44.8)	17(30.9)	
MIA or IAC	66(33.0)	45(31.0)	21(38.2)	
Metastases	6(3.0)	3(2.1)	3(5.5)	
Intraoperative blood loss (mL)	20(5-600)	20(5-500)	50(5-600)	.014
24 h postoperative drainage (mL)	100(0-1000)	90(0-1000)	110(10-420)	.119
Postoperative hospitalization time (day)	4(1-11)	3(1-11)	4(2-11)	.008

Data are presented as median (range) or number (proportion).

AAH, atypical adenomatous hyperplasia; AIS, adenocarcinoma in situ; MIA, minimally invasive adenocarcinoma; IAC, invasive adenocarcinoma.

Previous study had reported that simultaneous hookwire localization of each nodule in multiple nodules might increase the complication rate and prolong the duration of the procedure compared to single-nodule positioning.<sup>10</sup> The risk of pneumothorax in patients who experienced multiple localizations is higher.<sup>26</sup> The reason might be that multiple localizations simultaneously doubled the damage to the pleura and pulmonary parenchyma, and the duration of the localization procedure was also significantly extended which ultimately may have increased adverse events.<sup>10</sup> In addition, if pneumothorax occurs after the first localization of multiple nodules, the second ipsilateral pulmonary nodule position can become more difficult for the positioning needle is too soft to penetrate the lung parenchyma.<sup>14</sup>

Therefore, regarding the multiple nodules in this study, only 1 nodule of indeterminate nature, which might be difficult to palpate during surgery in group M, was selected for preoperative hookwire localization. The remaining nodules with obvious malignant signs on CT were directly removed by lobectomy or segmentectomy during a single-stage surgery. The overall hookwire localization time in our study was 13 min, which was shorter than the 14 to 28 min reported by other studies.<sup>26,27,31</sup> Compared with patients in group S,

patients in group M underwent more preoperative CT examinations, indicating that multiple nodules need to be observed more closely for observing changes. The differences of the volume of blood loss during VATS and the postoperative hospital stay between the 2 groups were statistically significant, while the hookwire localization related complications were not statistically significant. These results indicate that it is safe to perform single hookwire localization in SMPNs without increasing localization-related complications. Second, the increased volume of intraoperative blood loss might be associated with the direct removal of the remaining nodules in most patients in group M. The length of hospitalization was only extended by 1 day, which was acceptable for patients in group M because almost all the suspicious nodules were removed during single-stage surgery. The length of hospital stay would have been longer and would have cost more if a two-stage approach had been performed.

Currently, there is no optimal treatment for bilateral multiple pulmonary nodules.<sup>32-34</sup> Single-stage surgery for bilateral lung nodules can be risky.<sup>11</sup> Whether patients with SMPNs should undergo single-stage or two-stage surgeries remains controversial. Iguchi et al<sup>10</sup> pointed that simultaneous positioning of bilateral lung nodules may cause fatal pneumothorax. In contrast, Yao et al<sup>11</sup> and Teng et al<sup>13</sup> reported 29 cases and 8 cases of bilateral single-stage VATS surgery, respectively. Their findings revealed that single-stage VATS could reduce the time of hospitalization compared with a two-stage approach, and a combination of single-stage coil implantation and the VATS method can be safe and effective in patents with bilateral SMPNs. But single-stage bilateral lobectomy is not recommended because of the possibility of fatal complication requiring artificial ventilation.<sup>11</sup> In this study, 13 patients had undergone single-stage bilateral surgery, 1 of whom had massive blood loss and was discharged after treatment. None of bilateral lobectomy was seen in the 13 patients, which might indicate that single-stage bilateral surgery without bilateral lobectomy was safe in patients with bilateral SMPNs.

**Table 3.** Characteristics of 44 Patients Undergoing Single-Stage Additional Nodule Resection.

Variables	Localized nodule (n = 44)	Unlocalized nodule (n = 58)	P
Location			.356
Right lung	29(65.9)	33(56.9)	
Left lung	15(34.1)	25(43.1)	
Pathological type			.572
Nonmalignant	12(27.3)	13(22.4)	
Malignant	32(72.7)	45(77.6)	

Data are presented as number (proportion).



Previous research has shown that lung wedge resection is effective for diagnosis and treatment in patients with MIA,<sup>35</sup> and sublobar resection is equal to lobectomy for early stage (1a) lung cancer in terms of solid nodules.<sup>36</sup> In our study, 41 of the 44 patients who underwent a single-stage surgery to resect multiple nodules underwent wedge resection combined with other types of resection, which can maximize the retention of normal lung tissue in patients.

Our study observed an intrathoracic recurrence rate of 4.8% (4/84) during follow-up, which was consistent with the 0% to 22% reported in the literature.<sup>11,13,37</sup> Tumor recurrence may be related to various factors. Rodrigues et al<sup>37</sup> found that a distance from the pleura to the nodule of >10 mm was an independent predictor of tumor recurrence. Compared with lobectomy, sublobar resection may result in a positive surgical margin and a higher recurrence.<sup>38,39</sup>

The limitations of this study include the retrospective and single-center design. No patients with SMPNs had undergone simultaneous multiple hookwire localization in our center, so a comparison of multicenter studies may need to be conducted as a next step. Furthermore, nodules >40 mm from the pleura were excluded, which may have resulted in the underestimation of complications such as pneumothorax and pulmonary hemorrhage. In addition, long-term follow-up is still needed.

In conclusion, single-stage surgery via an approach of single hookwire localization combined with VATS is feasible and safe for SMPNs.

## Main Points

- The technical success rate of hookwire implantation was extremely high.
- One transpleural puncture was a significant independent protective factor for pneumothorax associated with preoperative hookwire localization, while pneumothorax was a significant independent risk factor for dislodgement.
- The approach of single hookwire localization combined with VATS is feasible and safe for SMPNs.

## Declaration of Conflicting Interests

The authors declared no potential conflicts of interest with respect to the research, authorship, and/or publication of this article.

## Funding


The authors disclosed receipt of the following financial support for the research, authorship, and/or publication of this article: This work was supported by the Natural Science Foundation of Shanghai (Grant Number 20ZR1456300).

## Authors' Note

Institutional Review Board approval was obtained. The current retrospective study was approved by the Ethics Committee of Changhai Hospital affiliated to Naval Medical University (Second Military

Medical University) and written informed consent was waived. We confirm that all methods were performed in accordance with the relevant guidelines and regulations.

## ORCID iD

Bingding Huang  <https://orcid.org/0000-0002-4748-2882>

## References

1. Swensen SJ, Jett JR, Hartman TE, et al. CT Screening for lung cancer: five-year prospective experience. *Radiology*. 2005;235(1):259-265.
2. Kakinuma R, Muramatsu Y, Kusumoto M, et al. Solitary pure ground-glass nodules 5 mm or smaller: frequency of growth. *Radiology*. 2015;276(3):873-882.
3. Gazdar AF, Minna JD. Multifocal lung cancers--clonality versus field cancerization and does it matter. *J Natl Cancer Inst*. 2009;101(8):541-543.
4. Zhang Y, Li G, Li Y, et al. Imaging features suggestive of multiple primary lung adenocarcinomas. *Ann Surg Oncol*. 2020;27(6):2061-2070.
5. MacMahon H, Naidich DP, Goo JM, et al. Guidelines for management of incidental pulmonary nodules detected on CT images: from the Fleischner Society 2017. *Radiology*. 2017;284(1):228-243.
6. Rivera MP, Mehta AC, Wahidi MM. Establishing the diagnosis of lung cancer: diagnosis and management of lung cancer, 3rd ed: American College of Chest Physicians evidence-based clinical practice guidelines. *Chest*. 2013;143(5 Suppl):e142S-e165S.
7. Yang ZJ, Liang YH, Li M, Fang P. Preoperative computed tomography-guided coil localization of lung nodules. *Minim Invasive Ther Allied Technol*. 2020;29(1):28-34.
8. Park CH, Han K, Hur J, et al. Comparative effectiveness and safety of preoperative lung localization for pulmonary nodules: a systematic review and meta-analysis. *Chest*. 2017;151(2):316-328.
9. Plunkett MB, Peterson MS, Landreneau RJ, Ferson PF, Posner MC. Peripheral pulmonary nodules: preoperative percutaneous needle localization with CT guidance. *Radiology*. 1992;185(9):274-276.
10. Iguchi T, Hiraki T, Gobara H, et al. Simultaneous multiple preoperative localizations of small pulmonary lesions using a short hook wire and suture system. *Cardiovasc Intervent Radiol*. 2015;38(4):971-976.
11. Yao F, Yang H, Zhao H. Single-stage bilateral pulmonary resections by video-assisted thoracic surgery for multiple small nodules. *J Thorac Dis*. 2016;8(3):469-475.
12. Fu YF, Gao YG, Zhang M, Wang T, Shi YB, Huang YY. Computed tomography-guided simultaneous coil localization as a bridge to one-stage surgery for multiple lung nodules: a retrospective study. *J Cardiothorac Surg*. 2019;14(1):43.
13. Teng F, Wu AL, Yang S, Lin J, Xian YT, Fu YF. Preoperative computed tomography-guided coil localization for multiple lung nodules. *Ther Adv Respir Dis*. 2020;14:1753466620909762.
14. Kadeer X, Wang L, Zhang L, Shi W, Chen C. Modified hook-wire placement technique for localizing multiple pulmonary nodules. *J Surg Oncol*. 2018;118(7):1188-1193.



15. Hu L, Gao J, Hong N, et al. Simultaneous preoperative computed tomography-guided microcoil localizations of multiple pulmonary nodules. *Eur Radiol.* 2021;31(9):6539–6546.
16. Xu Y, Ma L, Sun H, et al. The utility of simultaneous ct-guided localization for multiple pulmonary nodules using microcoil before video-assisted thoracic surgery. *BMC Pulm Med.* 2021; 21(1):39.
17. Huang ZG, Wang CL, Sun HL, et al. Ct-guided microcoil localization of small peripheral pulmonary nodules to direct video-assisted thoracoscopic resection without the aid of intraoperative fluoroscopy. *Korean J Radiol.* 2021;22(7):1124-1131.
18. Kleedehn M, Kim DH, Lee FT, et al. Preoperative pulmonary nodule localization: a comparison of methylene blue and hookwire techniques. *AJR Am J Roentgenol.* 2016;207(6):1334-1339.
19. Fan L, Yang H, Yu L, et al. Multicenter, prospective, observational study of a novel technique for preoperative pulmonary nodule localization. *J Thorac Cardiovasc Surg.* 2020;160(2):532-539. e2.
20. Yao F, Wang J, Yao J, Xu L, Wang J, Gao L. Reevaluation of the efficacy of preoperative computed tomography-guided hook wire localization: a retrospective analysis. *Int J Surg.* 2018; 51(3):24-30.
21. Iguchi T, Hiraki T, Gobara H, et al. CT fluoroscopy-guided preoperative short hook wire placement for small pulmonary lesions: evaluation of safety and identification of risk factors for pneumothorax. *Eur Radiol.* 2016;26(1):114-121.
22. Khan MF, Straub R, Moghaddam SR, et al. Variables affecting the risk of pneumothorax and intrapulmonary hemorrhage in CT-guided transthoracic biopsy. *Eur Radiol.* 2008;18(7): 1356-1363.
23. Iguchi T, Hiraki T, Matsui Y, et al. Preoperative short hookwire placement for small pulmonary lesions: evaluation of technical success and risk factors for initial placement failure. *Eur Radiol.* 2018;28(5):2194-2202.
24. Miyoshi K, Toyooka S, Gobara H, et al. Clinical outcomes of short hook wire and suture marking system in thoracoscopic resection for pulmonary nodules. *Eur J Cardiothorac Surg.* 2009;36(2):378-382.
25. Suzuki K, Shimohira M, Hashizume T, et al. Usefulness of CT-guided hookwire marking before video-assisted thoracoscopic surgery for small pulmonary lesions. *J Med Imaging Radiat Oncol.* 2014;58(6):657-662.
26. Ichinose J, Kohno T, Fujimori S, Harano T, Suzuki S. Efficacy and complications of computed tomography-guided hook wire localization. *Ann Thorac Surg.* 2013;96(4):1203-1208.
27. Dendo S, Kanazawa S, Ando A, et al. Preoperative localization of small pulmonary lesions with a short hook wire and suture system: experience with 168 procedures. *Radiology.* 2002;225(2):511-518.
28. Xu Y, Ma L, Sun H, et al. CT-guided microcoil localization for pulmonary nodules before VATS: a retrospective evaluation of risk factors for pleural marking failure. *Eur Radiol.* 2020; 30(10):5674-5683.
29. Wang MY, Liu YS, An XB, Li K, Liu YJ, Wang F. Cerebral arterial air embolism after computed tomography-guided hook-wire localization of a pulmonary nodule: a case report. *Medicine (Baltimore).* 2019;98(18):e15437.
30. Torigoe H, Hirano Y, Ando Y, Washio K. Migration of a hookwire used as a video-assisted thoracoscopic surgery marker into the splenic artery. *Gen Thorac Cardiovasc Surg.* 2020;68(2):194-198.
31. Huang W, Ye H, Wu Y, et al. Hook wire localization of pulmonary pure ground-glass opacities for video-assisted thoracoscopic surgery. *Thorac Cardiovasc Surg.* 2014;62(2):174-178.
32. Baisi A, De Simone M, Cioffi U, Raveglia F. Should pulmonary lobectomy be replaced by sublobar resection in patients with stage I non-small cell lung cancer. *J Thorac Cardiovasc Surg.* 2014;147(6):1997-1998.
33. Toufektzian L, Attia R, Veres L. Does the extent of resection affect survival in patients with synchronous multiple primary lung cancers undergoing curative surgery. *Interact Cardiovasc Thorac Surg.* 2014;19(6):1059-1064.
34. Zuin A, Andriolo LG, Marulli G, et al. Is lobectomy really more effective than sublobar resection in the surgical treatment of second primary lung cancer. *Eur J Cardiothorac Surg.* 2013;44(2):e120-e125. discussion e125.
35. Fu YF, Zhang M, Wu WB, Wang T. Coil localization-guided video-assisted thoracoscopic surgery for lung nodules. *J Laparoendosc Adv Surg Tech A.* 2018;28(3):292-297.
36. Altorki NK, Yip R, Hanaoka T, et al. Sublobar resection is equivalent to lobectomy for clinical stage 1A lung cancer in solid nodules. *J Thorac Cardiovasc Surg.* 2014;147(2):754-762. Discussion 762–764.
37. Rodrigues J, Pierre AF, Hanneman K, et al. CT-guided microcoil pulmonary nodule localization prior to video-assisted thoracoscopic surgery: diagnostic utility and recurrence-free survival. *Radiology.* 2019;291(1):214-222.
38. Khullar OV, Liu Y, Gillespie T, et al. Survival after sublobar resection versus lobectomy for clinical stage IA lung cancer: an analysis from the national cancer data base. *J Thorac Oncol.* 2015;10(11):1625-1633.
39. Subramanian M, McMurry T, Meyers BF, Puri V, Kozower BD. Long-Term results for clinical stage IA lung cancer: comparing lobectomy and sublobar resection. *Ann Thorac Surg.* 2018;106(2):375-381.