

Knotting of a Cervical Epidural Catheter in the Patient with Post-Herpetic Neuralgia: A Rare Complication

Jong Taek Park, Dong Woo Cho, Young Bok Lee*

Department of Anesthesiology and Pain Medicine, Yonsei University Wonju College of Medicine, Wonju, Korea

Epidural block is achieved either by single injection of local anesthetic through an epidural needle or as a continuous block by infusion pump through an epidural catheter. Complications associated with epidural catheters include breakage, entrapment, and knotting. Knotting of epidural catheters is very rare, but knotting in lumbar epidural catheters has been reported in a number of studies, and most of these cases involved removal difficulty. We report a case in which we inserted a cervical epidural catheter in a patient who was experiencing severe post-herpetic neuralgia and then removed the knotted catheter without complications.

Key Words: Cervical, Complication, Epidural catheter, Knotting, Removal

INTRODUCTION

Post-herpetic neuralgia is a serious complication of herpes zoster that causes critical pain to patients even after skin lesions have healed. Epidural blocks are employed to control pain that does not subside after medical treatment. Epidural blocks are achieved either by single injection of local anesthetic through the epidural needle or as continuous block by infusion pump through an epidural catheter [1,2]. The epidural catheter can be inserted not only in thoracic and lumbar vertebra, but also in cervical vertebra. Complications of epidural catheter insertion include breakage, entrapment, and knotting. Knotting of epidural catheters is very rare,

but knotting in lumbar epidural catheters has been reported in a number of studies, and most of these cases involved removal difficulty [3]. We report a case in which we inserted a cervical epidural catheter in a patient who was experiencing severe post-herpetic neuralgia and then removed the knotted catheter without complications.

CASE REPORT

A female patient, 73 years old, was diagnosed with herpes zoster and received medical treatment at another medical clinic. However, when her serious pain did not subside after treatment, she visited our pain clinic. Her pain was severe, 10/10 on the numeric rating scale (NRS) at the first visit. She appeared to have herpes zoster involving the fifth cervical spinal nerve root on the right and was diagnosed with post-herpetic neuralgia. We explained our plan to perform a cervical epidural block along with medical treatment and received informed consent. A cervical epidural block was performed with the patient in the sitting position. The patient was instructed to flex her neck so that her interlaminar space was easily distinguished. Skin over the C6-7 inter-

Received: September 6, 2016, Accepted: October 21, 2016

*Corresponding author: Young Bok Lee

Department of Anesthesiology and Pain Medicine, Yonsei University Wonju College of Medicine, 20 Ilsan-ro, Wonju 26426, Republic of Korea
Tel: 82-33-741-1536, Fax: 82-33-742-8198
E-mail: yblee@yonsei.ac.kr

© This is an Open Access article distributed under the terms of the Creative Commons Attribution Non-Commercial License (<http://creativecommons.org/licenses/by-nc/4.0>) which permits unrestricted noncommercial use, distribution, and reproduction in any medium, provided the original work is properly cited.

laminar space was sterilized with betadine solution and topically anesthetized with 2 ml of 2% lidocaine. Using the mid-line approach, we checked the epidural space through a 20-gauge Tuohy needle using the loss of resistance method; after assuring that there was no cerebrospinal fluid or blood aspirated, 5 ml of 1% mepivacaine and 2 mg of dexamethasone were injected. Immediately after the injection, the patient reported that her pain temporarily decreased; but after about 40 minutes, she said the pain was again as severe as it used to be. We explained the use of an epidural block with epidural catheter insertion and received agreement from the patient to proceed. The epidural space was checked using an 18-gauge Tuohy needle at C6-7 using the same technique as for the cervical epidural block. The depth of the epidural space from the skin was 5.2 cm. A 20-gauge epidural catheter (Smiths Medical ASD, Inc. Keene, USA) was advanced by 7 cm cephalad through the epidural needle; after the needle was removed, the catheter was pulled out by 2 cm and inserted 5 cm from the epidural space. The patient did not experience any discomfort except mild paresthesia of the right arm. After insertion of the epidural catheter and confirming that no blood or cerebrospinal fluid had been pulled in, 3 ml of 1% mepivacaine was injected. The patient reported that her pain was subsiding, so she was given 2 ml of 0.18% ropivacaine per hour through an infusion pump. We prescribed pregabalin 225 mg, tramadol 150 mg, and amitriptyline 10 mg per day, and the patient was discharged. She visited our clinic every day for the next four days and received additional injections of 5 ml of 1% mepivacaine through the epidural catheter, maintained by infusion pump. After this, she reported that the pain was decreased to 5-6 on NRS, and that she could finally sleep at night. On the fifth day, she reported her pain to be 3-4/10 on NRS, and that she wanted to remove the epidural catheter, while remaining on her prescribed medication. We attempted to remove the catheter from the patient in a seated posture; however, after it was pulled out about 3 cm, there was resistance, and it stopped moving. When asked if there was any pain or discomfort of the neck, the patient answered that there was not. After asking the patient to repeat bending and then straightening her neck a few times and pulling the catheter out with slightly stronger force, the catheter suddenly snapped out. The patient reported no pain

in the neck or arm, so our medical team sterilized the area where the catheter had been installed and applied a dressing. When the removed catheter was thoroughly examined, a knot was discovered 1.5 cm from the tip (Fig. 1).

DISCUSSION

Side effects or complications of epidural catheter placement include unsuccessful catheter placement, intrathecal or intravascular placement, catheter damage, knotting, and difficult removal. Knotting is a very rare complication in epidural catheters, and the actual incidence is difficult to determine because most of the documentation is provided in the form of case reports. However, McGregor reported the incidence to be 0.00015% [4]. Some reports described single cases in samples of over 20,000-30,000 [5-7]. Most of the reported cases were related to obstetric epidural analgesia and/or anesthesia [8]. Therefore, cases of knotting have been reported primarily in lumbar epidural catheters, with only one case involving a thoracic epidural catheter [9]. In 12 cases, the knots arose less than 3 cm from the catheter tip, near the distal end. In one case, a double knot was found 1.5 cm to 3 cm from the tip of the catheter, while another case involved a butterfly-like knot 5 cm below the catheter tip [10,11]. In our case, the knot was located 1.5 cm below from the catheter tip after cervical epidural catheter placement, a condition that has never been reported previously.

The insertion of epidural catheters is performed through

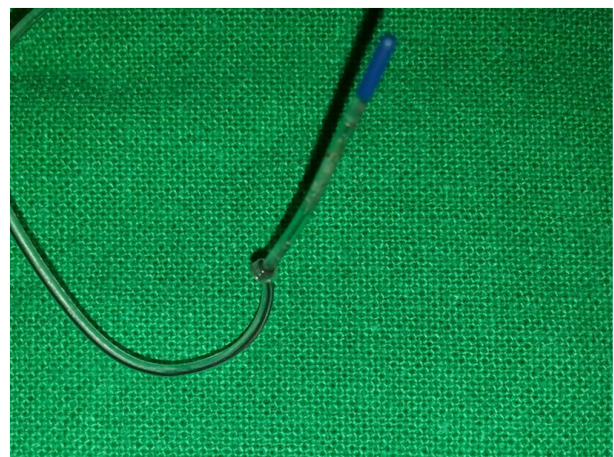


Fig. 1. Knot in the catheter 1.5 cm from the tip.

Tuohy needles, with the clinician threading the epidural catheter into the epidural space and subsequently withdrawing the catheter through the desired level in the epidural space. The longer is the distance the catheter is inserted from the epidural space, the greater is the chance of knotting. Therefore, several authors have recommended that the length of the catheter passed beyond the tip of the needle should be limited to reduce this risk. The optimal length of insertion, however, remains controversial. It has been recommended that the length of catheter insertion not exceed 5 cm, and less than 3-4 cm is considered optimal to prevent knotting [8,10]. However, knots in epidural catheters have been reported even when no more than 3 cm had passed in the epidural space. In our case, a knot formed 1.5 cm from the catheter tip.

When removing an epidural catheter, steady and gentle firm traction must be applied in the same direction as when the catheter was inserted. If the catheter begins to stretch too much or the patient complains of pain or paresthesia during withdrawal, the traction should be stopped at once. In most cases, gentle traction applying mild force is sufficient to successfully remove the catheter. Difficult removal of epidural catheters occasionally occurs, and several maneuvers have been recommended in response: (1) slow, continuous, and steady pressure on the catheter to avoid catheter breakage; (2) reapplication of force and traction several hours later; (3) having the patient adopt the same position as when the catheter was inserted; (4) having the patient adopt the lateral decubitus position (as greater force is required to remove epidural catheters in the flexed sitting position than in the lateral position); and (5) attempting removal after injection of normal saline through the catheter, which may also assist in determining whether the catheter is knotted. If necessary, radiological images can be checked while injecting radiopaque dye through the catheter, and computer tomography can also help to clarify the image [12]. Such imaging helps to visualize the structure of the knot and its position. Gadalla reported that catheters were more successfully removed with patients under general anesthesia with muscle relaxation [13]. Surgical removal is the last choice after all other attempts have failed. Surgical removal can be also applied when a patient shows neurologic signs during traction or pieces of broken catheter are de-

tected [14,15].

After removing an epidural catheter, the catheter tip should be thoroughly checked to determine whether there is breakage. If a catheter fragment is retained in the body, it remains debatable whether the fragment should be removed surgically. Some experts recommend that, as catheters are sterile and unlikely to cause neurologic damage, fragments should be left *in situ*, especially if no neurologic sequelae are noted. Surgical removal may increase the risk of neurologic damage due to infection, fibrosis, or mechanical neural irritation. However, some reports have demonstrated adverse effects after leaving the sheared catheter *in situ* such as radiculopathy, weakness, granuloma formation, and fibrosis as a result of long-term retention of epidural catheters.

In the present report, we describe the successful removal of a knotted epidural catheter. Our patient did not complain of discomfort during removal of the catheter, but mild resistance was experienced when our medical team attempted to pull out the catheter. The patient was placed into the same seated posture as she had assumed when the catheter was inserted and bent her neck down and up a few times, and the catheter was then successfully removed without any complications. A knot was found 1.5 cm from the tip of the catheter, which itself was 5 cm long. It is normally recommended that the length of epidural catheters be less than 5 cm, while catheters less than 3-4 cm in length are considered ideal to prevent possible knotting.

REFERENCES

1. Sim WS, Choi JH, Han KR, Kim YC. Treatment of herpes zoster and post-herpetic neuralgia. *Korean J Pain* 2008;21:93-105.
2. Galluzzi KE. Management strategies for herpes zoster and postherpetic neuralgia. *J Am Osteopath Assoc* 2007;107:8-13.
3. Chen JL, Cherng CH, Chan SM, Lin CS, Wong CS, Juan CJ, Yeh CC. Difficult removal of an epidural catheter in the anterior epidural space. *Acta Anaesthesiol Taiwan* 2010;48:49-52.
4. McGregor PJ. In reply. *Anesthesiology* 1990;73:1293.
5. Bromage PR. Epidural analgesia. WB Saunders; Philadelphia. 1978.
6. Folk JW, Joye TP, Duc TA Jr, Bailey MK. Epidural catheters: the long and winding road. *South Med J*

- 2000;93:732-3.
7. Macfarlane J, Paech MJ. Another knotted epidural catheter. *Anaesth Intensive Care* 2002;30:240-3.
 8. Brichant JF, Bonhomme V, Hans P. On knots in epidural catheters: a case report and a review of the literature. *Intl J Obstet Anesth* 2006;15:159-62.
 9. Hsin ST, Chang FC, Tsou MY, Liao WW, Lee TY, Lui PW, Luk HN. Inadvertent knotting of a thoracic epidural catheter. *Acta Anaesthesiol Scand* 2001;45:255-7.
 10. Arnaoutoglou HM, Tzimas PG, Papadopoulos GS. Knotting of an epidural catheter: a rare complication. *Acta Anaesth Belg* 2007;58:55-7.
 11. Chang PY, Hu J, Lin YT, Chan KH, Tsou MY. Butterfly-like knotting of a lumbar epidural catheter. *Acta Anaesthesiol Taiwan* 2010;48:45-8.
 12. Aslanidis T, Fileli A, Pyrgos P. Management and visualization of a kinked epidural catheter. *Hippokratia* 2010;14:294-6.
 13. Gadalla F. Removal of a tenacious epidural catheter. *Anesth Analg* 1992;75:1071-2.
 14. Gozal D, Gozal Y, Beilin B. Removal of knotted epidural catheters. Case reports. *Reg Anesth* 1996;21:71-3.
 15. Al-Kayed O, Al-Bouti F, Ababneh MO. Surgical removal of a loop and knotted epidural catheter in a postpartum patient. *Middle East J Anaesthesiol* 2008;19:913-8.