



# Twist Technique to Stop Fluid Leakage and Fixate the Eye During Bimanual Cortex Removal in Phacoemulsification

Hassan Khaled <sup>1,\*</sup>, Bilal Haj Najeeb <sup>2,\*</sup>

<sup>1</sup>Magrabi Eye & Ear Hospital, Makkah, Saudi Arabia; <sup>2</sup>Department of Ophthalmology, Medical University of Vienna, Vienna, Austria

\*These authors contributed equally to this work

Correspondence: Hassan Khaled, Magrabi Eye & Ear Hospital, The Holy Mosque Street, Al Murasalat, Makkah, 24247, Saudi Arabia, Email hassan.adel@magrabi.com.sa

**Abstract:** Leakage of fluid through the side port during aspiration of the cortex leads to instability of the anterior chamber. In addition, eye movement may cause an unintended pulling of the irrigation probe out of the corneal wound resulting in collapsing of the anterior chamber. Both situations could pose a challenge to the surgeon and increase the risk of serious intraoperative complications. Therefore, we describe a simple effective maneuver to avoid these conditions during bimanual cortex removal and viscoelastic washout. In Khaled technique, rotating the irrigation probe outwards causes complete occlusion of the lumen of the side port and a simultaneous stabilization of the anterior chamber. Twisting the incision by the irrigation probe also offers better fixation of the eye at the edge of the side port and a subsequent reduction of eye movement.

**Keywords:** irrigation probe, irrigation/aspiration, cataract surgery, cortex removal, phacoemulsification

## Introduction

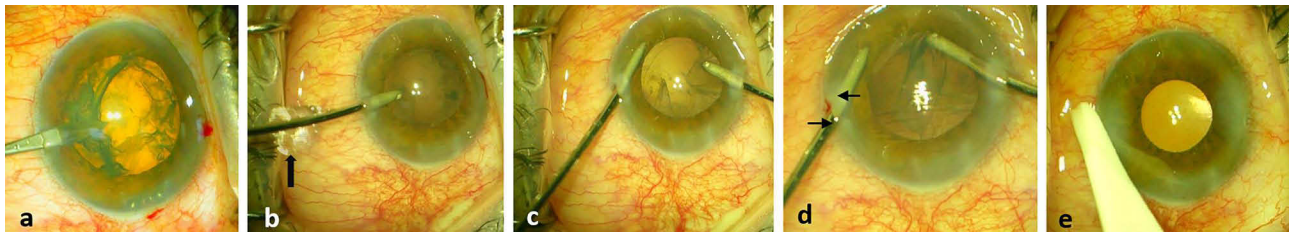
Successful aspiration of the cortex during phacoemulsification surgery is crucial to ensure a precise position of the intraocular lens and a reduction of the postoperative inflammation.<sup>1</sup> To achieve a safe cortex aspiration, a stable anterior chamber (AC) is mandatory.<sup>2</sup> One common reason for fluctuation of the depth of the AC and the fluttering of the posterior capsule is the outflow of fluid through the side port. This unavoidable leakage may occur even when the size of the side port is equal to that of the irrigation probe. Subsequently, an unstable AC promotes serious intraoperative complications during cortex removal such as zonular dialysis, posterior capsule rupture and vitreous loss.

In addition, eye movement could cause an inadvertent pulling of the irrigation probe out of the corneal incision during the irrigation aspiration (I/A) of the residual cortex resulting in collapsing of the AC and unfavorable complications.<sup>3</sup> Unfortunately, to date there has been no simple maneuver to overcome these two intraoperative problems. Therefore, we describe how to manage these situations using one novel easy technique.

This study was conducted in accordance with the tenets of the Declaration of Helsinki. No ethical approval was needed as we report on one case study. An informed consent was obtained from the study participant.

## Surgical Technique

Once the surgeon observes leakage through the side port after introducing the 20- gauge irrigation probe, rotating the irrigation probe outwards about 50 degrees from its radial position can stop the leakage (Figure 1a-c), (Video 1). This twist maneuver causes occlusion of the side port and subsequently a fast stabilization of both AC and posterior capsule. Also, it helps the surgeon to fixate the eye by providing two support points, namely the proximal outer edge and the distal inner edge of the corneal incision (Figure 1d). Of course, this technique does not prevent a simultaneous clean-up of the



**Figure 1** The twist technique: Creating corneal incision using a 20 gauge microvitrectomy blade (a). Leakage of fluids through the side port after inserting a same size (20 gauge) irrigation probe (black arrow) (b). No more leakage after rotating the probe outwards about 50 degrees (c). The twist technique provides two support points for the irrigation probe to fixate the eye (the outer proximal and inner distal edges of the corneal incision) (2 arrows) and stabilizes the AC and posterior capsule that allows a safe aspiration through the second side port (d). No leakage after hydrating the incision (e).

cortex and the viscoelastic substance using the 20-gauge aspiration probe at the second side port. During twisting the incision, the surgeon should be aware not to touch the corneal endothelium or the iris with the tip of the irrigation probe (Figure 1a–c), (Video 1).

## Discussion

In addition to the traditional bimanual I/A technique,<sup>4</sup> many methods have been described to aspirate the cortex such as the use of coaxial I/A. Nonetheless, removal of the subincisional cortex could be challenging, in particular when the capsulorehxis is not quite large. Also, posterior capsule rupture is more prevalent in the coaxial I/A technique than in the bimanual technique.<sup>5,6</sup> Simcoe I/A cannula is another option. However, the side port should be enlarged.

To minimize the leakage, partial hydration of the side port could be an alternative way. However, it is time-consuming, causes corneal haziness which may affect the view during cortex removal. Also, it could be complicated with unfavorable Descemet membrane detachment, and it does not provide a simultaneous fixation of the eye as it does with our technique. Notably, entering the AC without applying any pressure on the inner side of the wound also reduces leakage and prevents the shallowing of the AC. AC maintainer can sometimes be used to provide more stability to the AC, but an additional corneal incision is needed. Compared to the previous techniques, our simple twist maneuver provides an immediate occlusion of the leaking port and maintains a closed eye system for an uneventful aspiration of the residual cortex. Interestingly, this procedure is cost-free, easy to learn and not time-consuming.

The second benefit of our technique is that movement of the eye is reduced, as twisting the incision offers two contact points between the irrigation probe and the side port (Figure 1d). Thus, drawing back the probe out of the eye and a subsequent collapse of the AC is much less likely. It is especially important when the patient cannot fixate on the light of the microscope under topical anesthesia.<sup>3</sup> Moreover, this maneuver does not affect the integrity and self-sealing property of the side ports (Figure 1e).

## Conclusion

Khaled twist technique offers several advantages to maintain a stable AC compared to other maneuvers. In addition, this simple, cost-free maneuver provides more fixation of the eye and reduces the rate of complications during cortex removal.

## Funding

This research did not receive any specific grant from funding agencies in the public, commercial, or not-for-profit sectors.

## Disclosure

HK: none, BHN: RetInSight, unrelated to this study.

## References

- Schwartz SG, Holz ER, Mieler WF, et al. Retained lens fragments in resident-performed cataract extractions. *CLAO J.* 2002;28(1): 44–47.

2. Geng W, Lin W, Song P, et al. Effect of anterior chamber instability during phacoemulsification combined with intraocular lens implantation. *J Ophthalmol.* 2022;2022:1–10. doi:10.1155/2022/2848565
3. Brogan K, Dawar B, Lockington D, et al. Intraoperative head drift and eye movement: two under addressed challenges during cataract surgery. *Eye.* 2018;32(6):1111–1116. doi:10.1038/s41433-018-0047-x
4. Brauweiler P. Bimanual irrigation/aspiration. *J Cataract Refract Surg.* 1996;22(8):1013–1016. doi:10.1016/S0886-3350(96)80112-X
5. Ti S-E, Yang Y-N, Lang SS, et al. A 5-year audit of cataract surgery outcomes after posterior capsule rupture and risk factors affecting visual acuity. *Am J Ophthalmol.* 2014;157(1):180–185.e1. doi:10.1016/j.ajo.2013.08.022
6. Bai H, Yao L, Wang H. Clinical investigation into posterior capsule rupture in phacoemulsification operations performed by surgery trainees. *J Ophthalmol.* 2020;2020:1317249. doi:10.1155/2020/1317249

## Clinical Ophthalmology

Dovepress

### Publish your work in this journal

Clinical Ophthalmology is an international, peer-reviewed journal covering all subspecialties within ophthalmology. Key topics include: Optometry; Visual science; Pharmacology and drug therapy in eye diseases; Basic Sciences; Primary and Secondary eye care; Patient Safety and Quality of Care Improvements. This journal is indexed on PubMed Central and CAS, and is the official journal of The Society of Clinical Ophthalmology (SCO). The manuscript management system is completely online and includes a very quick and fair peer-review system, which is all easy to use. Visit <http://www.dovepress.com/testimonials.php> to read real quotes from published authors.

Submit your manuscript here: <https://www.dovepress.com/clinical-ophthalmology-journal>