

 **Review Article** 

Recent Advances and Mid-to-Long Term Results of Endovascular Aneurysm Repair for Abdominal Aortic Aneurysms


Noriyasu Morikage, MD and Kimikazu Hamano, MD

Endovascular aneurysm repair (EVAR) has become the standard therapy alongside open surgery repair (OSR) for abdominal aortic aneurysm (AAA) and it is rapidly becoming prevalent. There has been substantial technical progress with respect to EVAR since its introduction. Technical contrivance can be used to manage even inappropriate EVAR cases, including those involving a hostile neck, deficient access route, or aneurysm rupture. However, there are some controversies over reinterventions in relation to long-term outcomes. Although a long-term result has not yet been analyzed in Japan a randomized controlled trial (RCT) held in the West reported that OSR is superior to EVAR for avoiding reinterventions and aneurysm-related death. The RCT involved the use of older devices and proceeded in a different way from the present study; therefore, different results may be obtained for Japanese EVAR outcomes. However, this Western RCT result should be considered as an important warning. Type II endoleak also must be managed in order to improve long term outcomes of EVAR. Efforts to improve both technical methodology and long-term outcomes are necessary to ensure EVAR as a minimally invasive therapy for patients with AAA. (This is a translation of *Jpn J Vasc Surg* 2018; 27: 405–411.)

Keywords: abdominal aortic aneurysm, endovascular aneurysm repair (EVAR), long-term results, instructions for use (IFU), outside IFU

Division of Vascular Surgery, Department of Surgery and Clinical Science, Yamaguchi University Graduate School of Medicine, Ube, Yamaguchi, Japan

Received: December 18, 2018; Accepted: December 19, 2018
Corresponding author: Noriyasu Morikage, MD. Division of Vascular Surgery, Department of Surgery and Clinical Science, Yamaguchi University Graduate School of Medicine, Minami-kogushi 1-1-1, Ube, Yamaguchi 755-8505, Japan
Tel: +81-836-22-2260, Fax: +81-836-22-2423
E-mail: morikage@yamaguchi-u.ac.jp
This is a translation of *Jpn J Vasc Surg* 2018; 27: 405–411.

 ©2019 The Editorial Committee of Annals of Vascular Diseases. This article is distributed under the terms of the Creative Commons Attribution License, which permits use, distribution, and reproduction in any medium, provided the credit of the original work, a link to the license, and indication of any change are properly given, and the original work is not used for commercial purposes. Remixed or transformed contributions must be distributed under the same license as the original.

Introduction

Eleven years have passed since stent graft endovascular aneurysm repair (EVAR) was introduced in Japan in 2007, when it quickly gained popularity. As of 2015, 51,380 cases were registered with the Japanese Committee for Stentgraft Management (JACSM) registry, which was simultaneously established with the introduction of EVAR, and the outcomes of these cases have been analyzed.¹⁾ In this registry, 7 factors were established for the outside-instruction for use (IFU) cases, and it was determined that 47.6% of cases are now outside IFU.¹⁾ While this comprehensive analysis of big data may have inadvertently included some IFU cases depending on the type of the device, the proportion of outside IFU cases still exceeds expectations even if such cases were excluded. The reported operative mortality rate of 1.15%¹⁾ was not inferior to past large-scale studies based on IFU cases.^{2–4)} According to the annual report of the number of vascular surgeries registered at the National Clinical Database, as verified by the Japanese Society for Vascular Surgery database Management Committee, EVAR exceeded open surgical repair (OSR) in 2013 (<http://www.jsvs.org/ja/>), and has now truly become a standard treatment for abdominal aortic aneurysm (AAA). This report aims to outline recent technological advances in EVAR, summarize long-term results, and highlight issues for improvement together with a discussion of cases treated at our institution.

Recent Technological Advances in EVAR

Hostile neck resolution and treatment outcomes

To successfully treat cases of outside IFU in the proximal neck, termed “hostile neck,” type Ia endoleaks (EL) must be reliably controlled. If this is not achieved, reintervention may become more difficult along with the increased risk of occurrence of rupture. Cases of short neck must undergo treatment for accurate placement of the edge of the graft fabric of stent graft directly under the renal artery. One technique is the Endowedge technique, which uses the Excluder (W.L. Gore and Associates, Flagstaff, AZ, USA).⁵⁾ For the Endurant (Medtronic, Santa Rosa,

CA, USA), techniques include alternate, slow deployment of the main body and suprarenal stent, and the reverse slider technique.⁶ For angulated necks, the Excluder scrum technique⁵ and the Endurant push-up technique⁷ are both known to be useful. However, planning is crucial in the implementation of such technical adjustments. As the stent graft is not necessarily placed axially in the aorta, particularly in cases involving severe angulation, it is important that the treatment plan predicts the morphology of the actual placement. Of the various types of hostile neck, short neck in particular is the greatest risk factor for type Ia EL. The incidence in standard EVAR ranges from 5% to 10%.^{8,9} Oliveira-Pinto et al.¹⁰ gathered 13 observational studies related to outside IFU cases and compared the long-term outcomes of these studies with those of 4 randomized controlled trials (RCTs) of IFU cases (EVAR-1, DREAM, OVER, ACE). They found that the rate of type Ia EL occurrence was equivalent between inside IFU and outside IFU with angulated or thrombus load neck. However, short neck was the factor to increase type Ia EL. In the ENGAGE registry, the largest EVAR registry for single devices, the only anatomical factor for type Ia EL is a short neck <10 mm.⁸ Accordingly, in Western countries, fenestrated EVAR, branched EVAR, and chimney EVAR

(chEVAR) are performed for cases of short neck, with some multicenter joint studies and systematic reviews investigating this topic.¹¹⁻¹³ Thirteen facilities from Europe and the US participated in the PERICLES registry, the largest registry for chEVAR in the world with 517 registered cases. Favorable outcomes have been reported for these cases, with type Ia EL arising in 2.9% of cases over a mean follow-up period of 17.1 months.¹² In our institution, for cases of short neck with risk of type Ia EL with just standard EVAR, complete use of the short neck below the renal artery is ensured by the chimney technique. The stent graft is placed at a more proximal level of the renal artery and blood flow is ensured with a bare-metal stent (Fig. 1).⁶ Results were found to be identical for both IFU and outside IFU proximal neck cases, including chimney cases, with occurrence of type Ia EL at 0.8% (3/389 cases) and 1.0% (2/207 cases) and the reintervention avoidance rate at 99.2% and 98.5% at 1 year and 98.4% and 98.5% at 3 years. As the long-term outcomes remain unknown, EVAR should only be considered as a treatment option for cases considered unsuitable for open repair. However, the addition of technical adjustments for cases of hostile neck has made it possible to perform EVAR on more patients. Previously, surgery was avoided for high-risk cases con-

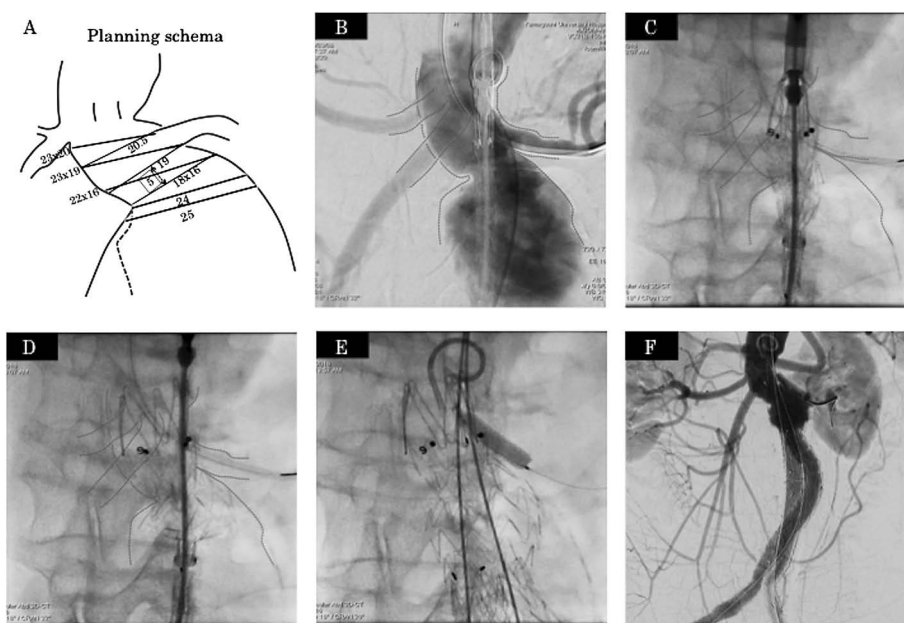


Fig. 1 Hostile neck case (short and angulated neck).

A: Planning schema, short and angulated neck case with 5 mm length from lower left renal artery to aneurysm, 90° neck angulation. **B:** Intraoperative angiogram. **C:** Before releasing suprarenal stent, the main body and suprarenal stent were deployed alternately and slowly to dilate the proximal edge of endograft. **D:** After deploying the 3rd stent, suprarenal stent was released, and endograft was fitted along shape of aneurysm transition with good conformability using the push-up technique. **E:** After the endograft was implanted, a bare stent was deployed into the left renal artery. **F:** The final angiogram showed patency of the left renal artery and no endoleak.

sidered unsuitable for surgery. Recent advances have now made it possible to provide minimally-invasive treatment for such cases.

EVAR for poor-access routes

Cases presenting with femoral and iliac artery stenosis and occlusion or severe angulation are considered cases of outside IFU. We have previously treated one case for which treatment was discontinued owing to poor access when EVAR was first introduced. As devices have technically improved and we have gained experience in performing these endovascular treatments, EVAR is no longer avoided because of poor access. While techniques such as guidewire replacement, balloon pre-dilatation, and pull-through technique can be effective, they do not provide consistent outcomes. Therefore, the treatment method must be carefully considered for each individual patient. We have empirically determined that for cases for which access is predicted to be poor, it is effective to expose at least the common femoral artery (CFA) and guide the external iliac artery (EIA) to some extent. Naturally, if the access route is damaged, rescue by means of instant bleeding control and endovascular treatment must be performed after sufficient preparation. In some cases, it may be better to change the treatment plan to an aorto-uni-iliac (AUI) stent graft.

In terms of recent advances, we will describe AAA complicated by iliac artery occlusion, a classic type of poor-access route. When iliac artery chronic total occlusion (CTO) occurs, options include an AUI stent graft or hybrid surgery, in which feasibility of adding a femoral–femoral (F–F) artery bypass to an AUI stent graft is determined by the state of collateral blood flow from the internal iliac artery or lumbar artery. A bifurcated stent graft can be used as a means of anatomical revascularization similar to OSR. Vallabhaneni et al.¹⁴⁾ reported that bifurcated stent graft treatment was successful for 13 (92.9%) out of 14 cases of AAA complicated by iliac artery occlusion (occlusion length: 79.2 ± 45.2 mm), and patency was achieved for all cases (mean follow-up period: 28.2 months). At our institution, the first treatment option is a bifurcated stent graft with anatomical revascularization (Fig. 2). With this technique, the site of arterial occlusion is recanalized and as a rule, a 12-Fr sheath is inserted without dilatation of the balloon after the contralateral leg is deployed here. In fact, there were 15 cases of AAA complicated by femoral and iliac artery occlusion, and the CTO lesions was the common iliac artery (CIA) for 3 cases, the CIA–EIA for 2 cases, the EIA for 7 cases, and the EIA–CFA for 1 case (mean occlusion length: 89.7 ± 43.6 mm). Bifurcated stent graft was placed in 13 cases with a technical success rate of 86.7%. An AUI+F–F bypass was performed for the 2 cases of CIA–EIA and EIA occlusion for which the occlu-

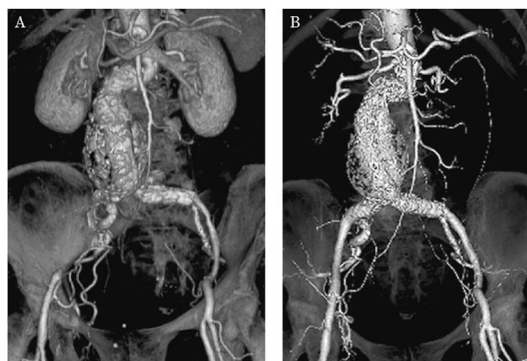


Fig. 2 EVAR using bifurcated endoprosthesis with concomitant recanalization of iliac artery occlusion. Patient 5.5-cm abdominal aortic aneurysm and right EIA occlusion. **A:** Pre-procedure CTA, **B:** Post-procedure CTA.

sion site could not be recanalized.¹⁵⁾ For the initial case, peripheral embolization was observed when the balloon was dilated before sheath insertion and the thrombus had to be intraoperatively excised. No arterial damage or any other complications were noted and patency was achieved for any of the cases without reintervention (follow-up period: 17.2 ± 17.7 months).¹⁵⁾ While long-term outcomes remain unclear for these cases and careful follow-up observations are still required, we believe that using bifurcated stent grafts following iliac artery recanalization for concomitant AAA and CTO of access routes could become a standard technique if further advances are achieved in devices.

EVAR for ruptured abdominal aortic aneurysm

In 2000, Ohki et al.¹⁶⁾ reported favorable results of EVAR performed for ruptured abdominal aortic aneurysm (RAAA), with an operative mortality rate of 10% (2/20 cases). After this report, many observational studies were conducted and in 2008, Mastracci et al.¹⁷⁾ released a meta-analysis demonstrating a 21% mortality rate for EVAR. The IMPROVE trial, which was a typical large-scale RCT, indicated no superiority for EVAR in terms of 30-day mortality rate, which was 35% compared with 37% for OSR.¹⁸⁾ At 3 years, the mortality rate was significantly lower for EVAR (42%) than for OSR (54%).¹⁹⁾ Additionally, compared with OSR, EVAR resulted in higher quality of life, shorter duration of hospital stay, and decreased costs in addition to longer quality-adjusted life-year expectancy.¹⁹⁾ The utility of a protocol designating EVAR as the first-line treatment has been previously reported.^{20,21)} At our institution, EVAR was designated as a first-line treatment for RAAA in November 2011. As of October 2017, we have performed EVAR for 38 RAAA cases (including 4 cases of cardiopulmonary arrest on arrival or in the emergency room). Indications for selecting EVAR are proximal neck length of minimum 10 mm and a

proximal neck diameter of ≤ 32 mm, including some cases with proximal neck of < 10 mm. If a patient is considered eligible for EVAR, they are quickly transported to the hybrid operating theater and EVAR is immediately initiated under a condition that proximal aortic control is possible after inserting a 12–18-Fr sheath and stent graft balloon with femoral artery puncture under local anesthesia. Postoperative bleeding is a decisive factor in determining the success of EVAR for ruptured aneurysms, as a type Ia EL is fatal. Although 18 of our cases (47.3%) were proximal neck outside IFU patients, we avoided type Ia EL in all of these cases. Avoiding type Ia EL is an absolute requirement in the treatment of ruptured aneurysms with EVAR. A similar level of caution is also required not only for type Ib and III EL but also for type II EL in rupture cases. If massive bleeding causes coagulation hemostasis function to fail, persistent bleeding from the rupture hole can result in shock, even in type II EL cases. In some cases, expansion of retroperitoneal hematoma can cause abdominal compartment syndrome (ACS).²²⁾ Previous work has shown that injections of N-butyl-2-cyanoacrylate (NBCA) into the aneurysm are effective for preventing post-EVAR persistent bleeding, in such cases where massive bleeding has impaired coagulation function.²³⁾ At our institution, we perform intra-aneurysm embolization using NBCA for cases classified as Fitzgerald III preoperatively or in cases with unstable hemodynamics following stent graft placement (Fig. 3). In either case, computed tomography (CT) is used to postoperatively confirm that the rupture hole was reliably closed by NBCA, and it appears to be a beneficial technique for controlling persistent post-EVAR bleeding. However, indications require further investiga-

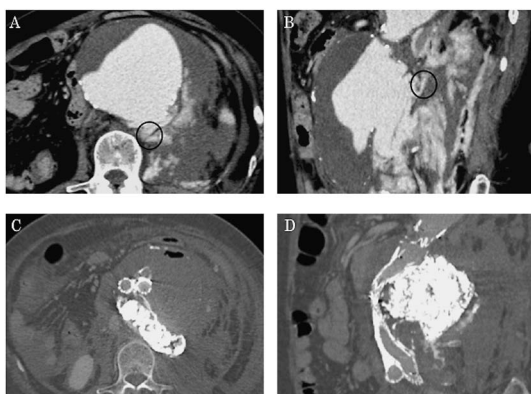


Fig. 3 Sac embolization in EVAR for ruptured AAA. Preoperative contrast-enhanced CT scan (A: axial image, B: sagittal image) showed 9.0-cm ruptured AAA and extravasation of the contrast material. Black circle indicates the bleeding site. Postoperative bone window CT image (C: axial image, D: sagittal image) showed the accumulation of NBCA from sac to retroperitoneal space, it covered the bleeding site.

tions as it is associated with the risk of embolization as a complication. Moreover, ACS differs somewhat depending on the association with EVAR or OSR, primarily involving intestinal edema with OSR but mainly hematoma with EVAR. While the necessity of open abdominal treatment (OAT) for ACS is the same as that of OAT for OSR, if OAT is performed after EVAR, single-stage retroperitoneal incision should be avoided, and the procedure should only be considered after confirmation of no persistent bleeding and coagulation hemostasis has been rectified. In cases of severe ACS, the fact that type II EL is not apparent on pre-OAT arteriography must be considered.

The greatest advantage of EVAR is that treatment for RAAA can be performed within a short period of time. While it is clear that the operative time for EVAR is shorter than that for OSR, a protocol establishing EVAR as the first-line treatment could also promote a sense of urgency regarding the condition in each treating department to organize a coordinated in-hospital team system, thereby shortening the time to surgery initiation. While EVAR for RAAA involves specific challenges that are different from non-rupture cases, it is now possible to achieve favorable outcomes and high-quality life-saving if appropriate treatment is immediately implemented.

Long-Term Outcomes of EVAR and Issues for Improvement

RCTs of EVAR and OSR

In previous literature, it has been reported that 4 RCTs have been implemented—EVAR-1, DREAM, OVER, and ACE.^{2–4,24)} In the EVAR-1, DREAM, and OVER reports, it was demonstrated that EVAR achieved a significantly low aneurysm-related mortality (ARM) rate in the early stages, indicating beneficial early outcomes.^{2–4)} However, the EVAR-1 study found no significant difference in overall ARM (median follow-up period: 12.4 years), (EVAR vs. OSR: 8.9% vs. 7.2%, $p=0.21$). ARM was significantly lower in EVAR at 0–6 months (EVAR vs. OSR: 2.2% vs. 4.8%, $p=0.0031$). However, at 8 years, ARM was significantly lower in OSR (EVAR vs. OSR: 4.7% vs. 0.9%, $p=0.006$). The main reason of this was rupture (Fig. 4).²⁾ Over the 12-year follow-up period in the DREAM trial, no significant differences were noted for the cumulative survival rate (EVAR vs. OSR: 38.5% vs. 42.2%, $p=0.48$) or ARM (EVAR vs. OSR: 4.8% vs. 7.4%, $p=0.35$). However, the reintervention avoidance rate was significantly higher for OSR (EVAR vs. OSR: 62.2% vs. 78.9%, $p=0.01$), indicating that more additional treatment was required for EVAR (Fig. 5).³⁾ While the EVAR-1 and DREAM trials showed that far more reintervention was required for EVAR, the results of the OVER trial indicated no difference between the 2 procedures over a mean

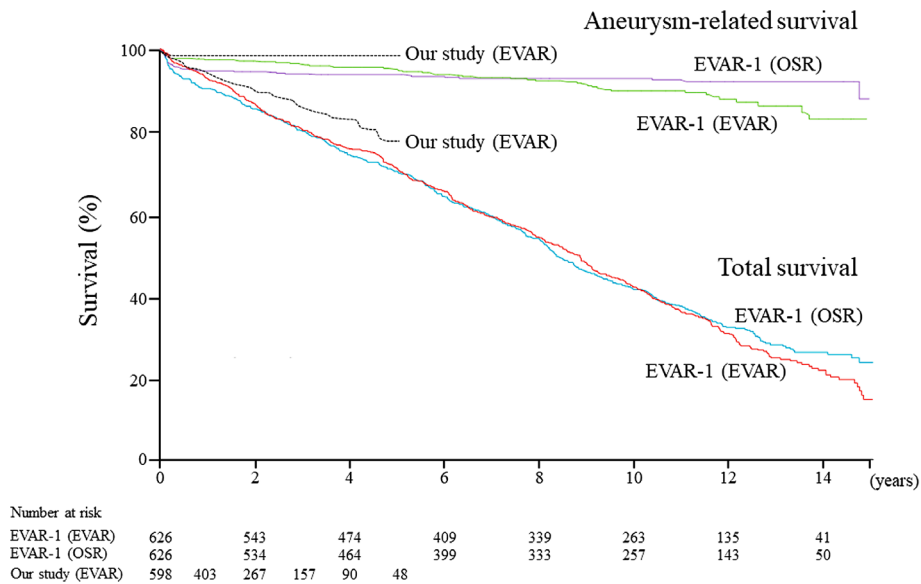


Fig. 4 Kaplan–Meier estimates for total survival and aneurysm-related survival in EVAR trial 1 (Patel R et al. Endovascular versus open repair of abdominal aortic aneurysm in 15-years’ follow-up of the UK endovascular aneurysm repair trial 1 (EVAR trial 1): a randomised controlled trial. *Lancet* 2016. [http://dx.doi.org/10.1016/S0140-6736\(16\)31135-7](http://dx.doi.org/10.1016/S0140-6736(16)31135-7)) and our study.

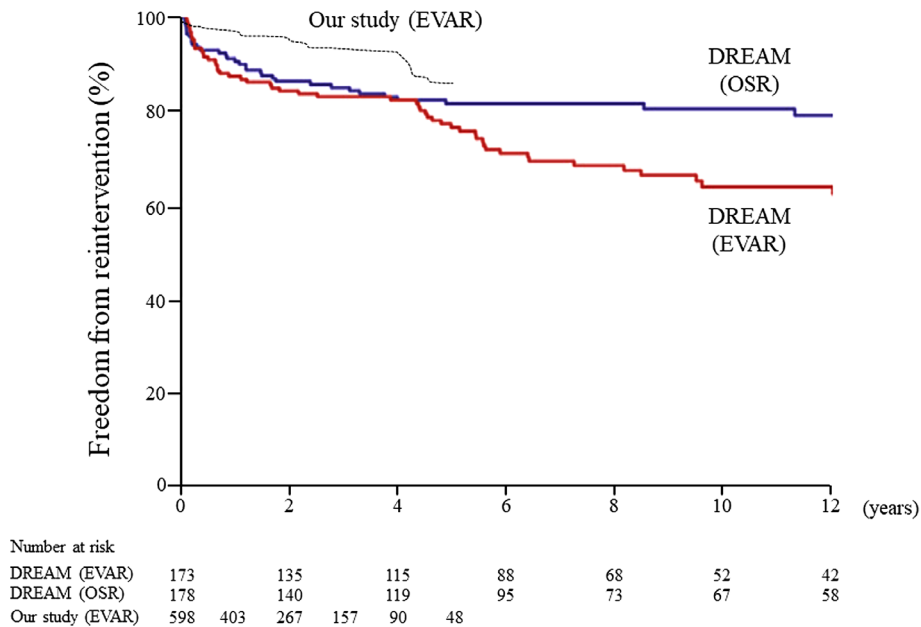


Fig. 5 Kaplan–Meier estimates of freedom from reintervention in DREAM trial (Van Schaik TG et al. Long-term survival and secondary procedures after open or endovascular repair of abdominal aortic aneurysms. *J Vasc Surg* 2017. <http://dx.doi.org/10.1016/j.jvs.2017.05.122>) and our study.

follow-up period of 5.2 years.⁴⁾ Moreover, a meta-analysis compiling the results of these 4 RCTs (median follow-up period: 5.5 years) reported that while the 30-day ARM was significantly lower for EVAR, there was no difference for the next 3 years. From 3 years onward, the ARM was significantly increased for EVAR.²⁵⁾ Among our own cases,

an analysis of 596 EVAR cases (including 38 rupture cases) that underwent CT from 3 months postoperatively (follow-up period: 28.0 ± 20.9 months) indicated that the additional treatment avoidance rate was 99.0% at 1 year, 94.2% at 3 years, and 84.7% at 5 years (Fig. 5). In addition, aneurysm-related death occurred in the perioperative

Table 1 Early outcomes: EVAR-1, DREAM versus our study

Outcome (0–6 months)	EVAR-1 (n=626)	DREAM (n=173)	Our study (n=596)
Aneurysm related-mortality	14 (2.2%)	3 (3.5%)	6 (1.0%)
Rupture before EVAR	5	0	4
Rupture after EVAR	7	0	0
Other	2	3	2
Reinterventions	67 (10.7%)	14 (16.5%)	11 (1.8%)

period in only 6 cases (1.0%), including 4 cases involving ruptures resulting in preoperative shock. When limited to cases involving elective surgery, aneurysm-related death was observed in 2 cases (0.4%). The aneurysm-related death avoidance rate, including preoperative rupture cases, was 99.2% at 1 year, 99.2% at 3 years, and 99.2% at 5 years (Fig. 4). As the follow-up period for our cases was shorter than the previously reported RCTs, we cannot reliably compare our long-term outcomes. Therefore, we showed a comparison of outcomes for our cases with EVAR-1²⁾ and DREAM,³⁾ for early outcomes over the first 0–6 months, which could be reliably compared (Table 1). Comparing our results and the reports from EVAR-1 and DREAM at 0–6 months postoperatively, our relative risk reduction (RRR) for ARM was 45.5% (vs. EVAR-1) and 71.4% (vs. DREAM), and RRR for reintervention was 83.2% (vs. EVAR-1) and 89.1% (vs. DREAM), indicating that early outcomes for our cases were clearly favorable. It is presumed that our superior results are indicative of the recent technological advances as we used the current, improved model in comparison to these previous RCTs which employed older generation models. As there remain differences in early outcomes, they will not necessarily lead to the same long-term outcomes as reported by previous RCTs. However, despite this, the ruptures reported in the EVAR-1 trial as having occurred after a fairly long period of time postoperatively²⁾ indicates the importance of long-term follow-up, including diagnostic imaging. We have to keep in our mind these precepts when implementing such follow-up protocols.

Response to type II EL

The JACSM registry also indicates that type II EL is a risk factor for post-EVAR aneurysm expansion.¹⁾ Among our cases, type II EL was the most common reason for reintervention, accounting for 25%. Aneurysm expansion due to type II EL can result in various clinical courses; in cases with relatively short proximal and distal landings in particular, caution is required regarding further landing shortening due to vertical expansion. Among our cases, 2 of the 5 cases (0.8%) of type Ia EL and 2 of the 8 cases (1.3%) of type Ib EL that occurred during the follow-up period involved a secondary aneurysm expansion due to type II EL. Therefore, 30.7% of the type I EL cases were caused by type II EL. Accordingly, type II EL appears to be

an important factor affecting long-term results of EVAR.

There have been many reports investigating type II EL risk factors. A meta-analysis showed that if non-smokers were excluded, most cases involved anatomical factors, including aortic side branches such as inferior mesenteric artery (IMA) and lumbar artery, or aneurysmal thrombus quantity.^{26,27)} We previously reported that in our cases, each independent risk factor was as follows: IMA of ≥ 3 mm, IMA patency with lumbar artery of ≥ 2 mm, or IMA patency with aortoiliac type.²⁸⁾ Many observational studies and meta-analyses have investigated pre-EVAR IMA embolization with the aim of inhibiting type II EL and have indicated that the procedure is fairly effective. However, these were all retrospective studies.²⁹⁾ We are currently conducting an RCT (UMIN000022147) to target type II EL high-risk cases with one of the above 3 risk factors and aim to determine whether IMA embolization during EVAR can inhibit type II EL.²⁹⁾ If a few slight adjustments are made, operative time, irradiation time, and contrast medium volume for IMA embolization during EVAR could be comparable with cases which do not undergo embolization, which is acceptable as an option during EVAR.³⁰⁾ We plan to discuss the utility of this procedure following the conclusion of the ongoing RCT. It is more difficult to treat the lumbar artery than the IMA, and there are various unresolved issues regarding the validity and methods for actual clinical application. Meanwhile, Nelix (Endologix, Santa Rosa, CA, USA), which is yet unapproved in Japan, involves a completely new concept called endovascular aneurysm sealing (EVAS), which has drawn interest from the viewpoint and goal of suppressing type II EL.

The treatment of type II EL remains controversial, with no fixed consensus regarding the necessity of interventional treatment, optimal timing, and/or choice in method. However, as type II EL affects long-term treatment outcomes, developing some sort of treatment strategy for high-risk cases determined based on accurate risk classifications is necessary to improve long-term outcomes.

Conclusion

As the recent advances in EVAR, we focused on the technological advances in cases of hostile neck and poor access, as well as the treatment for RAAA. We also presented

long-term outcomes from RCTs such as EVAR-1 and DREAM and countermeasures for type II EL as the related issues, together with the outcomes for cases in our own practice. Although the long-term outcomes reported in previous RCTs are suggestive of common problems, these are not necessarily related to the use of EVAR in Japan. This is likely because these RCTs were conducted using previous generation devices; steady advances have been made in EVAR technology since then. Despite this, these results are valuable as an important warning. In order to completely determine the benefits of less-invasive EVAR, both the devices and technology must evolve.

Disclosure Statement

There are no conflicts of interest to declare with regards to this article.

Additional Note

The main ideas introduced in this article were presented at the 27th Educational Seminar of the Japanese Society for Vascular Surgery (May 11, 2018, Yamagata).

References

- Hoshina K, Ishimaru S, Sasabuchi Y, et al. Outcomes of endovascular repair for abdominal aortic aneurysms: a nationwide survey in Japan. *Ann Surg* 2017; Sep 6. [Epub ahead of print] Available from: doi: 10.1097/SLA.0000000000002508
- Patel R, Sweeting MJ, Powell JT, et al.; EVAR trial investigators. Endovascular versus open repair of abdominal aortic aneurysm in 15-years' follow-up of the UK endovascular aneurysm repair trial 1 (EVAR trial 1): a randomised controlled trial. *Lancet* 2016; 388: 2366-74.
- van Schaik TG, Yeung KK, Verhagen HJ, et al.; DREAM trial participants. Long-term survival and secondary procedures after open or endovascular repair of abdominal aortic aneurysms. *J Vasc Surg* 2017; 66: 1379-89.
- Lederle FA, Freischlag JA, Kyriakides TC, et al. Long-term comparison of endovascular and open repair of abdominal aortic aneurysm. *N Engl J Med* 2012; 367: 1988-97.
- Banno T, Kato R, Hanaoka R, et al. Technical tips for endovascular aortic repair using the Gore Excluder abdominal stent-graft: endo-wedge technique and scrum technique. *Open Med Imaging J* 2014; 8: 8-21.
- Morikage N, Mizoguchi T, Takeuchi Y, et al. Usefulness of chimney EVAR using Endurant stent graft for patients with juxtarenal abdominal aortic aneurysms. *Japanese Journal of Endovascular Intervention* 2018; 19: 36-41. (in Japanese)
- Dohi S, Yokoyama Y, Yamamoto T, et al. Push-up technique and anatomical deployment with the Endurant stent-graft system for severely angulated aneurysm necks. *J Endovasc Ther* 2017; 24: 435-9.
- Bastos Goncalves F, Hoeks SE, Teijink JA, et al. Risk factors for proximal neck complications after endovascular aneurysm repair using the Endurant stentgraft. *Eur J Vasc Endovasc Surg* 2015; 49: 156-62.
- Gallitto E, Gargiulo M, Freyrie A, et al. Results of standard suprarenal fixation endografts for abdominal aortic aneurysms with neck length ≤ 10 mm in high-risk patients unfit for open repair and fenestrated endograft. *J Vasc Surg* 2016; 64: 563-70.e1.
- Oliveira-Pinto J, Oliveira N, Bastos-Gonçalves F, et al. Long-term results of outside "instructions for use" EVAR. *J Cardiovasc Surg (Torino)* 2017; 58: 252-60.
- Katsargyris A, Oikonomou K, Klonaris C, et al. Comparison of outcomes with open, fenestrated, and chimney graft repair of juxtarenal aneurysms: are we ready for a paradigm shift? *J Endovasc Ther* 2013; 20: 159-69.
- Donas KP, Lee JT, Lachat M, et al.; PERICLES investigators. Collected world experience about the performance of the snorkel/chimney endovascular technique in the treatment of complex aortic pathologies. *Ann Surg* 2015; 262: 546-53; discussion, 552-3.
- Li Y, Hu Z, Bai C, et al. Fenestrated and chimney technique for juxtarenal aortic aneurysm: a systematic review and pooled data analysis. *Sci Rep* 2016; 6: 20497.
- Vallabhaneni R, Sorial EE, Jordan WD Jr, et al. Iliac artery recanalization of chronic occlusions to facilitate endovascular aneurysm repair. *J Vasc Surg* 2012; 56: 1549-54; discussion, 1554.
- Takeuchi Y, Morikage N, Mizoguchi T, et al. Using bifurcated endoprosthesis after iliac artery recanalization for concomitant abdominal aortic aneurysm and chronic total occlusions of access routes. *J Vasc Surg* 2018; Dec 8. [Epub ahead of print] Available from: doi: <https://doi.org/10.1016/j.jvs.2018.08.191>
- Ohki T, Veith FJ. Endovascular grafts and other image-guided catheter-based adjuncts to improve the treatment of ruptured aortoiliac aneurysms. *Ann Surg* 2000; 232: 466-79.
- Mastracci TM, Garrido-Olivares L, Cinà CS, et al. Endovascular repair of ruptured abdominal aortic aneurysms: a systematic review and meta-analysis. *J Vasc Surg* 2008; 47: 214-21.e14.
- Powell JT, Sweeting MJ, Thompson MM, et al. Endovascular or open repair strategy for ruptured abdominal aortic aneurysm: 30 day outcomes from IMPROVE randomised trial. *BMJ* 2014; 348: f7661.
- IMPROVE Trial Investigators. Comparative clinical effectiveness and cost-effectiveness of endovascular strategy v open repair for ruptured abdominal aortic aneurysm: three year results of the IMPROVE randomised trial. *BMJ* 2017; 359: j4859.
- Mehta M, Taggart J, Darling RC 3rd, et al. Establishing a protocol for endovascular treatment of ruptured abdominal aortic aneurysms: outcomes of a prospective analysis. *J Vasc Surg* 2006; 44: 1-8; discussion, 8.
- Ogino H, Watanabe K, Ikegaya Y, et al. Protocol-based strategy for endovascular repair of ruptured abdominal aortic aneurysms. *Ann Vasc Dis* 2013; 6: 169-74.
- Ogawa Y, Nishimaki H, Chiba K, et al. Life-saving embolization in a patient with recurrent shock due to a type II endoleak after endovascular aortic repair for a ruptured abdominal aortic aneurysm. *Ann Vasc Dis* 2015; 8: 131-4.
- Koike Y, Nishimura J, Hase S, et al. Sac angiography and glue embolization in emergency endovascular aneurysm

- repair for ruptured abdominal aortic aneurysm. *Cardiovasc Intervent Radiol* 2015; **38**: 457-62.
- 24) Becquemin JP, Pillet JC, Lescalie F, et al. ACE trialists. A randomized controlled trial of endovascular aneurysm repair versus open surgery for abdominal aortic aneurysms in low-to moderate-risk patients. *J Vasc Surg* 2011; **53**: 1167-73.e1.
- 25) Powell JT, Sweeting MJ, Ulug P, et al. Meta-analysis of individual-patient data from EVAR-1, DREAM, OVER and ACE trials comparing outcomes of endovascular or open repair for abdominal aortic aneurysm over 5 years. *Br J Surg* 2017; **104**: 166-78.
- 26) Fujimura N, Obara H, Matsubara K, et al. Characteristics and risk factors for type 2 endoleak in an East Asian population from a Japanese multicenter database. *Circ J* 2016; **80**: 118-23.
- 27) Lalys F, Durrmann V, Duménil A, et al. Systematic review and meta-analysis of preoperative risk factors of type II endoleaks after endovascular aneurysm repair. *Ann Vasc Surg* 2017; **41**: 284-93.
- 28) Samura M, Morikage N, Mizoguchi T, et al. Identification of anatomical risk factors for type II endoleak to guide selective inferior mesenteric artery embolization. *Ann Vasc Surg* 2018; **48**: 166-73.
- 29) Samura M, Morikage N, Mizoguchi T, et al. Effectiveness of embolization of inferior mesenteric artery to prevent type II endoleak following endovascular aneurysm repair: a review of the literature. *Ann Vasc Dis* 2018; **11**: 259-64.
- 30) Morikage N, Samura M, Takeuchi Y, et al. Innovative procedure for inferior mesenteric artery embolization using the Amplatzer Vascular Plug 4 during endovascular aneurysm repair. *Ann Vasc Surg* 2017; **44**: 431-8.