

A Comparative Study of Safety and Efficacy of Ultrasound-Guided Infra-Clavicular Axillary Vein Cannulation versus Ultrasound-Guided Internal Jugular Vein Cannulation in Adult Cardiac Surgical Patients

Abstract

Background: Ultrasound (US)-guided internal jugular vein (IJV) cannulation is a widely accepted standard procedure. The axillary vein (AV) in comparison to the subclavian vein is easily visualized, but its cannulation is not extensively studied in cardiac patients. **Aims:** This study is an attempt to study the efficacy of real-time US-guided axillary venous cannulation as a safe alternative for the time-tested US-guided IJV cannulation. **Design:** This is a prospective randomized controlled study. **Materials and Methods:** A total of 100 adult patients scheduled for cardiac surgery were divided equally in Group A-US-guided IJV cannulation, and Group B-US-guided axillary venous cannulation. Under local anesthesia and real-time US guidance the IJV or AV was secured. The access time, guidewire time, and procedure time were noted. Furthermore, the number of needle attempts, malposition, change of site, and complications were noted. **Results:** The data were analyzed for 49 patients in Group A and 48 patients in the Group B due to exclusions. The access time and the guidewire time were comparable in both groups. The first attempt needle puncture was successful for the IJV group in 98% of patients in comparison to 95% of patients in Group B. Guidewire was passed in the first attempt in 94% in Group A and 89% in the Group B. Except for arterial puncture in one case in group A, the complications were insignificant in both groups. **Conclusion:** The study shows that the US-guided AV cannulation may serve as an effective alternative to the IJV cannulation in cardiac surgery.

Keywords: Anesthesia, axillary vein, ultrasound

Introduction

Ultrasound (US) is increasingly utilized to enhance the safety and success while cannulating major vascular structures.^[1] In cardiac anesthesia, the internal jugular vein (IJV) is the most commonly utilized site due to many advantages such as straight course into the superior vena cava (SVC), ease, familiarity of the landmarks, and its high success rates. It lends itself well to US and the US-guided IJV cannulation is accepted as evolving standard of care in many clinical areas.^[2]

There are suggested advantages of the subclavian or axillary vein (AV) cannulation with regard to colonization, possible infection, and thrombosis in pediatric and adult patients.^[3] The subclavian vein is not amenable easily to the US due to its location while the AV is quite easily visualized and also has the advantage

of being the easily compressible site.^[4] Large studies have revealed the benefits of US-guided AV cannulation in diverse areas such as the intensive care units, oncology, and emergency medicine.^[5,6] The literature is quite sparse with respect to the US-guided AV cannulation in anesthesia.

This study is an attempt to reveal the efficacy of the US-guided AV cannulation as an alternative to IJV cannulation.

Materials and Methods

After the Institutional Medical Ethics and Scientific Research Committee approval a prospective, randomized, controlled comparative study was carried out in 100 adult patients due to undergo elective coronary artery surgery and cardiac valve surgery during 1 year (January 2017– January 2018). Written informed valid consent was obtained from all the patients for participation in the study.

How to cite this article: Shinde PD, Jasapara A, Bansode K, Bunage R, Mulay A, Shetty VL. A comparative study of safety and efficacy of ultrasound-guided infra-clavicular axillary vein cannulation versus ultrasound-guided internal jugular vein cannulation in adult cardiac surgical patients. *Ann Card Anaesth* 2019;22:177-86.

Prajakta D Shinde,
Amish Jasapara,
Kishan Bansode,
Rohit Bunage,
Anvay Mulay,
Vijay L Shetty¹

Departments of Anaesthesiology and Cardiac Surgery and ¹Anaesthesiology, Fortis Hospital, Mumbai, Maharashtra, India

Address for correspondence:
Dr. Prajakta D Shinde,
Department of Anaesthesiology,
Fortis Hospital, Mulund
Goregaon Link Road,
Mulund West,
Mumbai - 400 078,
Maharashtra, India.
E-mail: dr.prajaktadshinde@
gmail.com, vijay.drviijays@
gmail.com

Access this article online

Website: www.annals.in

DOI: 10.4103/aca.ACA_24_18

Quick Response Code:



This is an open access journal, and articles are distributed under the terms of the Creative Commons Attribution-NonCommercial-ShareAlike 4.0 License, which allows others to remix, tweak, and build upon the work non-commercially, as long as appropriate credit is given and the new creations are licensed under the identical terms.

For reprints contact: reprints@medknow.com

Exclusion criteria included patient refusal, weight >100 kg or Body Mass Index (BMI) >35, arrhythmia, history of allergy to local anesthetic, infection at the sites of insertion, previous venous cannulation in the past 6 months, and underlying lung disease.

Sample size

Considering success rate of AV cannulation around 80%^[5] and that the success rate of IJV around 99% based on our pilot studies and other studies in literature,^[2,7] the power of the study is 80% with 5% level of significance. The sample size required was calculated as 92 and 50 patients were enrolled for both groups.

The recruited patients were randomly assigned to IJV group and AV group based on computer-generated

random number table. The procedure was performed by one of two experienced anesthetists with >5-year experiences in US vascular cannulation. Scout ultrasonography (USG) scan was performed in the operation theater before draping to confirm the patency of bilateral IJV veins and AVs in patients of both groups and to rule out anatomical variations [Figure 2a and b]. The patients in whom the vertical depth of the AV from the skin was >4 cm or with a venous thrombus detected by the scout scan were excluded from the study.

On the operating table, routine monitors were applied and mild sedation provided with injection midazolam 1 mg and injection fentanyl 50 mcg. The entire area about the bilateral IJV and bilateral AV region was cleaned as per institutional protocol, and the whole-body draped. A gentle Trendelenburg position was given. A high-frequency (13-6 MHz) Linear US probe (GE VENUE40™ SONOGRAPHY MACHINE) with jelly and sterile camera cover was used. An 8F, 15 cm long, four-lumen CERTOFIX BBraun™ catheter was secured.

In patients randomized under Group B-USG-guided AV, With the patient in gentle Trendelenburg position, head neutral and right arm in abducted position, the USG scan was performed over the infraclavicular (IC) region where right AV was located in the long axis and its entire course revealed [Figure 1]. The right IJV and its course was also revealed. The vertical depth of the right AV from the skin was noted. Local anesthesia was administered under USG guidance along the proposed needle path. The puncture of the right AV was performed under USG guidance under

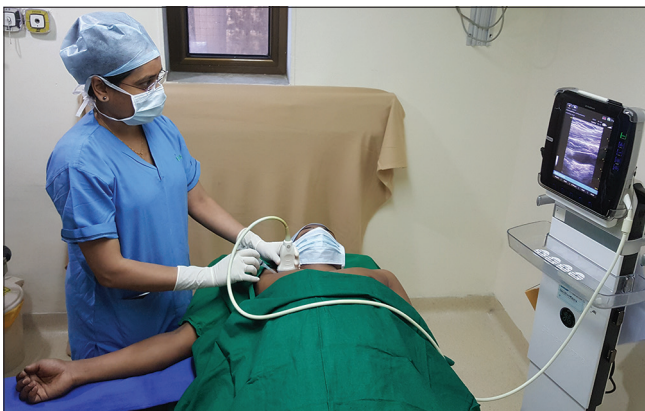

Figure 1: Patient position for ultrasound scan for right axillary vein cannulation

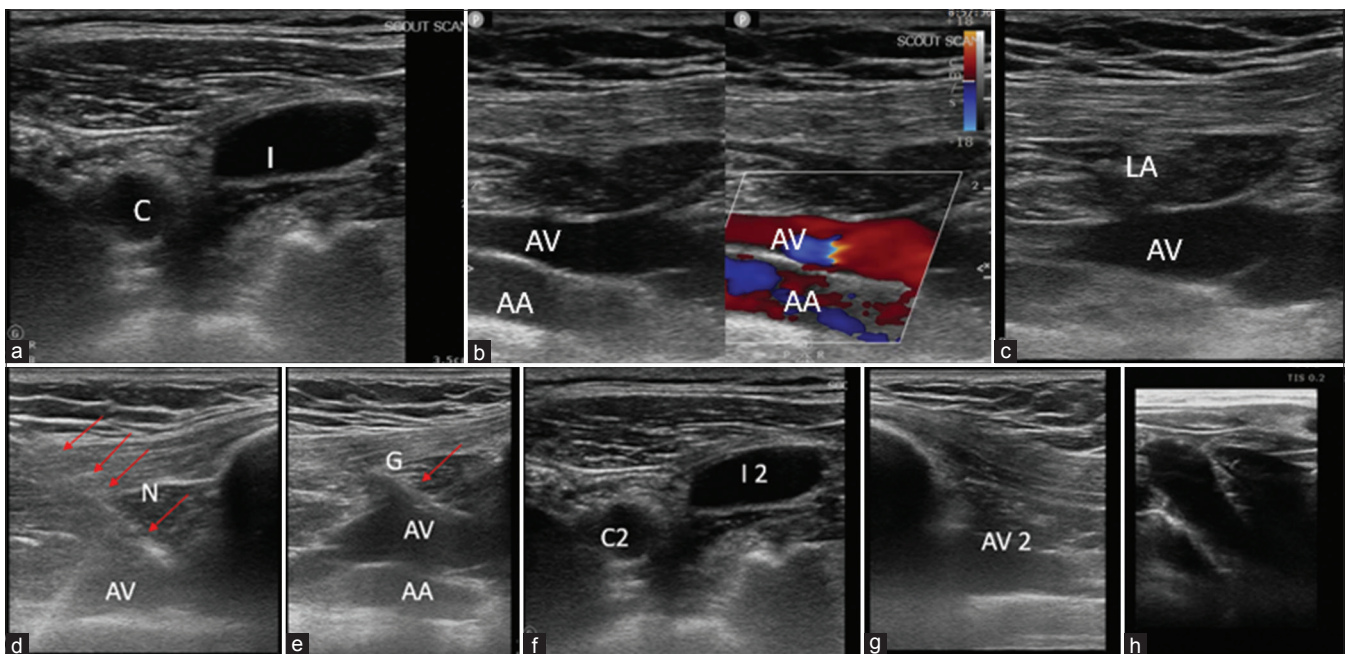


Figure 2: (a) Scout scan of right internal jugular vein. (b) Scout scan of right infraclavicular region. (c) Instillation of local anaesthesia. (d) Needle about to enter the right axillary vein. (e) Guidewire into the right axillary vein. (f) Absence of guidewire in left internal jugular vein confirmed (g) Absence of guidewire in left axillary vein. (h) Guidewire seen passing 'down' into the innominate C- right common carotid artery I- right internal jugular vein AA- right axillary artery axillary vein -right axillary vein LA- Local Anaesthesia G-Guidewire C2- left common carotid I2-Left internal jugular vein axillary vein 2- left axillary vein

a long axis view (in-plane) to reveal the entire length of the needle. After confirming the free aspiration of venous blood, the guide wire was threaded as per the traditional Seldinger technique. The needle was removed, and a final scan was done to assess-

- a. The correct position of the guidewire at the expected site and its absence at other sites
- b. On the supra manubrium scan, attempt to visualize the guidewire going “down” toward the SVC [Figure 2c-2h].

Subsequent dilation and passage of the 4-lumen catheter and free aspiration of blood from all ports were determined. The catheter was fixed at 15 cm and dressing applied.

In patients randomized under Group A-USG-guided IJV -

Under local anesthesia, the puncture of the right IJV was performed with USG using the out of the plane technique.

The following times were noted:

- a. Procedure start time-Sterile probe use started
- b. Access Time-From time of needle puncture to free aspiration of venous blood
- c. Guidewire Time-From needle puncture to smooth passage of guidewire till 20 cm. The guidewire was immediately retracted a couple of cm whenever arrhythmias were encountered.
- d. Needle attempts-Every time the needle enters the skin after exiting was described as an attempt. Four unsuccessful needle attempts were noted as a failure.

In case of failure to secure right IJV– alternative site proposed was left IJV followed by right AV, whereas failure to secure right AV– alternative site used was right IJV followed by left IJV.

During procedure-A note was made of arrhythmias, arterial puncture, patient complaints including pain/paraesthesia and sudden cough.

Intra-operative confirmation – On the transesophageal echo (TEE probe placed after induction of anesthesia)-the tip of the central vein catheter was visualized in the mid-esophageal bicaval view and its relation to the junction of the SVC and the right atrium (*crista terminalis*) was noted in cm.

Intraoperative:

1. Patency of all the four lumens, especially after Sternal retraction
2. Abnormal CVP tracing indicating compression or distortion of the catheter.

Postoperative-A post operative X-ray was done after shifting the patient to the Intensive Care Unit (ICU) for

- a. Confirming the position of the venous catheter in the SVC and the position of the catheter tip within 2 cm of the Right Tracheobronchial angle

- b. Rule out pneumothorax.

A note was made of the functioning of the catheter with regard to ease of aspiration, inadvertent removal, pain, discomfort to the patient, and local site infection.

Post removal-An USG scan was done after 24 h to confirm the patency of the central veins and to rule out any fresh thrombus.

Data were expressed as a mean ± standard deviation. Two sample *t*-test for continuous data and Chi-square analysis for categorical data were used to identify the difference between two groups. A value of $P < 0.05$ was considered statistically significant. Statistical Package for Social Sciences Version 16 (SPSS-16, IBM, Chicago, USA) was used for analysing the data.

Results

A total of 100 adult cardiac surgical patients were randomly allocated to two groups-Real time USG-guided IJV group (Group A) and IC AV group (Group B).

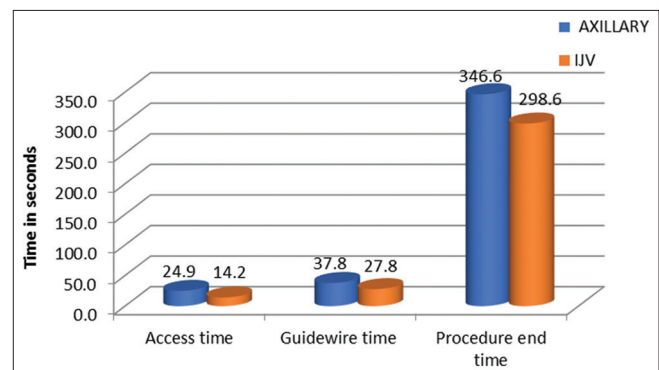
Two patients planned for CABG were excluded from the AV group due to the deeper position of the AV in one and due to guidewire deformation along with the inability to pass the catheter smoothly in another. The analysis of all the technical data was restricted to 48 patients in Group B.

In the IJV group, one patient (redo AVR) had a right IJV thrombus detected during the scout scan was excluded from the study. The Left IJV was cannulated in the first attempt under real-time USG guidance.

The demographic data were comparable between groups in terms of age, sex, height, weight, BMI [Annexure 1].

In both groups, the majority of the surgeries planned for the enrolled patients were coronary artery bypass surgeries [Table 1].

The access time-time taken from the first skin puncture with the needle to aspiration of blood freely was lesser in the IJV group. (14.16 s in Group A and 24.92 s in Group B) P value 0.136, statistically not significant [Graph 1].



Graph 1: Time required for cannulation (seconds)

The guidewire time-time taken from the initial skin puncture to pass a guidewire smoothly till the 20-cm mark was also lesser in the IJV group (27.7 s in Group A and 37.81 s in Group B) [Graph 1].

The procedure time (Time from start of sterile probe use to the completion of the final dressing) was more in the AV group. (298.61 s in Group A as compared to 346.58 s in group B.) *P* values calculated by two-sample *t*-test 0.003 (significant) [Graph 1]. The needle attempts are shown in Table 2. with >95% needing only one needle attempt in Group B as compared to 98% in Group A. Again 94% in Group A and 89% in Group B had successful guidewire insertion in the first attempt [Annexure 2].

Among the complications, one patient in Group A had an inadvertent arterial injury. Only one patient in the AV group complained of paraesthesia, and all other patients in both groups were comfortable. Eighty-one percentage patients had temporary arrhythmias-including atrial ectopics and atrial tachycardias in Group B, whereas only 55% had them in Group A [Table 3]. Guidewire malposition occurred in three patients in Group B and no patient in Group A which is statistically not significant [Annexure 3].

Twenty-two patients in Group A and 26 patients in Group B had an intraoperative TEE. Catheter tip was not visible in 2/22 patients in Group A and 1/26 patients in Group B in whom the TEE was performed.

In 4/49 patients in Group A and in 3/48 patients in the AV group, the catheter tip was detected at a level below the carina on chest X-ray. In the remaining patients, the catheter tip was in the lower SVC and within 2 cm of the right tracheobronchial angle.

Discussion

The complication rate of intravascular cannulations has been shown to be significantly less with the use of US.^[2] Complications such as AV/subclavian arterial puncture, hematomas, pneumothorax, and brachial plexus injury were reduced with the use of US.^[3] The CDC also recommends IC venous access based on its benefits of reduced infection rates and lesser thrombotic complications.^[3] The US-guided real-time IC venous access finds a preference in society recommendations including the American Society of Anesthesiologists.^[8]

In this study, the efficacy of real-time US for cannulation of the AV is compared to the time-tested and highly recommended standard of care^[1] real-time US-guided IJV cannulation in patients undergoing cardiac surgery.

The short axis technique was utilized for the IJV as it was the prevalent technique in our institute. For the AV group, the longitudinal (in-plane method) was chosen as most literature showed it to be superior to the cross-sectional method regarding visualization of the needle trajectory and prevention of complications.^[9,10] A more

Table 1: Distribution of surgical procedures

Surgery	Axillary	IJV
AVR	1 (2.1)	1 (2.0)
CABG	46 (95.8)	45 (91.8)
Minimally invasive CABG	1 (2.1)	1 (2.0)
Minimally invasive AVR	00 (00.0)	1 (2.0)
MVR + TV repair	00 (00.0)	1 (2.0)
Total	48 (100)	49 (100)

P values calculate by Chi-square test 0.704 (not significant). IJV: Internal jugular vein, AVR: Aortic valve replacement, CABG: Coronary artery bypass grafting, MVR: Mitral valve replacement, TV: Tricuspid valve

Table 2: Number of needle attempts

Needle attempts	IJV (Group A)	AV (Group B)
1	48 (98.0)	46 (95.8)
2	1 (2.00)	00 (00.0)
3	00 (00.0)	2 (4.2)
Total	49 (100)	48 (100)

P values calculated by Chi-Square test 0.217 (not significant). IJV: Internal jugular vein

Table 3: Complications chart

Complications	IJV group	AV group	<i>P</i>
1. Paraesthesia	0/49	1/48	0.305
2. Arrhythmias	27/49	39/48	0.004
3. Artery puncture	1/49	0/48	0.325
4. Hematoma	0/49	0/48	-
5. Site conversion	0/49	0/48	-
6. GW malposition	0/49	3/48	0.073
7. Pain	2/49	5/48	0.218
8. Pneumothorax	0/49	0/48	-
9. Loss of CVP trace and inability to aspirate distal lumen	0/49	2/48	0.149

GW: Guidewire, CVP: Central venous pressure, IJV: Internal jugular vein, AV: Arteriovenous

recent comparative study by Maddali *et al.* however found that the cross-sectional method to be effective for the AV.^[11]

In the present study, the access time was 24.9 s in the AV group in comparison to 14 s in the IJV group (*P* = 0.103). The minimum time in both groups was around 7 s. The mean access time in the AV group was similar to that described by Fragou *et al.* (26.8 ± 12.5 (16.4–39.2) in their study in 200 ICU patients on a ventilator.^[12]

A 4-cm depth at the proposed site of venous puncture was a predetermined cutoff for the AV was used to define a “deep” location at the time of the scout scan, and a site change was necessitated in one patient in Group B. The patient was successfully cannulated in a single attempt by the US-guided IJV method.

The AV is a deeper vein, and a higher rate of complications was revealed whenever multiple needle attempts were

made.^[2] About 95% of the patients in the AV group required only one needle attempt in comparison to 98% in the IJV group. The first attempt success rates vary among studies and ranges from 85% as in the study in 200 mechanically ventilated critically ill patients under emergency and non-emergency conditions by Czarnik *et al.* and around 75% in his study in AV cannulation for renal replacement therapy.^[5,13] O'Leary *et al.* showed a high first pass success of 95% in their retrospective analysis of 2500 patients over diverse indications.^[6] In the present study, two patients in the AV group required three needle attempts. Both patients had a depth of 3.3 cm while the average depth of the AV at the site of desired needle puncture was 2.5 cm.

Pittiruti *et al.* showed that arm abduction and forward rotation of the shoulder increases the diameter of the AV and may help in the cannulation.^[14] In the present study, the right arm was already extended for securing the right radial artery and maintained as such in Group B and this in combination with the posterior scapular roll may have had a similar effect on the AV. All cannulations were performed in spontaneously breathing patients under mild sedation. Any inadvertent needle contact with the brachial plexus could, therefore, be immediately identified. We observed that there is collapse in the AV in direct proportion to the patient's inspiratory efforts but the medial most of the AV is always held open by the surrounding fascia. In the present study, a more medial puncture site over the vein was selected which helps to avoid the brachial plexus and also presents a more distended part of the AV.

The guidewire course for the IJV is a relatively straight one and for the AV significantly curved with more malpositions. A protocolized US approach such as used in the present study assists in revealing the normal anatomy of all the vascular structures and the depth through a pilot scan. Subsequently, the US reveals the guidewire in the chosen vein as well as its course down the innominate. The absence of guidewire in an undesirable location (for instance-absence of the guidewire in the IJV while the AV guidewire is screened for is reassuring) was also noted. In the present study, the IJV guidewire was passed to the correct location in all the cases. In the AV group, there were three instances of the guidewire visualized in the Right IJV. They were withdrawn carefully under USG guidance and rerouted into the SVC [Annexure 4]. The guidewire passing down the innominate vein was revealed in 70% of the patients in Group B, and 60% in Group A. Catheter misplacement was around 9.5% in the US-guided IC access study by Fragou *et al.*^[12]

Eight-one percentage of the patients in the AV group had atrial ectopics while the guidewire was being passed and was taken as an indication of the correct course of the guidewire. No patient with guidewire malposition had ectopics. In comparison, only 54% in the IJV group had atrial ectopics.

The procedural time was 320 s (216–660 s) in Group B in comparison to 300 s (195–453 s) in the IJV group. ($P = 0.003$ statistically significant). Additional time is required in preparation of the US probes (not measured in this study but important that close attention is paid to this step to minimize infection risks) and serial scanning of the various sites once the guide wire in place. The authors believe that with routine use the timings will be similar to the IJV cannulations.

Difficulty in passing the catheter occurred in three patients in the AV group. Two of them required the tissue dilation twice with the same dilator before the catheter could be passed smoothly. In the third patient, there were multiple guidewire attempts following a needle puncture in the first attempt followed by difficulty in passing the catheter and patient discomfort. The site was changed, and a US-guided IJV catheter was passed in the first attempt. The authors recommend that great care be taken while dilating over the guidewire during the AV cannulation due to a thick chest wall and a possible acute angle of entry. O'Leary *et al.* commented in their landmark study that the AV cannulation is technically more difficult than the IJV route and also with the US and practice it could well be a suitable alternative to the IJV.^[6] The in-plane technique allows a less acute angle for the needle and subsequent guidewire entrance into the AV. The recommendation of confirming ability to move the guidewire with small to and fro movements during various stages of dilation should be strictly adhered to during the AV cannulation.

Neither axillary artery puncture or injury nor brachial plexus injury was encountered. In one case in Group A, an arterial puncture was encountered which was managed with pressure. The IJV was secured in the second attempt without any further complications.

Conventionally, more mechanical complications are expected during the landmark-based or US based IC AV access. Fragou *et al.* in their study reported only one arterial puncture and three hematomas out of 200 patients with the US approach for subclavian vein and no phrenic nerve injury or pneumothorax. Our study shows similarly low complications rate. In the recent study by Maddali *et al.* overall AV artery puncture was seen in four out of 43 patients using the same technique that was used in our study.^[11] In this large analysis of US-guided central venous access, including 1644 cases of right AV venous and 279 cases of left AV cannulation where US-guided AV venous cannulation was performed for tunneled catheters, O'Leary *et al.* showed only 8 cases of axillary arterial injury (0.4%) and only three cases of pneumothorax.^[6] In the same study, the incidence of arterial puncture during IJV cannulation was 11/636 patients with an incidence of 1.72%.

In our study, no patient in either group had pneumothorax as evidenced by postoperative X-ray. Approximately, 80% of the patients in each group could be subjected to a post-removal US scan 24 h after the removal of the catheter. No patient revealed any significant hematomas, thrombosis, or vascular narrowing.

Loss of CVP trace and inability to aspirate was encountered in two patients in group B after sternal retraction for the internal mammary harvest and sternal retraction. This phenomenon was reversed on removal of the retraction.

Limitations of the study – Our study has a few limitations.

1. Study was done in small number of patients in a single centre
2. Only the acute complications were studied. Long-term problem such as stenosis, thrombotic problems and central venous catheter-related infections not studied
3. A real-time intra atrial ECG derived by attaching an appropriate sterile lead assembly to the guidewire while the introduction of the catheter would have definitely helped in a more appropriate “real-time” confirmation of the catheter position in the SVC^[15]
4. A lung scan can be easily performed prior to and after the procedure to help detect pneumothorax was not consistently performed in all patients in this study

Conclusion

This study reveals the efficacy of the real-time US cannulation of the AV as an alternative to the IJV in cardiac surgical patients, especially when conditions such as IJV thrombus preclude its safe use. Limitations of the AV cannulation exist such as catheter malposition, risk of axillary artery injury, pneumothorax, and difficulty in threading the catheter. This study reveals that these limitations could be successfully circumvented to a great extent by an US-based protocol. The authors hope that increased application of this technique in future will encourage its use in other intraoperative clinical areas.

Financial support and sponsorship

Nil.

Conflicts of interest

There are no conflicts of interest.

References

1. Augoustides JG, Cheung AT. Pro: Ultrasound should be the standard of care for central catheter insertion. *J Cardiothorac Vasc Anesth* 2009;23:720-4.
2. Weiner MM, Geldard P, Mitnacht AJ. Ultrasound-guided vascular access: A comprehensive review. *J Cardiothorac Vasc Anesth* 2013;27:345-60.
3. O’Grady NP, Alexander M, Burns LA, Dellinger EP, Garland J, Heard SO, *et al.* Guidelines for the prevention of intravascular catheter-related infections. *Am J Infect Control* 2011;39:S1-34.
4. Galloway S, Bodenham A. Ultrasound imaging of the axillary vein – Anatomical basis for central venous access. *Br J Anaesth* 2003;90:589-95.
5. Czarnik T, Gawda R, Nowotarski J. Real-time ultrasound-guided infraclavicular axillary vein cannulation: A prospective study in mechanically ventilated critically ill patients. *J Crit Care* 2016;33:32-7.
6. O’Leary R, Ahmed SM, McLure H, Oram J, Mallick A, Bhambra B, *et al.* Ultrasound-guided infraclavicular axillary vein cannulation: A useful alternative to the internal jugular vein. *Br J Anaesth* 2012;109:762-8.
7. Milling TJ Jr, Rose J, Briggs WM, Birkhahn R, Gaeta TJ, Bove JJ, *et al.* Randomized, controlled clinical trial of point-of-care limited ultrasonography assistance of central venous cannulation: The third sonography outcomes assessment program (SOAP-3) trial. *Crit Care Med* 2005;33:1764-9.
8. American Society of Anesthesiologists Task Force on Central Venous Access, Rupp SM, Apfelbaum JL, Blitt C, Caplan RA, Connis RT, *et al.* Practice guidelines for central venous access: A report by the American society of anesthesiologists task force on central venous access. *Anesthesiology* 2012;116:539-73.
9. Sommerkamp SK, Romaniuk VM, Witting MD, Ford DR, Allison MG, Euerle BD, *et al.* A comparison of longitudinal and transverse approaches to ultrasound-guided axillary vein cannulation. *Am J Emerg Med* 2013;31:478-81.
10. He YZ, Zhong M, Wu W, Song JQ, Zhu DM. A comparison of longitudinal and transverse approaches to ultrasound-guided axillary vein cannulation by experienced operators. *J Thorac Dis* 2017;9:1133-9.
11. Maddali MM, Arora NR, Chatterjee N. Ultrasound guided out-of-plane versus in-plane transpectoral left axillary vein cannulation. *J Cardiothorac Vasc Anesth* 2017;31:1707-12.
12. Fragou M, Gravvanis A, Dimitriou V, Papalois A, Kouraklis G, Karabinis A, *et al.* Real-time ultrasound-guided subclavian vein cannulation versus the landmark method in critical care patients: A prospective randomized study. *Crit Care Med* 2011;39:1607-12.
13. Czarnik T, Gawda R, Nowotarski J. Real-time, ultrasound-guided infraclavicular axillary vein cannulation for renal replacement therapy in the critical care unit – A prospective intervention study. *J Crit Care* 2015;30:624-8.
14. Pittiruti M, Biasucci DG, La Greca A, Piza A, Scoppettuolo G. How to make the axillary vein larger? Effect of 90° abduction of the arm to facilitate ultrasound-guided axillary vein puncture. *J Crit Care* 2016;33:38-41.
15. Ender J, Erdoes G, Krohmer E, Olthoff D, Mukherjee C. Transesophageal echocardiography for verification of the position of the electrocardiographically-placed central venous catheter. *J Cardiothorac Vasc Anesth* 2009;23:457-61.

Annexure

Annexure 1

Table 1: Age

Age	Mean	SD	Median	Minimum	Maximum
AXILLARY	60.75	9.70	61.50	25.00	76.00
IJV	61.90	8.30	62.00	43.00	75.00

P values calculate by two-sample *t*-test 0.533 (not significant).
IJV: Internal jugular vein, SD: Standard deviation

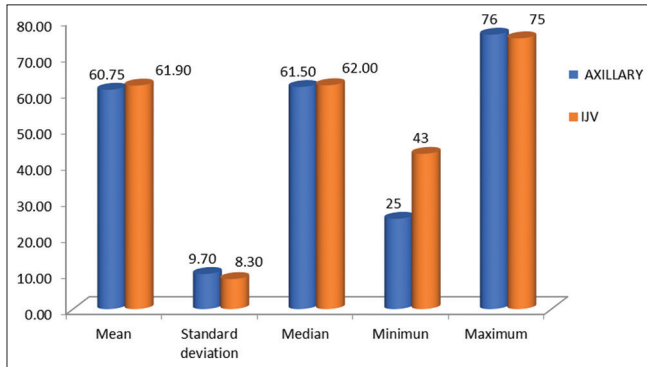


Figure 1: Age

Table 2: Sex

Sex	Axillary	IJV
Female	6 (12.5)	9 (18.4)
Male	42 (87.5)	40 (81.6)
Total	48 (100)	49 (100)

P Values calculate by Chi-Square test 0.315 (not significant).
IJV: Internal jugular vein

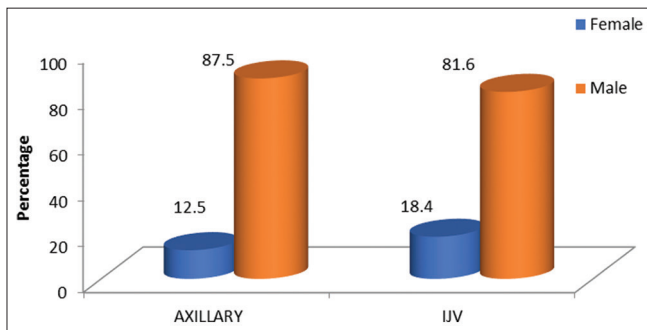


Figure 2: Sex

Table 3: Height (cm)

Height (cm)	Mean	SD	Median	Minimum	Maximum
Axillary	163.04	4.75	164.50	155	174
IJV	162.02	5.15	163.00	147	169

P values calculate by two-sample *t*-Test 0.312 (not significant).
SD: Standard deviation, IJV: Internal jugular vein

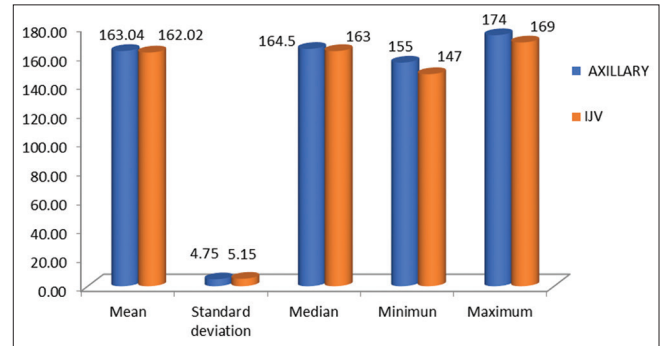


Figure 3: Height (cm)

Table 4: Weight (kg)

Weight (kg)	Mean	SD	Median	Minimum	Maximum
Axillary	65.99	7.15	66.00	52	92.90
IJV	67.20	10.24	67.00	41	90.00

P values calculate by two-sample *t*-test 0.502 (not significant).
SD: Standard deviation, IJV: Internal jugular vein

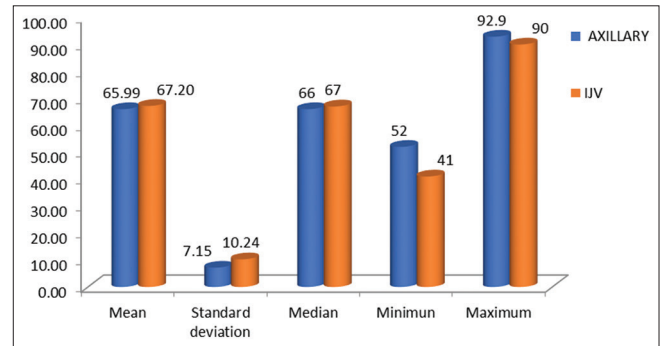


Figure 4: Weight (kg)

Table 5: BMI

BMI	Mean	SD	Median	Minimum	Maximum
Axillary	24.84	2.41	25.00	19.40	32.80
IJV	25.57	3.55	25.40	16.60	33.80

P values calculated by two-sample *t*-test 0.238 (not significant).
SD: Standard deviation, BMI: Body mass index, IJV: Internal jugular vein

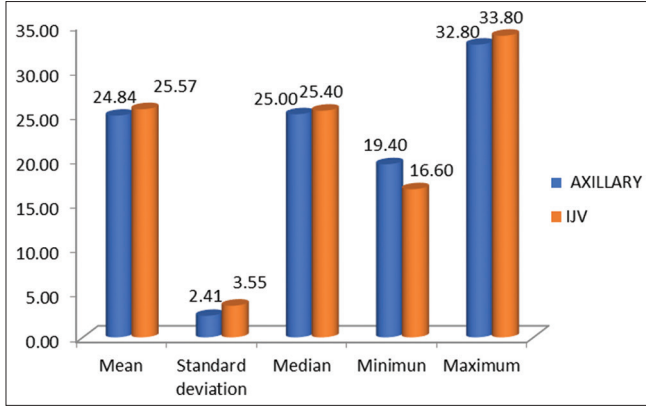


Figure 5: BMI

Annexure 2

Table 1: Guidewire attempts

Guidewire attempts	Axillary	IJV
1	43 (89.6)	46 (93.9)
2	3 (6.3)	3 (6.1)
3	2 (4.2)	00 (00.0)
Total	48 (100)	49 (100)

P values calculate by Chi-Square test 0.343 (not significant).
IJV: Internal jugular vein

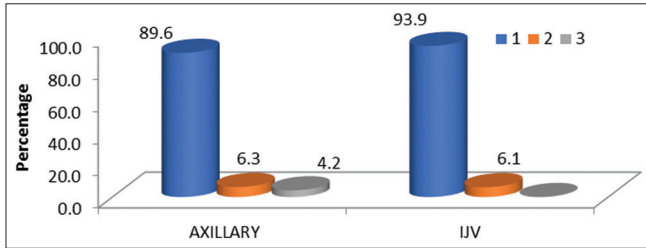


Figure 1: Guidewire attempts

Table 6: Surgery

Surgery	Axillary	IJV
AVR	1 (2.1)	1 (2.0)
CABG	46 (95.8)	45 (91.8)
MICAS	1 (2.1)	1 (2.0)
Minimally invasive AVR	00 (00.0)	1 (2.0)
MVR + TV repair	00 (00.0)	1 (2.0)
Total	48 (100)	49 (100)

P values calculate by Chi-Square test 0.704 (not significant).
IJV: Internal jugular vein, AVR: Aortic valve replacement, CABG: Coronary artery bypass grafting, MVR: Mitral valve replacement, TV: Tricuspid valve, MICAS: Minimally Invasive Coronary Artery Surgery

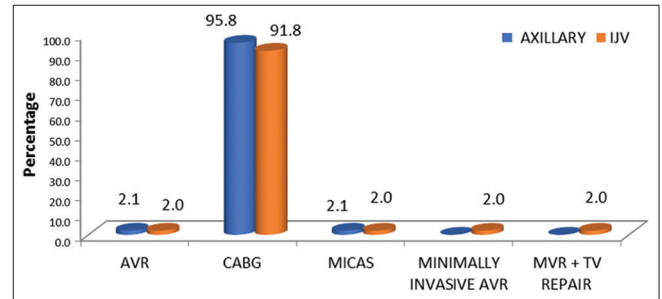


Figure 6: Surgery

Annexure 3

Table 1: Paraesthesia

Paraesthesia	Axillary	IJV
Yes	1 (2.1)	00 (00.0)
No	47 (97.9)	49 (100)
Total	48 (100)	49 (100)

P values calculate by Chi-Square test 0.305 (not significant).
IJV: Internal jugular vein

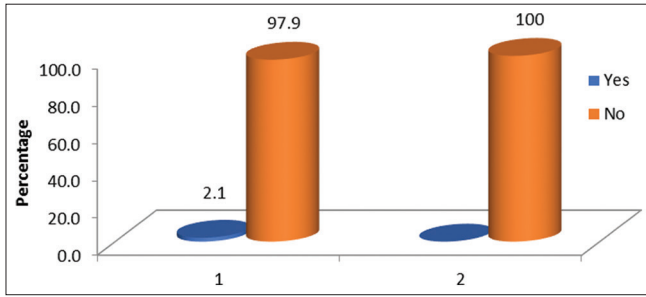


Figure 1: Paraesthesia

Table 2: Arrythmia

Arrythmia	Axillary	IJV
Yes	39 (81.3)	27 (55.1)
No	9 (18.8)	22 (44.9)
Total	48 (100)	49 (100)

P values calculate by Chi-Square test 0.004 (significant).
IJV: Internal jugular vein

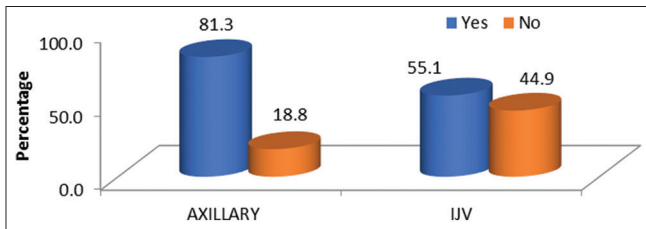


Figure 2: Arrythmia

Table 3: Artery puncture

Artery puncture	Axillary	IJV
Yes	00 (00.0)	1 (2.0)
No	48 (100)	48 (98.0)
Total	48 (100)	49 (100)

P values calculate by Chi-Square test 0.325 (not significant).
IJV: Internal jugular vein

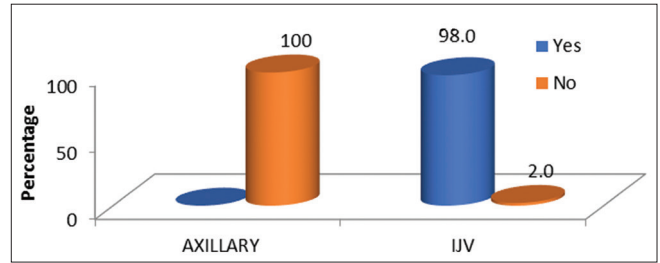


Figure 3: Artery puncture

Table 4: Hematoma

Hematoma	Axillary	IJV
No	48 (100)	49 (100)
Total	48 (100)	49 (100)

IJV: Internal jugular vein

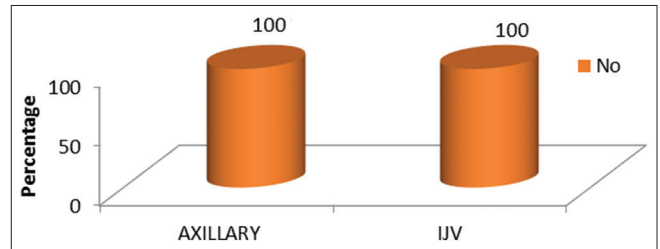


Figure 4: Hematoma

Table 5: Site conversion

Site conversion	Axillary	IJV
No	48 (100)	49 (100)
Total	48 (100)	49 (100)

IVJ: Internal jugular vein

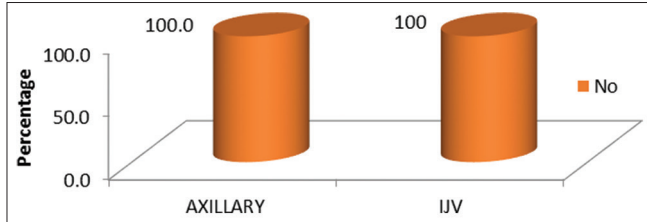


Figure 5: Site conversion

Table 6: Guidewire malposition

Guidewire malposition	Axillary	IJV
Yes	3 (6.2)	00 (00.0)
No	45 (93.8)	49 (100)
Total	48 (100)	49 (100)

P values calculate by Chi-Square test 0.073 (not significant).

IVJ: Internal jugular vein

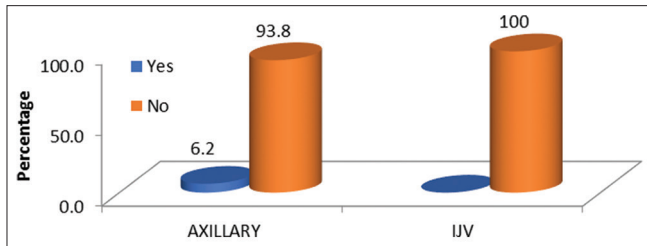


Figure 6: Guidewire malposition

Annexure 4

Table 1: Attempts to correct guidewire

Attempts to correct guidewire	Axillary	IJV
1	1 (2.1)	00 (00.0)
2	1 (2.1)	00 (00.0)
3	1 (2.1)	00 (00.0)
No	45 (93.8)	49 (100)
Total	48 (100)	49 (100)

P values calculate by Chi-Square test 0.358 (not significant).

IVJ: Internal jugular vein

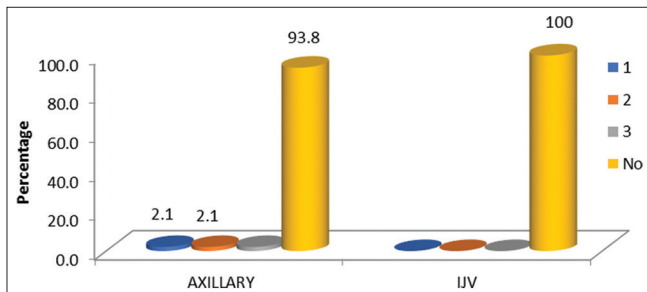


Figure 1: Attempts to correct guidewire

Table 7: Pain during procedure

Pain	Axillary	IJV
MILD	5 (10.4)	2 (4.1)
NO	43 (89.6)	47 (95.9)
Total	48 (100)	50 (100)

P values calculate by Chi-Square test 0.218 (not significant).

IVJ: Internal jugular vein

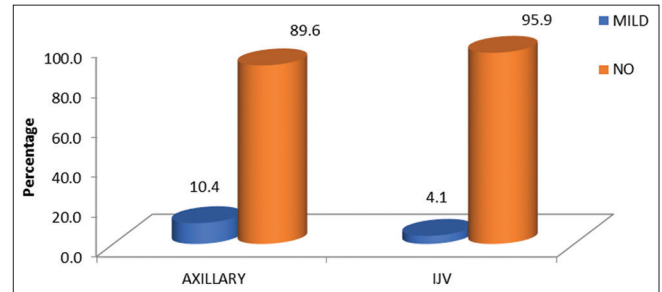


Figure 7: Pain during procedure

Table 8: Postoperative chest X-ray

Chest X-ray	Axillary	IJV
No pneumo	48 (100)	49 (100)
Total	48 (100)	49 (100)

IVJ: Internal jugular vein

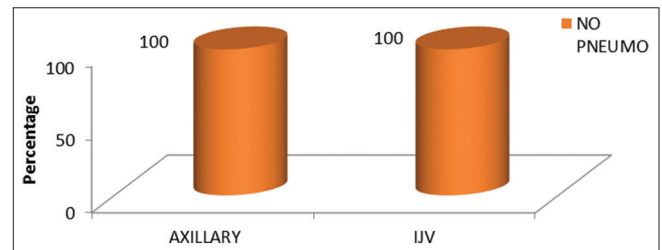


Figure 8: Postoperative chest X-ray