

Prospective study of treatment outcome of implant retained mandibular overdenture: Two years follow-up

VIMAL ARORA, DINESH KUMAR¹, V. S. LEGHA¹, K. V. ARUN KUMAR¹

Abstract

Aims: The aim of this study is to evaluate the treatment outcome of immediately loaded Implants in the interforaminal region of anterior mandible. **Materials and Methods:** A total of 15 completely edentulous patients aged between 50 and 70 years were selected satisfying certain inclusion and exclusion criteria. Two implants were placed in 33 and 43 region (B and D location) and the implants were loaded immediately by mandibular overdenture retained with O-ring attachments. The implants were evaluated for various clinical parameters at 6 months, 1 year, 1.5 years, and 2 years intervals after initial placement. **Results:** There was increased marginal bone loss around implants during the 1st year after that the bone loss was insignificant. Clinical stability of immediately loaded implants was lower initially for 6 months, but improved by the end of 1st year. Survival rate for immediately loaded implants was 96.6% at the end of the period of study. **Conclusion:** Immediate loading of interforaminal mandibular implants demonstrated a highly acceptable clinical success at the end of 2 years. However, initially the marginal bone level and clinical stability were significantly lower which showed improvement with time.

Keywords: Immediate loading, mandibular overdenture, marginal bone, O-ring attachment, periosteal

Introduction

Complete dentures are the most conventional artificial substitutes for missing teeth and adjacent soft tissue and they must replace the form of the living tissues as nearly as possible and function in harmony with the surrounding tissues. Despite following all the biomechanical principles in fabrication, mandibular complete denture has remained a challenge. This is because of form and nature of the basal bone, tongue and its size, form and activity and high muscular attachments, which further complicates the rehabilitation with mandibular denture.

Implant supported mandibular overdenture has been successfully used to overcome the inherent problems of mandibular complete denture.^[1] The primary indication for

a mandibular overdenture are problems often found with mandibular complete denture, such as lack of retention and stability, difficulty in chewing and speech, tissue sensitivity, and tissue abrasions.

Minimal bone resorption of the anterior ridge occurs in implant supported overdentures. The bone under an overdenture may resorb as little as 0.6 mm vertically over 5 years and long term bone resorption may remain <0.1 mm/year.^[2,3] Implant supported overdenture provides the stability to mandibular denture and reduces the horizontal movement of the prosthesis.^[4]

Fabrication of implant supported overdenture and immediately loading the implants with the denture has been gaining momentum for the last 15 years. This concept of immediately loading the implants not only provides all the advantages of one-stage surgical technique, but also decreases the risk of overload because of increased surface area and improved biomechanical retention. Various authors have reported that immediate loaded implants are capable to osseointegrate, even though they are exposed to the oral environment by extending above the bone and soft tissues during early bone remodeling. In addition, it eliminates the second stage surgery and aids in immediate prosthetic rehabilitation of the patient. Several studies have demonstrated that immediate loading of a complete mandibular overdenture supported by four implants connected with a bar results in implant survival rates that are comparable to those obtained following a delayed approach.^[5]

Recently, it has been advocated that immediate loading of two implants with a mandibular overdenture retained with O-ring attachments has shown favorable results. However, only a few

Prof and HOD, ADC R and R, Delhi cantt affiliated to Delhi University, ¹Department of Dental Surgery, Division of Prosthodontics, AFMC, Pune, Maharashtra, India

Correspondence: Col Dr. Dinesh Kumar,
Department of Dental Surgery, Division of Prosthodontics,
AFMC, Pune, Maharashtra, India.
E-mail: drdineshsaini@yahoo.co.in

Access this article online	
Quick Response Code: 	Website: www.contempclindent.org
	DOI: 10.4103/0976-237X.132304

articles have been reported on the treatment outcome of this modality.^[6,7] Marzola *et al.*^[6] evaluated the performance of two immediately loaded implants with mandibular overdenture retained with O-ring and found marginal bone loss of 0.7 mm in a period of 1 year. Cooper *et al.* in a similar study found 96% success rate in 5 years prospective study and marginal bone loss 0.13 mm in 1 year.

The aim of this study 2 year study was to evaluate the implant success rate and treatment outcome of immediately loaded implant supported mandibular overdenture retained with two O-ring attachments.

Materials and Methods

Patient selection

Fifteen completely edentulous adults with a mean age of 60 years (range 50-70 years) were included in the study. To be included in the study, patients had to be edentulous in both the arches with class I ridge relation and patients needed to have sufficient bone volume to allow for the implant placement of the size of 3.3 mm × 13 mm Equinox snap implants in the mandible in B and D position. Patients with history of systemic diseases like diabetes, bone diseases and patients with history of head and neck radiations were excluded from the study. Patients were rehabilitated with two implants placed in mandible symphysis region in B and D position and immediately loaded with mandibular overdenture using O-ring attachment as retentive mechanism against maxillary complete denture.

Clinical procedure

After case selection, new maxillary and mandibular complete denture were fabricated for each patient before implant surgery. Lingualized balanced occlusion was selected for all prosthesis. The mandibular denture was duplicated in acrylic resin. Two steel balls were placed in the B and D location in acrylic template. Orthopantomogram (OPG) was taken for each patient with the acrylic template in place to determine the bone quality and vital structures [Figure 1]. This template was used as the surgical template also for placement of implants.

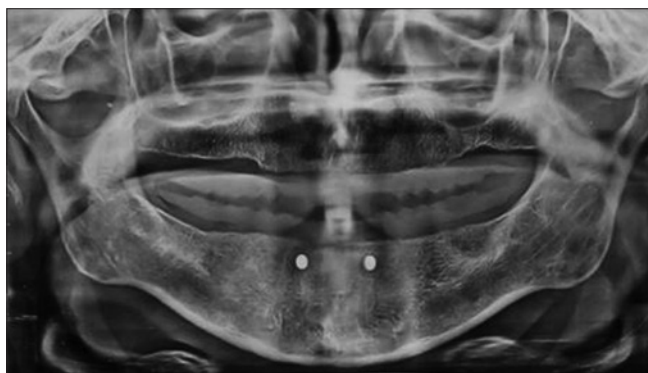


Figure 1: Orthopantomogram showing steel balls in B and D location

Single piece implants were placed following the standard surgical protocols under local anesthesia. Full-thickness flap was raised in B and D position of the implant. The sharp bony spicules were removed in some cases. The implants (Equinox Myriad snap) were placed in B and D location for each patient following the standard surgical technique using template [Figure 2]. Postoperative OPG was done for each patient after implant placement [Figure 3]. The O-ring attachments were placed on the implants. The intaglio surface of the denture was trimmed to make space for attachment. The mandibular denture was placed into patient mouth and occlusion was verified. A window was created above the attachments and the attachment was picked up into the mandibular denture by adding small increments of self-cure acrylic resin. Intaglio surface of the mandibular denture was finished [Figure 4]. Patient was delivered maxillary complete denture and mandibular implant supported mandibular overdenture on the same day [Figure 5].

Postoperative antibiotics and analgesics were prescribed. Chlorhexidine mouthwash was given to each patient and advised to use 2 times a day for 15 days. The patients were advised only nocturnal removal of dentures to reduce the unwanted forces on implants for 1 month. Oral hygiene instructions were given and each patient was kept on a liquid diet for initial 15 days. Followup was done after 1 week, 15 days, and 1 month for any postsurgical pain or swelling or post insertion complaints related to overdenture.

Data collection and analysis

All clinical examination and data collections were done by one clinician. The patients were recalled at an interval of 6 months for 2 years. Marginal bone loss, implant mobility, and implant survival rate were studied.

Marginal bone loss

The intra oral periapical (IOPA) X-ray was taken at the time of implant placement with grid using the long cone parallel technique at the time of implant placement, at 6 months, at 1 year, 1.5 year, and at 2 years. For this

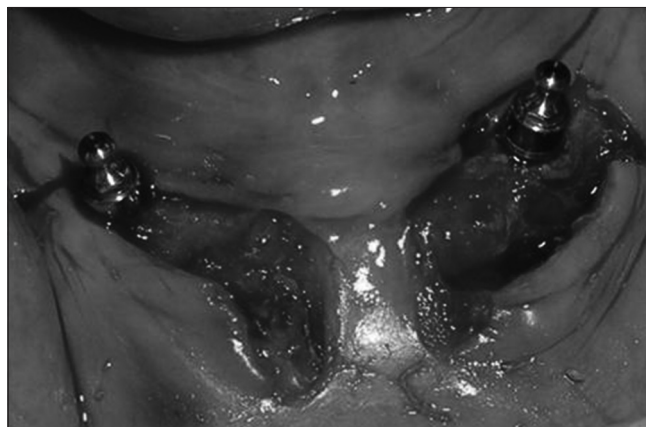


Figure 2: Surgical placement of implants

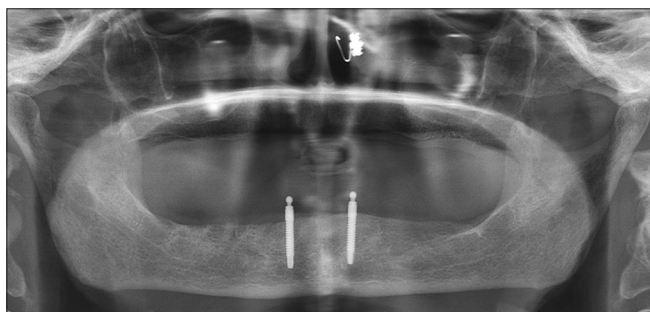


Figure 3: Postoperative orthopantomogram showing two implants in B and D location

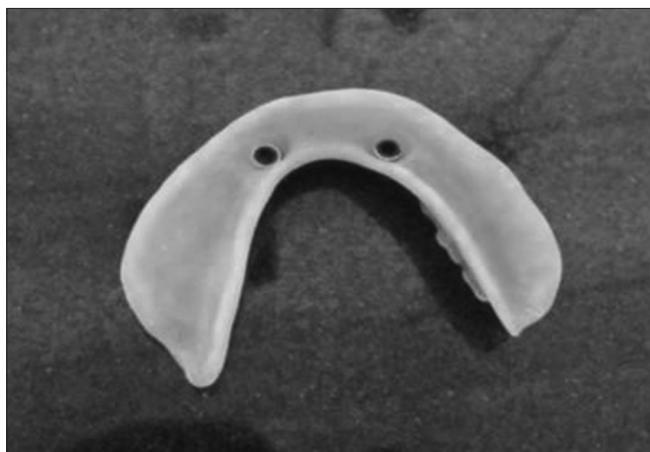

Figure 4: O-ring attachment in intaglio surface of denture

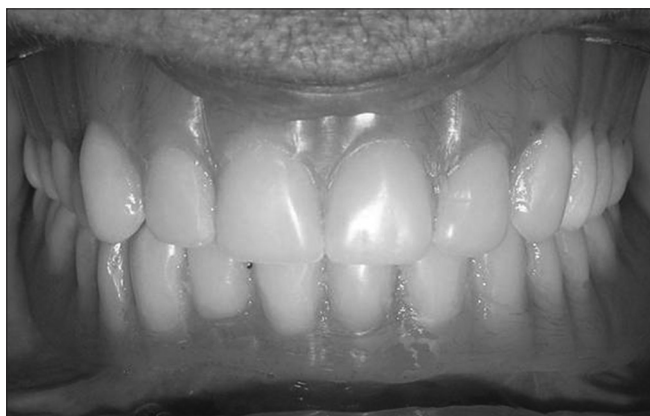

Figure 5: Complete dentures inserted and occlusion adjusted

technique radiographic grid (indirect digital mammography, Japan) along with periapical film (Kodak, Germany) was held parallel to the long axis of the implant using the film-holding instrument. The central ray was directed to pass at a perpendicular angle to both the implant and the film. Exposures, developing and fixing was done by one operator under standardized protocols. It was ensured that each radiograph showed an undistorted view of the featured implant with enough of surrounding bone around the implants. A computer loaded with Corel DRAW™ 11 software from Corel Corporation was used to analyze the

radiographs. The IOPA radiographs were transferred to the computer, enlarged to actual size (known actual implant dimensions). Linear distance was measured from first bone to implant contact to the implant shoulder on the mesial and distal sides of the implant.^[8]

Implant mobility

The implant mobility was measured with the help of periostest^[9,10] at baseline, 6 month, 1 year, 1.5 years, and 2 years. The periostest (Medizintechnik Gulden) uses an electromagnetically driven and electronically controlled tapping metallic rod in a handpiece. Response to striking was measured by a small accelerometer incorporated into the head. Contact time between the test object and tapping rod was measured on the time axis as a signal for analysis. The signals are then converted to a unique value called the periostest value (PTV). After three tapings, the mobility of the implants was evaluated at baseline, 6 months, 1 year, 1.5 years, and 2 years. The handpiece was held horizontally at right angles to the long axis of the implant. The smaller values reflected greater stability. Interpretations of the PTVs were based on the manufacturer's instructions. Three measurements were made at each appointment and most frequently recorded reading was used in data analysis.

Implant survival rate

It was evaluated at each appointment according to the criteria proposed by Smith and Zarb.^[11] The implant was considered a failure when there was periimplant radiolucency noted on the IOPA X-ray, clinical mobility of the implant, pain, or discomfort.

Results

This study was taken up to evaluate the treatment outcomes of completely edentulous patients rehabilitated with immediately loaded implant supported mandibular overdenture retained by two O-ring attachments. Evaluation of the three clinical parameters was carried out at baseline, 6 month, 1 year, 1.5 years, and 2 years. The results were drawn taking into consideration the three quoted parameters: Marginal bone loss, implant mobility and implant survival rate. All the data obtained were tabulated and statistically analyzed as shown in Tables 1-3.

Table 1 shows the results of marginal bone loss with respect to different periods. The base line mean marginal bone loss was significantly different statistically from the mean marginal bone loss at the end of 6 month, 1 year, 1.5 years, and 2 years.

Table 2 depicts descriptive statistics of mobility in relation to O-ring attachments and reflects mean mobility of implants over the period of study. In each case, it was seen that the mean mobility values decreased with an increase in the observation period. Chart 1 reflects the same statistics.

Table 1: Marginal bone level (mm)

	Marginal bone level				
	Base line	6 months	1 year	1.5 years	2 years
Minimum	1.1	1.5	1.2	0.6	0.05
Maximum	2.1	2.21	1.51	1.1	0.41
Mean	1.7	1.98	1.33	0.88	0.16
Standard deviation	0.38232	0.36159	0.11937	0.14851	0.13509

Table 2: Implant mobility (PTV)

	Clinical stability (PTV)				
	Base line	6 months	1 year	1.5 years	2 years
Minimum	-4.1	-3.4	-3.9	-3.4	-3.9
Maximum	-1.1	-2.4	-1.7	-1.4	-1.9
Mean	-2.5	-3.3	-3.4	-3.6	-3.7
Standard deviation	0.69421	0.817	0.695	0.686	0.536

PTV: Periotest value

Table 3: Survival rate

Time	Cumulative implant success rate		
	Number of patients	Number of implants	Success rate %
6 months	15	30	100
1 year	15	30	100
1.5 years	15	30	100
2 years	15	29	96.6

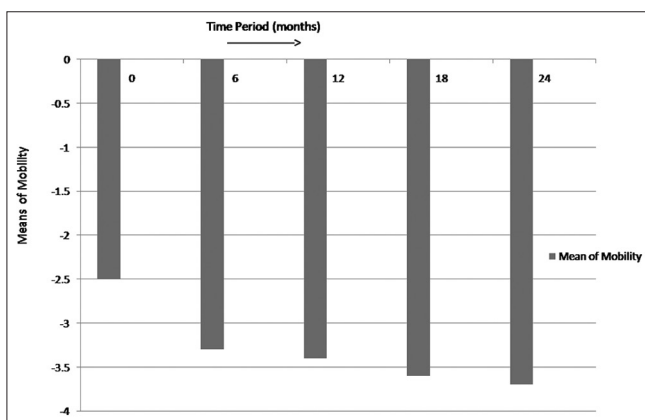


Chart 1: Mean mobility by period

Table 3 depicts the results of implant survival rate. A total of 15 edentulous patients were rehabilitated with implant supported mandibular overdentures retained with O-ring attachments. There was one failure, in which implant showed radiolucency after 1.5 years and patient complaint of continuous pain; therefore, implant was removed and the patient was excluded from the study. A total of 29 implants

survived in 15 patients during the course of study. The implant survival rate was 96.6%.

Discussion

The immediate loading concept challenges the conventional healing time of 3-6 months where the prosthesis is loaded on the day of implant surgery. Immediate loading of dental implants was first proposed by Ledermann in the year 1979. Since then numerous clinical studies have proved that immediate loading in completely edentulous patients is a reality and has more than 90% survival rate.^[12] Various attachment systems have been used in implant supported overdenture such as ball, locator, magnets, bar and clips and precision attachments to augment retention and stability.

For this study, Equinox Snap implants (Equinox Medical technologies, The Netherlands) were used. The specification of the implant include 1 mm implant collar with calcium oxidized nanoporous surface that feature three-dimensional interconnecting porosities which not only the increases initial stability, but also shortens healing period to facilitate immediate loading. Two implants were placed in the interforamina region as the greatest available height of bone is located in the anterior mandible. This region also presents optimal density of bone for implant support. Parallelism between adjacent implants was ensured during surgical placement. Absolute parallelism was ensured during osteotomy with paralleling pins and intermediate radiographs using radio visual graph.

Assessment of marginal bone level

Intra oral periapical radiographs were taken using the long cone paralleling technique and assessed at the time of implant placement, at 1, 3, 6, and 9 months. Transparent radio-opaque grid was superimposed on the IOPA film and exposures, developing and fixing was done by the same operator under standardized protocols. There were no significant differences in the marginal bone level between the early loaded implants at different time intervals by IOPA X-ray with grid. Statistical differences were noted at 1 year, 1.5 year, and 2 years. Adell *et al.*^[8] have reported marginal bone loss in their 15 year study of osseointegrated implants in the edentulous mandible. The study indicated greater magnitude and occurrence of bone loss during the 1st year of prosthesis loading, averaging 1.2 mm with a range of 0-3 mm. The results of this study are similar to the study conducted by us. Weber HP, Buser D, Donath K, Fiorellini^[13] demonstrated that in one stage implants, a large percentage of initial bone loss occurred during the 1st months, whereas in two-stage implants 40% of initial bone resorption was found after re-entry. This study compares and evaluates the mean marginal bone level on the mesial and distal surface of immediately loaded implants over a period of 2 years. Based on the results obtained, it can be concluded that the mean marginal bone loss around early loaded implants was

1.08 mm over a period of 2 years similar to other studies of two free standing implants to retain immediate mandibular overdenture rehabilitated immediately.^[6,7]

Assessment of clinical stability using periotest

Implant stability, an indirect indication of osseointegration, is a measure of the clinical immobility of an implant. Periotest has been thoroughly studied and advocated as a reliable method to determine implant stability.^[14] Schulte and Lukas^[9] have described the detail procedure for how to use the periotest in implant dentistry.

This study compared the PTVs for immediate loaded implants at every 6 months for a period of 2 years. At 6 months and 1 year there were no statistical significant differences between the two groups; however, significant differences were noted between the two groups at 1.5 and 2 years indicating better stability with the immediately loaded implants. The values of periotest also decreased with time which indicated well osseointegrated implants. The same has been shown in Chart 1. Clinically, lack of mobility usually means that at least a portion of the implant is in direct contact with bone, although the percentage of bone contact cannot be specified. Randow *et al.*^[15] compared an experimental group (immediate loading fixed superstructures) with the traditional two stage concept. They found a decrease of PTVs in immediate loaded groups with a mean of -2.6 and a mean of -3.9 for unloaded groups over a period of 18 months.

Assessment of survival rate

Finally, the survival rate of immediate loaded implants was assessed in this study over a period of 2 years. The survival rate of immediate loaded implants was 96.6%. There was only one failure of implant after 1.5 years due to periimplantitis and mobility and continuous pain. The implant was removed and the patient was excluded from the study. Otherwise, there was no failure of implants although there was some amount of periimplantitis around few of the early loaded implants in the 1st 2 months of loading. There were no other complaints reported by the patients over a period of 2 years. Various other studies have also reported the similar results with immediate loading of implants with mandibular overdenture.^[12,16]

Conclusion

Early loading of interforaminal mandibular implants demonstrated a highly acceptable clinical success at the end of 2 years. However, marginal bone level and clinical stability were significantly lower initially for immediate loaded implants, but later it improved. Further long-term studies are necessary to evaluate bone density, marginal

bone resorption, prosthetic complications, and success rates in order to thoroughly evaluate this modality of treatment.

References

- Babbush CA, Kent JN, Misiek DJ. Titanium plasma-sprayed (TPS) screw implants for the reconstruction of the edentulous mandible. *J Oral Maxillofac Surg* 1986;44:274-82.
- Jemt T, Chai J, Harnett J, Heath MR, Hutton JE, Johns RB, *et al.* A 5-year prospective multicenter follow-up report on overdentures supported by osseointegrated implants. *Int J Oral Maxillofac Implants* 1996;11:291-8.
- Naert I, Gizani S, Vuylsteke M, van Steenberghe D. A 5-year randomized clinical trial on the influence of splinted and unsplinted oral implants in the mandibular overdenture therapy. Part I: Peri-implant outcome. *Clin Oral Implants Res* 1998;9:170-7.
- Jemt T, Stålblad PA. The effect of chewing movements on changing mandibular complete dentures to osseointegrated overdentures. *J Prosthet Dent* 1986;55:357-61.
- Chiapasco M, Abati S, Romeo E, Vogel G. Implant-retained mandibular overdentures with Brånemark System MKII implants: A prospective comparative study between delayed and immediate loading. *Int J Oral Maxillofac Implants* 2001;16:537-46.
- Marzola R, Scotti R, Fazi G, Schincaglia GP. Immediate loading of two implants supporting a ball attachment-retained mandibular overdenture: A prospective clinical study. *Clin Implant Dent Relat Res* 2007;9:136-43.
- Cooper LF, Moriarty JD, Guckes AD, Klee LB, Smith RG, Almgren C, *et al.* Five-year prospective evaluation of mandibular overdentures retained by two microthreaded, TiOblast nonsplinted implants and retentive ball anchors. *Int J Oral Maxillofac Implants* 2008;23:696-704.
- Adell R, Lekholm U, Rockler B, Brånemark PI. A 15-year study of osseointegrated implants in the treatment of the edentulous jaw. *Int J Oral Surg* 1981;10:387-416.
- Olivé J, Aparicio C. Periotest method as a measure of osseointegrated oral implant stability. *Int J Oral Maxillofac Implants* 1990;5:390-400.
- Schulte W, Lukas D. Periotest to monitor osseointegration and to check the occlusion in oral implantology. *J Oral Implantol* 1993;19:23-32.
- Smith DE, Zarb GA. Criteria for success of osseointegrated endosseous implants. *J Prosthet Dent* 1989;62:567-72.
- Gatti C, Haefliger W, Chiapasco M. Implant-retained mandibular overdentures with immediate loading: A prospective study of ITI implants. *Int J Oral Maxillofac Implants* 2000;15:383-8.
- Weber HP, Buser D, Donath K, Fiorellini JP. Comparison of healed tissues adjacent to submerged and non-submerged unloaded titanium dental implants. *Clin Oral Implants Res* 1996, 7:11-9.
- Meredith N. Assessment of implant stability as a prognostic determinant. *Int J Prosthodont* 1998;11:491-501.
- Randow K, Ericsson I, Nilner K, Petersson A, Glantz PO. Immediate functional loading of Brånemark dental implants. An 18-month clinical follow-up study. *Clin Oral Implants Res* 1999;10:8-15.
- Liao KY, Kan JY, Rungcharassaeng K, Lozada JL, Herford AS, Goodacre CJ. Immediate loading of two freestanding implants retaining a mandibular overdenture: 1-year pilot prospective study. *Int J Oral Maxillofac Implants* 2010;25:784-90.

How to cite this article: Arora V, Kumar D, Legha VS, Arun Kumar KV. Prospective study of treatment outcome of implant retained mandibular overdenture: Two years follow-up. *Contemp Clin Dent* 2014;5:155-9.

Source of Support: Nil. **Conflict of Interest:** None declared.