

Overcoming the Challenge of Full-Thickness Resection of Gastric Lesions Using a Colonic Full-Thickness Resection Device

Yazan Fahmawi, MD¹, Patel Krutika, MD², Manoj Kumar, MD, MPH³, Lindsey Merritt, MD³, and Meir Mizrahi, MD³

¹Department of Internal Medicine, University of South Alabama, Mobile, AL

²Department of Pathology, University of South Alabama, Mobile, AL

³Department of Gastroenterology and Hepatology, Advanced Endoscopy Unit, University of South Alabama, Mobile, AL

ABSTRACT

Endoscopic full-thickness resection device (FTRD) is a new and promising device for endoscopic full-thickness resection of gastrointestinal lesions. Limited data is available regarding its role in endoscopic full-thickness resection of upper gastrointestinal lesions compared with its well-studied role in colorectal lesions. Colonic FTRD is a preloaded device with a large cap which limits peroral insertion. A 49-year-old woman was referred to us for submucosal gastric lesion resection. Gradual dilatation of the upper esophagus was performed before successful advancement of the endoscope mounted with a FTRD system into the stomach. The lesion was successfully resected with no complications.

INTRODUCTION

Full-thickness resection device (FTRD; Ovesco Endoscopy AG, Tuebingen, Germany) is an over-the-scope device that has been developed for one-step procedure endoscopic full-thickness resection (eFTR).¹ FTRD has been reported to be safe and feasible for colorectal lesions with good clinical outcomes.² However, its safety, feasibility, and clinical outcomes for upper gastrointestinal (GI) lesions are yet to be studied. Colonic FTRD system's cap diameter is 21 mm, making oral insertion very challenging.¹ We present a novel technique for upper esophagus dilation to facilitate a safe oral insertion of the colonic FTRD system.

CASE REPORT

A 49-year-old woman with a medical history of gastroesophageal reflux disease and obesity, who was being evaluated for bariatric gastric bypass surgery at an outside hospital, was referred to our GI clinic for resection of suspected gastrointestinal stromal tumor (GIST) on previous endoscopic ultrasound and biopsy. Her history and physical examination were significant for heartburn and morbid obesity. Her initial endoscopic gastroduodenoscopy revealed a 1 × 1-cm mass in the gastric body. On endoscopic ultrasound, the mass was hypoechoic measuring 0.8 × 0.8 cm and arising from the intersection of submucosal layer and muscularis layer without adjacent lymphadenopathy. The walls of the mass were well-demarcated. eFTR under general anesthesia was planned. To facilitate advancing the pediatric colonoscope with the installed colonic FTRD without causing local trauma, the upper and lower esophagus sphincters were gradually dilated with a Savary-Gilliard (Wilson-Cook Medical, Winston-Salem, NC) dilator.

Dilation was performed from size 51 French for 1 minute, and then 55 French for another minute, and finally with a 60 French dilator for 5 minutes. After these serial dilations, a pediatric colonoscope with the installed colonic FTRD was able to be advanced successfully to the stomach lumen with no resistance. The lesion was marked circumferentially using a FTRD marking probe (Figure 1). Favorable positioning was achieved. A FTRD grasper was used to grasp and mobilize the lesion into the cap. The clip was deployed, and the snare was hooked to a high frequency generator performing high frequency snare resection. The endoscope was removed successfully along with the resected specimen (Figure 2). The total procedure time was 60 minutes. There were no

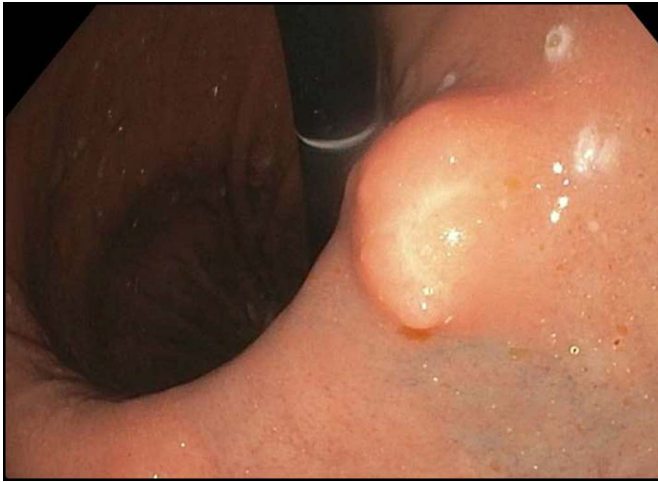

Figure 1. Endoscopic imaging of the lesion before resection.

intraoperative, early, or delayed complications. The patient was discharged the same day on an oral proton-pump inhibitor. Histopathology revealed fibrotic nodule with complete resection (R0), with the absence of muscularis propria (MP) (Figure 3). A follow-up endoscopy at 3 months revealed no recurrence (Figure 4).

DISCUSSION

Submucosal gastric tumors are frequently encountered during upper endoscopy. Most of these tumors are benign. However, tumors arising from the MP can have malignant potential.³ GIST is the most common tumor originating from the MP of the stomach.³ Malignant transformation of GISTs has been reported in up to 30% of cases.^{4,5} Therefore, full-thickness resection of these lesions is required. The American Society for Gastrointestinal Endoscopy (ASGE) and the National Comprehensive Cancer Network guidelines (NCCN) recommend removing lesions that are symptomatic, larger than 2 cm, and/or contain high-risk features of GISTs (irregular border,

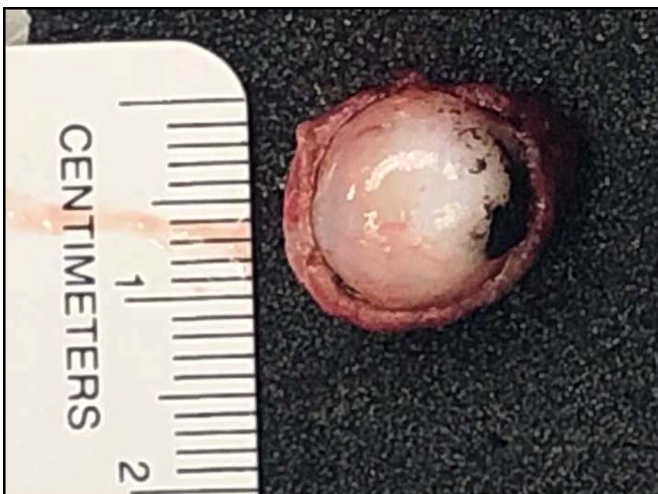

Figure 2. The lesion after resection.

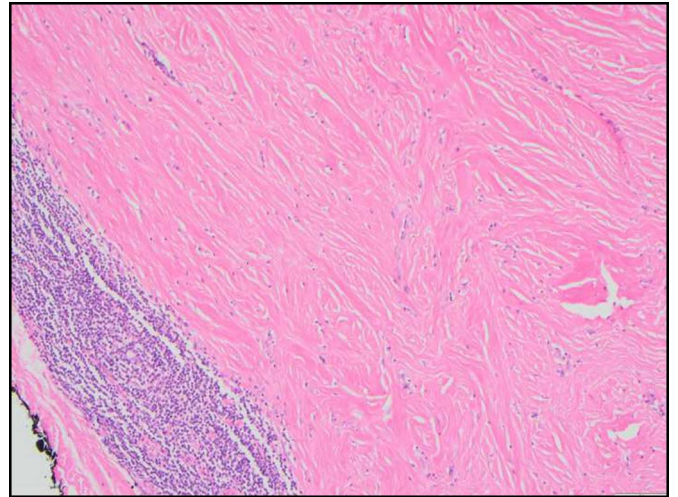


Figure 3. Histology of the resected lesion shows fibrous tissue.

presence of cystic spaces, heterogeneous echo pattern, and echogenic foci).⁶ The recommendation regarding the removal of asymptomatic GISTs less than 2 cm remains controversial. Although the ASGE and the NCCN recommend a regular follow-up for asymptomatic lesions less than 2 cm and GISTs without high-risk features, the European Society for Medical Oncology group recommends resecting any histologically confirmed GIST regardless of the size.⁷ In our case, the lesion did not meet the ASGE or the NCCN criteria for removal. However, the patient was planning to undergo Roux-en-Y surgery for her morbid obesity, which could interfere with this surgery or make future surgical resection of the gastric lesion difficult.

eFTR offers a minimally invasive procedure with good clinical outcomes.² Two different eFTR techniques are reported. The first one is the free-hand eFTR in which an endoscopic submucosal dissection full-thickness resection is performed first, followed by a gastric wall defect closure. The other eFTR technique is the device-assisted technique in which patency of

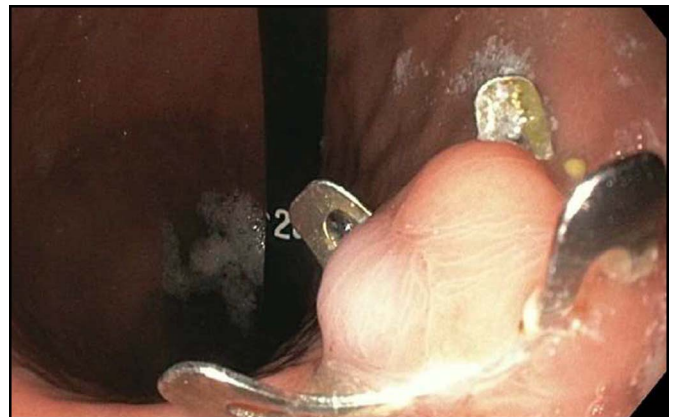

Figure 4. Endoscopic imaging of the resection site after 3 months with an over-the-scope clip still in place.

gastric wall is secured first by a clip, followed by a eFTR.⁸ FTRD is an example of the device-assisted eFTR technique. FTRD is an over-the-scope clip system that can be installed over standard endoscopes. The FTRD consists of a transparent cap with preloaded clip and thread and an integrated snare system.¹ Many studies have reported its safety and efficacy in treating colorectal lesions, whereas the data of its role in upper GI lesions are still very limited.^{2,9,10} A recently published abstract from an international study including 47 patients who underwent eFTR for upper GI lesions reported a technical success rate of 89% and histologic complete resection (R0) rate of 81%.¹¹ To date, eFTR is only approved for colorectal lesions in the United States. This procedure was an off-label use of this device, and the patient's consent was obtained for the same.

Colonic FTRD's system cap has an outer diameter of 21 mm, which limits peroral introduction and poses the risk of local trauma such as superficial mucosal tear and even esophageal perforation. Gradual dilatation of the upper esophageal sphincter as seen in this case can increase esophageal compliance and allow for the insertion of the endoscope with the installed FTRD while mitigating risk of complications. In our case, we used the Savary-Gilliard dilator, which is a push-type tapered thermoplastic dilator, to gradually dilate the upper esophageal sphincter by increasing the diameter. At the time of this procedure, only colonic FTRD was available in the US market. Hopefully, the new gastroduodenal FTRD system that has a cap diameter of 19.5 mm will be approved in the United States, which will facilitate the procedure and will reduce the risk of intra-procedural complications.¹ Despite having a smaller cap, this novel technique can also be used in gastroduodenal FTRD because it can still be challenging to advance it in patients with small upper GI caliber. Similar to other procedures that involve esophageal dilatation, this technique has potential risk of esophageal perforation. In conclusion, this novel technique of upper esophageal dilatation before using a FTRD for the complete resection of upper GI lesions can allow advancement of the endoscope with the installed device and minimize adverse events.

DISCLOSURES

Author contributions: All authors contributed equally to this manuscript. Y. Fahmawi is the article guarantor.

Financial disclosure: None to report.

Previous presentation: This case was presented as a poster at the ACG Annual Scientific Meeting, October 25-30, 2019; San Antonio, Texas.

Informed consent was obtained for this case report.

Received August 18, 2019; Accepted December 19, 2019

REFERENCES

1. FTRD® System Archives. *Ovesco Endoscopy AG* (<https://ovesco.com/ftd-system/>). Accessed June 21, 2019.
2. Schmidt A, Beyna T, Schumacher B, et al. Colonoscopic full-thickness resection using an over-the-scope device: A prospective multicentre study in various indications. *Gut*. 2018;67(7):1280–9.
3. Kim SY, Kim KO. Management of gastric subepithelial tumors: The role of endoscopy. *World J Gastrointest Endosc*. 2016;8(11):418–24.
4. Gu M, Ghafari S, Nguyen PT, Lin F. Cytologic diagnosis of gastrointestinal stromal tumors of the stomach by endoscopic ultrasound-guided fine-needle aspiration biopsy: Cytomorphologic and immunohistochemical study of 12 cases. *Diagn Cytopathol*. 2001;25(6):343–50.
5. Lee HL. Advances in the management of upper gastrointestinal subepithelial tumor: Pathologic diagnosis using endoscopy without endoscopic ultrasound-guided biopsy. *Clin Endosc*. 2016;49(3):216–9.
6. Evans JA, Evans JA, Chandrasekhara V, et al. The role of endoscopy in the management of premalignant and malignant conditions of the stomach. *Gastrointest Endosc*. 2015;82(1):1–8.
7. Group ESNW. Gastrointestinal stromal tumors: ESMO clinical practice guidelines for diagnosis, treatment and follow-up. *Ann Oncol*. 2012;23:vii49.
8. Cai MY, Martin Carreras-Presas F, Zhou PH. Endoscopic full-thickness resection for gastrointestinal submucosal tumors. *Dig Endosc*. 2018;(30 Suppl 1):17–24.
9. Andrisani G, Soriani P, Manno M, et al. Colo-rectal endoscopic full-thickness resection (EFTR) with the over-the-scope device (FTRD®): A multicenter Italian experience. *Dig Liver Dis*. 2019;51(3):375–81.
10. Valli PV, Mertens J, Bauerfeind P. Safe and successful resection of difficult GI lesions using a novel single-step full-thickness resection device (FTRD®). *Surg Endosc*. 2018;32(1):289–99.
11. Hajifathalian K, Dawod QM, Issa D, et al. Tu1116 Full-thickness resection device (FTRD) for treatment of upper gastrointestinal tract lesions: The first international experience. *Gastrointest Endosc*. 2019;89(6):AB565–AB566.

Copyright: © 2020 The Author(s). Published by Wolters Kluwer Health, Inc. on behalf of The American College of Gastroenterology. This is an open-access article distributed under the terms of the Creative Commons Attribution-Non Commercial-No Derivatives License 4.0 (CCBY-NC-ND), where it is permissible to download and share the work provided it is properly cited. The work cannot be changed in any way or used commercially without permission from the journal.