



Received: 2015.05.14
Accepted: 2015.07.21
Published: 2015.11.13

Authors' Contribution:

- A** Study Design
- B** Data Collection
- C** Statistical Analysis
- D** Data Interpretation
- E** Manuscript Preparation
- F** Literature Search
- G** Funds Collection

Right Liver Lobe Hypoplasia and Related Abnormalities

Banu Alicioglu^{A,B,C,D,E,F}

Department of Radiology, Visart Medical Imaging Center, Ankara, Turkey

Author's address: Banu Alicioglu, Department of Radiology, Visart Medical Imaging Center, Ankara, Turkey,
e-mail: alicioglu.b@gmail.com

Background:

Hypoplasia and agenesis of the liver lobe is a rare abnormality. It is associated with biliary system abnormalities, high location of the right kidney, and right colon interposition. These patients are prone to gallstones, portal hypertension and possible surgical complications because of anatomical disturbance.

Case Report:

Magnetic resonance imaging features of a rare case of hypoplasia of the right lobe of the liver in a sigmoid cancer patient are presented.

Conclusions:

Hypoplasia of the right liver should not be confused with liver atrophy; indeed, associations with other coexistent abnormalities are also possible. Awareness and familiarity with these anomalies are necessary to avoid fatal surgical and interventional complications.

MeSH Keywords:

Anatomic Variation • Liver • Magnetic Resonance Imaging

PDF file:

<http://www.polradiol.com/abstract/index/idArt/894658>

Summary

Background

There have been significant recent developments in liver transplantation and introduction of advanced imaging methods. These developments have mandated the need to better understand anatomical hepatic variations as well as vascular and biliary territories which can be isolated as units for partial hepatectomy and other local surgical interventions. Minor anatomical variations of the liver such as Riedel's lobe and accessory lobes are not infrequent. However, hypoplasia or agenesis of the liver lobe is a rare condition and is generally associated with gallbladder, biliary tract abnormalities and misplaced neighbouring organs [1–3]. These anomalies may be complicated by gallstone formation or by portal venous hypertension or complications that arise during surgery or interventions; the anomalies are usually also asymptomatic and often found incidentally on abdominal radiological scans [2]. Herein we report magnetic resonance imaging (MRI) and magnetic resonance cholangiopancreatography (MRCP) features of right lobe hypoplasia of the liver in a case of a sigmoid colon tumor.

Case Report

A 72-year-old man with diagnosed sigmoid colon carcinoma was admitted to our Radiology Department for liver

magnetic resonance imaging (MRI) for metastasis scanning. This scan detected a T1 hypointense, T2 hyperintense ring-enhancing lesion with late enhancement and delayed wash out at the junction of segment II-III of the liver. This lesion was compatible with a metastasis. The left lobe of the liver was hypertrophic and the right lobe was smaller and had a smooth contour. The segments V-VIII were extremely hypoplastic. The hepatic flexura and the right kidney were located just below the diaphragm. The right colon and hepatic flexura were displaced laterally and posteriorly. The right adrenal gland was located in front of the kidney (Figure 1A, 1B). All of the hepatic veins were normal (Figure 1C). The portal vein was 14 mm, a normal maximal value, and the right and left portal vein branches were prominent with normal branching patterns. The course of the portal vein, however, was abnormal. The splenic vein, the superior mesenteric veins and their confluence were normal. The portal vein was found to extend laterally then curve antero-medially with an acute angulation (Figure 1D). There was no porto-caval shunt. The gallbladder was absent. The common bile duct was 1 cm in diameter, tapering distally and no stone, stenosis or mass was seen. The common bile duct had a more vertical course than normal (Figure 2A, 2B). The abdominal aorta and inferior vena cava were tortuous and displaced to the right side because of the hypoplastic

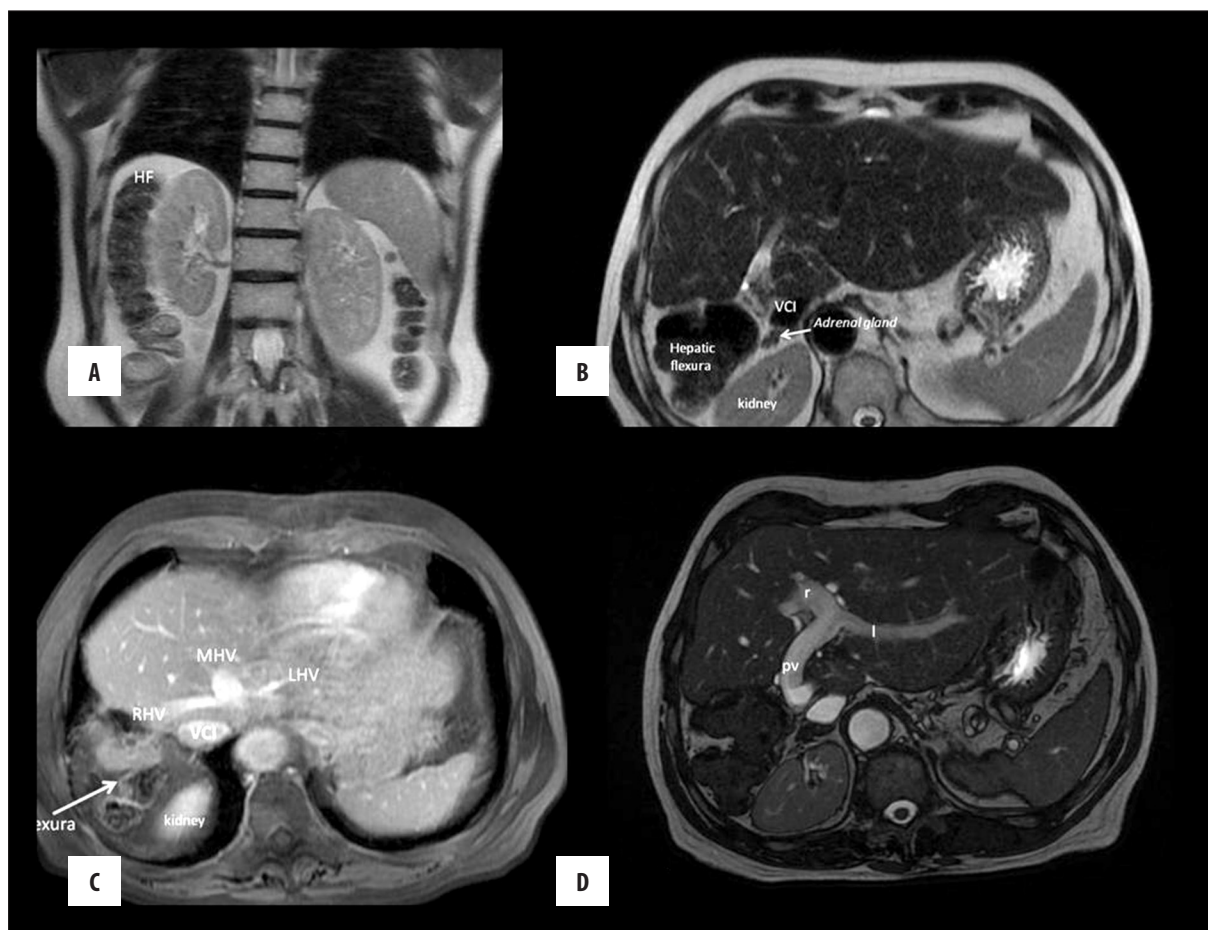


Figure 1. (A) Coronal T2 W image. The hepatic flexura and the right kidney appears below the diaphragm. No liver tissue is seen posteriorly. (B) Axial T2 W image. The hepatic flexura and the right kidney appears below the diaphragm. No liver tissue is seen posteriorly. Adrenal gland is in front of the right kidney. (C) Post-contrast T1 W axial scan. Hepatic veins are seen; the inferior vena cava is located more laterally. (D) Axial 2D fiesta T2 W image. Enlargement of the portal vein and the right and left branches are seen. The portal vein course is more vertical and lateral, showing convexity medially.

right liver lobe. The abdominal aorta exhibited no significant atherosclerosis or scoliosis. The liver functions of the patients were normal.

The liver enzymes were in normal range. He had no previous liver surgery, but he had been operated on twice (open laparotomy) because of his gallstones. The first surgery failed because the gallbladder could not be located.; With the second surgery, however, the gallbladder was found behind the liver and was excised.

Discussion

Agenesis of the right lobe of the liver is characterized by the absence of the right hepatic vein, and the presence of liver tissue on the right side; it is usually associated with hypertrophy of the left lobe of the liver, colonic interposition between the liver and the diaphragm, right diaphragmatic hernia, portal hypertension, or an anomalously positioned gallbladder. It is generally asymptomatic and found incidentally with ultrasonography (USG) and computed tomography (CT) [4]. The pathogenesis of the agenesis is not fully understood. However, one possible pathogenic

mechanism is the abnormal development of the portal venous segment during embryologic growth [4].

The differential diagnosis includes cirrhosis, cholangiocarcinoma, choledocholithiasis, idiopathic portal hypertension, prior fulminant hepatitis and Caroli's disease if there has not been recent liver surgery. The gallbladder is often malpositioned retro- or suprahepatic in a vertical position with right liver agenesis [5].

A misplaced gallbladder, distorted biliary architecture and decreased number of right lobe biliary channels may be complicated by biliary stones or strictures [6]. A predisposition to a gallbladder carcinoma may be also associated with poor biliary drainage [3]. A retrohepatic or suprahepatic location of the gallbladder complicates a surgical approach without mobilization of the liver. Moreover, an abnormal course of the biliary system may lead to the complications of severe iatrogenic biliary injuries [7]. The abnormality may further be complicated by portal hypertension. Esophageal varices are an additional complication because of a possible decrease in the number of intrahepatic portal vein branches since this results in the failure

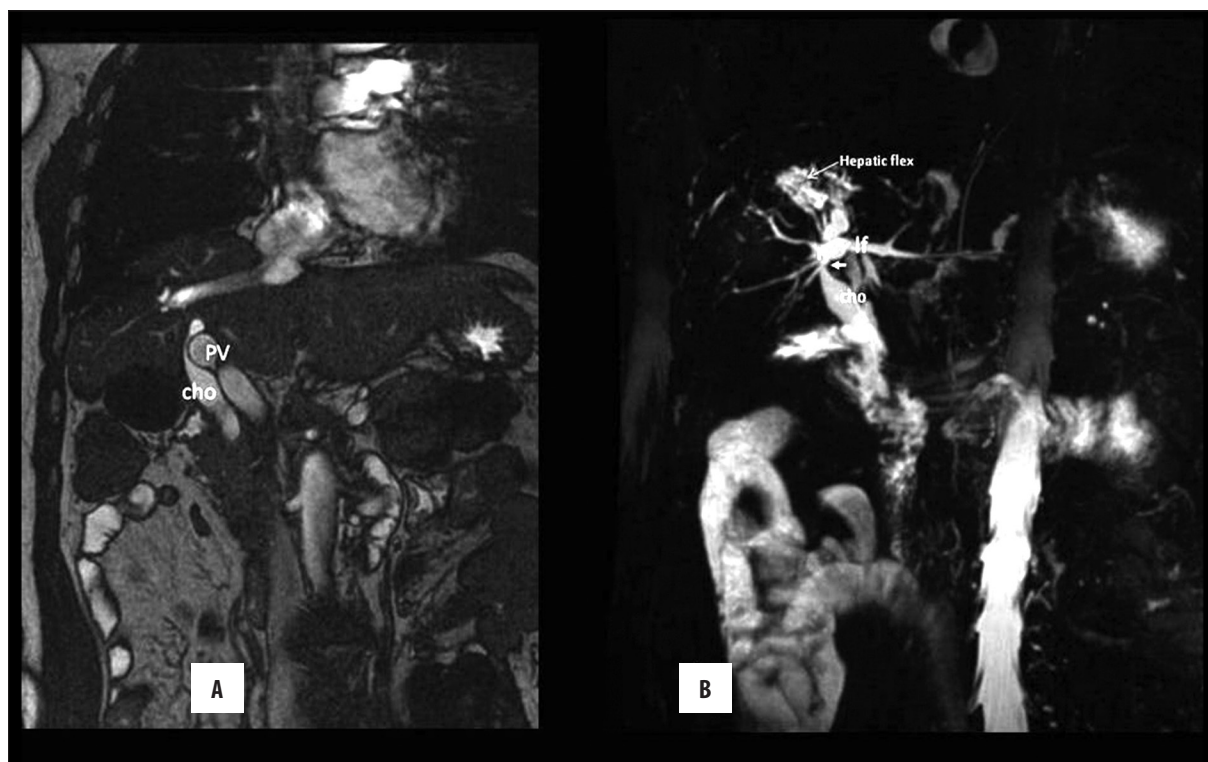


Figure 2. (A) Coronal 2D fiesta T2 W image. The course of the main bile duct and the portal vein is seen; dilated portal vein causes indentation of the common bile duct (arrow). (B) 3D MRCP image shows the common bile duct and the right and left branches. Extrinsic compression of the common bile duct caused by enlarged portal vein is seen (small arrow). High signal intensity caused by the hepatic flexura luminal content is remarked (arrow).

of compensation by the left lobar portal vein branches. Another hypothesis on the origin of portal hypertension is a potential shunt flow between the hepatic artery and the portal vein [4]. Kidney or liver biopsies or colonic surgeries can induce additional complications. The previous reported cases were demonstrated on a cadaver [8]; endoscopic retrograde cholangiopancreatography [7] on USG [6] and mostly on computed tomography [1,4,7]. We could find no literature citations involving MRI and MRCP approaches to the identification of the abnormality in the English literature. The anatomical course of the portal vein and the main bile duct has not been discussed extensively in cases from the prior literature. When we look at the images of our case and those of previous case reports [3,5,7], the anatomical course of the portal vein and the main biliary duct are similar. They are located more laterally and enter into the hepatic hilum vertically (the normal portal venous entrance

is more horizontal). We also demonstrated that after the portal confluents, the portal vein proceeds horizontally to the right, then swirls forward with an acute angle and finally, after slightly curving, reaches the hepatic hilum.

Hypoplasia of the right liver lobe was found associated with a persistent right umbilical vein [8,9]; there was not a visible vein consistent with patency of the right umbilical vein within the ligamentum teres in our case.

Conclusions

Hypoplasia of the right liver lobe is a very rare abnormality but it should not be confused with liver atrophy; indeed, associations with other coexistent abnormalities are also possible. Awareness and familiarity of these anomalies is necessary to avoid fatal surgical and interventional complications.

References:

1. Chou CK, Mak CW, Lin MB et al: CT of agenesis and atrophy of the right hepatic lobe. *Abdom Imaging*, 1998; 23: 603–7
2. Inoue T, Ito Y, Matsuzaki Y et al: Hypogenesis of right hepatic lobe accompanied by portal hypertension: case report and review of 31 Japanese cases. *J Gastroenterol*, 1997; 32: 836–42
3. Radin DR, Colletti PM, Ralls PW et al: Agnesis of the right lobe of the liver. *Radiology*, 1987; 164: 639–42
4. Suh HJ, Kim WT, Kim MY, Cho YK: Combined anomaly of the right hepatic lobe agenesis and absence of the inferior vena cava: A case report. *Korean J Radiol*, 2008; 9(Suppl.): S61–64
5. Nacif LS, Buscariolli Ydos S, D'Albuquerque LA, Andraus W: Agnesis of the right hepatic lobe. *Case Rep Med*, 2012; 2012: 415742
6. Hsu KL, Cheng YF, Ko SF: Hypoplastic right hepatic lobe with retrohepatic gallbladder complicated by hepatolithiasis and liver abscess: a case report. *Hepatogastroenterology*, 1997; 44: 803–7
7. Paik KY: Biliary injury after cholecystectomy in a patient with severe right liver atrophy. *J Korean Surg Soc*, 2013; 84: 185–88
8. Shankar N, Rabi S: A rare case of combined hypoplasia of the right lobe of the liver and a persistent right umbilical vein. *Eur J Anat*, 2005; 9: 55–57
9. Varma V, Mehta N, Kumaran V, Nundy S: Indications and contraindications for liver transplantation. *Int J Hepatol*, 2011; 2011: 1–9