









# Unilateral Pulmonary Vein Atresia Initially Presenting as Interstitial Lung Disease in an Elderly Female: Serial Chest Radiograph Changes and Its Literature Review

고령에서 일측성 간질성 폐질환으로 보이는  
 일측성 폐정맥 폐쇄: 흉부 X선 사진의 시계열적 변화와  
 문헌 고찰

Young Woo Sim, MD<sup>1</sup> , Jongmin Park, MD<sup>2\*</sup> , Byungeon Park, MD<sup>2</sup> ,  
 Jae-Kwang Lim, MD<sup>2</sup> , Kyung Min Shin, MD<sup>2</sup> , Young-Seon Kim, MD<sup>1</sup> 

<sup>1</sup>Department of Radiology, Yeungnam University Hospital, Yeungnam University College of Medicine, Daegu, Korea

<sup>2</sup>Department of Radiology, School of Medicine, Kyungpook National University, Daegu, Korea

Unilateral pulmonary vein atresia (PVA) is a rare congenital cardiovascular anomaly occurring after the common pulmonary vein fails to incorporate into the left atrium. It is most commonly diagnosed in childhood, and diagnosis after reaching adulthood is extremely rare. Dyspnea on exertion and hemoptysis are common clinical features in adult PVA patients, whereas lung parenchymal abnormalities are indirect signs of PVA, which can manifest as interstitial lung disease. Herein, we present the case of a 62-year-old female diagnosed with unilateral PVA presenting as unilateral interstitial lung disease and report the changes in her chest radiographs over 12 years.

**Index terms** Pulmonary Vein; Computed Tomography, X-Ray; Interstitial Lung Disease

## INTRODUCTION

Pulmonary vein atresia (PVA) is a rare congenital anomaly that leads to progressive pulmonary hypertension and cardiac failure (1, 2). Based on the normal development

Received February 18, 2021

Revised April 15, 2021

Accepted May 30, 2021

\*Corresponding author

Jongmin Park, MD  
 Department of Radiology,  
 School of Medicine,  
 Kyungpook National University,  
 680 Gukchaebosang-ro, Jung-gu,  
 Daegu 41944, Korea.







Tel 82-53-200-6242

Fax 82-53-422-2677

E-mail [jmmpark@knu.ac.kr](mailto:jmmpark@knu.ac.kr)

This is an Open Access article distributed under the terms of the Creative Commons Attribution Non-Commercial License (<https://creativecommons.org/licenses/by-nc/4.0/>) which permits unrestricted non-commercial use, distribution, and reproduction in any medium, provided the original work is properly cited.

### ORCID iDs

Young Woo Sim   
<https://orcid.org/0000-0002-3868-0238>  
 Jongmin Park   
<https://orcid.org/0000-0001-9240-4181>  
 Byungeon Park   
<https://orcid.org/0000-0002-5807-9271>  
 Jae-Kwang Lim   
<https://orcid.org/0000-0002-1299-9996>  
 Kyung Min Shin   
<https://orcid.org/0000-0003-4109-0228>  
 Young-Seon Kim   
<https://orcid.org/0000-0002-9168-8204>

of pulmonary venous drainage and extent of involvement, PVA is classified into three types: common, individual, and unilateral (3). Unilateral PVA is a rare condition characterized by the complete absence of a pulmonary vein in one of the lungs. Unilateral PVA is commonly diagnosed during childhood, but, in rare cases, it may not be diagnosed until adulthood (4). It is generally associated with hemoptysis, recurrent infection, and pulmonary hypertension (4, 5). In such patients, unilateral PVA is associated with high morbidity and mortality (6). PVA may also be initially diagnosed as pneumonia or other parenchymal lung diseases, leading to delayed treatment and unnecessary invasive diagnostic studies (7, 8).

Herein, we describe the case of a 62-year-old female with unilateral PVA that was initially misdiagnosed as interstitial lung disease and review the relevant literature. Further, we focused on the radiological changes on long-term chest radiographs.

## CASE REPORT

A 62-year-old female, who was a nonsmoker, visited our respiratory outpatient clinic. She presented with a 3-day history of dyspnea and sputum. The patient did not claim to have any respiratory symptoms during childhood. Since the age of 20, she had to rest while walking due to shortness of breath (modified Medical Research Council [mMRC] scale grade 2). However, she had not undergone any examination or medical treatment. She had been regularly monitored in the outpatient clinic of our hospital for the past 5 years due to the suspicion of interstitial lung disease. Pulmonary function tests were performed, demonstrated a forced expiratory volume in 1 second (FEV1) of 48%, forced vital capacity of 49%, and diffusing capacity for carbon monoxide of 56% of predicted, which showed both restrictive and obstructive respiratory patterns.

She was admitted to our hospital for pneumonia 1 year ago and was treated for hemoptysis 5 years ago. She had no history of environmental or occupational exposure. She was diagnosed with hepatitis B-induced cirrhosis with esophageal varix 13 years ago. The patient regularly visited our facility for medication. She had no history of any procedure or surgery affecting the pulmonary vein.

Contrast-enhanced chest CT showed unilateral diffuse ground-glass opacities, reticulation, and traction bronchiectasis with volume loss in the right lung, suggesting unilateral interstitial lung disease (Fig. 1A-C). All her chest radiographs from 12 years of age until the present were reviewed. An initial chest radiograph showed a small right hemithorax with mediastinal shifting to the right as well as diminished vessel size in the right lung (Fig. 1D). Reticular opacity and ground-glass opacities in the right lung were also noted. On follow-up chest radiography, the extent of reticular opacity increased, which was indicative of gradual pulmonary fibrosis progression.

Furthermore, contrast-enhanced chest CT also revealed the absence of the right superior and inferior pulmonary veins entering the left atrium as well as right pulmonary artery hypoplasia. Meanwhile, volume-rendered reconstructed image of the chest CT showed that the posterior wall of the left atrium (at the expected site of entry of the right pulmonary vein) was completely smooth, which was consistent with unilateral PVA. There was also a relatively dilated left pulmonary artery (Fig. 1E). However, pulmonary hypertension was excluded

**Fig. 1.** Radiologic findings of unilateral pulmonary vein atresia in a 62-year-old female, presenting as unilateral interstitial lung disease.

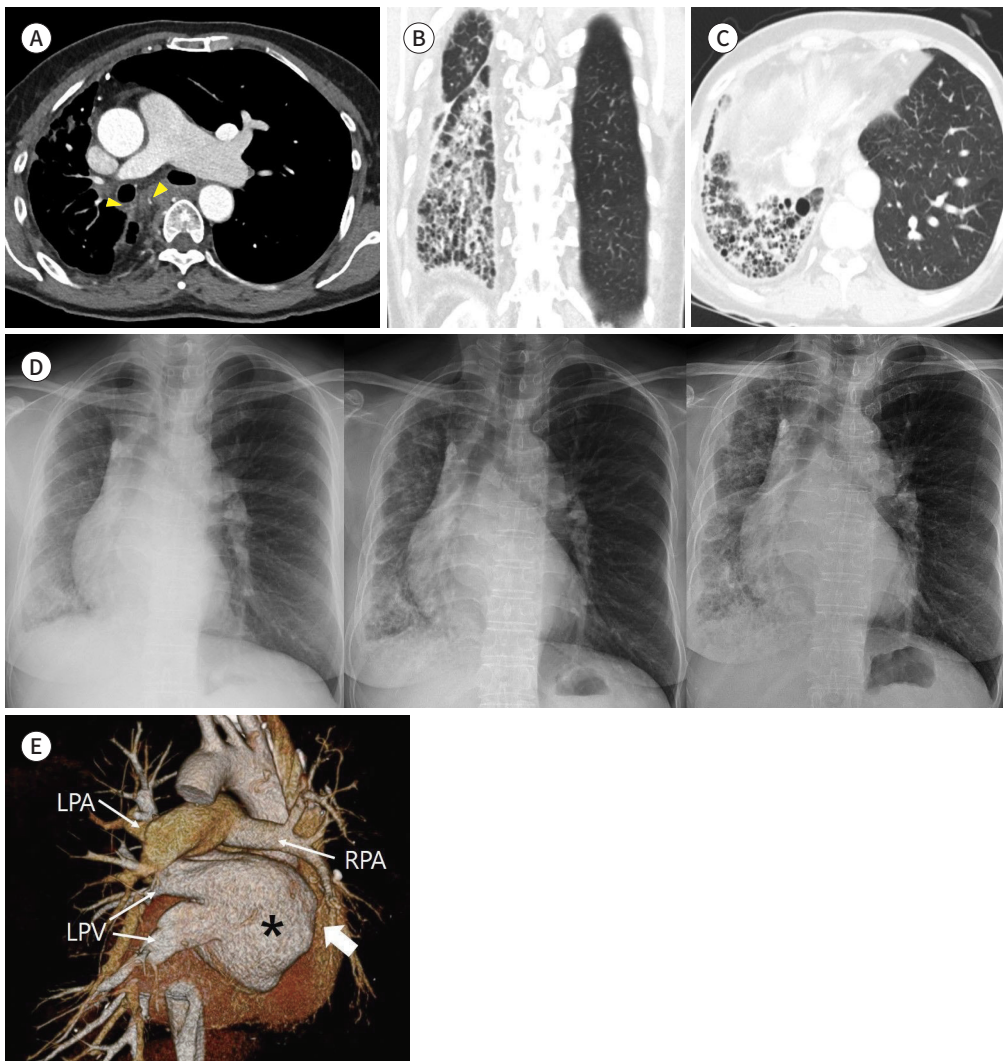
**A.** Axial image of the mediastinal window demonstrates a significant size discrepancy between the RPA and LPA. Apparent pleural thickening is noted along the right lung lateral margin. The hypertrophied hilar branch of the bronchial artery is noted (arrowheads).

**B, C.** Lung window setting images show unilateral diffuse ground-glass opacities, reticulation, and traction bronchiectasis, with right lung volume loss.

**D.** Serial chest radiographs taken in 2008, 2016, and 2020 (images from left to right). Initial chest radiograph (left) shows a small right hemithorax with right mediastinal shifting and diminished vessel size in the right lung. Right-mid and lower-zonal linear infiltration, reticular infiltration, and ground-glass opacities are visible. The follow-up chest radiograph (middle) demonstrates increased extent of linear, reticular infiltration, and ground-glass opacities with basal predominance in the right lung. The last follow-up chest radiograph (right) reveals progression of the reticular infiltrates, ground-glass opacities, and consolidations in the right lung.

**E.** Posterior view of the volume-rendered reconstructed image of the chest CT, with removal of the descending aorta, shows the absence of right pulmonary venous drainage into the left atrium (arrow). The entirely smooth margin of the left atrium is noted (asterisk).

LPA = left pulmonary artery, LPV = left pulmonary vein, RPA = right pulmonary artery



due to the absence of abrupt narrowing of the peripheral pulmonary vessels, right ventricular hypertrophy, and right atrial and ventricular enlargement. There was no anomalous pulmonary venous return or intracardiac anatomic abnormality.

Electrocardiography (ECG) was performed to assess the impact of lung disease on cardiac structure and function. Normal sinus rhythm was observed on ECG. For further evaluation of cardiac function, echocardiography or cardiac CT was recommended, but the patient refused to undergo further examinations.

This study was approved by the Institutional Review Board of our institution, and the requirement for informed consent was waived (IRB No. KNUH 2021-02-018).

## DISCUSSION

PVA can be classified into three types based on the extent of involvement: common, unilateral, and individual (3). PVA may present as an isolated anomaly, but in approximately 50% of patients, it is associated with a congenital heart defect or anomalous pulmonary venous return (4, 6). Noncardiovascular manifestations, such as pulmonary lymphatic dilatation or lymphangiectasia, have also been reported in PVA (9). Unilateral PVA is a rare anomaly characterized by complete absence of the pulmonary vein in the affected lung, and it is associated with a high mortality rate (1, 6). Moreover, PVA can be classified into congenital and acquired types. The etiologies of congenital PVA are unknown, but it can be described as a defect in the connection between the common pulmonary vein and left atrium. In this case, the absence of bronchial obstruction or any obstructive mediastinal lesions on chest CT suggested a congenital anomaly. In addition, we also suspected congenital PVA because of the completely smooth margin of the posterior wall of the left atrium, which is expected to enter the right pulmonary vein. The absence of any history of procedure or surgery also strengthens our suspicion of congenital PVA.

The radiological findings of PVA include ground-glass opacities, septal thickening, and a small hemithorax with an ipsilateral mediastinal shift (4). Pulmonary fibrosis was also seen, and this was attributed to pulmonary venous infarction and chronic pulmonary edema (10). Our patient experienced obstructed venous return throughout her lifetime, resulting in progressive pulmonary fibrosis. On chest radiographs over a 12-year period, pulmonary fibrosis gradually progressed in the right lung. Considering the mild symptoms that occurred during her 20s, pulmonary fibrosis has likely been progressing for a long time. To our knowledge, only two other case reports have discussed PVA that was first diagnosed in adults presenting as interstitial lung disease (Table 1). In all cases, CT exams performed at the time of diagnosis revealed an interstitial lung pattern in the lung affected by PVA. Chest CT is essential to diagnose PVA, and if unilateral interstitial lung disease is seen on chest X-ray, further assessment via a CT scan is necessary to avoid delayed diagnosis and treatment.

PVA is rarely diagnosed first in adults because most clinical symptoms occur during childhood. Because of the extremely low prevalence of unilateral PVA and its high mortality in childhood (1, 6), studies with long-term follow-up are limited. Herein, we also reviewed previous case reports related to PVA; none of the previous cases had a patient diagnosed at an advanced age, as in our study. The absence of a concomitant anomaly helped in preventing

Table 1. Articles Reported in the Literature about Adult Patients with PVA Demonstrating Interstitial Lung Disease

Reference	Age at Diagnosis	Sex	Clinical Symptom	Diagnosis	Chest CT	Treatment
Bentaoune et al. (7)	54	F	Chronic dyspnea asthenia	Congenital left PVA with right upper lobar PVA	Bilateral ground-glass opacities; small left hemithorax	Conservative treatment
Savaş Bozbaş et al. (8)	20	F	Dyspnea on exertion	Congenital right PVA	Interstitial disease pattern with shifting of mediastinal structures	Conservative treatment
Current study	62	F	Dyspnea on exertion hemoptysis	Congenital right PVA	Diffuse ground-glass opacity; extensive pulmonary fibrosis; subpleural reticulation; traction bronchiectasis	Conservative treatment

PVA = pulmonary vein atresia

serious disease progression in our patient. Our patient had mild symptoms from a young age, and unilateral pulmonary fibrosis of an unknown cause continued to progress.

In summary, we reported the changes in chest radiographs in an elderly patient with unilateral PVA without associated congenital heart disease over a 12-year period. Therefore, when a patient presents with complaints of ambiguous symptoms suggestive of progressive pulmonary fibrosis, such as dyspnea and hemoptysis, with suspicious radiologic findings, PVA should be considered as a differential diagnosis.

#### Author Contributions

Conceptualization, P.J., P.B.; data curation, S.Y.W.; investigation, S.Y.W.; resources, L.J.; supervision, P.J., L.J., S.K.M.; visualization, S.Y.W., P.B.; writing—original draft, S.Y.W., P.J., P.B.; and writing—review & editing, S.K.M., K.Y., L.J.

#### Conflicts of Interest

The authors have no potential conflicts of interest to disclose.

#### Funding

None

#### REFERENCES

1. Driscoll DJ, Hesslein PS, Mullins CE. Congenital stenosis of individual pulmonary veins: clinical spectrum and unsuccessful treatment by transvenous balloon dilation. *Am J Cardiol* 1982;49:1767-1772
2. Drossner DM, Kim DW, Maher KO, Mahle WT. Pulmonary vein stenosis: prematurity and associated conditions. *Pediatrics* 2008;122:e656-e661
3. Lee HN, Kim YT, Cho SS. Individual pulmonary vein atresia in adults: report of two cases. *Korean J Radiol* 2011;12:395-399
4. Heyneman LE, Nolan RL, Harrison JK, McAdams HP. Congenital unilateral pulmonary vein atresia: radiologic findings in three adult patients. *AJR Am J Roentgenol* 2001;177:681-685
5. Gómez Hernández MT, Rodríguez Pérez M, F Jiménez M. Isolated unilateral pulmonary vein atresia in adults. *Arch Bronconeumol* 2015;51:424-425
6. Pourmoghadam KK, Moore JW, Khan M, Geary EM, Madan N, Wolfson BJ, et al. Congenital unilateral pulmonary venous atresia: definitive diagnosis and treatment. *Pediatr Cardiol* 2003;24:73-79
7. Bentaoune T, Arous S, Baghdadi H, Assaidi A, Drighil A, Habbal R. Unilateral pulmonary vein atresia with contralateral upper pulmonary vein atresia in an adult patient. *J Cardiol Curr Res* 2016;7:00262

8. Savaş Bozbaş Ş, Varan B, Akçay Ş. Right pulmonary venous atresia: a case report and review of literature. *Tuberk Toraks* 2012;60:254-257
9. Perez M, Kumar TK, Briceno-Medina M, Alsheikh-Ali M, Sathanandam S, Knott-Craig CJ. Common pulmonary vein atresia: report of three cases and review of the literature. *Cardiol Young* 2016;26:629-635
10. Nasrallah AT, Mullins CE, Singer D, Harrison G, McNamara DG. Unilateral pulmonary vein atresia: diagnosis and treatment. *Am J Cardiol* 1975;36:969-973

## 고령에서 일측성 간질성 폐질환으로 보이는 일측성 폐정맥 폐쇄: 흉부 X선 사진의 시계열적 변화와 문헌 고찰

심영우<sup>1</sup> · 박종민<sup>2\*</sup> · 박병건<sup>2</sup> · 임재광<sup>2</sup> · 신경민<sup>2</sup> · 김영선<sup>1</sup>

일측성 폐정맥 폐쇄는 총폐정맥이 좌심방내로 연결되는 못하는 드문 심혈관계 기형이다. 일측성 폐정맥 폐쇄는 흔히 어린 시기에 진단이 되며, 성인이 된 이후에 진단이 되는 경우는 극히 드물다. 성인 환자에서 활동 시 호흡곤란과 객혈이 흔한 임상증상이다. 폐실질의 이상은 폐정맥 폐쇄의 간접적인 소견이며, 간질성 폐질환으로 나타날 수 있다. 우리는 62세 여자 환자에서 일측성 간질성 폐질환을 보이는 일측성 폐정맥 폐쇄의 증례와 12년간의 흉부 X선 사진 소견의 변화를 보고하고자 한다.

<sup>1</sup>영남대학교 의과대학 영남대학교병원 영상의학과,  
<sup>2</sup>경북대학교 의과대학 영상의학교실