

This is an Open Access article licensed under the terms of the Creative Commons Attribution-NonCommercial 3.0 Unported license (CC BY-NC) (www.karger.com/OA-license), applicable to the online version of the article only. Distribution permitted for non-commercial purposes only.

Case Studies

Cutaneous Myopericytoma: A Report of 3 Cases and Review of the Literature

Phyu P. Aung^a Lynne J. Goldberg^b Meera Mahalingam^b Jag Bhawan^b

^aDermatopathology Section, Department of Pathology, MD Anderson Cancer Center, Houston, Tex., and ^bDermatopathology Section, Department of Dermatology, Boston University School of Medicine, Boston, Mass., USA

Key Words

Cutaneous · Myopericytoma · Scalp · Verruca vulgaris

Abstract

Cutaneous myopericytoma is a rarely reported mesenchymal neoplasm with a benign biologic behavior. It is seen more commonly in males and typically occurs in adults on the distal extremities. To the best of our knowledge, there are only 13 reports describing 45 cases of cutaneous myopericytoma in the literature. The 3 cases in this report expand the clinical presentation and reinforce the histopathologic features of cutaneous myopericytoma. While the clinical presentation in 2 cases (located on the scalp and heel) was in keeping with that reported previously of a slow-growing painless firm nodule, the third case, located on the dorsal wrist, presented as a scaly keratotic nodule. Histopathologic examination of all 3 cases revealed an unencapsulated dermal nodule with concentric perivascular arrangement of plump, spindle-shaped myoid cells admixed with thin-walled blood vessels. Immunohistochemical staining revealed the lesional cells to be actin- (3/3) and caldesmon- (2/3) positive and negative for other smooth muscle markers, compatible with perivascular myopericytic differentiation.

© 2015 S. Karger AG, Basel

Introduction

Myopericytoma, a relatively uncommon benign neoplasm, was first described by Granter et al. in 1998 [1]. In the initial series, the 7 reported cases were located in the subcutaneous and superficial soft tissue of distal extremities. The clinical presentation in all cases was fairly innocuous and was that of a painless firm nodule. In addition to occurring in subcutaneous and soft tissues, myopericytomas can occur superficially, involving only the dermis. The

Jag Bhawan, MD
Dermatopathology Section, Department of Dermatology
Boston University School of Medicine, 609 Albany St, J-301
Boston, MA 02118 (USA)
E-Mail jbhawan@bu.edu

largest series of ‘cutaneous myopericytoma’ was reported by Mentzel et al. [2]. In this series, the authors described a total of 54 cases of which 26 were cutaneous myopericytomas, including 20 cases confined to the dermis and 6 cases showing subcutaneous extension. The clinical presentation, as in its soft tissue counterpart, was not distinct, with the lesions presenting predominantly as slowly enlarging, painless nodules.

‘Cutaneous myopericytoma’ usually presents as a solitary lesion, although multiple lesions can occur [2–7]. Three cases reportedly occurred in an area of prior trauma [5, 7]. Most cases of myopericytoma behave in a benign fashion, with recurrence being uncommon despite incomplete excision. In the study of ‘cutaneous myopericytomas’ by Mentzel et al. [2], despite marginal or incomplete excision in 50%, only 2 neoplasms (1 malignant and 1 intravascular myopericytoma) recurred locally (within 1 and 4 years, respectively).

Histopathologically, myopericytoma is characterized by a well-circumscribed, unencapsulated nodular proliferation with numerous thin-walled vessels and a concentric, perivascular arrangement of ovoid spindle-shaped myopericytes in the dermis, subcutis or soft tissues [2]. Mitotic activity and cytologic atypia are usually minimal. However, a rare atypical/malignant variant histologically characterized by high cellularity, significant mitotic activity, pleomorphism, necrosis, and metastasis has been reported [2, 8]. Immunohistochemically, all cases express α -smooth muscle actin (SMA) and most also express h-caldesmon (90%) [2].

We present 3 patients with cutaneous myopericytoma, one of which resembled a verruca, expanding the clinical spectrum of this uncommon benign neoplasm, and review its histopathologic features.

Case Report

Case 1

A 77-year-old man presented with a 4-mm, flesh-colored papule on his scalp. The clinical diagnosis was a cyst. Histopathologic examination of a shave biopsy revealed a well-circumscribed, dermal proliferation of plump, spindled myoid cells arranged concentrically around vessels (fig. 1A, B). Cytologic atypia and mitoses were absent. Immunohistochemical stains revealed patchy and weak staining of the lesional cells with SMA (fig. 1C) and h-caldesmon, and negative staining with S100 protein, Mart-1/Melan A, EMA, CD31, and CD34.

Case 2

A 45-year-old female presented with a scaly keratotic papule on her left dorsal wrist. The clinical impression was squamous cell carcinoma versus prurigo nodule. Histopathologic examination of a shave biopsy revealed hemorrhagic scale crust, papillomatous epidermal hyperplasia with hypergranulosis, and an underlying ill-defined proliferation of uniform, ovoid, spindled cells arranged in short fascicles around blood vessels in the superficial dermis (fig. 1D, E). Cytologic atypia and mitoses were absent. Immunohistochemical stains revealed diffuse and strong staining of the lesional cells with SMA (fig. 1F) and h-caldesmon, and negative staining with S100 protein, Mart-1/Melan A, EMA, CD31, and CD34.

Case 3

A 66-year-old female presented with a papule on the left heel. Histopathologic examination of a punch biopsy revealed an ill-circumscribed proliferation of plump, spindled to round cells closely surrounding numerous dilated and branching endothelial cell-lined vessels (fig. 1G, H). Cytologic atypia and mitoses were absent. Immunohistochemical stains revealed focal positive staining of the lesional cells with SMA (fig. 1I) and negative staining with S100 protein, desmin, h-caldesmon, pancytokeratin, CD31, and CD34.

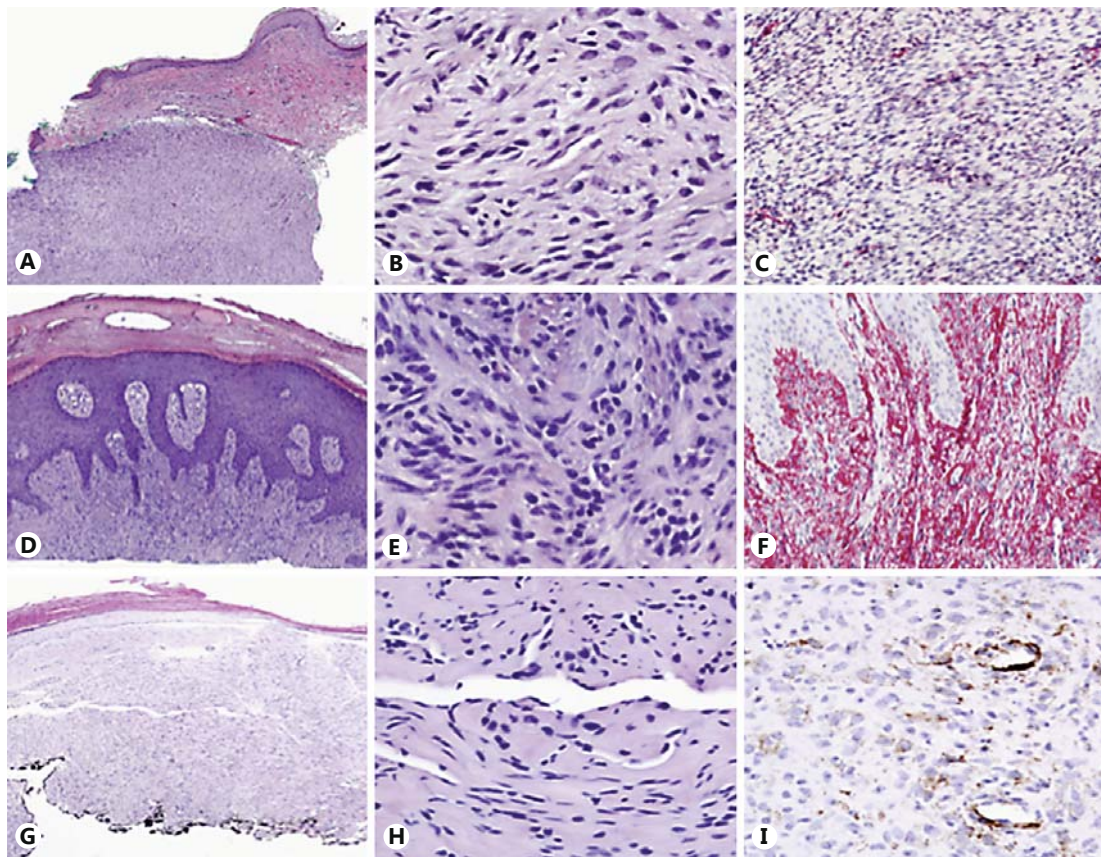


Fig. 1. **A–C** Representative figures of case 1. **A, B** A well-circumscribed, superficial dermal proliferation of plump, spindled myoid cells arranged concentrically around vessels. **A** HE. $\times 4$. **B** HE. $\times 20$. **C** A patchy and weak immunohistochemical staining of the lesional cells with SMA. $\times 10$. **D–F** Case 2. **D, E** An ill-defined proliferation of uniformly, ovoid, spindled cells arranged in short fascicles around blood vessels in the superficial dermis. **D** HE. $\times 4$. **E** HE. $\times 20$. **F** A diffuse and strong immunohistochemical staining of the lesional cells with SMA. $\times 10$. **G–I** Case 3. **G, H** An ill-circumscribed proliferation of plump, spindled to round cells closely surrounding numerous dilated and branching endothelial cell-lined vessels. **G** HE. $\times 4$. **H** HE. $\times 20$. **I** A focal and weak immunohistochemical staining of the lesional cells with SMA. $\times 20$.

Discussion

The term ‘myopericyte’, coined by Dictor et al. [9], was used to denote ‘atypical pericytes surrounded by bundles of sclerotic smooth muscle abutting on staghorn vessels’ that formed the predominant cell type in an unusual case of metastasizing ‘myofibromatosis-like heman-giopericytoma’ in a young boy. The authors emphasized that the myopericyte represents a transitional cell form between pericytes and vascular smooth muscle cells [9]. Candidates for the progenitor cell of origin for the myopericyte include the myofibroblast or the pericyte, both of which exhibit properties of modified smooth muscle cells [6]. The myofibroblast is a spindle-shaped cell with an elongated nucleus and pale eosinophilic cytoplasm that usually shows a desmin-negative, actin-positive immunohistochemical phenotype. The pericyte is suggested as a pluripotential resting stem cell, and differentiation of pericytes into myofibroblasts and smooth muscle cells has been documented [6, 10].

We searched in PubMed using the terms ‘cutaneous myopericytomas’ and ‘intravascular myopericytomas’ and found a total of 13 different reports describing 45 cases. A limitation of

this approach is that cases of myopericytomas that have been reported under different terminologies in the past are not included in our review. The typical clinical and histopathologic findings of the reported cutaneous myopericytomas is listed in table 1 [2, 4–7, 11–18]. Most patients were male (male:female = 1.5:1), and patient age ranged from 13 to 87 years (median = 47 years). Although some lesions were painful, most were asymptomatic. The lower extremities were most commonly affected (37 cases), followed by the upper extremities (18 cases), the head and neck region (9 cases), and the trunk (2 cases). Most lesions were solitary, although 5 were multiple, either in single or multiple anatomic locations. All lesions were grossly nodular, firm gray-white or hemorrhagic red-brown lesions. In the majority of the cases, the lesions were confined to the dermis and superficial parts of the subcutis. Nine cases arose within a vessel showing an attachment to the vessel wall [2, 11, 14, 17, 18], and 3 cases developed in a scar or previously traumatized area [5, 7].

Histologically, most lesions were well-circumscribed nodular neoplasms, with the exception of 3 that had ill-defined borders and an infiltrative pattern. All lesions contained numerous thin-walled blood vessels and ovoid, plump, spindle-shaped, and/or round myoid lesional cells with eosinophilic cytoplasm and spindle-shaped or round nuclei exhibiting a concentric perivascular growth pattern. In addition to the classic solid nodular pattern, other morphologic patterns may be seen in myopericytoma including hemangiopericytoma-like (numerous thin-walled, dilated, and branching vessels), angioleiomyoma-like (perivascular bundles of elongated and spindle-shaped cells), cutaneous myofibroma-like (ill-defined dermal infiltrate), hypocellular fibroma-like (low cellularity in a prominent collagenous stroma), and glomoid (round lesional cells with uniform nuclei) myopericytomas [2]. Rare malignant myopericytoma, in addition to having a clinically aggressive course, histologically revealed infiltrative growth, prominent cytologic atypia, increased mitotic activity, necrosis [60% (3/5) of patients] and metastases [80% (4/5) of patients] [2, 8].

Myopericytes are usually positive for SMA and frequently positive for h-caldesmon, but negative for markers indicative of definitive smooth muscle differentiation such as desmin. Some authors prefer the term 'modified smooth muscle cell' for the myopericyte. Our cases were positive for SMA (3/3) and h-caldesmon (2/3), consistent with the previous reported immunohistochemical findings in this entity [2].

The patients in our case series exhibited unusual clinical findings. All were female, despite the known male predominance of this entity [2]. Two presented on the extremities, a typical site, while 1 occurred in the scalp, the first lesion to be reported from this location. One presented as a scaly keratotic nodule, which histologically demonstrated overlying verruca-like changes. The histopathologic features in our cases were typical for cutaneous myopericytoma except for 2 cases with an ill-circumscribed proliferation. They were unencapsulated benign neoplasms with numerous thin-walled vessels and a concentric, perivascular arrangement of ovoid spindle-shaped myopericytes in the dermis, with no mitotic activity or cytologic atypia.

Despite overlapping morphologic features with other myofibroblast lineage-related lesions, myopericytoma is a distinct perivascular myoid neoplasm arising predominantly in the superficial tissues of the extremities of adult patients with a benign clinical course [2]. The differential diagnosis of myopericytoma is broad and includes other neoplasms composed of myopericytes such as myofibroma/myofibromatosis, angioleiomyoma, perivascular epithelioid neoplasm, and glomus tumor, as well as entities characterized by a vascular and/or spindle cell proliferation.

The biologic behavior of most cutaneous myopericytomas is benign, with minimal recurrence following excision [2, 4–7, 11–18]. Of the 45 cases published in the literature, only 2 recurred. All of our tumors were completely excised, and have not recurred to date with 6–48 months of follow-up.

Table 1. Cases of cutaneous myopericytoma reported to date

Study	Cases, n	Gender	Age, years	Site	Clinical presentation	Clinical impression	Lesions	Size, mm	Histopathologic features	Positive immunohistochemistry	Local recurrence (follow-up period)
McMenamin and Calonje [11]	1	male	54	LE	PN	angioleiomyoma, angiolipoma, glomus/adnexal tumor	S	15	CPVP of spindled myoid cells, numerous vascular channels, located intravascularly	SMA, CD34 focal	unknown
Mimami et al. [12]	1	female	61	UE	AN	unknown	S	20	CPVP of ovoid spindle cells, numerous vascular channels, rare mitosis	SMA	unknown
Mentzel et al. [2]	26/54	unknown	13–87	LE > UE > H&N > trunk	unknown	unknown	S S2, multiple 2	unknown	CPVP of ovoid, plump, spindled myoid cells, numerous vascular channels, intravascular location (5), cytologic atypia (1), mitosis (1 with >3/10 hpf)	SMA 32/32, h-caldesmon 29/32, desmin 3/33 focal	intravascular 1 in 2 years, malignant 1 in 1 year (0.5–14 years)
Dray et al. [6]	7	4 male, 3 female	13–71	LE	AN 5, PN 2	unknown	S 6, multiple 1	11–30	CPVP of bland, round, ovoid myopericytes, numerous vascular channels, mitosis (1 with <1/10 hpf)	SMA 7/7, desmin 2/7 patchy	no recurrence(0.1–5 years)
Scott et al. [7]	1	female	58	LE	AN	DFSP, pilomatricoma, calcinosis cutis	multiple	20–90	CPVP of spindled, round myoid cells, numerous vascular channels	SMA focal	unknown
Woolard et al. [18]	1	male	63	UE	AN	unknown	S	10	CPVP of ovoid myoid cells capsulated by collagenous fibers, numerous vascular channels, located intravascularly	unknown	unknown
Laga et al. [5]	2	1 male, 1 female	64, 72	H&N	AN	PG, granuloma, peripheral ossifying fibroma, SCC	multiple, S	3–15	CPVP of bland, spindled myopericytes	SMA, calponin	no recurrence (1.5 years)
Terrada [13]	1	female	56	H&N	AN	unknown	S	3	CPVP of ovoid myoid cells encased by a fibrous capsule, numerous vascular channels, mitosis (3/50 hpf)	SMA, h-caldesmon, Ki67 8%	no recurrence (2 years)
Park et al. [14]	1	female	79	H&N	AN	epidermal cyst	S	12	CPVP of ovoid myoid cells completely lying within an expanded vessel, numerous blood vessels at periphery of the lesion, located intravascularly	SMA	unknown
Numata et al. [15]	1	male	59	H&N	AN	unknown	S	40	CPVP of round, ovoid myoid cells, numerous branching vessels	SMA, MSA, vimentin, Ki67 <3%	stable in size without excision
Paek et al. [16]	1	female	45	LE	AN	epidermal cyst, pilomatricoma calcinosis cutis	S	90	CPVP of spindled myoid cells, numerous vascular channels	SMA	unknown
Ko et al. [17]	1	male	67	LE	PN	unknown	S	35	CPVP of spindled myoid cells, numerous vascular channels, located intravascularly	SMA, CD34 focal	unknown
Jung et al. [4]	1	female	40	H&N	AN	unknown	S	20, 2	CPVP of ovoid myoid cells capsulated by collagenous fibers, numerous vascular channels	SMA	recurrent/2nd primary in 8 years after excision
Aung et al., current report	3	female	45–77	H&N, UE, LE	AN 2, VV 1	SCC, cyst, prurigo nodularis, unknown	S	4, 2, unknown	CPVP of spindled, round cells, numerous branching vascular channels, an overlying hemorrhagic scale crust, papillomatous epidermal hyperplasia 1/3	SMA focal	no recurrence (0.5–4 years)

LE = Lower extremities; UE = upper extremities; H&N = head and neck; PN = painful nodule; AN = asymptomatic nodule; VV = verruca vulgaris; DFSP = dermatofibrosarcoma protuberans; PG = pyogenic granuloma; SCC = squamous cell carcinoma; S = solitary; CPVP = concentric perivascular proliferation; hpf = high-power field; MSA = muscle-specific actin.

Cutaneous myopericytoma is a rarely reported neoplasm in the literature. We add 3 cases to the literature, all in women, including 1 with unusual overlying verrucous epidermal hyperplasia.

Disclosure Statement

The authors have no conflict of interest to declare.

References

- 1 Granter SR, Badizadegan K, Fletcher CD: Myofibromatosis in adults, glomangiopericytoma, and myopericytoma: a spectrum of tumors showing perivascular myoid differentiation. *Am J Surg Pathol* 1998;22:513–525.
- 2 Mentzel T, Dei Tos AP, Sapi Z, et al: Myopericytoma of skin and soft tissues: clinicopathologic and immunohistochemical study of 54 cases. *Am J Surg Pathol* 2006;30:104–113.
- 3 Song XL, Sun XY, Zhang GL, et al: Myopericytoma presenting as multiple pulmonary nodules. *Intern Med* 2012;51:639–642.
- 4 Jung YI, Chung YK, Chung S: Multiple myopericytoma of the face and parotid gland. *Arch Plast Surg* 2012;39:158–161.
- 5 Laga AC, Tajirian AL, Islam MN, et al: Myopericytoma: report of two cases associated with trauma. *J Cutan Pathol* 2008;35:866–870.
- 6 Dray MS, McCarthy SW, Palmer AA, et al: Myopericytoma: a unifying term for a spectrum of tumors that show overlapping features with myofibroma. A review of 14 cases. *J Clin Pathol* 2006;59:67–73.
- 7 Scott RS, Blank KL, Proffer LH, et al: Perivascular myoma of myopericytoma and myofibromatosis-type arising in a chronic scar. *J Cutan Pathol* 2006;33:231–235.
- 8 McMenamin ME, Fletcher CD: Malignant myopericytoma: expanding the spectrum of tumours with myopericytic differentiation. *Histopathol* 2002;41:450–460.
- 9 Dictor M, Elnér A, Andersson T, et al: Myofibromatosis-like hemangiopericytoma metastasizing as differentiated vascular smooth-muscle and myosarcoma: myopericytes as a subset of ‘myofibroblasts’. *Am J Surg Pathol* 1992;16:1239.
- 10 Requena L, Kutzner H, Hugel H, et al: Cutaneous adult myofibroma: a vascular neoplasm. *J Cutan Pathol* 1996;23:445–447.
- 11 McMenamin ME, Calonje E: Intravascular myopericytoma. *J Cutan Pathol* 2002;29:557–561.
- 12 Mimami Y, Shiomi T, Manaba T: Perivascular myoma: case report and immunohistochemical and ultrastructural studies. *Pathol Int* 2002;52:69–74.
- 13 Terada T: Minute myopericytoma of the neck: a case report with literature review and differential diagnosis. *Pathol Oncol Res* 2010;16:613–616.
- 14 Park HJ, Lee DR, Park MY, et al: A case of intravascular myopericytoma. *J Clin Pathol* 2010;63:847–848.
- 15 Numata I, Nakagawa S, Hasegawa S, et al: A myopericytoma of the nose. *Acta Derm Venereol* 2010;90:192–193.
- 16 Paek JO, Kang HS, Yeo KY, et al: A case of myopericytoma on the lower leg. *Ann Dermatol* 2011;23:201–204.
- 17 Ko JY, Choi WJ, Kang HS, et al: Intravascular myopericytoma: an interesting case of a long-standing large, painful subcutaneous tumor. *Pathol Int* 2011;61:161–164.
- 18 Woollard AC, Southgate C, Blair JW: Intravascular myopericytoma of the superficial palmar arch. *J Hand Surg Eur* 2007;32:475.