

Xanthogranulomatous Cholecystitis and Misdiagnosis Analysis

Ya-Qiang Li¹, Jian Song¹, Zheng-Xin Liu¹, Dong-Yuan Xie¹, Tao Jiang², Guang-Hui Wei³, Hua-Chong Ma³, Jian-Xin Wang¹, Mu-Lan Jin⁴

¹Department of Gastroenterology, Beijing Chao-Yang Hospital, Capital Medical University, Beijing 100020, China

²Department of Radiology, Beijing Chao-Yang Hospital, Capital Medical University, Beijing 100020, China

³Department of General Surgery, Beijing Chao-Yang Hospital, Capital Medical University, Beijing 100020, China

⁴Department of Pathology, Beijing Chao-Yang Hospital, Capital Medical University, Beijing 100020, China

Key words: Xanthogranulomatous Cholecystitis; Gastric Sub-epithelial Masses; Gastrointestinal Stromal Tumor

INTRODUCTION

Gastric sub-epithelial masses (SEMs) are relatively common findings when receiving gastric endoscopy. It is a mass, bulge, or impression visible. Computed tomography (CT) and magnetic resonance imaging can assist in making a diagnosis, but the final diagnosis depends on histopathological examination. Gastrointestinal stromal tumor (GIST) is a relatively frequent mesenchymal tumor of the gastrointestinal tract. Xanthogranulomatous cholecystitis (XGC) is a benign, chronic inflammatory disease of the gallbladder. Acute inflammation of the gallbladder and calculous outflow obstruction are two main pathogenetic mechanisms. The gallbladder wall may appear irregular and thickened, with adhesions to surrounding tissue, and fistulas may develop into adjacent organs. In this case, because of the XGC, the gallbladder was perforated and adhered to the gastric wall, resulting in misdiagnosing as GIST.

MISDIAGNOSIS ANALYSIS

A 63-year-old man complained of upper abdominal pain for 20 days then was admitted to our department. His pain was getting more and more serious after meals and no obvious radiating pain to the back. No fever, no nausea, no vomiting, no diarrhea, and melena were reported. Then he went to the local hospital, where he was given omeprazole and other acid-inhibitory drugs. His symptoms got better slightly but still existed. For further treatment, the patient came to our hospital. Physical examinations showed no singular findings. Laboratory parameters lists are as below: White blood cell $10.4 \times 10^9/L$, NE% 74.4%, hemoglobin 142.0 g/L. Biochemical test aspartate aminotransferase 44 U/L, alanine

aminotransferase 53 U/L, alkaline phosphatase 194 U/L, gamma glutamyl transpeptidase 328 U/L, total bilirubin 7.0 $\mu\text{mol/L}$, direct bilirubin 1.22 $\mu\text{mol/L}$. Gastroscopy showed obvious deformation of antrum, and there are spherical protrusion lesions about 6 cm \times 6 cm and its together with ulcer formed at top [Figure 1]. An enhanced CT examination was performed as well. The result is that antrum gastric wall was thickened; the gallbladder was enlarged with the thickening wall and exudation around but without positive stones. The gallbladder has obvious line enhancement. In order to make the diagnosis clear, an exploratory laparotomy was arranged in the hospital. During the operation, the oppression of antrum was found from lateral mass which was the swelling of the gallbladder surrounded by omental tissue, about 8 cm \times 7 cm \times 6 cm. The stomach became soft without thickening after separating the adhesion between antrum and bladder. Because of cholecystitis with perforation, the gallbladder was removed at the same time, and it was confirmed by biopsy [Figure 2]. Gastroscopy was done again to confirm the oppression from out of the stomach. The final diagnosis of the case is XGC. The patient was successfully discharged a few days later. Followed up to the moment when we write a paper, the patient had no upper abdominal pain and unusual symptoms.

DISCUSSION

Sub-epithelial mass lesions in the stomach are relatively common findings in patients undergoing gastric endoscopy. The endoscopic appearance of a sub-epithelial lesion in the stomach is that of the mass, bulge, or impression visible within the gastric lumen that is covered with normal-appearing epithelium. The frequency of finding these lesions is likely to vary according to the size and location of the mass, as well as the care taken during the endoscopic examination.^[1] There are no recent studies that have identified the prevalence of gastric SEMs on a population basis. The evaluation of

Access this article online

Quick Response Code:



Website:
www.cmj.org

DOI:
10.4103/0366-6999.158384

Address for correspondence: Prof. Zheng-Xin Liu,
Department of Gastroenterology, Beijing Chao-Yang Hospital,
Capital Medical University, Beijing 100020, China
E-Mail: liuzhengx2003@vip.sina.com

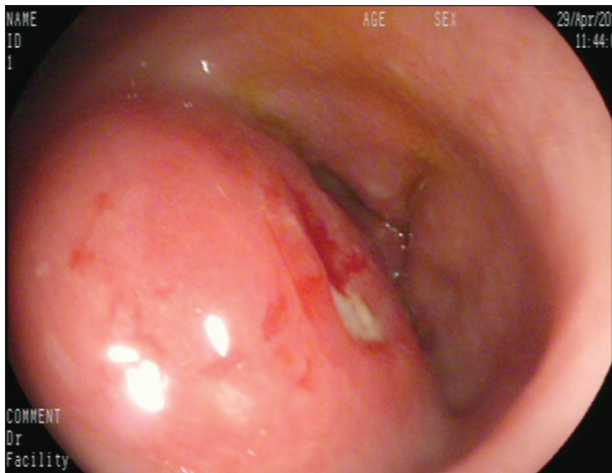

Figure 1: Gastroscopy-deformation of sinuses ventriculi, spherical protrusion lesions about 6 cm × 6 cm, the surrounding mucosa is smooth, with small ulcer formed on the top (EG-2990i-70).

SEMs begins with the initial endoscopy. The final diagnosis depends on histopathological examination. Endoscopic resection, endoscopic ultrasonography (EUS)-guided fine-needle aspirations (FNAs), EUS-guided core needle biopsy are necessarily required. EUS-FNA-based cytology is safe and has only limited value for the differential diagnosis of submucosal tumors.^[2] To harvest sufficient material, it is necessary for us to have an exploratory laparotomy. Differential diagnoses of sub-epithelial gastric masses include benign and malignant. GIST is a relatively frequent mesenchymal tumor of the gastrointestinal tract with an annual incidence estimated at 10–20/million.^[3] GIST is usually found incidentally by endoscopy or radiographic examinations, in 4%–39% of cases.^[4] The clinical manifestation of GIST is variable. Endoscopy shows the characteristic of SEMs including hemispherical apophysis with or without bridging fold. If the diameter is more than 6 cm, the tumors are usually accompanied by central necrosis.^[4] EUS plays a crucial role in diagnosis. EUS shows low echo and homogeneous mostly located muscle layer, but inhomogeneous, choice or high echo when tumors are possibly malignant.^[5] The therapy depends on the histology. The highly curative option is surgical resection including open or laparoscopic surgery.^[6]

For this case, endoscopy result corresponds to the characteristic of GIST, and endoscopic doctor advised patient to accept EUS that could cooperate FNA necessarily but rejected. Hence, the patient chose to receive CT examination. The CT results suggested cholecystitis, thickening of the gastric wall, but not found a relationship between gallbladder and stomach. Then the patient accepted exploratory laparotomy to make a definitive diagnosis. It was surprising that the obvious deformation of antrum come from the oppression of the gallbladder. The gallbladder disease called XGC, with perforation and involve to the stomach wall.

Xanthogranulomatous cholecystitis is a benign, chronic inflammatory disease of the gallbladder consisting of multiple

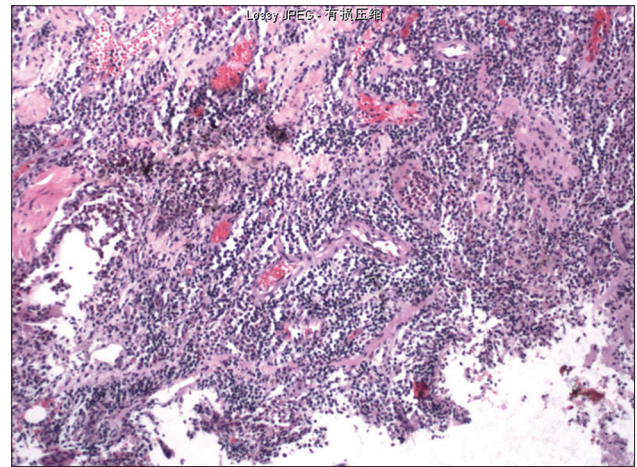


Figure 2: Gallbladder epithelium are most erosion, the formation of granulation tissue, massive infiltration of lymphocytes, plasma cells, and numerous foamy phagocytic cell aggregation within the stroma, mucous glands, vascular dilatation, and hemorrhage can be visibly seen in muscle layer. Diagnosis xanthogranulomatous cholecystitis (periodic acid-Schiff staining, original magnification ×200).

yellow-brown intramural nodules that are characterized by extensive fibrosis and foam cells.^[7] Chronic right upper quadrant pain is the most common clinical presentation, it is similar to acute and chronic cholecystitis.^[8] The disease XGC accounts for only 0.7%–13.2% of all inflammatory disease of the gallbladder, usually observed in the sixth to seventh decade in life, primarily in women. It is difficult to diagnose XGC preoperatively or intra-operatively, and the definitive diagnosis depends exclusively on pathologic examination.^[9] The gallbladder wall may appear irregular and thickened, with adhesions to surrounding tissue, and fistulas may develop into adjacent organs, and in some cases, can cause Mirizzi syndrome.^[10] Zhao *et al.* reported that 40% cases had an early enhancement of liver parenchyma. Infiltration to other surrounding tissues included bowel ($n = 3$), stomach ($n = 2$), and abdominal wall ($n = 1$).^[11] The incidence of gallbladder carcinoma associated with XGC was the lowest in European studies (3.3%) varying from 5.1% to 5.9% in the remaining regions. Alvi *et al.* reported that laparoscopic cholecystectomy was carried out with a high conversion rate to improve the safety of the operation.^[12] Intra-operative frozen section may be required for definitive diagnosis of XGC.^[9] It is difficult to diagnose XGC preoperatively or intra-operatively, and the definitive diagnosis depends exclusively on pathologic examination.^[12]

In conclusion, we must take warning and avoid misdiagnosis happening again. First, each endoscopic technologist must have abundant experience to identify the SEM. When highly suspecting patients with GIST tumor or unable to identify as soon as possible, EUS and FNA examination are required to confirm the diagnosis. Second, patients' psychological status will affect the whole process of diagnosis and treatment. Full communication clinicians are particularly important. It is difficult to diagnose XGC preoperatively or intra-operatively, even if accepting CT examination. The definitive diagnosis

depends exclusively on pathologic. What you have seen is not necessarily the truth. We also realized the diagnosis is closely related to the multi-disciplinary co-operation.

REFERENCES

1. Hwang JH, Rulyak SD, Kimmey MB, American Gastroenterological Association Institute. American Gastroenterological Association Institute technical review on the management of gastric subepithelial masses. *Gastroenterology* 2006;130:2217-28.
2. Philipper M, Hollerbach S, Gabbert HE, Heikaus S, Böcking A, Pomjanski N, *et al.* Prospective comparison of endoscopic ultrasound-guided fine-needle aspiration and surgical histology in upper gastrointestinal submucosal tumors. *Endoscopy* 2010;42:300-5.
3. Beham AW, Schaefer IM, Schüler P, Cameron S, Ghadimi BM. Gastrointestinal stromal tumors. *Int J Colorectal Dis* 2012;27:689-700.
4. Correa-Cote J, Morales-Uribe C, Sanabria A. Laparoscopic management of gastric gastrointestinal stromal tumors. *World J Gastrointest Endosc* 2014;6:296-303.
5. Nishida T, Kawai N, Yamaguchi S, Nishida Y. Submucosal tumors: Comprehensive guide for the diagnosis and therapy of gastrointestinal submucosal tumors. *Dig Endosc* 2013;25:479-89.
6. Demetri GD, von Mehren M, Antonescu CR, DeMatteo RP, Ganjoo KN, Maki RG, *et al.* NCCN Task Force report: Update on the management of patients with gastrointestinal stromal tumors. *J Natl Compr Canc Netw* 2010;8 Suppl 2:S1-41.
7. Ueda J, Yoshida H, Arima Y, Mamada Y, Tani N, Mineta S, *et al.* A case of xanthogranulomatous cholecystitis preoperatively diagnosed with contrast-enhanced ultrasonography. *J Nippon Med Sch* 2011;78:194-8.
8. Jetley S, Rana S, Khan RN, Jairajpuri ZS. Xanthogranulomatous cholecystitis – A diagnostic challenge. *J Indian Med Assoc* 2012;110:833-7.
9. Yabanoglu H, Aydogan C, Karakayali F, Moray G, Haberal M. Diagnosis and treatment of xanthogranulomatous cholecystitis. *Eur Rev Med Pharmacol Sci* 2014;18:1170-5.
10. Yang T, Zhang BH, Zhang J, Zhang YJ, Jiang XQ, Wu MC. Surgical treatment of xanthogranulomatous cholecystitis: Experience in 33 cases. *Hepatobiliary Pancreat Dis Int* 2007;6:504-8.
11. Zhao F, Lu PX, Yan SX, Wang GF, Yuan J, Zhang SZ, *et al.* CT and MR features of xanthogranulomatous cholecystitis: An analysis of consecutive 49 cases. *Eur J Radiol* 2013;82:1391-7.
12. Alvi AR, Jalbani I, Murtaza G, Hameed A. Outcomes of Xanthogranulomatous cholecystitis in laparoscopic era: A retrospective Cohort study. *J Minim Access Surg* 2013;9:109-15.

Received: 26-11-2014 **Edited by:** De Wang

How to cite this article: Li YQ, Song J, Liu ZX, Xie DY, Jiang T, Wei GH, Ma HC, Wang JX, Jin ML. Xanthogranulomatous Cholecystitis and Misdiagnosis Analysis. *Chin Med J* 2015;128:1700-2.

Source of Support: Nil. **Conflict of Interest:** None declared.