



Prosthetic management of a growing patient with Russell-Silver syndrome: a clinical report

Kanghyun Kim, Kwantae Noh, Janghyun Paek, Kung-Rock Kwon, Ahran Pae*

Department of Prosthodontics, School of Dentistry, Kyung Hee University, Seoul, Republic of Korea

Russell-Silver syndrome (RSS) is a congenital disease characterized by short stature due to growth hormone deficiency, physical asymmetry, inverted triangular face, micrognathia, prominent forehead, and hypodontia. This case report presents a prosthetic management of a 6-year-old patient with Russell-Silver syndrome treated with overdentures on the maxilla and the mandible using the remaining primary teeth. Subsequent and comprehensive dental management considering the growth and development of a young patient will be necessary. [*J Adv Prosthodont 2015;7:406-10*]

KEY WORDS: Russell-Silver syndrome; Hypodontia; Overdenture; Early prosthetic rehabilitation

INTRODUCTION

Russell-Silver syndrome (RSS) is a dysplastic disease mainly showing delayed growth, distinctive craniofacial features, and common physical asymmetry.¹ Clinical symptoms involve low birth weight, continued poor growth, low muscle tone, a variety of psychomotor impairments, and irregular craniofacial characteristics.^{2,3} The craniofacial characteristics of the RSS are inverted triangular face, prominent forehead, decreased lower facial height, mouth with downturned corners, micrognathia, ear anomalies, abnormal shape of the teeth, and hypodontia.^{4,5} The prevalence rate reported is from 1:3000 to 1:100 000.⁶ Patients with this syndrome commonly do not have any mental problems, therefore, this specific consideration may not be required during oral management and preventive treatment.

Abnormal appearance and hypodontia, which are major clinical symptoms of RSS, may have adverse effects on the social behavior of the patient. Therefore, oral rehabilitation

is necessary for the patient to have similar appearance and function of his/her peers.

Hypodontia is attributed to craniofacial dysplasia of the RSS population, which results in the differing cranial base measurements and mandibular length.^{7,8} Decision-making and interdisciplinary management of the RSS patient with orthodontics or prosthodontics is recommended to improve both the sagittal and vertical skeletal relationship during craniofacial growth and development, as well as to provide improvements in esthetics, speech, and masticatory efficiency.⁹ Patients with RSS can be provided with prosthetic treatment options such as complete dentures, partial removable dental prostheses, partial fixed dental prostheses, and dental implants. This case report presents the early prosthetic oral rehabilitation of a young patient with RSS showing severe hypodontia in the primary dentition.

CLINICAL PRESENTATION

A 6-year-old boy with RSS was referred to the Department of Prosthodontics, School of Dentistry, Kyung Hee University from the Department of Pedodontics for prosthetic management. The main concern of the patient and his parents was deficient masticatory function due to hypodontia and severe dental caries. The medical history and records revealed the occurrence of RSS. Both of the second primary molars, primary canines, primary central incisors, the left lateral incisor, and the left first primary molar of the maxilla, both of the primary central incisors, primary lateral incisors, and the right primary canine of the mandible were remaining with dental caries at the initial intraoral examina-

Corresponding author:
Ahran Pae
Department of Prosthodontics, School of Dentistry, Kyung Hee University
23 Kyung Hee Dae-ro, Seoul 02447, Republic of Korea
Tel. 82 2 958 9340; e-mail, ahranp@khu.ac.kr
Received July 22, 2015 / Last Revision October 1, 2015 / Accepted
October 2, 2015

© 2015 The Korean Academy of Prosthodontics
This is an Open Access article distributed under the terms of the Creative Commons Attribution Non-Commercial License (<http://creativecommons.org/licenses/by-nc/3.0>) which permits unrestricted non-commercial use, distribution, and reproduction in any medium, provided the original work is properly cited.

tion (Fig. 1). Clinical examination showed short lower anterior facial height, downturned corners of the mouth, micrognathia, and decreased occlusal vertical dimension (OVD) due to missing posterior teeth (Fig. 2).

Problems of the patient were as follows; severe dental caries and loss of multiple teeth, underdevelopment of the alveolar bone, masticatory and speech difficulties, and abnormal facial profile. Besides the functional and esthetic aspects, the ongoing growth and economic state of the patient needed consideration with the treatment plan. Thus, overdentures retained by natural primary teeth, which can offer minimal tooth reduction, preserve the alveolar bone, and are easy to modify as growth occurs, were chosen as the optimal treatment plan for the patient.

Fabrication of an overdenture retained by the natural primary teeth for the maxilla and an overdenture supported by the natural roots for the mandible were planned. Before fabrication of trial dentures was carried out, both maxillary primary central incisors, left primary lateral incisor, left primary canine, left primary first molar, and mandibular left primary lateral incisor with severe root caries were extracted (Fig. 3). Endodontic treatment followed by reduction of the crown portion was performed on the mandibular primary anterior teeth due to severe dental caries.

Concerning the determination of the OVD, balance of the lower third facial appearance, lip support, harmony between the lower lip and the chin, phonetics, and swallowing were evaluated with wax occlusion rims.^{10,11} Arrangement of the prosthetic teeth was carried out considering the location of the residual primary teeth and anatomical landmarks. Procedures for the fabrication of trial dentures followed that for a conventional definitive denture fabrication technique.

The patient was instructed to use the trial dentures for two months. After placement of the trial dentures and two weeks of adjustment and modification, the patient became well-adjusted to the dentures. He expressed no functional problems with the new OVD during the two months of the trial phase, and was satisfied with the improvement of his appearance.

Cephalometric measurement values before placement of the trial dentures presented increased facial axis, increased facial depth, decreased lower facial height angle, decreased mandibular plane angle, and increased mandibular arc. The ANS-Me/N-Me ratio, which shows the ratio of the lower facial height (anterior nasal spine-menton) to the total facial height (nasion-menton) was decreased, displaying reduced lower facial height before placement of the

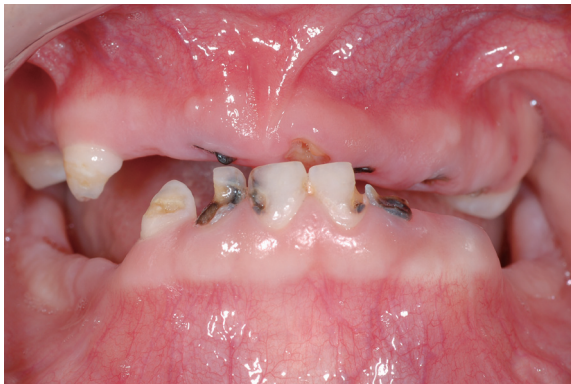

Fig. 1. Pretreatment intraoral frontal view. Severe dental caries and multiple loss of primary teeth were presented.

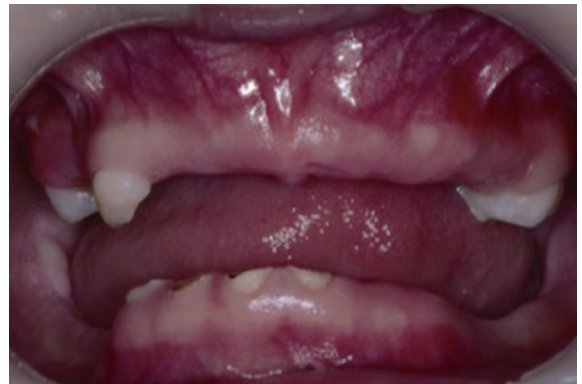

Fig. 3. Postextraction intraoral frontal view.

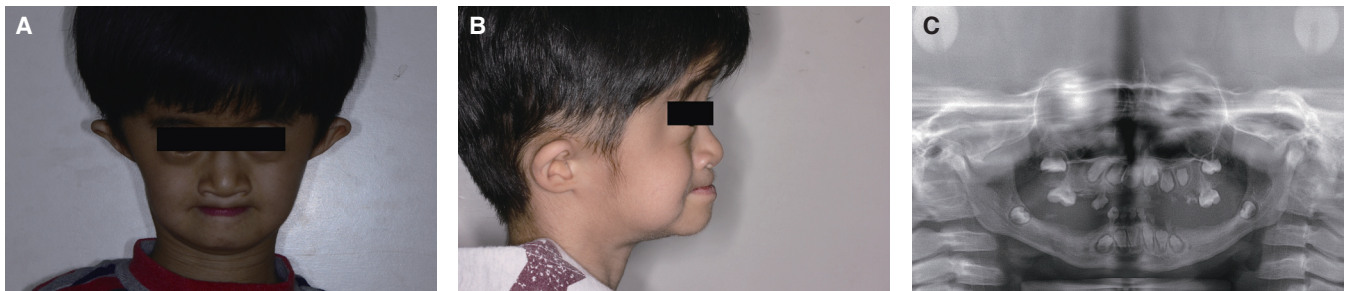

Fig. 2. Pretreatment (A) extraoral frontal view, (B) extraoral lateral view, and (C) panoramic view. Typical craniofacial characteristics of RSS patient.

dentures. Post-treatment cephalometric measurement values with the provisional dentures were closer to that of average values corresponding to the patient's age than the pretreatment values (Table 1). Therefore, the OVD with the provisional dentures was considered to be optimal.

Border molding of the maxillary and mandibular arch was carried through with modeling plastic impression compound (Peri Compound, GC Co., Tokyo, Japan) and definitive impressions (Exafine, regular body; GC Co.) were made using customized individual trays (OSTRON100; GC Co.) for the fabrication of the definitive prostheses. Master casts were made with type IV gypsum material (Fujirock EP, GC America, Alsip, IL, USA) (Fig. 4).

Based on the evaluation of the undercuts of the maxillary cast with a surveyor, the primary teeth used as abutments did not need tooth preparation because of the characteristics of the primary teeth having their height of contour on the gingival third. After the impression was made,

the verified OVD of the trial dentures was incorporated into that of the final maxillomandibular relationship with a record bases and wax occlusion rims. The wax occlusion rim was evaluated intraorally for analysis of the OVD of the lower third of the patient's face, lip form, and lip support were re-evaluated. The maxillomandibular relationship was recorded and a facebow transfer (Hanau™ Spring-Bows, Whip Mix Corp., Louisville, KY, USA) was performed. The maxillary and mandibular definitive casts were mounted on a semi-adjustable articulator (Hanau Modular Articulator System; Whip Mix Corp).

Compared to the provisional dentures, characteristics of a young patient were emphasized on the definitive dentures. As regards the arrangement of prosthetic primary teeth (Resin Natural Teeth™, Nissin Dental Products Inc., Kyoto, Japan), developmental spaces of the primary dentition in the anterior area were made and prosthetic teeth were arranged vertically to the occlusal plane (Fig. 5). The occlu-

Table 1. Cephalometric measurements of patient compared with normal average values

Measurement	Before denture	After denture	Norm age 6
Facial axis (degrees)	95.5	87.5	90
Facial depth (degrees)	90.0	85.5	86
Mandibular plane (degrees)	20	29.5	27
Lower facial height (degrees)	43	48	47
Mandibular arc (degrees)	33	30.5	24.5
Convexity of point A (mm)	-3	+0.5	+3
ANS-Me/N-Me (%)	50.6	51.8	54.2

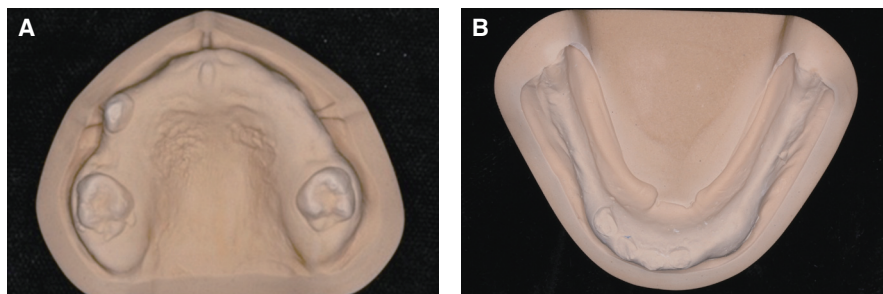


Fig. 4. Definitive cast after border molding and final impression making for (A) maxillary and (B) mandibular overdenture.

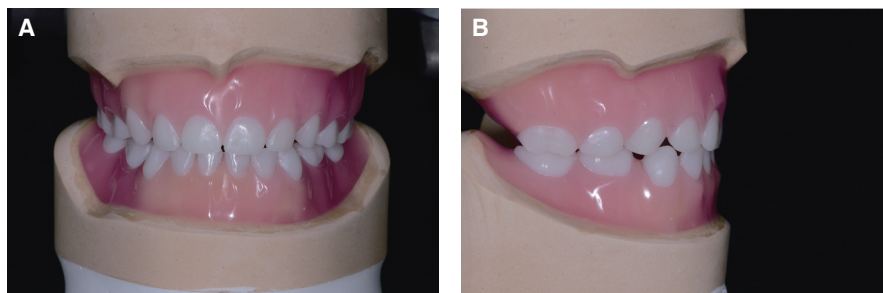


Fig. 5. Arrangement of prosthetic teeth on wax denture (A) with gingiva formation considering patient's young age, (B) developmental spaces, and tooth axis arranged vertical to occlusal plane.

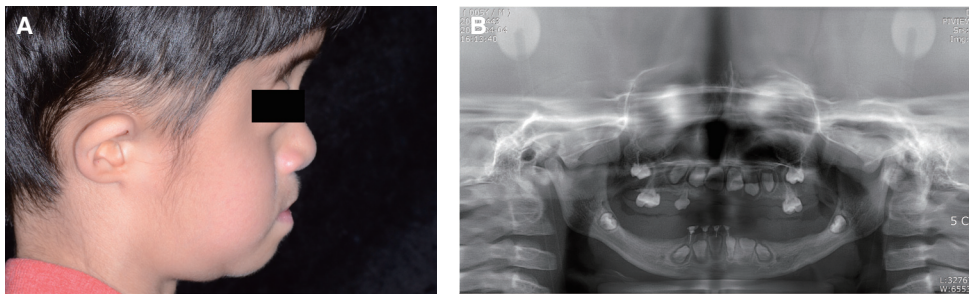


Fig. 6. Posttreatment (A) extraoral lateral view showing satisfactory esthetic results and (B) panoramic view with definitive prostheses.

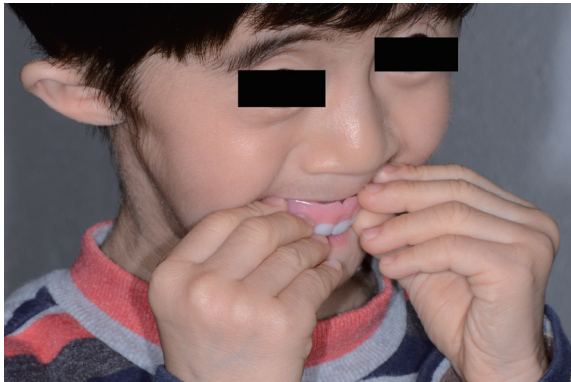

Fig. 7. Patient showing good adaptation to definitive prostheses.

sion was checked and adjusted to ensure the establishment of bilateral balanced occlusion. After clinical evaluation of the wax dentures, the definitive prostheses were heat polymerized with acrylic resin (Vertex Rapid Simplified, Vertex Dental, Zeist, Netherlands) and inserted.

The patient adapted to the definitive dentures with more ease than to the trial dentures. His mastication and speech with the dentures were improved significantly. He was also satisfied with his appearance with the dentures (Fig. 6). Although concerns of his wearing and maintaining the dentures himself still existed because of his young age, good denture stability, retention, and proper patient education indicated that he showed good adaptation to wearing dentures (Fig. 7).

DISCUSSION

Restoration leading to a natural and attractive appearance is important for the normal mental and future social development of RSS young patients. Prosthetic treatment methods using partial removable dental prostheses or dental implants are the primary treatment options for the prosthetic rehabilitation of these young patients with severe hypodontia. Hypodontia or total anodontia associated with RSS is often associated with underdeveloped alveolar ridges which bring

about less bone volume for the support of conventional removable dental prostheses or implant placement. When determining the most favorable prosthetic approach, the patient's age, dental and skeletal maturity, bone volume, and patient's cooperation must be considered. Therefore, partial removable dental prostheses sometimes can be a more advantageous option in growing patients than partial fixed dental prostheses because jaw growth necessitates prostheses adjustments. Whereas the establishment of lifetime dietary patterns and self-esteem develops during adolescence, early prosthetic rehabilitation is very important. Speech problems also have shown improvement after prosthetic rehabilitation with dentures has been achieved in young patients with severe hypodontia.¹²

Removable dental prostheses require follow-ups and management. They should be replaced or adjusted when decreased OVD or mandibular posture displacement are observed due to growth. Without dentures, the anterior-rotation of the mandible may cause an upward and forward displacement of the chin, leading to shortening of the lower third of the face and a Class III malocclusion tendency. With dentures, the mandible is rotated into a backward-downward position and the chin can maintain its normal position. Due to the growth and development of the patient, lack of occlusal contact of the posterior teeth may need to be managed by an addition of composite resin to the occlusal surface of the posterior denture teeth.

From the cephalometric evaluation done after the fabrication of dentures, the ANS-ME/N-Me ratio became closer to the average value, but still remained lower. Craniofacial characteristics of a RSS patient, such as, relative macrocephaly, micrognathia, and prominent forehead might explain the improved, but still low postoperative values of ANS-Me/N-Me ratio and convexity of point A.

Growth and development, and also the behavior management of the child need to be taken into consideration for early complete dentures. In these situations, the parents should be conscious of the possibility that young patients may refuse the treatment procedure or may not wear the dentures. Special attention is inevitable during clinical procedures as a result of the characteristics of the patient with RSS. For example, the small size of the arch requires cus-

tom trays for definitive impressions. Also, limitations in using anatomical landmarks for establishment of the occlusal plane due to asymmetry exist. In clinical reports of young patients with anodontia or ectodermal dysplasia, lack of occlusal contact of the posterior teeth and underextension of the denture flange were recurring problems.¹³ Removable dental prostheses with acrylic prosthetic teeth and autopolymerizing acrylic resin can provide solutions to these problems.^{14,15} It is important for young patients to be re-evaluated periodically. An exact visitation cycle has not been determined, however, 3-6 month recall appointments are recommended because repair and adjustment of the prostheses are required as the patient grows.

CONCLUSION

This case report underlines the importance of early prosthodontic rehabilitation of a young patient with RSS. In children with RSS, the presence of teeth plays an important role not only in function, but also in their social development and self-esteem. Prosthodontic treatment in these patients cannot be final and need periodic recall appointments to address growth and development.

ORCID

Kwantae Noh <http://orcid.org/0000-0003-3480-7737>

Janghyun Paek <http://orcid.org/0000-0002-1286-3140>

Ahran Pae <http://orcid.org/0000-0001-8758-0754>

REFERENCES

- Rossignol S, Netchine I, Le Bouc Y, Gicquel C. Epigenetics in Silver-Russell syndrome. *Best Pract Res Clin Endocrinol Metab* 2008;22:403-14.
- Silver HK, Kiyasu W, George J, Deamer WC. Syndrome of congenital hemihypertrophy, shortness of stature, and elevated urinary gonadotropins. *Pediatrics* 1953;12:368-76.
- Russell A. A syndrome of intra-uterine dwarfism recognizable at birth with cranio-facial dysostosis, disproportionately short arms, and other anomalies (5 examples). *Proc R Soc Med* 1954;47:1040-4.
- Tanner JM, Lejarraga H, Cameron N. The natural history of the Silver-Russell syndrome: a longitudinal study of thirty-nine cases. *Pediatr Res* 1975;9:611-23.
- Cassidy SB, Blonder O, Courtney VW, Ratzan SK, Carey DE. Russell-Silver syndrome and hypopituitarism. Patient report and literature review. *Am J Dis Child* 1986;140:155-9.
- Price SM, Stanhope R, Garrett C, Preece MA, Trembath RC. The spectrum of Silver-Russell syndrome: a clinical and molecular genetic study and new diagnostic criteria. *J Med Genet* 1999;36:837-42.
- Cullen CL, Wesley RK. Russell-Silver syndrome: microdontia and other pertinent oral findings. *ASDC J Dent Child* 1987; 54:201-4.
- Kotilainen J, Hölttä P, Mikkonen T, Arte S, Sipilä I, Pirinen S. Craniofacial and dental characteristics of Silver-Russell syndrome. *Am J Med Genet* 1995;56:229-36.
- Bergman A, Kjellberg H, Dahlgren J. Craniofacial morphology and dental age in children with Silver-Russell syndrome. *Orthod Craniofac Res* 2003;6:54-62.
- Shanahan TE. Physiologic jaw relations and occlusion of complete dentures. 1955. *J Prosthet Dent* 2004;91:203-5.
- Silverman MM. The speaking method in measuring vertical dimension. 1952. *J Prosthet Dent* 2001;85:427-31.
- Tarjan I, Gabris K, Rozsa N. Early prosthetic treatment of patients with ectodermal dysplasia: a clinical report. *J Prosthet Dent* 2005;93:419-24.
- Shaw RM. Prosthetic management of hypohidrotic ectodermal dysplasia with anodontia: case report. *Aust Dent J* 1990; 35:113-6.
- Pae A, Kim K, Kim HS, Kwon KR. Overdenture restoration in a growing patient with hypohidrotic ectodermal dysplasia: a clinical report. *Quintessence Int* 2011;42:235-8.
- Bhalla G, Agrawal KK, Chand P, Singh K, Singh BP, Goel P, Alvi HA. Effect of complete dentures on craniofacial growth of an ectodermal dysplasia patient: a clinical report. *J Prosthodont* 2013;22:495-500.