

Oncology

Successful Treatment with Paclitaxel, Carboplatin, and Gemcitabine as Second-line Chemotherapy for Recurrent Urothelial Carcinoma of the Bladder with Glandular Differentiation After Radical Cystectomy: A Case Report



Hiroki Fukuhara^{a,*}, Hiroshi Kakizaki^b, Hisashi Kaneko^b, Takuya Yamanobe^a, Masaki Ushijima^b, Yuya Kuboki^b, Norihiko Tsuchiya^a

^a Department of Urology, Yamagata University Faculty of Medicine, 2-2-2 Iida-nishi, Yamagata City, Yamagata Prefecture, 998-9585, Japan

^b Department of Urology, Nihonkai General Hospital, 30 Akiho-cho, Sakata City, Yamagata Prefecture, 998-8501, Japan

ARTICLE INFO

Article history:

Received 3 June 2017

Received in revised form

30 July 2017

Accepted 1 August 2017

Available online 8 September 2017

Keywords:

Urothelial carcinoma

Bladder cancer

Histological variant

Second-line chemotherapy

ABSTRACT

Urothelial carcinoma of the bladder (UCB) with glandular differentiation is a histological variant (HV) that is more likely to have positive extravesical tumors or nodes than those in pure UCB. Cisplatin-based neoadjuvant chemotherapy (NAC) prior to radical cystectomy (RC) is more effective for pure UCB; however, few reports are available on second-line chemotherapy for recurrence of UCB with HV. Here we report a 65-year-old Japanese male diagnosed with local recurrence UCB with HV after NAC + RC who safely achieved complete response with paclitaxel, carboplatin, and gemcitabine combination chemotherapy.

© 2017 The Authors. Published by Elsevier Inc. This is an open access article under the CC BY-NC-ND license (<http://creativecommons.org/licenses/by-nc-nd/4.0/>).

Introduction

Urothelial carcinoma of the bladder (UCB) with glandular differentiation is a histological variant (HV) that is reported in approximately 6% of patients with UCB. HV is associated with higher clinical or pathologic stage after radical cystectomy (RC).¹ Cisplatin-based neoadjuvant chemotherapy (NAC) is more effective in UCB with HV than in pure UCB,² but there are few reports on second-line chemotherapy for metastatic UCB with HV. We present a case of metastatic UCB with glandular differentiation after NAC and RC achieving complete response (CR) after paclitaxel, carboplatin, and gemcitabine second-line chemotherapy.

Case presentation

A 65-year-old Japanese man with a past history of non-insulin-dependent diabetes mellitus was referred for evaluation of asymptomatic gross hematuria. Flexible cystoscopy revealed a

sessile, exophytic lesion approximately 2.5 cm in size, arising from the left bladder wall. A biopsy of the bladder mass obtained by flexible cystoscopy was diagnosed as a high-grade urothelial carcinoma. Coronal T2-weighted magnetic resonance imaging (MRI) revealed a large solid tumor on the left side of the bladder and it was suspected that the tumor invaded the perivesical tissue (Fig. 1). Computed tomography (CT) of the lung, abdomen, and pelvis was negative for metastasis. RC with orthotopic neobladder reconstruction was performed after three cycles of gemcitabine/cisplatin chemotherapy. Histopathological evaluation of a surgical specimen revealed an invasive UC with glandular differentiation invading the bladder soft tissue, stage pT3a (Fig. 2a). Percentage of viable tumor cells in the resected specimens was approximately 50% (Fig. 2b). The patient was followed-up every 3–6 months. Fifteen months after RC, the patient visited the emergency department complaining of flank pain and nausea. CT revealed intestinal obstruction because of a bulky 11 cm mass adjacent to the descending colon (Fig. 3a and b). A percutaneous abdominal tumor biopsy confirmed the recurrence of bladder cancer.

Platinum-based combination chemotherapy is suitable as a second-line treatment for recurrent UCB; however, cisplatin was unfit for this case because residual viable cell count was approximately 50%

* Corresponding author.

E-mail address: hiroki_fukuhara@yahoo.co.jp (H. Fukuhara).

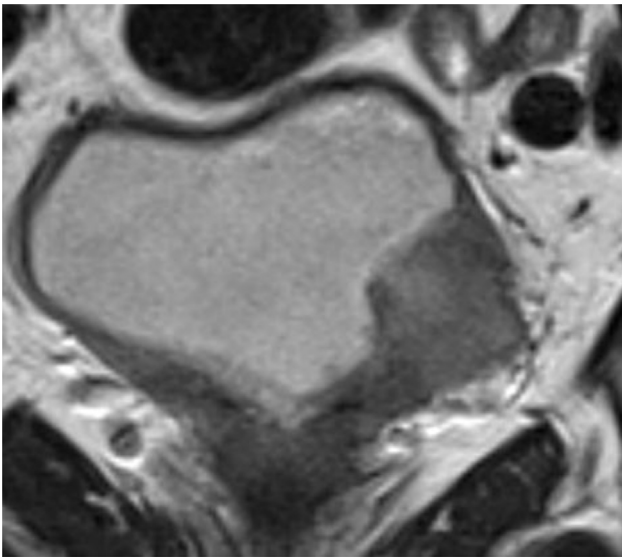


Figure 1. Coronal T2-weighted magnetic resonance imaging (MRI) of the bladder showing a 2.2 × 2.4 cm solid tumor on the left side with an extravesical mass.

in the resected specimens, indicating that UCB was resistant to cisplatin. In addition, many studies reported the effectiveness of paclitaxel or gemcitabine as second-line chemotherapy for UCB. Therefore, we chose paclitaxel, carboplatin, and gemcitabine combination chemotherapy as second-line chemotherapy administered with the following regimen: intravenous paclitaxel (200 mg/m²) and carboplatin (area under the curve 5) as a 60-min infusion on day 1 and intravenous gemcitabine (1000 mg/m²) as a 30-min infusion on days 1 and 8. The regimen was repeated every 4 weeks.

After two courses of paclitaxel, carboplatin, and gemcitabine combination chemotherapy, the size of the abdominal tumor was reduced by 66%, which was judged to be a partial response (PR). Three to six courses of gemcitabine was administered only on day 1, and the dose was reduced by 80% because of grade 3 thrombocytopenia. After six courses of chemotherapy, the abdominal and pelvic tumor had disappeared. The patient achieved CR (Fig. 3c and d). Other hematological toxicities evaluated using the common terminology criteria for adverse events (CTCAE) v4.0 included grade 3 neutropenia; the most severe non-hematologic toxicities were

grade 2 myalgia and grade 1 malaise and fever. The patient has been recurrence-free for 10 months after treatment; however, local recurrence was found in the 25-mm mass adjacent to the ileum. After six courses of additional paclitaxel, carboplatin, and gemcitabine combination chemotherapy, the tumor was reduced by 50% and PR was achieved. The patient is followed up with CT every 3 months without additional or maintenance chemotherapy. Although the viability of tumor was not assessed, the tumor size has not changed since 10 months from the last chemotherapy.

Discussion

The survival benefit of cisplatin-based NAC before RC for UCB with HV is greater than that for pure UCB because the rate of pathologic down-staging of UCB with HV is significantly higher than that for pure UCB.³ However, there is no standard regimen for metastatic UCB with HV after NAC, which develops resistance to initial cisplatin-based treatment.

The European Association of Urology guidelines recommend that if progression occurs ≥6–12 months after first-line cisplatin-based chemotherapy, rechallenge with a cisplatin combination is a reasonable strategy.³ In this case, recurrence was found 9 months after surgery; however, cisplatin readministration was not appropriate in our patient because many viable tumor cells were observed in the resected specimens suggesting that the tumor was resistant to cisplatin-based chemotherapy. We thus needed to choose agents other than cisplatin for second-line chemotherapy.

Carboplatin is another key drug for UC treatment, and some studies have reported the effectiveness of carboplatin-based combination chemotherapy as a second-line treatment with good tolerance. Ito et al. reported that paclitaxel, carboplatin, and gemcitabine combination chemotherapy were effective as second-line chemotherapy for metastatic pure UC in Japanese patients, achieving an overall response rate of 37.5% with a median OS of 8.0 months.⁴ However, this is the only report investigating the effectiveness of paclitaxel, carboplatin, and gemcitabine combination chemotherapy as second-line chemotherapy. Therefore, further studies should be performed to determine the efficiency of paclitaxel, carboplatin, and gemcitabine combination chemotherapy as a second-line setting.

Recently, the USFDA approved the use of atezolizumab, a programmed death-ligand 1 (PD-L1) blocking antibody, for the treatment of patients with advanced UC after platinum-based

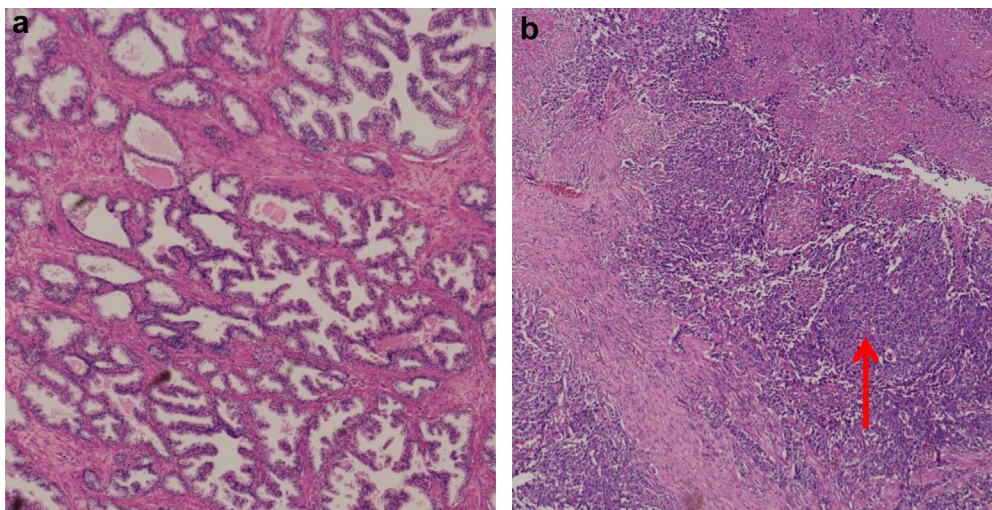


Figure 2. (a) Hematoxylin-eosin (HE) stain of the biopsy tissue showing glandular differentiation. (b) HE staining showing viable cells (red arrow).

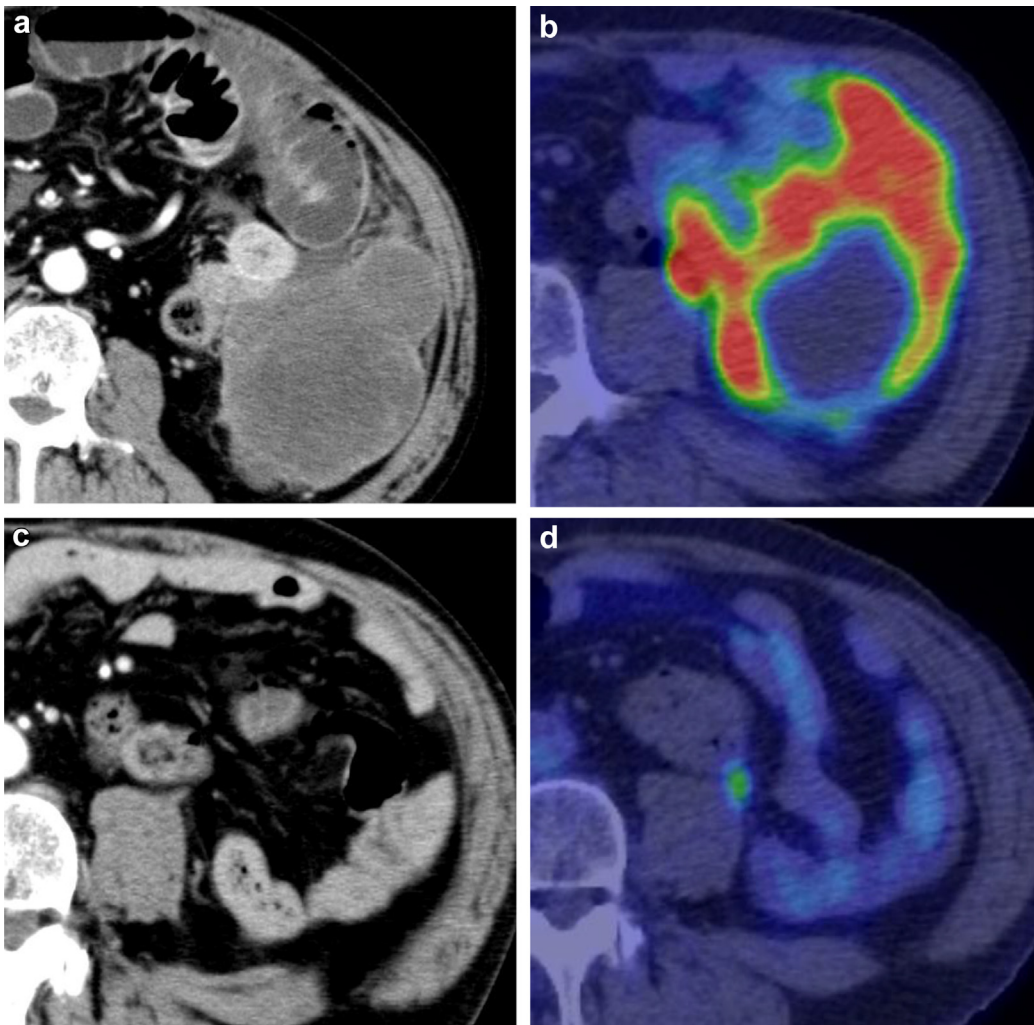


Figure 3. (a) Computed tomography of the abdomen showing a 1-cm mass adjacent to the descending colon and an intestinal obstruction. (b) $2\text{-}^{18}\text{F}$ fluorodeoxy-D-glucose positron emission tomography (FDG-PET) of the abdomen. (c) After six cycles showing complete response. (d) $2\text{-}^{18}\text{F}$ fluorodeoxy-D-glucose positron emission tomography (FDG-PET) of the abdomen after six cycles with absence of a positive lesion.

chemotherapy.⁵ Atezolizumab for UCB with historical variant is likely to be effective, although additional inspection is necessary.

This case demonstrates two important clinical issues. First, paclitaxel, carboplatin, and gemcitabine combination chemotherapy as second-line chemotherapy was effective in UCB with HV. Second, this regimen was effective against a bulky, rapidly growing metastatic UCB with HV tumor. The patient safely achieved CR without severe toxicity except for grade 3 neutropenia and thrombocytopenia. Paclitaxel, carboplatin, and gemcitabine combination chemotherapy might be considered as alternative second-line chemotherapy for UCB with HV.

Conflicts of interest

The authors declare that there is no conflict of interest regarding the publication of this paper.

References

1. Kim SP, Frank I, Cheville JC, et al. The impact of squamous and glandular differentiation on survival after radical cystectomy for urothelial carcinoma. *J Urol.* 2012;188:405–409.
2. Zargar-Shoshtari K, Sverrisson EF, Sharma P, et al. Clinical outcomes after neoadjuvant chemotherapy and radical cystectomy in the presence of urothelial carcinoma of the bladder with squamous or glandular differentiation. *Clin Genitourin Cancer.* 2016;14:82–88.
3. Witjes JA, Comperat E, Cowan NC, et al. EAU guidelines on muscle-invasive and metastatic bladder cancer: summary of the 2013 guidelines. *Eur Urol.* 2014;65:778–792.
4. Ito H, Aoki Y, Oyama N, Miwa Y, Akino H, Yokoyama O. Combination chemotherapy of paclitaxel, carboplatin and gemcitabine in patients who have received prior cisplatin-based chemotherapy. *Gan To Kagaku Ryoho.* 2011;38:481–484.
5. Ning YM, Suzman D, Maher VE, et al. FDA Approval Summary: atezolizumab for the treatment of patients with progressive advanced urothelial carcinoma after platinum-containing chemotherapy. *Oncologist.* 2017;22:743–749.