



Taibah University

Journal of Taibah University Medical Sciences

www.sciencedirect.com



Original Article

Hepatoprotective and antioxidant activities of *Spondias mombin* leaf and stem extracts against carbon tetrachloride-induced hepatotoxicity



Lucky L. Nwidu, PhD^{a,*}, Ekramy Elmorsy, PhD^b, Yibala I. Oboma, MSc^c and Wayne G. Carter, PhD^d

^a Department of Experimental Pharmacology and Toxicology, Faculty of Pharmaceutical Sciences, University of Port Harcourt, Choba, East West Road, Rivers State, Nigeria

^b Department of Forensic Medicine and Clinical Toxicology, Faculty of Medicine, Mansoura University, Egypt

^c Department of Medical Laboratory Science, Faculty of Basic Medical Sciences, College of Health Sciences, Wilberforce Island, Bayelsa State, Nigeria

^d School of Medicine, University of Nottingham, Royal Derby Hospital Centre, Derby, UK

Received 24 November 2017; revised 11 March 2018; accepted 14 March 2018; Available online 12 April 2018

المخلص

أهداف البحث: تستخدم ورقة نبات سيوندياس مومبين (بطمية) في الطب الشعبي في نيجيريا لعلاج التهاب الكبد. هذه الدراسة تقيم نسبيًا تأثيرات الحماية الكبدية ومضادات الأكسدة في الجسم الحي لورقة نبات سيوندياس مومبين ومستخلصات الميتانول في جذع النبات في نموذج الفئران لتسمم الكبد.

طرق البحث: تم تقسيم اثنين وأربعين فأرًا إلى سبع مجموعات. أعطيت المجموعة أ الماء، وأعطيت المجموعة ب الماء، كما أعطيت المجموعتين س و د ورقة نبات سيوندياس مومبين بجرعة 500 و 1000 مجم/كجم من وزن الجسم، على التوالي، وأعطيت المجموعتين إ و ف جذع نبات سيوندياس مومبين 500 و 1000 مجم/كجم من وزن الجسم، على التوالي، وأعطيت المجموعة ج سيليمارين بجرعة 100 مجم/كجم. أعطيت جميع المستخلصات والأدوية يوميًا بواسطة غشاء فموي لمدة سبعة أيام، ثم تم حث تسمم الكبد الحاد للمجموعتين ب و ج بإعطاء CCl₄. بعد 48 ساعة تم ذبح الفئران وفحص المؤشرات النسيجية والكيميائية الحيوية لتسمم الكبد.

الاستنتاجات: أحدث CCl₄ إصابة بالكبد بزيادة كبيرة في مستويات علامات الإصابة الكبدية: ALT, AST, TBIL, CBIL. بالإضافة إلى خفض كبير في البروتين الكلي في الدم. حسنت المستخلصات النباتية لورقة نبات سيوندياس مومبين وجذع نبات سيوندياس مومبين عند 500 و 1000 مجم/كجم قبل العلاج ب CCl₄ بشكل ملحوظ إصابة الكبد، وخفضت مستويات ALT, AST, TBIL, CBIL. مستخلصات ورقة نبات سيوندياس مومبين أو جذع نبات سيوندياس مومبين زاد

كثيرًا المستويات الخلوية للجلوتاثيون، ونشاطات الكاتالاز وديسموتاز الفائق، وخفض كثيرًا المواد المتفاعلة لحمض ثيوباربيتوريك.

النتائج: تقدم هذه الدراسة أدلة أولية تدعم الفوائد المحتملة لنبات سيوندياس مومبين لعلاج تسمم الكبد -الناجم عن الأكسجوبيوتيك.

الكلمات المفتاحية: ورقة نبات سيوندياس مومبين؛ تسمم الكبد؛ حماية الكبد؛ الأكسدة

Abstract

Objective: *Spondias mombin* L. is a tree used in folk medicine in Nigeria for the treatment of hepatitis. This study was carried out to comparatively evaluate the hepatoprotective and antioxidant effects of *S. mombin* leaf and stem (SML and SMS) methanolic extracts in a rat model of carbon tetrachloride (CCl₄)-induced hepatotoxicity.

Methods: Forty-two rats were distributed into seven groups. Groups A and B received water; groups C and D received 500 and 1000 mg/kg SML extract, respectively; groups E and F received 500 and 1000 mg/kg SMS extract, respectively; and group G received 100 mg/kg silymarin. Water, the two extracts, and silymarin were administered daily by oral gavage for 7 days. Hepatotoxicity was induced in groups B to G by the administration of CCl₄ once on the seventh day. After 48 h, rats were sacrificed, and tissues and serum samples were examined for histological and biochemical indices of hepatotoxicity.

* Corresponding address: P.O. Box 10935, Port Harcourt, Nigeria.

E-mail: menelucky@yahoo.com (L.L. Nwidu)

Peer review under responsibility of Taibah University.



Production and hosting by Elsevier

Results: Administration of CCl₄ resulted in liver injury with significant elevation in the hepatocellular injury markers alanine aminotransferase (ALT), aspartate aminotransferase (AST), alkaline phosphatase (ALP), total bilirubin (TBIL), and conjugated bilirubin (CBIL), associated with a significant reduction in total circulatory protein. Pretreatment with SML and SMS extracts at both doses significantly ameliorated liver injury; lowered ALT, AST, ALP, TBIL, and CBIL levels; elevated cellular glutathione levels as well as catalase and superoxide dismutase activities; and decreased the levels of thiobarbituric acid reactive substances.

Conclusion: This study provides preliminary evidence supporting the potential therapeutic benefit of *S. mombin* in xenobiotic-induced hepatotoxicity.

Keywords: Hepatoprotection; Hepatotoxicity; Oxidative stress; *Spondias mombin* L.

© 2018 The Authors.

Production and hosting by Elsevier Ltd on behalf of Taibah University. This is an open access article under the CC BY-NC-ND license (<http://creativecommons.org/licenses/by-nc-nd/4.0/>).

Introduction

Liver diseases are major causes of illness and death worldwide,^{1–4} and constitute a public health challenge that requires the development of new therapeutic options. Investigating the hepatoprotective effects of medicinal plants in laboratory animals is an important initial step in evaluating the safety of new biomolecules.^{5–9} Natural products from ethnomedicine have provided safe and effective alternatives for the treatment of hepatotoxicity. Many previous reports have demonstrated the hepatoprotective effects of local phytoextracts rich in natural antioxidants,^{5–15} and several bioactive compounds and plant extracts have been investigated for their hepatoprotective and antioxidant effects.^{16,17}

Phenolic compounds found in several plants are usually associated with multiple biological activities such as free radical scavenging activities.^{18–20} It has been suggested that natural antioxidants found in food, such as phenolic compounds or flavonoids, might play an important role in the prevention of oxidative stress-related disorders and in the reduction of premature mortality.^{21,22} Flavonoids are certainly ubiquitous in the epidermal cells of many plant parts and exist in both glycosidic and non-glycosidic forms.²³

Spondias mombin L. (Anacardiaceae) is commonly known as hog plum (English), akika (Yoruba), ijikara (Igbo), tsardamaser (Hausa), chabbuh (Fulani), nsukakara (Efik), and atoa (Ashanti).²⁴ It is a deciduous erect tree, which grows up to 15–20 m high, with a trunk that is 60–75 cm wide.^{25,26} *S. mombin* is commonly found in the tropical Americas, including the West Indies, and has also been naturalized in parts of Africa, including Ghana, and some parts of Asia.²⁶ In ethnomedicine, *S. mombin* parts, including the stem bark, leaves, and roots, have been used for the treatment of various conditions. *S. mombin* possesses antimicrobial^{27,28}

and antiviral activities.²⁹ Its leaves show anti-inflammatory,³⁰ anthelmintic,³¹ hematinic,³² and sedative³³ activities, while its stem bark possesses anti-mycobacterial activity.³⁴ In a previous study, phytochemical screening indicated that *S. mombin* leaf (SML) contains tannins, saponins, alkaloids, flavonoids, and phenols.³⁵ It is also rich in ascorbic acid and niacin, and contains riboflavin and thiamine.³⁵

The hepatoprotective effects of *Ocimum gratissimum* and SML have been previously evaluated in rats after intoxication with dimethylnitrosamine.³⁶ However, the effects of SML and *S. mombin* stem (SMS) on carbon tetrachloride (CCl₄)-induced hepatotoxicity have not yet been assessed. Thus, the aim of this study was to establish whether SML and SMS methanolic extracts show hepatoprotective effects against CCl₄-induced hepatotoxicity in rats.

Materials and Methods

Chemicals and reagents

CCl₄, silymarin, diethyl ether, and methanol were purchased from Sigma–Aldrich, St. Louis, Missouri, USA. Diagnostic kits for serum alanine aminotransferase (ALT), aspartate aminotransferase (AST), alkaline phosphatase (ALP), conjugated bilirubin (CBIL), and total bilirubin (TBIL) were purchased from Randox Laboratories Ltd., London, UK. All other chemicals and solvents were of the highest commercially available grade (analytical grade) and were obtained either from Sigma–Aldrich or Merck, UK.

Plant collection and validation

Fresh leaves and stems of *S. mombin* L. were collected from Obafemi Awolowo University campus in January 2015. The plant was identified and authenticated by Dr. Oladele Adekunle, a Taxonomist at the Forestry Department, University of Port Harcourt, Nigeria, where specimens of SML (20015) and SMS (20016) were deposited.

Preparation of *S. mombin* leaf and stem methanolic extracts

Three hundred grams of *S. mombin* L. fresh leaves and stem barks were weighed, air dried, and powdered. Then, powdered leaves and stems were extracted by the cold extraction method (maceration) using methanol as a solvent; SML and SMS powders were soaked in one liter of 50% methanol for 3 days, during which the mixture was shaken twice daily to promote extraction. The solvent was filtered over a layer of gauze and the filtrate was evaporated to dryness *in vacuo* at 55 °C. The weights of the dried extracts were 21.3 g and 9.4 g, and the obtained yields were 7.1% and 3.1% for SML and SMS extracts, respectively. The extracts were stored in a refrigerator for up to 4 weeks for subsequent use in assays.

Phytochemical screening

The methanolic extracts of SML and SMS were quantitatively assayed for the presence of phytochemicals such as saponins, tannins, alkaloids, terpenoids, cardiac glycosides, and flavonoids using standard procedures.³⁶

Experimental animals

Forty two healthy Wistar rats of both sexes (21 male rats and 21 female rats) weighing 320–355 g were purchased from the animal house of the Pharmacology Department, Faculty of Pharmacy, Niger Delta University, Bayelsa State, Nigeria. Animals were acclimatized for one week prior to experimentation. All animals were fed a standard chow diet and were given access to water *ad libitum*. Experimental techniques and protocols used in this study follow the “Guide to the Care and Use of Animals in Research and Teaching”³⁷ as adopted and approved by Niger Delta University Institutional Animal Care and Use Committee on 20/02/2015 with an approval number NDU/2014/007.

Acute toxicity study

An acute toxicity study was carried out to determine the approximate median lethal doses of SML and SMS extracts in Albino mice (25–30 g) of both sexes. Mice were distributed into eight groups, three mice per group, and were administered single doses of SML and SMS extracts (100, 500, 1000, 2000, 3000, 4000, and 5000 mg/kg) intraperitoneally. Treated animals were monitored for 24 h for mortality and behavioral changes consistent with toxicity.^{38,39}

Experimental design

A total of 42 rats were weighed and distributed into seven groups, six rats per group (three males and three females). In groups A (negative control) and B (positive control), rats received 0.2 mL/kg distilled water. In groups C and D, rats received 500 and 1000 mg/kg SML extract, respectively, dissolved in distilled water. In groups E and F, rats received 500 and 1000 mg/kg SMS extract, respectively, dissolved in distilled water. In group G, rats received 100 mg/kg silymarin suspended in distilled water. Distilled water, SML and SMS extracts, and silymarin were administered daily by oral gavage for 7 days. On the seventh day, 1 h after administration of the last dose, all groups except group A received a 1:1-mixture of freshly prepared CCl₄ in liquid paraffin (2 mL/kg) intraperitoneally. Body weights of all rats were measured and recorded daily throughout the 7 days of the experiment.

Fourty eight hours after CCl₄ administration, rats were anesthetized using diethyl ether and then sacrificed. Blood was collected by cardiac puncture into an EDTA vacutainer for determination of hematological parameters using the Automated Hematology Analyzer KX-21 (SYSMEX Corporation, Japan). The hemoglobin concentration, packed cell volume, red blood cell count, mean corpuscular hemoglobin, mean corpuscular hemoglobin concentration, mean corpuscular volume, white blood cell count, and platelet count were determined. For biochemical assessment, blood samples were centrifuged at 3000 rpm for 10 min at 4 °C, and serum was separated into vacutainer vials and stored at 4 °C for subsequent analysis. Livers were immediately collected, perfused with ice cold normal saline (0.9% sodium chloride), and transported on dry ice from the Pharmacology laboratory, Faculty of Pharmacy, Niger Delta University, Nigeria, to the School of Medicine, University of Nottingham, Royal

Derby Hospital Centre, Derby, UK, where they were stored at –80 °C for subsequent use in further analyses.

Assessment of biochemical parameters

Serum levels of ALT, AST, ALP, CBIL, TBIL, and total protein (TP) were assessed using Randox diagnostic kits. These analyses were performed at the Department of Chemical Pathology, Niger Delta University Teaching Hospital, Okolobiri, Bayelsa state, Nigeria.

Measurement of oxidative stress markers

Liver sections (100 mg) were diced and homogenized in 100 mL of 5 mM Tris/HCl buffer (pH 7.4), 1 mM EDTA, and complete, Mini, EDTA-free Protease Inhibitor Cocktail tablet (Roche). Homogenates were then centrifuged at 10,000 rpm for 10 min at 4 °C and the clear supernatant was collected for the estimation of reduced glutathione (GSH), superoxide dismutase (SOD), catalase (CAT), and thio-barbituric acid reactive substances (TBARS). Assessment of GSH was carried out based on the method published by Ellman et al.⁴⁰ with slight modifications as follows: the homogenate (0.2 mL) was mixed with 25% trichloroacetic acid and centrifuged at 3000 rpm for 10 min, then the supernatant (~0.2 mL) was mixed with 10 mM DTNB in the presence of phosphate buffer (0.1 M, pH 7.4), and the absorbance was read at 420 nm. Determination of CAT was performed based on the method described by Aebi,⁴¹ which relies upon the ultraviolet absorption of hydrogen peroxide that can be measured at 240 nm in the presence of 50 mM phosphate buffer. Hydrogen peroxide decomposition was monitored in a 96 well quartz plate using a Spectramax microplate reader (ThermoFisher, Stafford, UK). Catalase activity was expressed as units/mg protein. Liver cytosolic SOD activity was measured according to the method described by Kakkar et al.⁴² Finally, extent of lipid peroxidation was determined spectrophotometrically by measuring malondialdehyde levels, as described by Draper and Hadley.⁴³

Histopathological investigation

Liver specimens from each rat were cut into pieces (approximately 6 mm³ in size), fixed in phosphate buffered 10% formaldehyde, and embedded in paraffin wax. Then, 5-µm-thick sections were cut, fixed onto glass slides, and stained with hematoxylin and eosin (H&E). Slides were examined under a high-resolution microscope (Olympus BX60MF, Japan), and photomicrographs were taken at a magnification of ×400.

Statistical analysis

All statistical analyses were performed using Prism 5 (GraphPad Software Inc., San Diego, California, USA). Unless otherwise specified, results were expressed as mean ± standard error of mean (SEM). One-way analysis of variance (ANOVA) was used to compare group data, followed by Tukey’s multiple comparisons test. A *p* value < 0.05 was considered statistically significant.

Results

Phytochemical constituents in SML and SMS

Preliminary phytochemical screening of SML and SMS extracts revealed the presence of alkaloids, reducing sugars, saponins, and tannins [Table 1]. The SMS extract was found to contain more saponins and tannins than the SML extract. However, regarding other qualitative assays, both extracts were similar.

Acute toxicity study of SML and SMS in mice

Treated mice were monitored for mortality and no signs of toxicity were observed up to 24 h after extract administration of single dose (intraperitoneally) of either SML or SMS extracts (100–5000 mg/kg). Consequently, we chose two doses, 1/10 and 1/5 of the maximal dose examined (5000 mg/kg), i.e., 500 and 1000 mg/kg, for both extracts as the experimental doses.

Body weight changes throughout the study period

The effect of CCl₄ administration as well as pretreatment with SML and SMS extracts on the body weights of rats throughout the course of the experimental study is presented in Figure 1.

Significant changes in the body weights of the rats were observed in each group throughout the time course of the experiment (two-way ANOVA, $p < 0.0001$). However, when investigating the effects of the treatments, no significant differences were found between body weight changes in the treated groups and the CCl₄-induced group ($p = 0.506$). Pretreatments with 500 and 1000 mg/kg SMS extract were associated with 3.5% and 4.3% increase in body weights, respectively.

Effect of SML and SMS on biochemical and histological markers of hepatotoxicity

To assess the hepatoprotective effects of SML (500, 1000 mg/kg) and SMS (500, 1000 mg/kg) extracts in CCl₄-induced hepatotoxicity, serum ALT, AST, ALP, TP, CBIL, and TBIL levels were assessed [Table 3]. Administration of CCl₄ resulted in hepatocellular toxicity demonstrated by a significant ($p < 0.001$ – 0.05) elevation in serum ALT (102%), AST (58%), ALP (27%), and TBIL (62%) levels,

and a significant ($p < 0.001$) decrease in TP (54%), compared to the negative control group.

Pretreatment with 500 and 1000 mg/kg SML extract decreased serum levels of ALT by 7% and 46%; AST by 54% and 91%; ALP by 33% and 31%; TP by 97% and 116%; CBIL by 75% and 88%; and TBIL by 62% and 41%, respectively, compared to the positive control (CCl₄-induced) group. Regarding SMS extract, pretreatment with 500 and 1000 mg/kg lowered serum levels of ALT by 4% and 37%; AST by 47% and 83%; ALP by 27% and 23%; TP by 111% and 119%; CBIL by 8% and 31%; and TBIL by 59% and 55%, respectively, compared to the positive control group. Moreover, pretreatment with SML and SMS extracts counteracted the CCl₄-induced decrease in TP; pretreatment with 500 and 1000 mg/kg SML extract significantly ($p < 0.001$) increased serum TP levels by 97% and 116%, respectively, while 500 and 1000 mg/kg SMS extract significantly ($p < 0.001$) increased serum TP levels by 111% and 119%, respectively, compared to the positive control group. The standard antioxidant silymarin (100 mg/kg) significantly ($p < 0.001$) increased the serum level of TP by 116% and significantly ($p < 0.05$ – 0.001) decreased serum levels of ALT, AST, ALP, CBIL, and TBIL ($p < 0.05$) by 22%, 90%, 22%, 31%, and 36%, respectively, compared to the CCl₄-induced group.

The effects of pretreatment with SML and SMS extracts (500 and 1000 mg/kg) and silymarin (100 mg/kg) on liver histology of CCl₄-induced rats are presented in Figure 2.

Effect of SML and SMS on Haematological indices

Extracts at either 500 or 1000 mg/kg did not have any significant effect on the haematological indices evaluated, except SMS at 500 mg/kg which induced a significant ($p < 0.05$) change in PCV when compared to the CCl₄ intoxicated group (Table 2).

Effect of SML and SMS on oxidative stress markers

Glutathione levels decreased by 48%, CAT and SOD activities decreased by 59% and 30%, respectively, and TBARS levels increased by 67% following intoxication with CCl₄ (Figure 3). In contrast, pretreatment with SML and SMS extracts (1000 mg/kg) significantly increased GSH levels by 42% ($p < 0.05$) and 50% ($p < 0.01$), respectively, while pretreatment with silymarin (100 mg/kg) significantly ($p < 0.001$) increased GSH levels by 74%. Similarly, both CAT and SOD enzyme activities were significantly

Table 1: Phytochemical constituents of Spondias mombin leaf and stem Extracts.

Phytochemicals	Observations	Extract	
		SML Extract	SMS Extract
Reducing sugars	Reddish brown precipitate upon heating	+	+
Cardiac glycosides	Brick red precipitate	+	+
Saponins	Persistent froth unbroke upon standing	++	+++
Tannins	Blue black precipitate	++	+++
Flavonoid	Resultant solution turns yellow	+++	+++

(+) to (+++) = detected in moderate to abundant quantities.

Table 2: Effect of *Spondias mombin* leaf and stem extracts on hematological parameters.

Parameters	Group A	Group B	Group C	Group D	Group E	Group F	Group G
PCV(%)	42 ± 3.2	49 ± 7.9	44 ± 3.5	42 ± 3.9	40 ± 6.2*	44 ± 6.5	49 ± 3.1
Hb(g/dl)	12 ± 0.6	14 ± 2.1	13 ± 1.8	11 ± 0.7	12 ± 0.8	13 ± 2.3	13 ± 0.6
WBC (×10 ³ cells/μL)	13 ± 4.9	7 ± 4.2	9 ± 0.4	11 ± 7.7	11 ± 4.2	8 ± 2.3	13 ± 4.5
PLT (×10 ³ cells/μL)	468 ± 280	459 ± 366	761 ± 1.4	284 ± 316	500 ± 288	446 ± 306	642 ± 322
RBC (x10 ⁶ cells/μL)	7 ± 1.3	7 ± 1.2	6 ± 0.0	6 ± 1.1	7 ± 0.8	7 ± 0.9	8 ± 0.3
MCV (%)	63 ± 2.5	65 ± 2.0	65 ± 7.1	66 ± 4.4	62 ± 2.6	63 ± 0.8	65 ± 4.2
MCH (pg)	17 ± 2.0	18 ± 0.3	18 ± 1.7	18 ± 0.5	17 ± 0.7	19 ± 1.4	18 ± 1.2
MCHC (g/dl)	27 ± 2.7	28 ± 0.5	28 ± 0.4	27 ± 2.1	26 ± 2.1	30 ± 2.5	27 ± 2.1
NEU (%)	32 ± 8.2	44 ± 13	37 ± 7.1	40 ± 14	52 ± 13	39 ± 7.2	38 ± 5.4
LYM (%)	63 ± 8.0	44 ± 13	57 ± 9.9	51 ± 15	42 ± 14	54 ± 9.3	54 ± 7.3
MEB (%)	6 ± 2.4	10 ± 4.1	6 ± 2.1	9 ± 2.1	6 ± 3.5	8 ± 3.1	7 ± 4.3

Data are presented as mean ± SEM, n = 6. Statistical analysis was performed using one-way ANOVA. Group A received 0.2 mL/kg distilled water; group B was administered 1 mL/kg CCl₄; groups C and D were pretreated with 500 and 1000 mg/kg SML extract, respectively, and were administered 1 mL/kg CCl₄; groups E and F were pretreated with 500 and 1000 mg/kg SMS extract, respectively, and were administered 1 mL/kg CCl₄; group G was pretreated with 100 mg/kg silymarin and was administered 1 mL/kg CCl₄. The asterisk (*), $p < 0.05$ is significantly different from Group B (positive control). Statistical analysis was performed using one way ANOVA.

Abbreviations: PCV: packed cell volume; Hb: hemoglobin concentration; WBC: white blood cell count; PLT: platelet count; RBC: red blood cell count; MCV: mean corpuscular volume; MCH: mean corpuscular hemoglobin; MCHC: mean corpuscular hemoglobin concentration; NEU: neutrophil count; LYM: lymphocyte count; MXD: mixture (monocytes, basophils, and eosinophils) count.

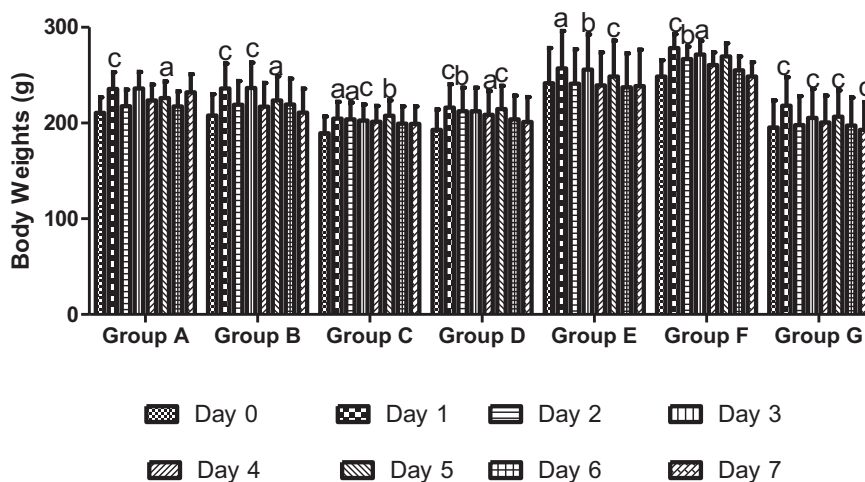


Figure 1: The effect of CCl₄ intoxication and pretreatment with *Spondias mombin* leaf and stem extracts on body weights of the experimental rats throughout the course of the experiment. Data are presented as mean ± SD. a, b, c; significant difference from body weight on day 0, $p < 0.05$, $p < 0.01$, $p < 0.001$, respectively.

Table 3: Effect of the different treatments on biochemical markers of hepatotoxicity.

Treatment	Dosing Regimen	ALT (U/L)	AST (U/L)	ALP (U/L)	TP (g/dl)	CBIL (μmol/L)	TBIL (μmol/L)
Control (water)	0.0	115.8 ± 1.2	212.6 ± 3.1	62.0 ± 2.1	85.2 ± 1.9	1.1 ± 0.04	3.4 ± 0.2
CCl ₄	1 ml/kg CCl ₄	233.5 ± 2.3 ^c	336 ± 25.8 ^c	79.0 ± 4.0 ^a	38.8 ± 1.1 ^c	1.6 ± 0.1 ^b	8.5 ± 0.3 ^c
SML	500 mg/kg	216 ± 2.6	154.7 ± 2.7 ^c	52.8 ± 1.1 ^c	76.3 ± 3.7 ^c	0.4 ± 0.17 ^c	3.2 ± 0.9 ^c
	1000 mg/kg	126.7 ± 16.9 ^c	31.3 ± 1.5 ^c	54.3 ± 1.8 ^c	84.0 ± 1.7 ^c	0.2 ± 0.03 ^c	5.0 ± 0.6 ^a
SMS	500 mg/kg	220.3 ± 5.2	177.3 ± 4.7 ^c	57.3 ± 1.2 ^c	82.0 ± 0.6 ^c	0.2 ± 0.1 ^c	3.5 ± 0.9 ^c
	1000 mg/kg	147.3 ± 9.4 ^b	55.8 ± 3.3 ^c	60.8 ± 0.9 ^b	84.8 ± 0.9 ^c	1.1 ± 0.1 ^b	3.8 ± 0.3 ^b
Silymarin	100 mg/kg	182.4 ± 21.9	34.4 ± 1.4 ^c	61.6 ± 4.7 ^b	84.0 ± 1.1 ^c	1.1 ± 0.1 ^b	5.4 ± 0.9 ^a

Values are represented as mean ± SEM, n = 6. Statistical analysis was performed using one-way ANOVA. Results of the CCl₄-induced group are compared to those of the negative control group (receiving water only), and results of the SML, SMS, and silymarin-treated groups are compared to those of the positive control (CCl₄-induced) group. ^a $p < 0.05$; ^b $p < 0.01$; ^c $p < 0.001$. ALT: alanine aminotransferase; AST: aspartate aminotransferase; ALP: alkaline phosphatase; TP: total protein; CBIL: conjugated bilirubin; TBIL: total bilirubin.

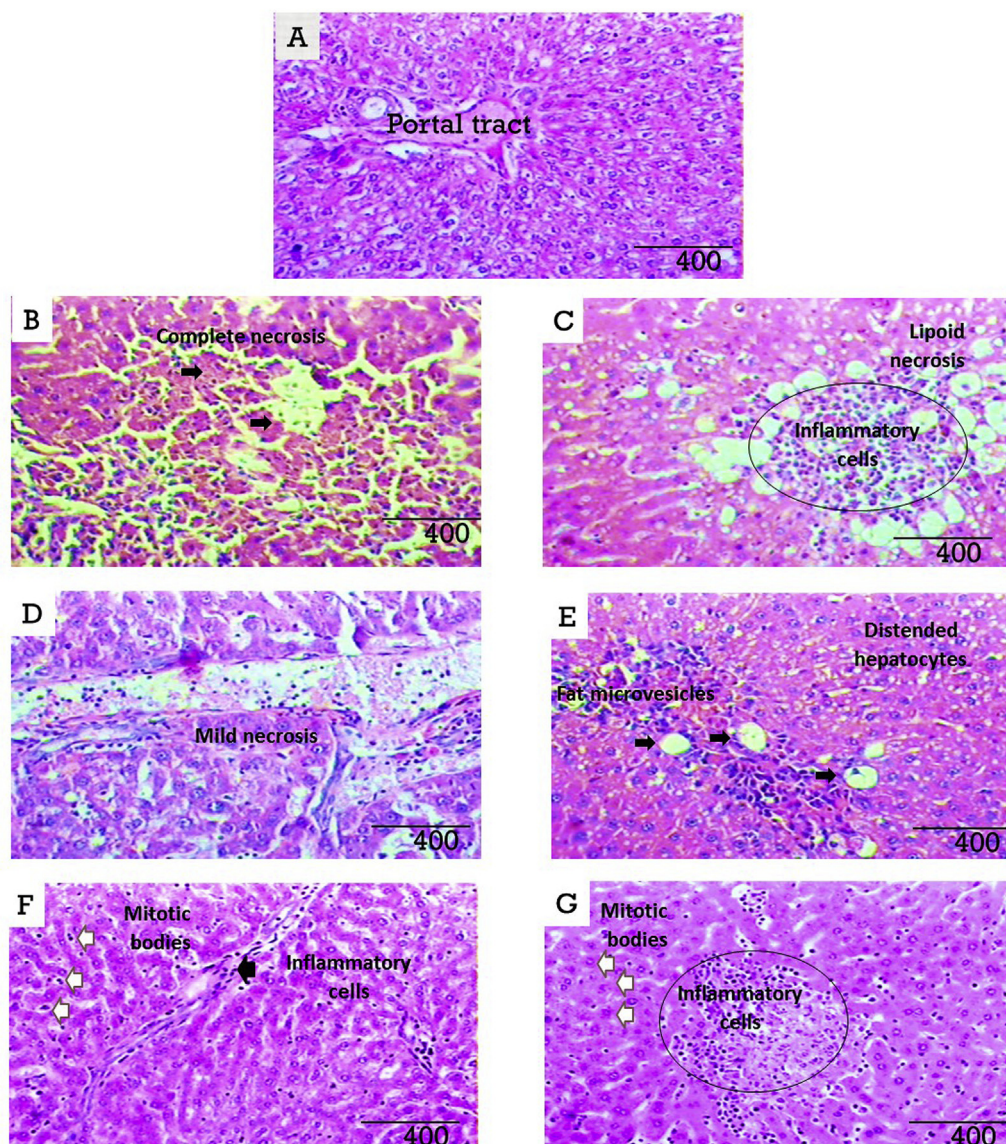


Figure 2: Photomicrographs of H&E-stained liver sections, magnification $\times 400$. **A:** micrograph of liver tissue specimen from rats administered 0.2 mL/kg distilled water showing normal liver histology with prominent hepatocytes, normal hepatic artery, portal tract, and blood vessels. **B:** micrograph of liver tissue specimen from rats intoxicated with CCl_4 showing marked distortion of hepatocytes morphology with areas of complete necrosis, which demonstrates the hepatotoxic effect of CCl_4 at the concentration and route of administration used. **C:** micrograph of liver tissue specimen from rats pretreated with 500 mg/kg SML extract prior to CCl_4 intoxication showing prominent microvesicles with degenerating lipid cells (lipoid necrosis), which reveals incomplete resolution of CCl_4 -induced hepatic injury by this dose of SML. **D:** micrograph of liver tissue specimen from rats pretreated with 1000 mg/kg SML extract prior to CCl_4 intoxication showing areas of fibrosis and localized mild necrosis, which indicates the hepatoprotective effect of SML extract at this dose. **E:** micrograph of liver tissue specimen from rats pretreated with 500 mg/kg SMS extract prior to CCl_4 intoxication showing microvesicles and hepatocytes with hyperchromatic nuclei, which indicates inadequate hepatoprotection provided by this dose of SMS. **F:** micrograph of liver tissue specimen from rats pretreated with 1000 mg/kg SMS extract prior to CCl_4 intoxication showing infiltration of inflammatory cells, mostly neutrophils, along the portal tract and abundant mitotic bodies, which indicates cellular regeneration and hepatoprotection provided by this dose of SMS. **G:** micrograph of liver tissue specimen from rats pretreated with the standard drug silymarin (100 mg/kg) prior to CCl_4 intoxication showing localized inflammatory reaction and areas of fibrosis with admixed mitotic bodies, which indicates healing by fibrosis and hepatoprotective effect of silymarin.

($p < 0.05$) increased by 28% and 18%, respectively, by pretreatment with SML extract (1000 mg/kg), and were significantly ($p < 0.05$) increased by 41% and 20%, respectively, by pretreatment with SMS extract (1000 mg/kg).

Discussion

Hepatotoxicity of different types and origins constitutes a major public health concern. Oxidative stress is implicated in

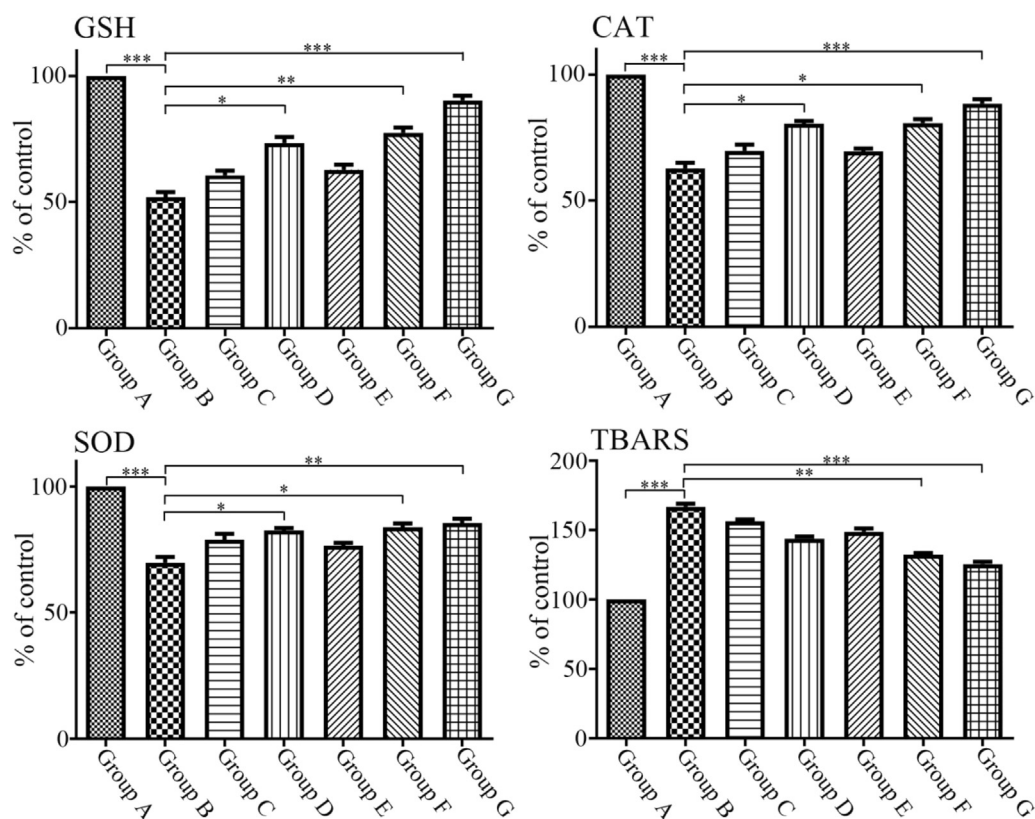


Figure 3: The effect of CCl_4 intoxication and pretreatment with *Spondias mombin* leaf and stem extracts on oxidative stress markers. Levels of GSH, CAT, SOD, and TBARS were measured in homogenized liver samples. Results of the positive control (CCl_4 -intoxicated) group are compared to those of the negative control group (receiving water only), and results of the SML, SMS, and silymarin-treated groups are compared to those of the positive control group. * $p < 0.05$; ** $p < 0.01$; *** $p < 0.001$. GSH: reduced glutathione; CAT: catalase; SOD: superoxide dismutase; TBARS: thiobarbituric acid reactive substances.

the pathogenesis of liver diseases. Accordingly, since natural antioxidants in plants and plant extracts could ameliorate free radical-induced oxidative stress, they could be beneficial in the treatment of liver diseases. In this study, the effects of SML and SMS extracts on the body weights of rats, their hematological indices, hepatic enzymes, and the hepatic antioxidant system were examined to reveal whether biomolecules present in these plants could offer hepatoprotection against CCl_4 -induced cellular insult.

It is important to investigate drug-induced body weight changes as they may provide an important indicator of drug effects. Previously, an increase in the body weights of laboratory animals was demonstrated following a sub-acute toxicity study of *Enantia chlorantha* aqueous extract.⁴⁴ In contrast, a decrease in the body weights of experimental rats after the administration of the ethanolic extract of *E. chlorantha* stem bark has also been reported.⁴⁵ Previous studies have used body weight changes for assessment of responses to *S. mombin* drug therapy.³³ Our results showed a dose-dependent but non-significant increase in the body weights of rats treated with SMS extract, and this is in agreement with previous reports demonstrating *S. mombin*-induced weight loss and appetite suppression.³³

Neither the toxicant (CCl_4) nor the assessed hepatoprotective agents (SML and SMS extracts and silymarin) induced significant changes in hematological parameters.

This indicates the absence of acute adverse effects on hematopoiesis. Low platelet counts have been associated with severe cases of liver cirrhosis.⁴⁶ However, platelet upregulation was observed only with the lower dose of SML, and was non-significant.

The effects of SML and SMS methanolic extracts on hepatic lipid accumulation in fatty liver diseases and on resolution of acute intoxication were examined by histopathological investigation of liver tissue specimens. CCl_4 administration resulted in damage to the normal histological architecture of hepatocytes as demonstrated by necrosis and membrane lipid peroxidation, which are common histopathological findings with CCl_4 -induced liver damage.^{47,48} Rats pretreated with SML and SMS for 7 days before challenging with CCl_4 demonstrated partial resolution of CCl_4 -induced alterations in the molecular architecture of hepatocytes.

Moreover, CCl_4 administration resulted in hepatotoxicity with significantly elevated serum levels of AST, ALT, ALP, CBIL, and TBIL. Elevation in serum aminotransferases is a well-known indicator of liver injury. Previous studies have also shown that hepatic damage caused by CCl_4 administration is associated with an increase in the activities of both serum aminotransferases and ALP.⁴⁹ Both plant extracts at both doses were effective at significantly lowering CBIL, TBIL, and ALP levels compared to the positive control. However, the effect of the SML extract was stronger than that of the

SMS extract. The higher dose (1000 mg/kg) of both extracts was more effective at lowering serum ALT and AST levels than the lower dose (500 mg/kg), with SMS extract being more effective than SML extract. In addition, CCl₄ administration resulted in significant reduction in TP levels. However, pretreatment with SML and SMS extracts significantly normalized TP levels compared to CCl₄-induced rats.

The mechanism of CCl₄-induced hepatotoxicity involves the generation of reactive oxygen species and depletion of antioxidant defenses like GSH, which results in a state of oxidative stress.⁵⁰ In the body, CCl₄ generates the free trichloromethyl radical (CCl₃•) which causes hepatic damage through the activation of the NADPH-Cyt P₄₅₀ system of the liver endoplasmic reticulum⁵¹ leading to the generation of the more reactive radical, trichloromethyl peroxy radical (CCl₃O₂•), which provokes lipid peroxidation, disruption of calcium homeostasis, and apoptosis.⁵² These functional and morphological changes in the cellular membrane and death of hepatocytes all result in leakage of hepatic enzymes. The oxidation of fatty acids by CCl₃• liberates lipid peroxides,⁵¹ which are free radicals that further exacerbate the state of oxidative stress within a *milieu* deficient in antioxidants.

The mechanisms of defense against free radicals include mobilization of radical scavengers and chain terminators such as vitamins C and E, antioxidants such as GSH, and redox regulatory enzymes such as CAT, SOD, and glutathione peroxidase. Tannins, saponins, alkaloids, flavonoids, phenols, and ascorbic acid, which were reported to be abundant in SML extracts,³⁴ might play an important role in its antioxidant effect. Hence, we evaluated the effects of SML and SMS extracts on GSH levels, CAT and SOD activities, and TBARS levels. Our results demonstrated that SML and SMS extracts significantly reversed the CCl₄-induced marked elevation in TBARS levels.

Different experimental models inducing hepatic fatty infiltration have reported depletion in liver GSH stores, and investigated the pathophysiological consequences of GSH depletion in relation to free radical generation.^{16,17,35} Indeed, serum GSH is a sensitive biomarker of the antioxidant status,⁵³ playing a pivotal defensive role against oxidative insults as an endogenous scavenger of free radicals.^{54,55} Administration of CCl₄ resulted in a five-fold decrease in GSH levels, compared to negative control rats. However, this effect was significantly counteracted in a dose-dependent manner by pretreatment with SML and SMS extracts. This implies that SML and SMS extracts could enhance the antioxidant capacity by elevating GSH concentrations, thereby ameliorating oxidative stress-induced damage, and this reflects the presence of free radical scavengers in *S. mombin*. Certainly, the liver is reported to maintain GSH even when experiencing elevated lipid peroxidation through supportive and compensatory mechanisms.^{55,56}

The role of SOD as an antioxidant is to convert superoxide to hydrogen peroxide, thereby protecting against the pervasive harmful effects of superoxide. The ability of SML and SMS extracts to elevate SOD activity, which had been decreased by CCl₄ intoxication, might be partly responsible for their hepatoprotective effects. Similarly, pretreatment with SML and SMS extracts induced an elevation in CAT activity, which is a hydrogen peroxide scavenger. Collectively, we hypothesize that the elevation of SOD and CAT

activities, as well as GSH levels in *S. mombin*-treated groups will augment the endogenous antioxidant system.

The restorative effects of silymarin on liver cytoarchitecture after CCl₄ treatment may leave the liver with scar tissue due to extensive fibrosis. However, this was not observed in rats treated with SMS extract (1000 mg/kg). Hence, cellular regeneration associated with *S. mombin* treatment might have been mediated by activation of liver stem cells. Moreover, the amelioration of CCl₄-induced damage by SML and SMS pretreatment might be attributed to membrane stabilization, which prevents the leakage of cellular contents, as suggested by previous studies investigating the hepatoprotective properties of *Vernonia amygdalina*,⁵⁷ *Rumex crispus*,⁵⁸ *Chrysophyllum albidum*,⁵³ *Ocimum gratissimum*, and *S. mombin*.³⁵

The protective effects of plant extracts against CCl₄-induced hepatotoxicity has been attributed to the presence of endogenous phytochemicals such as flavonoids, tannins, triterpenoids, and alkaloids.^{59,60} Flavonoids represent the most common and extensively distributed group of plant polyphenols, and serve as free radical scavengers and strong antioxidants that could protect against oxidative stress-induced cellular damage.⁶¹ Flavonoids and saponins were reported to be present in *S. mombin* leaves.⁶² Antioxidant chemicals in *S. mombin*, particularly polyphenols, could contribute to its antioxidant and hepatoprotective activities.⁶³ However, further research is required to isolate the bioactive compounds found in SML and SMS extracts and characterize the biochemical mechanisms responsible for their antioxidant and hepatoprotective activities. This work is being implemented in our laboratory and may well lead to the identification of one or more substances of potential clinical benefit in treatment of liver diseases.

Conclusion

In this study, both SML and SMS extracts were found to exhibit hepatoprotective effects by stabilizing hepatocyte cell membranes, promoting repair of injured hepatic tissues, enhancing free radical scavenging effects, and augmenting endogenous antioxidant systems, thereby limiting oxidative insults. These results provide the premise that requires further investigation of the promising therapeutic potential of *S. mombin* in liver damage and oxidative stress-induced diseases.

Authors' contributions

Conception and design, collection and assembly of data, drafting of the article and final approval of the article, administrative, technical and logistic support: LLN. Analysis and interpretation of data, statistical expertise: EE. Critical revision of the article for the important intellectual content, provision of study materials and obtaining of funding: WGC. All authors have critically reviewed and approved the final draft and are responsible for the content and similarity index of the manuscript.

Conflict of interest

The authors have no conflict of interest to declare.

Funding and Acknowledgement

The authors disclose receipt of the following financial assistance for the research, authorship, and publication of this article: a three-month Sabbatical Fellowship from Niger Delta University and an International Fellowship from the University of Nottingham to Dr. Lucky Legbosi. Dr. Ekramy ElMorsy was also provided a fund by an International Fellowship from the University of Nottingham, and Dr. Wayne Carter was supported by the University of Nottingham.

References

1. Rehm J, Samokhvalov AV, Shield KD. Global burden of alcoholic liver diseases. **J Hepatol** 2013; 59: 160–168.
2. Byass P. The global burden of liver disease: a challenge for methods and for public health. **BMC Med** 2014; 12: 159.
3. Mokdad AA, Lopez AD, Lozano R, Mokdad AH, Stanaway J, Murray CJL, Nghavi M. Liver cirrhosis mortality in 187 countries between 1980 and 2010: a systematic analysis. **BMC Med** 2014; 12: 145.
4. Wang FS, Fan JG, Zhang Z, Gao B, Wang HY. The global burden of liver disease: the major impact of China. **Hepatology** 2014; 60: 2099–2108.
5. Colark E, Ustuner MC, Tekin N, Colark E, Burukoglu D, Degirmenci I, Gunes HV. The hepatocurative effects of *Cynara scolymus* L. leaf extract on carbon tetrachloride-induced oxidative stress and hepatic injury in rats. **SpringerPlus** 2016; 5: 1–9.
6. Adeneye AA. Protective activity of the stem barks aqueous extract of *Musanga cecropioides* in carbon tetrachloride- and acetaminophen-induced acute hepatotoxicity in rats. **Afr J Tradit Complement Altern Med** 2009; 6: 131–138.
7. Ahmed H, Zahab HAE, Alswiai G. Purification of antioxidant protein isolated from *Peganum harmala* and its protective effect against CCl₄ toxicity in rats. **Turk J Biol** 2013; 37: 39–48.
8. Hussain L, Ikram J, Rehman K, Tariq M. Hepatoprotective effects of *Malva sylvestris* L. against paracetamol-induced hepatotoxicity. **Turk J Biol** 2014; 38: 891–896.
9. Lee IC, Kim SH, Baek HS, Moon SH, Kim YB, Yun WK, Kim HC, Kim JC. Protective effects of diallyl disulfide on carbon tetrachloride-induced hepatotoxicity through activation of Nrf2. **J Environ Toxicol** 2015; 30(9): 538–540.
10. Zhang M, Pan L, Jiang S, Mo Y. Protective effects of anthocyanin from purple sweet potato on acute carbon tetrachloride-induced oxidative hepatotoxicity fibrosis in mice. **Food Agric Immunol** 2015; 27: 157–170.
11. Zhao X, Quian Y, Li G, Tan J. Preventive effects of polysaccharide of *Larimichthys crocea* swim bladder on carbon tetrachloride (CCL₄)-induced damage. **Chin J Nat Med** 2015; 13: 521–528.
12. Wakawa H, Ira M. Protective effects of *Camellia sinensis* leaf extract against Carbon tetrachloride –induced liver injury in rats. **Asian J Biochem** 2015; 10: 86–92.
13. Wakawa H, Franklyne EA. Protective effects of *Abrus precatorius* leaf extract against carbon tetrachloride- induced liver injury in rats. **J Nat Sci Res** 2015; 5: 15–19.
14. Williams AF, Clement YN, Nayak SB, Rao AVC. *Leonotis nepetifolia* protects against acetaminophen-induced hepatotoxicity: histological studies and the role of antioxidant enzymes. **Nat Prod Chem Res** 2016; 4: 222.
15. Xin Y, Wei J, Chunhua M, Danhong Y, Jianguo Z, Zonqqi C, Jianam B. Protective effects of Ginsenoside Rg1 against carbon tetrachloride-induced liver injury in mice through suppression of inflammation. **Phytomed** 2016; 23: 583–588.
16. Al-Asmari AK, Al-Elaiwi AM, Athar MT, Tariq M, Al-Eid MA, Al-Asmary SM. Review of hepatoprotective plants used in Saudi traditional medicine. **Evid Based Complement Alternat Med** 2014; 2014: 1–22.
17. El-Hadary AE, Ramadan MF. Potential protective effect of cold-pressed *Coriandrum Sativum* oil against carbon tetrachloride-induced hepatotoxicity in rats. **J Food Biochem** 2015; 40: 190–200.
18. Sharma N, Shukla S. Hepatoprotective potential of aqueous extract of *Butea monosperma* against CCl₄ -induced damage in rats. **Exp Toxicol Pathol** 2011; 63: 671–676.
19. Ghanem MT, Radwan HM, Mahdy EL-SM, Elkholy YM, Hassanein HD, Shahat A. Phenolic compounds from *Foeniculum vulgare* (Subsp. Piperitum) (Apiaceae) herb and evaluation of hepatoprotective antioxidant activity. **Pharmacogn Res** 2012; 4: 104–108.
20. Shehab NG, Abu-Gharbieh E, Bayoumi FA. Impact of phenolic composition on hepatoprotective and antioxidant effects of four desert medicinal plants. **BMC Complement Altern Med** 2015; 15: 401.
21. Gupta RK, Patel AK, Shah N, Chaudhary AK, Jha UK, Yadav UC, Gupta PK, Pakuwal U. Oxidative stress and antioxidants in disease and cancer: a review. **Asian Pac J Cancer Prev** 2014; 2014(15): 4405–4409.
22. Lobo V, Patil A, Phatak A, Chandra N. Free radicals, antioxidants and functional foods: impact on human health. **Pharmacogn Rev** 2010; 4: 118–126.
23. Agati G, Azzarello E, Pollastri S, Tattini M. Flavonoids as antioxidants in plants: location and functional significance. **Plant Sci** 2012; 196: 67–76.
24. Gill LS. *Ethnomedicinal uses of plants in Nigeria*. Nigeria: UNIBEN Press; 1992. pp. 222–223.
25. Gregory H, Kathleen AK. Reproductive phenology of a tropical canopy tree, *Spondias mombin*. **Biotropica** 2000; 32: 686–692.
26. Burkill H. *The useful plants of West Africa*, vol. 1. Kew, UK: Royal Botanic Gardens; 1985.
27. Amadi ES, Oyeka A, Onyeagba RA, Okoli I. Studies on the antimicrobial effects of *Spondias mombin* and *Baphia nittida* on dental caries organism. **Pak J Biol Sci** 2007; 10: 393–397.
28. da Silva ARA, de Moraes SM, Marques MM, de Oliveira DF, Barros CC, de Almeida RR, Vieira IG, Guedes MI. Chemical composition, antioxidant and antibacterial activities of two *Spondias* species from Northeastern Brazil. **Pharm Biol** 2012; 50: 740–746.
29. Corthout J, Pieters L, Claeys M, Berghe DV, Vlietinck AJ. Antivirally active gallotannins from *Spondias mombin*. **Planta Med** 1988; 54: 573.
30. Nworu CS, Akah PA, Okoye FB, Toukam DK, Udeh J, Esimone CO. The leaf extract of *Spondias mombin* L. displays an anti-inflammatory effect and suppresses inducible formation of tumor necrosis factor- α and nitric oxide (NO). **J Immunotoxicol** 2011; 8: 10–16.
31. Ademola IO, Fagbemi BO, Idowu SO. Anthelmintic activity of extracts of *Spondias mombin* against gastrointestinal nematodes of sheep: studies in vitro and in vivo. **Trop Anim Health Prod** 2005; 37: 223–235.
32. Hamenoo NA. *Hepatoprotective and toxicological assessment of Spondias mombin L. (Anacardiaceae) in rodents*. MSc. Thesis submitted to Kwame Nkrumah University of Science & Technology, Kumasi Ghana; 2010. pp. 15–17.
33. Asuquo OR, Ekanem TB, Eluwa MA, Oko OO, Ikpi DE. Evaluation of toxicological effects of *Spondias mombin* in adult male Wistar rats. **J Nat Sci Res** 2012; 2: 144–151.
34. Njoku PC, Akumefula MI. Phytochemical and nutrient evaluation of *Spondias mombin* leaves. **Pak J Nutr** 2007; 6: 613–615.
35. Awogbindin IO, Tade OJ, Metibemu SD, Olorunsogo OO, Farombi EO. Assessment of flavonoid content, free radical scavenging and hepatoprotective activities of *Ocimum gratissimum* and *Spondias mombin* in rats treated with dimethylnitrosamine. **Arch Bas App Med** 2014; 2: 45–54.

36. National Institute of Health (NIH). number 28, august 16. **Revised guide for the care and use of laboratory animals NIH guide**, vol. 25; 1996.
37. Trease GE, Evans WC. *A textbook of pharmacognosy*. London: Baillière Tindall; 2001. p. 600.
38. Lorke D. A new approach to practical acute toxicity testing. **Arch Toxicol** 1983; 54: 275–289.
39. Pareek A, Godavarthi A, Issarani R, Nagori BP. Antioxidant and hepatoprotective activity of *Fagonia schweinfurthii* (Hadidi) Hadidi extract in carbon tetrachloride induced hepatotoxicity in HepG2 cell line and rats. **J Ethnopharmacol** 2013; 150: 973–981.
40. Ellman GL. Tissue Sulfhydryl groups. **Arch Biochem Biophys** 1959; 82: 70–77.
41. Aebi HE. Catalase. In: Bergmeyer H, Verlag C, Weinheim A, editors. *Methods of enzymatic analysis*. 3rd ed. Weinheim. Germany: Verlag Chemie; 1983. pp.273–277.
42. Kakkar P, Das B, Viswanathan PN. A modified spectrophotometric assay of superoxide Dismutase. **Indian J Biochem Biol** 1984; 21: 130–132.
43. Draper HH, Hadley H. Malondialdehyde determination as index of lipid peroxidation. **Methods Enzymol** 1990; 186: 421–431.
44. Tan PV, Boda M, Enow-Orock GE, Etoa F, Bitolog P. Acute and sub-acute toxicity profile of the aqueous stem bark Extract of *Enantia chlorantha* Oliver (Annonaceae) in Laboratory animals. **Pharmacol Online** 2007; 1: 304–313.
45. Adebisi OE, Abatan MO. Phytochemical and acute toxicity of ethanolic extract of *Enantia chlorantha* (oliv) stem bark in albino rats. **Interdiscip Toxicol** 2013; 6: 145–151.
46. Giannini EG. Review article: thrombocytopenia in chronic liver disease and pharmacologic treatment options. **Aliment Pharmacol Ther** 2006; 23: 1055–1065.
47. Obidah W, Garba GK, Fate JZ, Wakawa HY. Protective effect of *Bixa orellana* seed oil on carbon tetrachloride induced liver damage in rats. **JOLORN** 2010; 11: 19–23.
48. El-Sayed YS, Lebda MA, Hassinin M, Neoman SA. Chicory (*Cichorium intybus* L.) root extract regulates the oxidative status and antioxidant gene transcripts in CCl₄-induced hepatotoxicity. **PLoS One** 2015; 10: e0121549.
49. Perez- Gutierrez RM, Solis RV. Hepatoprotective and inhibition of oxidative stress in liver of *Prostechea michuacana*. **Rec Nat Prod** 2009; 3: 46–51.
50. Dahiru D, Mamman DN, Wakawa HY. *Ziziphus mauritiana* fruit extract inhibits carbon tetrachloride-induced hepatotoxicity in male rats. **Pak J Nutr** 2010; 9: 990–993.
51. Reckangale RO, Glende EA, Ugazio G, Koch RR, Sriniva SS. New data in support of lipid peroxidation of carbon tetrachloride liver injury. **Isr J Med Sci** 1974; 10: 301–307.
52. McCay PB, Lai EK, Poyer JL, DuBose CM, Janzen EG. Oxygen and carbon-centred free radical formation during carbon tetrachloride metabolism. **J Biol Chem** 1984; 259: 2135–2143.
53. Adebayo AH, Abolaji AO, Kela R, Oluremi SO, Owolabi OO, Ogungbe OA. Hepatoprotective activity of *Chrysophyllum albidum* against carbon tetrachloride induced hepatic damage in rats. **Canadian J Pure Appl Sci** 2011; 2: 1597–1602.
54. Spolarics Z, Meyenhofer M. Augmented resistance to oxidative stress in fatty rat livers induced by a short-term sucrose-rich diet. **Biochim Biophys Acta** 2000; 1487: 190–200.
55. Piemonte F, PasStose A, Tozzi G, Taqliacozzi D, Santorelli FM, Carozzo R, Cassali C, Damiano M, Fderici G, Bertini E. Glutathione in blood of patients with Friedreich's ataxia. **Eur J Clin Invest** 2001; 31: 1007–1011.
56. Valencia E, Marin A, Hardy G. Glutathione nutritional and pharmacological viewpoints: Part II. **Nutrition** 2001; 17: 485–486.
57. Adesonoye OA, Farombi EO. Hepatoprotective effects of *Vernonia amygdalina* (Asteraceae) in rats treated with carbon tetrachloride. **Exp Toxicol Pathol** 2010; 62: 197–206.
58. Maksimovic Z, Kovacevic N, Lakusic B, Cebovic T. Antioxidant activity of yellow Dock (*Rumex crispus* L., Polygonaceae) fruit extract. **Phytother Res** 2011; 25: 101–105.
59. Tran QI, Adnyana IK, Tezuka Y, Nagaoka T, Tran QK, Kadota S. Triterpene saponins from Vietnamese ginseng (*Panaxvietnamensis*) and their hepatocytoprotective activity. **J Nat Prod** 2001; 64: 456–461.
60. Gupta M, Mazumder UK, Kumar TS, Gomathi P, Kumar RS. Antioxidant and hepatoprotective effects of *Bauhinia racemosa* against paracetamol and carbon tetrachloride-induced liver damage in rats. **Iran J Pharmacol Therapeut** 2004; 3: 12–20.
61. Salah N, Miller NJ, Paganga G, Tijburg L, Bolwell GP, Rice-Evans C. Polyphenolic flavonols as scavenger of aqueous phase radicals and chain-breaking antioxidants. **Arch Biochem Biophys** 1995; 322: 339–346.
62. Igwe CU, Onyeze GOC, Onwuliri VA, Osuagwu CG, Ojiako AO. Evaluation of the chemical compositions of the leaf of *Spondias mombin* linn from Nigeria. **Aust J Basic Appl Sci** 2010; 4: 706–710.
63. Adewusi EA, Afolayan AJ. A review of natural products with hepatoprotective activity. **J Med Plant Res** 2010; 4: 1318–1334.

How to cite this article: Nwidi LL, Elmorsy E, Obama YI, Carter WG. Hepatoprotective and antioxidant activities of *Spondias mombin* leaf and stem extracts against carbon tetrachloride-induced hepatotoxicity. *J Taibah Univ Med Sc* 2018;13(3):262–271.