

## Bleeding colonic spider angioma

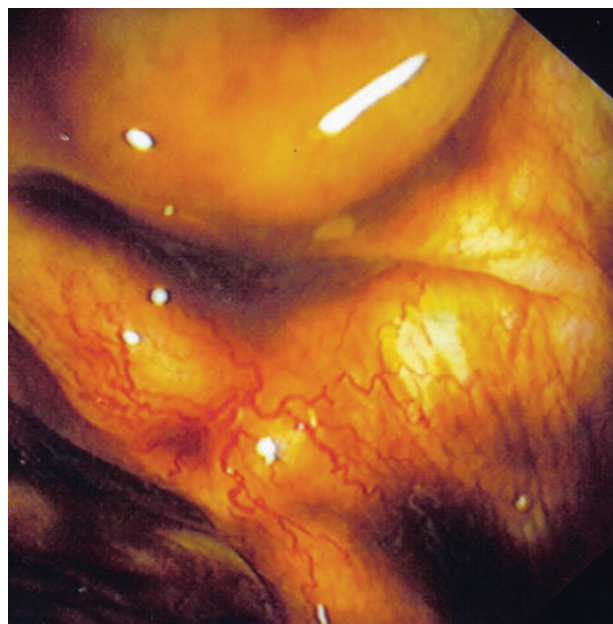
**Konstantinos H. Katsanos, Dimitrios E. Sigounas, Dimitrios K. Christodoulou, Epameinondas V. Tsianos**

University Hospital of Ioannina, Greece

Chronic liver disease is known to cause several skin manifestations, including cutaneous vascular changes such as palmar erythema and spider angioma. Spider angioma has been reported to be associated with severe chronic liver disease [1].

A 54-year-old male patient presented herein had diagnosed alcoholic cirrhosis for ten years and upper gastrointestinal endoscopy revealed grade III esophageal varices for which the patient was started on therapy with beta-blockers. The patient underwent endoscopy on emergency due to his first episode of massive gastrointestinal tract bleeding. No vasoactive drugs were administered. Upper endoscopy did not reveal the bleeding source and lower endoscopy was subsequently performed immediately afterwards with no preparation. The scope reached the cecum and terminal ileum and on descending colon a bleeding spider angioma was seen (Fig. 1). Argon plasma coagulation therapy was performed in one session with good results. Careful inspection of bowel mucosa did not reveal any other angioma. After the 4-month follow up the patient is still on beta-blockers and has no recurrence of his bleeding.

It has been suggested that cirrhotic patients with spider angiomas represent a group with high probability of relapsing variceal bleeding and pronounced esophageal varices. According to a study [2], spider angiomas were seen more commonly in patients with alcoholic cirrhosis than in those with non-alcoholic cirrhosis and in patients with Child's C cirrhosis rather than in those with Child's A and B cirrhosis. Spider angiomas are probable manifestations of endocrine imbalances in cirrhosis although the exact pathogenetic mechanism still remains unknown. Apart from the skin, unusual cases of massive bleeding from spider angiomas in the oral cavity and colon in association with cirrhosis of liver have been described [3]. Today, capsule endoscopy is providing new opportunities for small bowel investigation in these patients.



**Figure 1** Colonic spider hemangioma in a patient with cirrhosis

### References

1. Akiyama M, Inamoto N. Arteriovenous haemangioma in chronic liver disease: clinical and histopathological features of four cases. *Br J Dermatol* 2001;**144**:604-609.
2. Misra SP, Singh KJ, Dwivedi M, Misra V. Spider angiomas are not found in the retina of patients with cirrhosis. *J Assoc Physicians India* 1998;**46**:711-713.
3. Sood A, Midha V. Spider angiomas in the gastrointestinal tract. *Trop Gastroenterol* 2000;**21**:77.

1<sup>st</sup> Department of Internal Medicine & Hepato-Gastroenterology Unit, University Hospital of Ioannina, Greece

Conflict of Interest: None

Correspondence to: Prof. Epameinondas V. Tsianos, MD, PhD, AGAF, Professor of Internal Medicine, Department of Internal Medicine, Medical School, University of Ioannina, Leoforos Panepistimiou, 45 110 Ioannina, Greece  
Tel:++30-26510-07501, Fax:++30-26510-07016,  
e-mail: etsianos@uoi.gr

Received 7 December 2011; accepted 2 January 2012