

Modification in Contralateral Breast Flap in Delayed Autologous Breast Reconstruction

Hojjat Molaei^{1,2*}

1. Department of Plastic and Reconstructive Surgery, Razi Hospital, Tehran, Iran

2. Department of Plastic and Reconstructive Surgery, School of Medicine, Tehran University of Medical Sciences, Tehran, Iran

Please cite this paper as:

Molaei H. Modification in Contralateral Breast Flap in Delayed Autologous Breast Reconstruction. *World J Plast Surg.* 2024;13(1):103-105.

doi: 10.61186/wjps.13.1.103

DEAR EDITOR-IN-CHIEF

Breast reconstruction as staged procedure has its benefits and limitations. Following radiotherapy, implant based procedures might suffer complications accordingly. Therefore, some surgeons suggest autologous breast reconstruction surgeries. They support of this idea illustrating predictability and acceptable long term aesthetic and functional results. Among autologous breast replacement surgeries, free tissue transfers need special facility and expert surgeons who passed steeped learning curves. Thus, pedicle based flaps are generally accepted and adopted by plastic surgeons.

Contralateral breast flap presented by Marshal is a kind of pedicle flap based on medial perforators of breast¹. He proposed the procedure as two stages: during first stage, medial pedicle including NAC transferred to the previously mastectomy side. About weeks later, in the second operation, the attached pedicle was divided and extra tissues were reshaped to form breast monde in both sides. Viability of transferred flap is deeply dependent on preserving local perforators.

There are various types of loco-regional flaps in breast tissue replacement, but mostly discuss about ipsilateral reconstruction (2). Internal mammary artery perforators are reliable branches to harvest chest wall or even partial breast flaps. There are reports of supercharge micro anastomosis of breast tissue, too. Scaglioni et al reported a case of free flap of partial breast, which transferred to the contralateral side immediately after mastectomy based on internal mammary perforators, and anastomosed to perforators of other side³. We need expert surgeons to do such operations, but pedicle breast flap can be feasible for most of plastic surgeons. When the contralateral breast tissue crosses over the sternum, challenges may appear. It is not inevitable, because we need time before division of nourishing perforators. However, Jinguang et al presented their contralateral breast flap in one stage. They did flap de-epithelialization and demonstrated the final shape after 3 months without fullness over the midline⁴.

The patient was a 56 years old woman who underwent right modified radical mastectomy 12 years ago and asked to do breast reconstruction. She had huge ptotic left breast (Figure 1).

***Corresponding Author:**

Hojjat Molaei

Vali-e-asr Hospital, Imam Khomeini Hospital Complex, Khashavarz Bld., Tehran, Iran

Tel.: +989127798804

Email: hmolaei@sina.tums.ac.ir

Received: 11/4/2023

Accepted: 9/3/2024

Her request was reconstruction with autologous tissue without any surgery on abdomen. The patient was operated as below: left side breast reduction mammoplasty with supra-lateral pedicle with wise pattern incision and clockwise transfer of excess infra-

medial tissues to the contralateral side (Figure 2). About 3 months later, the second stage surgery was done and the flap was separated from its origin in left side. Internal mammary artery perforators were cut successfully and divided pedicle was folded bilaterally

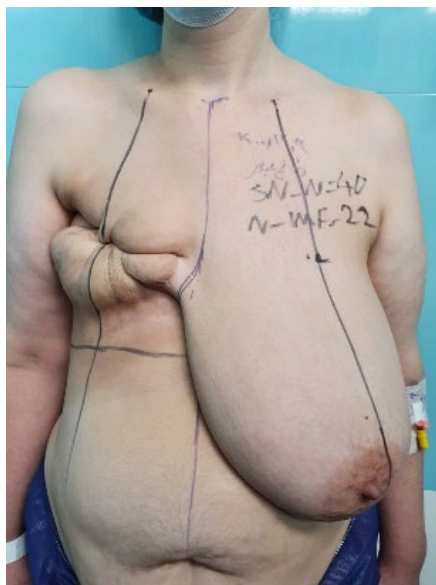


Figure 1: 56 years old woman with large left breast (SN-N= 40 cm) and right side mastectomy scar

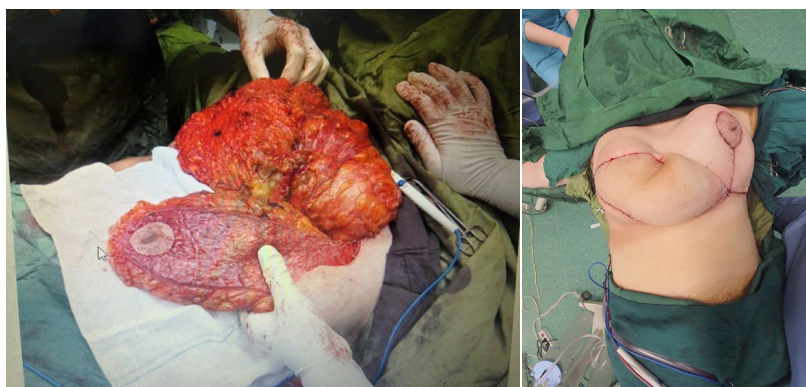


Figure 2: Left: de-epithelialized superolateral pedicle. Right: transferred tissue to opposite side

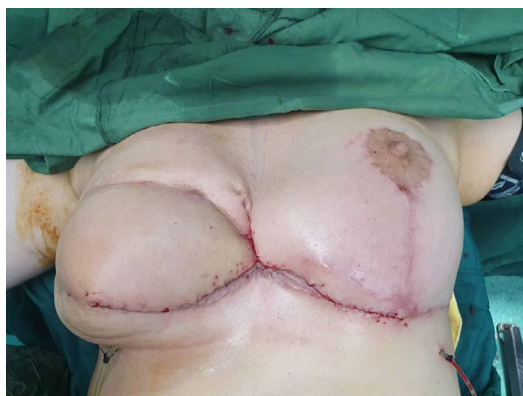

Figure 3: Flap division and reconstruction from contralateral breast

and secured under medial flaps of both breasts. At this stage, all previously transferred tissues were examined and any suspicious tissues were removed with less bleeding. At last, infra-medial Incisions of both breasts sutured accordingly (Figure 3).

The next decision was to do some refinement while nipple reconstruction, but she has not come back to do last surgery as she decided to postpone the surgery sometime.

This study was approved by Tehran University of Medical Sciences ethical committee with ID “IR.TUMS.IKHC.REC.1402.233”

Second primary carcinoma of the breast is the most concerning issue in these patients. Marshall prescribed this technique in older women who seemed have risk of contralateral breast cancer no more than normal population ¹. So, she was selected, as she was in postmenopausal period. On the other hand, Ramin et al evaluated risk factors for contralateral breast cancer and determined various factors as red flags in patient selection ⁵. In my opinion, older women who have huge contralateral breast with less pathologic risk factors might have good opportunity for this surgery. Moreover, it is possible to follow them by serial radiologic imaging like other patients.

FUNDING

The author received no financial support for the research, authorship, and publication of this article.

CONFLICT OF INTEREST

The author declared no potential conflicts of interest with respect to the research, authorship, and publication of this article.

REFERENCES

1. Marshall DR. The contralateral breast flap in reconstruction of the breast and chest wall. *Ann Plast Surg* 1993 Dec;**31**(6):508-13. doi: 10.1097/0000637-199312000-00006. PMID: 8297081.
2. Chartier C, Safran T, Alhalabi B, Murphy A, Davison P. “Locoregional perforator flaps in breast reconstruction: An anatomic review & quadrant algorithm”. *J Plast Reconstr Aesthet Surg* 2022 Apr;**75**(4):1328-1341.
3. Scaglioni, MF, Rodi, T, Wishart, K, Fritsche, E. Unilateral breast reconstruction with the free contralateral split breast flap using supermicrosurgical anastomosis: A case report. *Microsurgery* 2021; **41**: 258– 262.
4. Jinguang HE, Wang T, XU H, Zhang Y, Liu Y, Dong J. Pedicled or Free Flap from Contralateral Breast for Autologous Breast Reconstruction. *Chinese Journal of Plastic and Reconstructive Surgery* 2020 **2**(2): 103-106.
5. Ramin C, Mullooly M, Schonfeld SJ, Advani PG, Bodelon C, Gierach GL, Berrington de González A. Risk factors for contralateral breast cancer in postmenopausal breast cancer survivors in the NIH-AARP Diet and Health Study. *Cancer Causes Control* 2021 Aug;**32**(8):803-813.