

# Management of patients with condylar hyperplasia: A diverse experience with 18 patients

Access this article online

Website:  
www.amsjournal.com

DOI:  
10.4103/2231-0746.95311

Quick Response Code:



Ahmed Alyamani, Sondos Abuzinada

Department of Oral and Maxillofacial Surgery, King Abdulaziz University, Jeddah, Saudi Arabia

Address for correspondence:

Dr. Sondos Abuzinada, Department of Oral and Maxillofacial Surgery,  
King Abdulaziz University, Jeddah, Saudi Arabia.  
E-mail: [sondoz@hotmail.com](mailto:sondoz@hotmail.com)

## ABSTRACT

**Purpose:** The purpose was to report the clinical experience with patients diagnosed with Condylar Hyperplasia (CH).  
**Materials and Methods:** Eighteen patients with CH underwent condylar growth assessment using clinical and radiographic examinations. Seven patients with suspected active condyles underwent single photo emission computed tomography (SPECT) examination. A total of patients with asymmetry and malocclusion were treated with orthognathic surgery. Three patients with intact occlusion; underwent inferior border osteotomy with nerve repositioning. All patients were followed up for 3 years without any complications. **Conclusion:** There is great diversity in the clinical and radiographic presentation in cases with CH. Assessment of condylar growth activity is the cornerstone in managing these cases. After that each case has its own diverse treatment plan to achieve a satisfactory facial symmetry.

**Keywords:** Condylar hyperplasia, facial asymmetry, hemimandibular elongation, hemimandibular hypertrophy

## INTRODUCTION

Condylar hyperplasia (CH) is a complex deformity affecting the condyle and the mandible. It was first reported by Adams, in 1836.<sup>[1]</sup> CH causes an overdevelopment in the mandible and condyle. The resulting asymmetry and the significant functional deformities present a great challenge to both maxillofacial surgeons and orthodontists. This disorder is self-limiting, but the longer it persists the greater the developing asymmetry and associated occlusal changes.<sup>[2]</sup>

In the literature the term "condylar hyperplasia" is widely used. It generally describes an asymmetry developing with an abnormal condylar growth pattern. However, Obwegeser and Makek went on to describe two different deformities based on their clinical and radiographic observations, "Hemimandibular Elongation (HE)" and "Hemimandibular Hyperplasia (HH)". HH was characterized by a unilateral three-dimensional enlargement of the mandible including the condyle, the condylar neck, the ascending ramus, and was found to terminate at the symphysis. They noted that this

growth usually starts before puberty, so the maxilla follows the downward growth of the mandible and the teeth usually remain in occlusion. On the other hand, they described HE as a horizontal displacement of the mandible and chin to the unaffected side due to elongation in the condylar neck, with a displaced lower dental midline to the unaffected side and a lateral cross-bite on the affected side. In addition, they added the mixed forms which had varying degrees of combined forms. They emphasized the importance of differentiating HH from solitary hyperplasia of the condyle which is usually homogeneously enlarged.<sup>[3]</sup>

It is suggested not to use the term "condylar hyperplasia" to refer to either HH or HE, but to describe the condylar deformity that precedes the mandibular deformity occurs. In other words, progression of CH leads to HH or HE.<sup>[4]</sup> Most articles have used the term "condylar hyperplasia" to describe hemimandibular elongation,<sup>[5,6]</sup> while others used the term "hemimandibular hypertrophy" to describe hemimandibular hyperplasia.<sup>[7]</sup> The different terminologies used may cause some confusion, but the Obwegeser and Makek classification is still widely accepted

and has been used in this article for simplicity. Asymmetries developing from a hyperplastic condyle with a combination of HH and HE has been called the “hybrid form” as described in the literature.<sup>[3]</sup>

The first step in managing cases with CH is assessing condylar growth activity. This can be done using many methods. Bone scintigraphy is an effective diagnostic tool to confirm or exclude the progression of the deformity when correlated with the clinical findings.<sup>[5]</sup> In this article we report our experience with 18 cases. They all presented with facial asymmetry as a result of CH. We describe the different diagnostic and treatment methods used for each case. In addition we present a review of literature regarding the diagnosis and treatment methods used in cases with CH.

## MATERIALS AND METHODS

Eighteen patients with facial asymmetry resulting from condylar hyperplasia were evaluated and treated in this retrospective case series between 2003 and 2009 [Table 1].

The ages ranged between 17 and 54 years. A detailed history was obtained regarding the onset of the asymmetry and rate of progression. They underwent a routine clinical examination and records were taken which included facial and intraoral photographs. Dental cast models with bite registration verifying any canting, cross bite or open bite were also taken. Radiographic examination included orthopantomograms (OPG), posteroanterior (PA), and lateral cephalograms. Patients with severe asymmetry

underwent computed tomography (CT) examination with 3D reconstruction. Table 1 presents the demographic and diagnosis of all patients.

### Assessment

Patients who reported a rapid increase in the degree of asymmetry were the only ones who underwent bilateral temporomandibular joint scintigraphy with single photon emission computed tomography (SPECT) using <sup>99m</sup>Tc-labeled methylene diphosphonate. The areas of prominent uptake were noted and the relative uptake was calculated as described by Hodder *et al.*<sup>[6]</sup>

% Uptake in the right condyle = Right count/Left count × 100.

An initial scintigram was taken one at the first visit. If the relative uptake was 55% or more, the condyle was regarded as active in correlation with the clinical assessment and dental models. We also measured the percentile difference in uptake between both condyles for a more detailed assessment. A difference in uptake of more than 10% is considered active in correlation with clinical assessment and the relative uptake results.<sup>[8]</sup> If active growth continued to be noted with the aid of clinical assessment, the bone scan was repeated 6 months later and the two sets of records were compared [Table 2]. Patients who did not note any active clinical changes or any worsening in the degree of asymmetry were only clinically evaluated.

### Treatment plan

The treatment plan was established according to the degree of

**Table 1: Clinical details, assessment and management of patients with mandibular condylar hyperplasia**

Patient No	Age at presentation (Years)	Sex	Type of CH	Examination performed	Treatment
1	31	F	Right hybrid form	Clinical records, bone scan SPECT	Le Fort I, IVRO
2	27	F	Left HH	Clinical records	inferior border osteotomy with inferior alveolar nerve repositioning
3	20	F	Right HE	Clinical records, bone scan SPECT	Le Fort I, BSSO
4	35	F	Right HE	Clinical records, bone scan SPECT	Le Fort I, BSSO, genioplasty, soft tissue augmentation using fat
5	18	F	Left HE	Clinical records, bone scan SPECT	BSSO, genioplasty
6	28	M	Right hybrid	Clinical records, bone scan PLANAR	Le Fort I, BSSO
7	38	F	Left HH	Dental models, bone scan PLANAR	high condylectomy, inferior border osteotomy with inferior alveolar nerve repositioning
8	17	F	Left HE	Clinical records	Le Fort I, BSSO, genioplasty
9	40	M	Left HH	Clinical records	BSSO, genioplasty, inferior border osteotomy
10	19	F	Right HE	Clinical records, bone scan SPECT	Le Fort I, BSSO, genioplasty, Medpore left gonial implant
11	20	F	Left HE	Clinical records	Le Fort I, BSSO
12	23	F	Left hybrid form	Clinical records,	BSSO
13	17	F	Left HE	Clinical records	BSSO, genioplasty, medpore left side gonial implants
14	54	M	Left hybrid form	Clinical records	BSSO
15	23	F	Left HH	Clinical records, bone scan SPECT	Extended sagittal split on the left side with inferior border osteotomy /nerve repositioning/genioplasty
16	18	F	Right HE	Clinical records	Le fort I, BSSO, genioplasty
17	19	F	Right HE	Clinical records	Le Fort I, BSSO
18	35	F	Left HH	Clinical records, bone scan SPECT	Le Fort I, extended BSSO left side, genioplasty

HH: Hemimandibular hyperplasia, HE: Hemimandibular elongation, BSSO: Bilateral sagittal split osteotomy, clinical records; orthopantomograph, lateral cephalometric radiograph, and dental models

**Table 2: Single photon emission computed tomography uptake in patients with suspected active condylar growth**

Patient	Age (years)	SPECT Percentageuptake*		Percentile difference between right and left condyles†
		Right condyle	Left condyle	
1	31	58.74	41.26	17.48
	35	53.20	46.60	06.68
3	20	51.09	48.91	02.18
	21	57.74	42.26	15.00
4	38	53.19	46.81	06.38
	40	53.46	46.54	06.92
5	20	47.40	52.29	04.89
	22	44.88	54.12	09.24
10	18	56.03	43.97	12.60
	19	54.42	45.58	08.84
15	23	51.80	48.19	03.61
18	35	41.64	58.36	16.72

\*If scan uptake >55% active growth, †Percentile difference>10% active, SPECT: Single photon emission computed tomography

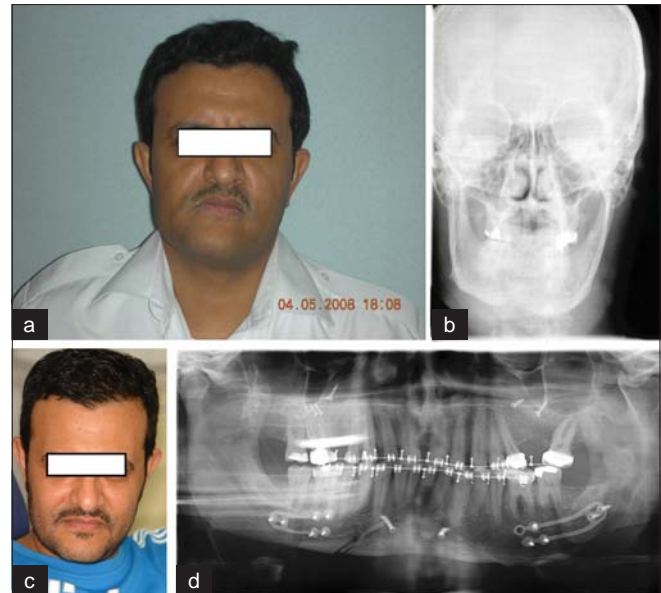asymmetry, the resulting malocclusion, and the condylar growth activity. Orthognathic surgery was performed for correction of any existing malocclusion. This is usually performed after completion of the presurgical orthodontic treatment. Orthognathic surgery included a combination of bilateral or unilateral mandibular osteotomies to correct the mandibular deviation, with or without Le Fort I leveling osteotomy according to the need to level occlusal plane when occlusal canting is observed. A genioplasty to correct any residual chin deviation or asymmetry when indicated is presented in Figure 1. It also shows facial recontouring for correction of facial asymmetry in patients with intact occlusion. Surgical correction included inferior border osteotomy and genioplasty. In patients who showed active condylar growth, a condylectomy was performed simultaneously with orthognathic and corrective bone surgery.

Final attention was directed toward the soft tissues which usually require correction especially in patients with longstanding condylar hyperplasia that has lead to severe asymmetry over a long time period. Soft tissue procedures include face lifts or augmentation using medpore implants or fat grafts.

## RESULTS

Table 1 shows a list of all eighteen patients including their demographic and clinical data. A total of 15 females and three males. The mean age was 23 years (range 17-54 years). The main complaint was facial asymmetry. A total of 10 patients presented with a vertical asymmetry. Five patients presented with a transverse asymmetry and three presented with the combination of both. All patients with a vertical asymmetry showed canting in the occlusal plane and only one patient with the combination form showed canting in the occlusal plane.

The radiographic evaluation showed an elongated condyle, hemimandibular elongation (HE) in nine patients and a hemimandibular hyperplasia (HH) in five patients. Four patients presented with an enlarged and elongated condyle (combination of HE and HH).



**Figure 1:** (a) Clinical picture showing chin deviation to the right side and facial asymmetry. (b) Posteroanterior radiograph showing hyperplasia in the left condylar region. (c) Postoperative clinical picture. (d) Postoperative orthopantogram showing BSSO and genioplasty fixation

Patients with HE who underwent CT examination showed an elongated condylar neck and the mandibular body was displaced toward the normal side. Patients who presented with HH showed an enlarged condylar head, neck, ramus, and body. The mandibular angle was displaced inferiorly so was the inferior alveolar nerve. The rest of the cases which presented with a combination (hybrid form) showed variable CT images which included an elongated condylar neck with some enlargement in the ramus [Figure 1]. Others showed a three-dimensional enlargement in condylar head and neck.

### Bone scan

The initial results in four patients who underwent a bone scan showed a relative uptake of less than 55% between the condyles. They were then evaluated using clinical methods only every 6 months during the presurgical orthodontic phase [Table 2]. Four patients(1,3,10,18) showed a relative uptake of more than 55% in one of the condyles. They underwent another bone scan during their orthodontic treatment, in addition to the clinical assessment, until no signs of condylar growth were noted. Two patients(1,3) had a relative uptake <55% in the right condyle upon completion of orthodontic treatment and the condyle was considered inactive when correlated with their clinical assessment. In the final scan the difference in uptake between condyles was less than 5 in all six patients except for two patients (3,7) who were assessed clinically and showed no growth. One patient (9) presented at the initial consultation with a planar scintigraphy which was done at different center and it showed increased uptake. She had severe left TMJ symptoms, but refused to undergo a SPECT scan and was therefore assessed clinically by comparing previous records which showed clinical signs of active growth.

### Surgical treatment

A total of 15 patients with inactive condyles and malocclusion underwent orthognathic surgery. Ten of them underwent double

jaw orthognathic surgery using Le Fort I and BSSO. One patient underwent IVRO and Le Fort I leveling osteotomy [Figure 2]. Three patients underwent single jaw BSSO and genioplasty [Figure 3]. Patients with inactive condyles and intact occlusion were managed as follows: one underwent an extended sagittal split osteotomy on the affected side and genioplasty [Figure 3]. Two patients underwent inferior border osteotomy with inferior alveolar nerve repositioning and genioplasty. Only one patient required a condylectomy with inferior border osteotomy with inferior alveolar nerve repositioning [Figure 4].

All patients showed satisfactory occlusal and bony correction after undergoing the initial surgical phase. However, soft tissue assessment showed some residual asymmetry in three patients with HE (4,10,13) This required correction using medpore gonial implants in the elongated side in two patients and fat grafting in one patient to augment the cheek region.

### DISCUSSION

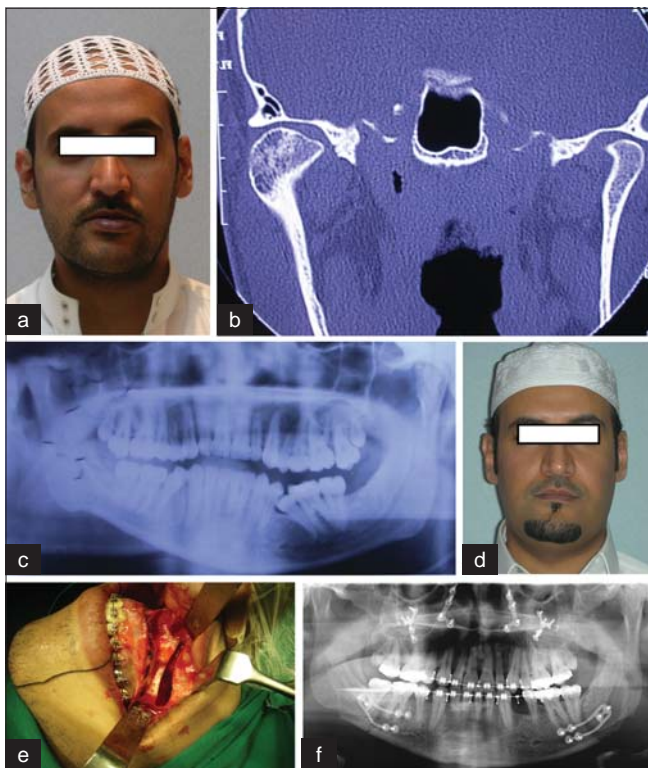
Facial asymmetry resulting from condylar hyperplasia has a diverse presentation. All patients listed in this article presented with various degrees of asymmetry and malocclusion despite all being diagnosed with condylar hyperplasia. We did in fact follow the Obwegeser and Makek classification of CH.<sup>[3]</sup> However, we

found no strict correlation between the clinical features and the radiographic features of HH and HE. We also presented some asymmetries developing from a hyperplastic condyle showing a combination of HH and HE. For such cases we used the term “hybrid form” as described in the literature.<sup>[3,6,8]</sup>

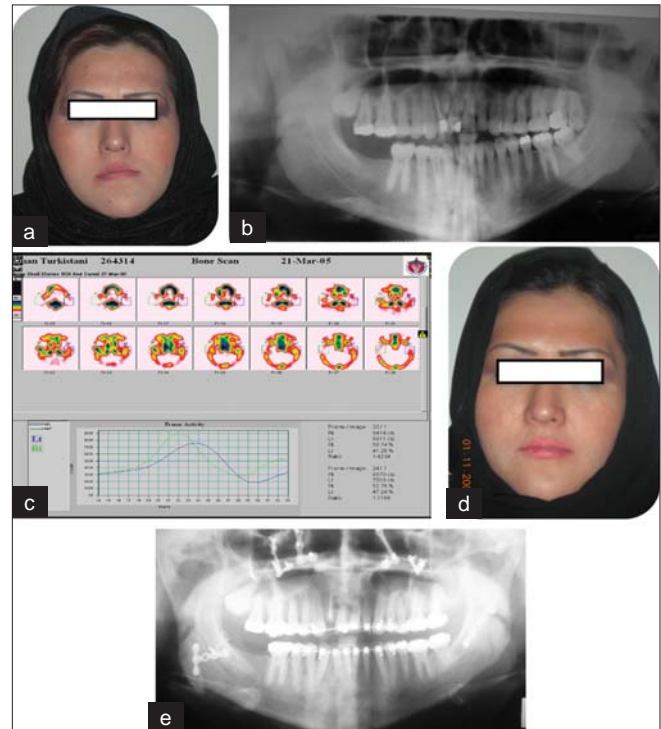
The age of onset has not been agreed upon. The literature noted a female predilection.<sup>[9]</sup> However, other studies found a male predilection,<sup>[2]</sup> while others have found an equal predilection between males and females.<sup>[10]</sup> We found a female predilection as 14 of our 17 patients were females. It has been reported that there is an increased number of estrogen receptors in the temporomandibular joint in females and this could be the cause for the increased growth activity.<sup>[9,11,12]</sup>

Some studies mentioned that CH occurs between 10 and 30 years of age.<sup>[2]</sup> Other studies presented a wider age range between 19 and 37 years<sup>[11]</sup> and 14 and 59 years. Our patients had an age range of 17–55 years. However, many of these patients did not seek treatment except at the late stage of the deformity.

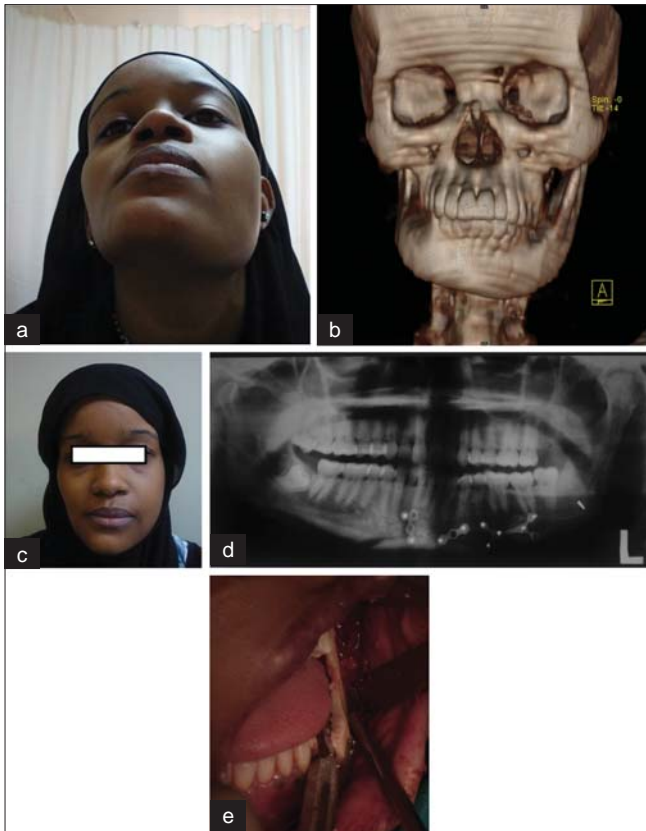
It has been noted that the radiographic appearance varies and sometimes fails to demonstrate the typical Obwegeser and Makek CH classification system.<sup>[2]</sup> Sometimes normally shaped condyles were part of an asymmetric mandible. A random radiologic appearance was observed in some patients for example one patient presented with a mandibular asymmetry and a unilateral posterior open bite. However, her OPG showed an elongated



**Figure 2:** (a) Patient 6: preoperative clinical picture showing mandibular asymmetry with downward displacement of left mandibular angle and chin deviation to the right. (b) CT scan coronal section showing three dimensional enlargement of left condyle. (c) Orthopantomogram (OPG) showing enlarged left condyle with downward displacement of gonial angle. (d) Postoperative clinical picture. (e) Intraoperative picture showing Le Fort I leveling osteotomy. (f) Postoperative OPG showing Le Fort I leveling osteotomy and BSSO osteotomy



**Figure 3:** (a) Patient 1: clinical picture showing severe mandibular asymmetry with chin deviation to the left and flattening in the right side of the face. (b) Orthopantomogram (OPG) showing elongated condyle and enlarged right vertical and horizontal ramus. (c) Bone scintigraphy showing increased uptake in left condyle. (d) Postoperative clinical picture. (e) OPG showing IVRO and Le Fort I osteotomy



**Figure 4:** (a) Clinical picture showing severe left mandibular asymmetry. (b) CT scan showing 3D enlargement of the left side of mandible. (c) Postoperative clinical pictures. (d) orthopantogram showing extended BSSO (Furgson technique) on the left side (e) intraoperative picture showing extended BSSO

condyle and according to the Obwegeser classification a posterior cross bite usually seen in HE. Radiographs showed an elongated condyle in nine patients and an enlarged condylar head and neck along with the ramus and mandibular body in five patients. The radiographs for the remaining four patients showed variable atypical forms. As reported by Nitzan we observed adversity in the radiographic features of CH.<sup>[2]</sup>

The value of CT images and 3D reconstruction in the diagnosis of CH and the resulting mandibular asymmetry has been emphasized in the literature.<sup>[13]</sup> The exact location and degree of the deformity can be detected clearly. Moreover, the atypical and hybrid forms of CH are better appreciated. Most of our patients underwent a CT examination especially those who presented with a severe asymmetry or displayed an atypical condylar form or shapes on plain radiographs.

#### Bone scan

The assessment of the condylar growth activity is essential in treating the asymmetry. Clinical assessment using dental casts by recording any changes in the dental occlusion and the dental midline can be used, but it will require at least two measurements 6 months apart. Clinical assessment can be supplemented with bone scintigraphy to show areas of increased osteoblastic activity using the bone seeking radiopharmaceutical agent <sup>99</sup>Tc-labelled

methylene diphosphonate.<sup>[13]</sup> Two types of bone scintigraphy images have been mentioned in the literature. The planar and the single photon emission computed tomography (SPECT). Kaban *et al.* first reported the use of planar scintigraphy in assessing condylar growth.<sup>[13,14]</sup> The two condyles were evaluated using two lateral views and then considering the normal isotope deposit in the fourth lumbar vertebra or using the unaffected condyle as a reference. It was done qualitatively without quantification. Therefore, it is subjective and may lead to false positive or false negative results.

It is suggested that quantitative assessments are more accurate. SPECT has been used with quantitative assessment of one condyle to the clivus or lumbar spine. Pogrel *et al.* compared between SPECT and planar images for quantitative skeletal scintigraphy of the mandible condyle. They compared the uptake ratio for condyle to clivus with SPECT and condyle uptake with L4 using planar scans. It was easier to perform and had better reproducibility than the planar scan.<sup>[13]</sup> Hodder *et al.* assessed the condylar growth using the Planar images initially along with clinical assessment. If the planar scan result was abnormal, a SPECT bone scan was used and was repeated 6 months later. The relative uptake between left and right condyle was calculated as follows:

$$\% \text{ Uptake in right condyle} = \frac{\text{right count}}{\text{left count} + \text{right count}} \times 100.$$

A difference in uptake of 10% or more between condyles was regarded as indicative of condylar hyperplasia and the affected condyles had a relative uptake of 55% or more. They concluded that the quantitative bone SPECT used to compare both condyles is helpful in assessing bone activity. They also concluded that comparison of condyles to basal bone activity was not necessary.<sup>[6]</sup>

We used this method in Table 2 and correlated it with the clinical assessment. SPECT scan was found to be a valuable initial tool in assessing active growth, but it was not regarded as the main indicator of growth due to the possibility of giving false positive results in cases with TMJ inflammation as observed in patients<sup>[3,14]</sup> where the uptake result was > 55% but the clinical assessment showed no progression in asymmetry.

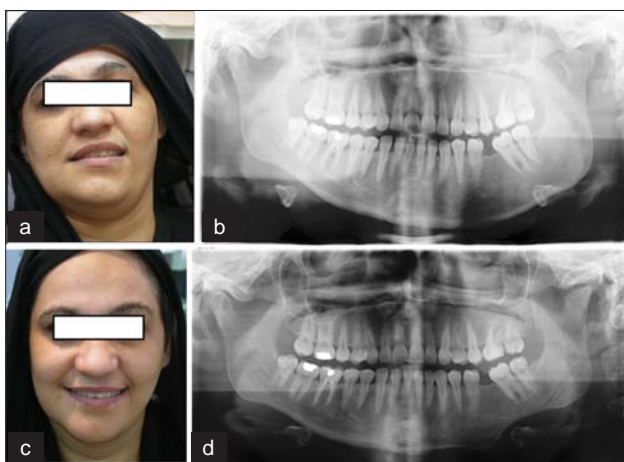
Pripatnanont *et al.* used the SPECT to evaluate growth cessation of the mandible in unilateral condylar hyperplasia. They relied on clinical assessment every 6 months and a single SPECT scan. They compared the percentile uptake of both condyles and concluded that if the percentile difference was less than 10%, it was considered to be normal.<sup>[14]</sup> On the other hand, other articles were published noting that a percentile difference between both condyles greater than 6.2% in males and 5.7% in females is considered abnormal.<sup>[15,16]</sup> When we measured the percentile difference in uptake [Table 2], we found them to be more than 10% in active condyles. However, in some female patients with clinically inactive condyles the percentile uptake was > 5.7% and > 6.2% in males with percentile uptakes of less than 55% in both condyles. This may contradict the studies mentioned earlier and these values were not taken into consideration.<sup>[16]</sup>

#### Treatment

The treatment of the asymmetry resulting from CH is as variable as

the condition itself. However, the common ground is determining condylar growth activity first. If condylar growth was found to be inactive the surgical correction of asymmetry mainly depends on the degree of the asymmetry and the resulting malocclusion. This usually includes a selection of, Le Fort I leveling osteotomy in cases with an occlusal cant in addition to BSSO or IVRO to correct the mandibular shift, and genioplasty. This was applied to most of our patients with HE and the combination (hybrid type), yet some only underwent BSSO without the need for maxillary or chin correction. Some have suggested performing unilateral vertical ramus or sagittal split osteotomy at the hyperplastic site, but we did not perform this technique<sup>[10]</sup>. We found that patients with HH usually require an inferior border mandibular osteotomy with nerve repositioning. This was clearly demonstrated in two patients who also needed a genioplasty. Sometimes the asymmetry was so severe that a correction of the malocclusion and inferior border osteotomy is required. In such cases we applied an extended mandibular sagittal split as described by Ferguson<sup>[17]</sup> [Figure 5].

When the condyles show active growth, the management becomes even more diverse. Some authors have advocated condylectomy in actively growing condyles especially in immature patients. It is performed as early as 10–12 years to avoid further deformities from developing and possible normalization of occlusion and facial asymmetry spontaneously. Therefore, sparing the patients the need for orthognathic surgery at an older age.<sup>[8]</sup> However, in older patients condylectomy is still controversial. Some authors perform condylectomies routinely with orthognathic surgery when growth is noted to prevent relapse.<sup>[18,19,20]</sup> Others avoided condylectomy and postponed the surgery until condylar growth has subsided in fear of possible functional alterations after condylectomy. We have adopted this protocol as most of our patients were adults (over 17 years). Moreover, the asymmetry and malocclusion was already quite evident and advanced due to the condylar growth. Only one patient with HH underwent condylectomy due to a suspected active condyle and severe TMJ



**Figure 5:** (a) Patient 7: clinical pictures showing mandibular asymmetry. (b) Orthopantomogram (OPG) showing three-dimensional enlargement of the left condyle and mandibular ramus and body with downward displacement of inferior alveolar nerve. (c) Intraoperative picture showing extended sagittal split mandibular osteotomy on the left side. (d) Postoperative OPG showing inferior border osteotomy and contouring with nerve repositioning and left condylectomy. (e) Postoperative clinical picture

symptoms. This showed very positive cosmetic and functional results. Published articles have demonstrated the effectiveness of condylectomy only in managing adult patients with active condylar hyperplasia.<sup>[21]</sup>

A recent study evaluated condylar function in patients with active CH who underwent condylectomy. They found a good condylar function, if the patients followed a postoperative physiotherapy schedule and they suggested that condylectomies must be considered in treatment of active CH in adults as well as growing children with CH.<sup>[22]</sup> Further prospective comparative studies are needed to compare protocols including the time of rehabilitation needed and the correction in facial symmetry and occlusion after condylectomy.<sup>[22]</sup> Most of these patients require adjunctive soft and hard tissue procedures to correct the residual facial asymmetry after undergoing surgical correction of the underlying bony foundation. These procedures include soft tissue augmentation using fat injections, medpore or silicone facial implants. There is no rule to correcting this residual deformity; however we did notice that the HE type usually required augmentation in the elongated side and cases with the HH type required augmentation in the normal side.

## CONCLUSION

We have reported our diverse experience in managing patients with CH. There is a great diversity in the clinical and radiographic forms of CH and the resulting mandibular asymmetry. In addition, the clinical presentation does not necessarily correlate with the radiographic picture or form. Many methods are used to assess condylar growth activity, but the clinical assessment using dental models and radiographs is highly accepted along with the aid of SPECT scan if and when available.

The management of asymmetry resulting from CH is as diverse as the condition itself. However, assessment of condylar growth activity is the initial step. The age of the patient, the severity of the asymmetry, and resulting malocclusion. TMJ symptoms and pain are also important factors to consider. If a child or a young patient presents with a mild developing mandibular asymmetry, a condylectomy is best performed at an early stage followed by functional rehabilitation to prevent further progression of the asymmetry which may require a more complex treatment in the future.

Adults with a progressive mandibular asymmetry and malocclusion with no active condylar growth are best treated with orthognathic surgery. However, patients with facial asymmetry and intact occlusion can be treated with mandibular inferior border osteotomy and facial recontouring according to the severity of the asymmetry. Condylectomies are reserved for cases with active condylar growth and TMJ pain. This can be performed simultaneously with orthognathic surgery and mandibular osteotomies or at an earlier stage.

Last but not least, it is almost impossible to achieve complete symmetry in patients with CH even after undergoing soft and hard tissue touch ups. The patient must be made well aware of this point in order to avoid unnecessary disappointment at the end of treatment.

## REFERENCES

- Adams R. The disease in the temporomandibular articulation or joint of the lower jaw. A treatise on rheumatic gout or chronic rheumatism of all the joints. 2<sup>nd</sup> ed. London: Churchill; 1873. p. 271.
- Nitzan D, Katsnelson A, Bermanis I. The clinical characteristics of condylar hyperplasia: Experience with 61 patients. *J Oral Maxillofac Surg* 2008;66:312-8.
- Obwegeser H, Makek M. Hemimandibular hyperplasia – Hemimandibular elongation. *J Maxillofac Surg* 1986;14:183-208.
- Lippold C, Kruse-Losler B, Danesh G. Treatment of hemimandibular hyperplasia: The biological basis of condylectomy. *Br J Oral Maxillofac Surg* 2007;45:353-60.
- Yang J, Lignelli JL, Ruprecht A. Mirror-image condylar hyperplasia in two siblings. *Oral Surg Oral Med Oral Pathol Oral Radiol Endod* 2004;97:281-5.
- Hodder SC, Rees JL, Oliver TB, Facey PE, Sugar AW. SPECT bone scintigraphy in the diagnosis and management of mandibular condylar hyperplasia. *Br J Oral Maxillofac Surg* 2000;38:87-93.
- Chen Y, Bendor-Samuel R, Huarg C. Hemimandibular Hyperplasia. *Plast Reconstr Surg* 1996;97:730-7.
- Wolford LM, Morales-Ryan CA, Garcia-Morales P, Perez D. Surgical management of mandibular condylar hyperplasia type 1. *Proc (Bayl Univ Med Cent)* 2009;22:321-9.
- Raijmakers PG, Karssemakers LH, Tuizing DB. Female Predominance and effect of gender on unilateral condylar hyperplasia: A review and meta-analysis. *J Oral Maxillofac Surg* 2012;70:e72-6.
- Motamedi MH. Treatment of condylar hyperplasia of the mandible using unilateral ramus osteotomies. *J Oral Maxillofac Surg* 1996;54:1161-9; discussion 1169-70.
- Ribeiro-Dasilva MC, Peres Line SR, Leme Godoy dos Santos MC, Arthuri MT, Hou W, Fillingim RB, *et al*. Estrogen receptor-alpha polymorphisms and predisposition to TMJ disorder. *J Pain* 2009;10:527-33.
- Mutoh Y, Ohashi Y, Uchiyama N. Three dimensional analysis of condylar hyperplasia with computed tomography. *J Craniomaxillofac Surg* 1991;19:49-55.
- Pogrel MA, Kopf J, Dodson TB, Hattner R, Kaban LB. A comparison of single photo emission computed Tomography and planar imaging. *Oral Surg Oral Med Oral Pathol Oral Radiol Endod* 1995;80:226-31.
- Pripatnanont P, Vittayakittipong P, Markmanee U, Thongmak S, Yipintsoi T. The use of SPECT to evaluate growth cessation of the mandible in unilateral condylar hyperplasia. *Int J Oral Maxillofac Surg* 2005;34:364-8.
- Kajan ZD, Motevasseli S, Nasab NK, Ghanepour H, Abbaspur F. Assessment of growth activity in the mandibular condyles by single-photon emission computed tomography. *Aust Orthod J* 2006;22:127-30.
- Saridin C, Raijmakers P, Becking A. Quantitative analysis of planar bone scintigraphy in patients with unilateral condylar hyperplasia. *Oral Surg Oral Med Oral Pathol Oral Radiol Endod* 2007;104:259-63.
- Ferguson W. Definitive surgical correction of the deformity resulting from Hemimandibular hyperplasia. *J Craniomaxillofacial Surg* 2005;33:150-7.
- Brusati R, Pedrazzoli M, Colletti G. Functional results after condylectomy in active laterognathia. *J Craniomaxillofac Surg* 2010;38:179-84.
- Wolford M. Clinical Indications for Simultaneous TMJ and Orthognathic Surgery. *J Craniomandibular Pract* 2007;25:271-82.
- Wolford LM, Mehra P, Reiche-Fischel O, Morales-Ryan CA, Garcia-Morales P. Efficacy of high condylectomy for management of condylar hyperplasia. *Am J Orthod Dentofacial Orthop* 2002;121:136-51.
- Butt FM, Guthua SW, Nganga P, Edalia M, Dimba EA. One-stage treatment of acquired facial deformity caused by severe unilateral condylar hyperplasia. *J Craniofac Surg* 2011;22:1966-8.
- Saridin C, Gilijamse M, Kuik D. Evaluation of temporomandibular function after high partial condylectomy because of unilateral condylar hyperactivity. *J Oral Maxillofac Surg* 2010;68:1094-9.

**Cite this article as:** Alyamani A, Abuzinada S. Management of patients with condylar hyperplasia: A diverse experience with 18 patients. *Ann Maxillofac Surg* 2012;2:17-23

**Source of Support:** Nil, **Conflict of Interest:** None declared.

## New features on the journal's website

### Optimized content for mobile and hand-held devices

HTML pages have been optimized for mobile and other hand-held devices (such as iPad, Kindle, iPod) for faster browsing speed.

Click on **[Mobile Full text]** from Table of Contents page.

This is simple HTML version for faster download on mobiles (if viewed on desktop, it will be automatically redirected to full HTML version)

### E-Pub for hand-held devices

EPUB is an open e-book standard recommended by The International Digital Publishing Forum which is designed for reflowable content i.e. the text display can be optimized for a particular display device.

Click on **[EPub]** from Table of Contents page.

There are various e-Pub readers such as for Windows: Digital Editions, OS X: Calibre/Bookworm, iPhone/iPod Touch/iPad: Stanza, and Linux: Calibre/Bookworm.

### E-Book for desktop

One can also see the entire issue as printed here in a 'flip book' version on desktops.

Links are available from Current Issue as well as Archives pages.

Click on  View as eBook