



CASE REPORT

Case Report: Coronary artery stent infection with mycotic aneurysm secondary to tricuspid valve infective endocarditis [version 1; peer review: 2 approved]

Mejdi Ben Messaoud ¹, Nidhal Bouchahda¹, Marouane Mahjoub¹, Badii Hmida², Zohra Dridi¹, Habib Gamra¹

¹Cardiology A Department, Fattouma Bourguiba University Hospital, Monastir, Monastir, Monastir, 5000, Tunisia

²Radiology Department, Fattouma Bourguiba University Hospital, Monastir, Monastir, Monastir, 5000, Tunisia

v1 **First published:** 12 Jun 2019, 8:853 (<https://doi.org/10.12688/f1000research.19067.1>)
Latest published: 12 Jun 2019, 8:853 (<https://doi.org/10.12688/f1000research.19067.1>)

Abstract

Coronary artery stent infection with mycotic aneurysm is a rare life-threatening complication following coronary angioplasty, usually requiring surgical intervention. Reaching and confirming the diagnosis remains the most challenging aspect of this complication. We describe an unusual case of bare metal stent infection and coronary artery aneurysm in the setting of tricuspid valve infective endocarditis, resulting in ST elevation myocardial infarction, with a favorable outcome after primary angioplasty and antibiotic therapy. In the current era of growth of coronary stent implantation, it's important for clinicians to consider and to prevent such potentially fatal events. The diagnosis process remains difficult and requires the association of multiple clinical, biological and imaging parameters. Although treatment modalities tend to favor surgery, we showed that coronary angioplasty could be a successful alternative solution.

Keywords

endocarditis, stents, infection, coronary aneurysm, acute coronary syndrome

Open Peer Review

Reviewer Status

	Invited Reviewers	
	1	2
version 1 published 12 Jun 2019	 report	 report

- Nicolas Amabile**, Institut Mutualiste Montsouris, Paris, France
- Marouane Boukhris**, Centre Hospitalier de l'Université de Montréal, Montréal, Canada

Any reports and responses or comments on the article can be found at the end of the article.

Corresponding author: Mejdi Ben Messaoud (mejdibenmessaoud@yahoo.fr)

Author roles: **Ben Messaoud M:** Writing – Original Draft Preparation; **Bouchahda N:** Formal Analysis; **Mahjoub M:** Project Administration; **Hmida B:** Conceptualization; **Dridi Z:** Writing – Original Draft Preparation; **Gamra H:** Writing – Review & Editing

Competing interests: No competing interests were disclosed.

Grant information: The author(s) declared that no grants were involved in supporting this work.

Copyright: © 2019 Ben Messaoud M *et al.* This is an open access article distributed under the terms of the [Creative Commons Attribution License](https://creativecommons.org/licenses/by/4.0/), which permits unrestricted use, distribution, and reproduction in any medium, provided the original work is properly cited.

How to cite this article: Ben Messaoud M, Bouchahda N, Mahjoub M *et al.* **Case Report: Coronary artery stent infection with mycotic aneurysm secondary to tricuspid valve infective endocarditis [version 1; peer review: 2 approved]** F1000Research 2019, 8:853 (<https://doi.org/10.12688/f1000research.19067.1>)

First published: 12 Jun 2019, 8:853 (<https://doi.org/10.12688/f1000research.19067.1>)

Introduction

Infectious complications following percutaneous cardiac interventions are known but not very common. Coronary stent implantation is associated with complications, though rare, such as stent infection or coronary aneurysms resulting from several mechanisms, and needing special investigations for their diagnosis and management^{1,2}. Simultaneous occurrence of coronary stent infection and mycotic aneurysm has been described in a few cases as an unusual life-threatening complication following coronary angioplasty³. The majority of the few reported cases had an unfavorable outcome⁴, with the majority treated surgically.

We report a rare case of ST elevation myocardial infarction due to bare metal stent infection and coronary artery aneurysm in the setting of tricuspid valve infective endocarditis. The management and outcome of our patient was quite different from what was reported in the literature.

It is important for the interventional cardiologist, to remember that such complication might occur and should be prevented. If it does occur however, its treatment and outcome represent a challenge for clinicians.

Case

A 71-year-old North African retired male patient with a history of smoking (40 pack-years) and no known medical or surgical history, was referred to our center in October 2017, from the emergency department, for inferior ST elevation myocardial infarction with complete atrioventricular block. He underwent a successful primary angioplasty of the right coronary artery (RCA) with a bare metal stent (Figure 1). A temporary cardiac pacing via the right femoral vein was performed for 24 hours and the patient was discharged at day 5. Initial and controlled laboratory tests during hospitalization were normal except

elevated troponin at admission. One week later, the patient was referred again to our center from the emergency department for persistent chest pain with a new right bundle branch block. An urgent coronary angiogram showed a thrombus with an aneurysm on the distal part of the RCA stent and a Thrombolysis In Myocardial Infarction (TIMI) 3 flow (normal flow) (Figure 2A and 2B). An additional angioplasty using a second bare metal stent overlapping with the previous one was successfully performed with exclusion of the aneurysm and disappearance of the thrombus. (Figure 2B and 2C). The initial physical exam in the coronary care unit immediately after angioplasty found a mild fever at 38°C with a systolic tricuspid regurgitation murmur. Echocardiography showed vegetation (17 × 14 mm) at the level of the tricuspid valve with a moderate tricuspid regurgitation and a moderate pericardial effusion (Figure 3A and 3B). Transesophageal echocardiography confirmed the same findings and ruled out a patent foramen ovale or any involvement of the other valves. Laboratory tests (which were normal at the previous admission) showed a marked elevation of white blood cells count (24,000 E/mm³, normal value < 11,800 E/mm³), C reactive protein (186 mg/L, normal value < 6 mg/L), and liver enzymes (Alanine transaminase (ALT) at 215 IU/L and Aspartate aminotransferase (AST) at 165 IU/L, normal value respectively < 35 IU/L and < 40 IU/L) associated with acute renal failure (serum creatinine at 148 mmol/L, normal value < 105 mmol/L) and hemolytic anemia (Hemoglobin 8 g/DL, normal value > 13 g/DL). Blood cultures were positive to negative coagulase *Staphylococcus*. The diagnosis of infective endocarditis of the tricuspid valve with RCA mycoticaneurysm at the site of stent implantation was strongly suspected. Cardiac CT scan confirmed the vegetation in the right ventricle with hematoma around the RCA and pericardial effusion (Figure 3C). It also showed a mycotic aneurysm of the RCA which was excluded by the overlapping stent (Figure 3D). Following a thorough search for the underlying cause, we concluded that the temporary cardiac

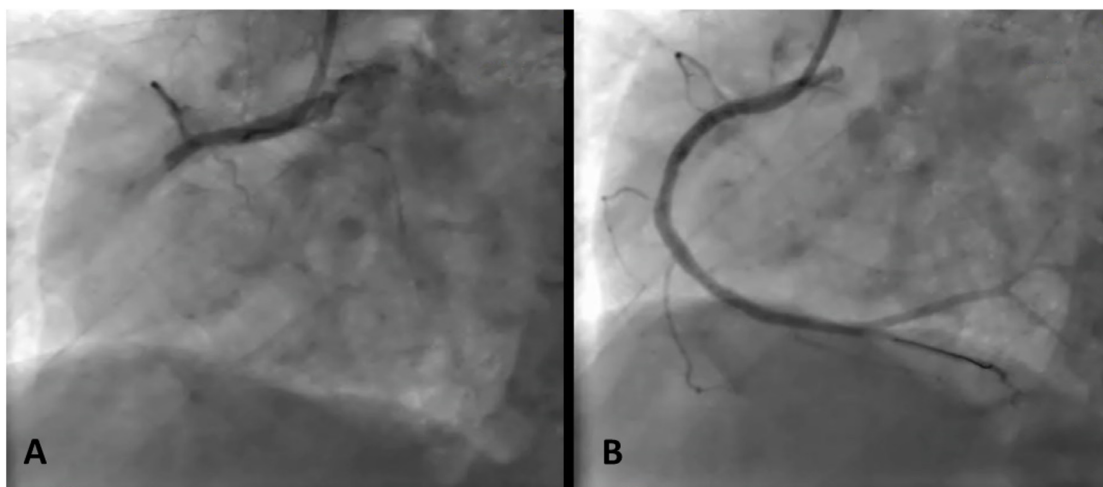


Figure 1. Coronary angiogram images before (A) and after (B) the first primary angioplasty of the right coronary artery.

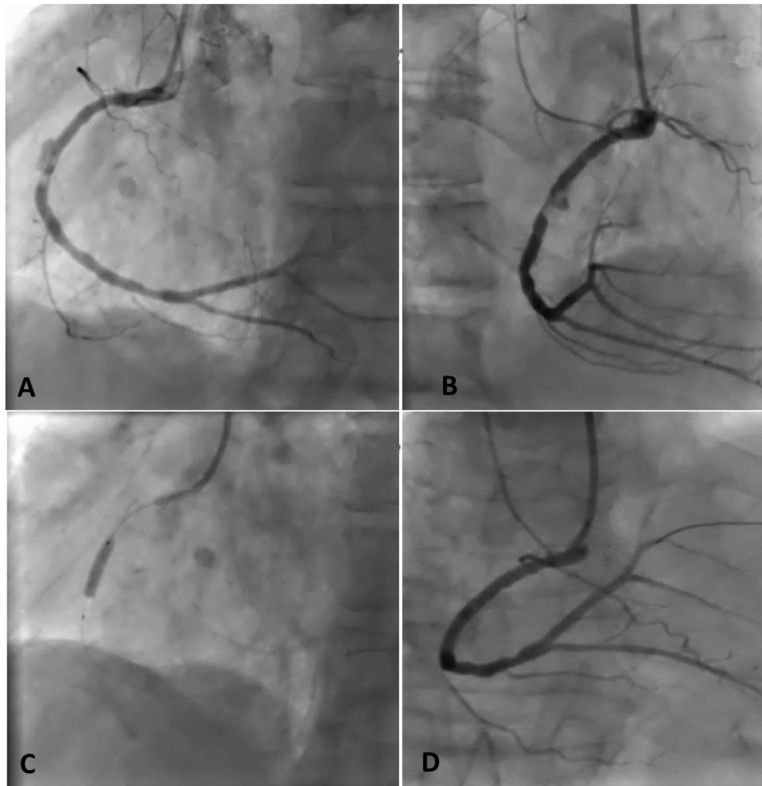


Figure 2. Coronary angiogram images of the second primary angioplasty: **A** and **B** show the intrastent thrombus with mycotic aneurysm of the right coronary artery. **C** and **D** show the right coronary artery angioplasty with an overlapping bare metal stent.

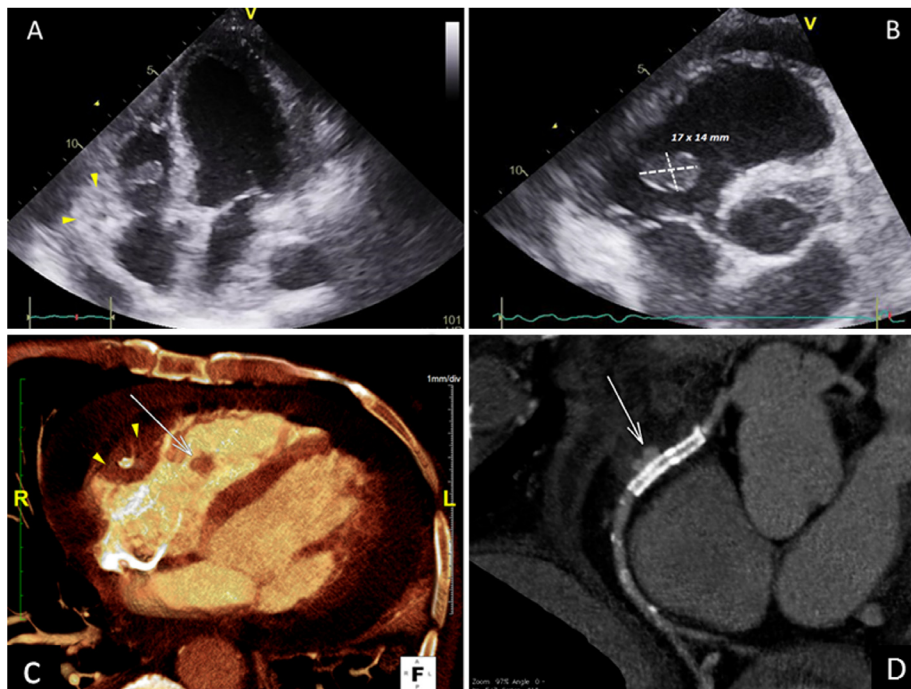


Figure 3. Imaging showing tricuspid valve vegetation (arrow) with hematoma around the right coronary artery (arrowhead) and pericardial effusion in transthoracic echocardiography (**A** and **B**) and cardiac computed tomography scan (**C**). **D**: computed tomography coronary angiography showing the right coronary artery aneurysm excluded by the overlapping stent.

pacing was the most likely origin of the tricuspid valve infective endocarditis. Antibiotic therapy (vancomycin 30 mg/Kg/day i.v. in 2 doses, rifampicin 900 mg orally in 3 divided doses and gentamycin 3 mg/Kg i.v. once daily) was provided resulting in total regression of the infection symptoms, the tricuspid vegetation and the pericardial effusion. The patient was discharged from the hospital after six weeks of antibiotic therapy. The patient has completed one-year of follow-up with repeated echocardiography and blood tests, all of which were ordinary.

Discussion

Stent infection can occur early (less than 10 days) or late (10 days or longer) following coronary angioplasty⁴ and is frequently diagnosed in the context of an acute coronary syndrome due to stent thrombosis or coronary artery aneurysm. The diagnosis of coronary stent infection is confirmed based on the criteria proposed by Dieter¹. The diagnosis is definitive when confirmed by autopsy or surgical material examination if at least three of the following criteria are present: coronary stent implantation during the last 4 weeks; repeated interventions through the same arterial sheath; fever > 38°C, documented bacteremia, leukocytosis without evident etiology; acute coronary syndrome; or positive cardiac imaging. Mycotic coronary aneurysms may result from different mechanisms including direct bacterial invasion in the setting of infective endocarditis, injury caused by immune complexes, arterial trauma and vasa vasorum embolic occlusion. Other mechanisms such as immunocompromised status and congenital cardiovascular defects might be involved². Following testing for all these mechanisms in our patient we strongly suspected the infective endocarditis as the main etiology of the right coronary stent mycotic aneurysm. The majority of the similar reported cases were associated with a fatal outcome⁴. In few cases, like in ours, pericoronary hematoma with pericardial effusion can be present and it may be due to the coronary aneurysm leak or rupture⁵. Irrespective of time of presentation, the majority of stent infection with coronary aneurysm must be treated by surgical

extraction of the stent with aneurysm repair when indicated and with simultaneous intravenous antibiotic therapy for at least 4 weeks⁶. In our case, the follow up at 1 year didn't show any signs of relapse. Consequently, the patient was not referred to surgery.

One limitation of this report relates to the mycotic nature of the stent aneurysm which can only be confirmed by tissue analysis. This was not possible since the patient did not have surgery nor a postmortem autopsy. However, the diagnosis was highly probable based on the clinical, biological and imaging parameters.

In conclusion, coronary stent infection in the setting of infective endocarditis is rare but must be considered whenever a patient develops fever and chest pain after stent implantation. Treatment modalities tend to favor surgery, but in our case, we showed that coronary angioplasty and prolonged antibiotic therapy may be sufficient. To prevent such complications, adherence to aseptic precautions and treatment of pre-existing infections are of paramount importance.

Consent

Written informed consent for publication of their clinical details and/or clinical images was obtained from the patient/parent/guardian/relative of the patient.

Data availability

Underlying data

All data underlying the results are available as part of the article and no additional source data are required.

Grant information

The author(s) declared that no grants were involved in supporting this work.

References

- Dieter RS: **Coronary artery stent infection**. *Clin Cardiol*. 2000; **23**(11): 808–810.
[PubMed Abstract](#) | [Publisher Full Text](#)
- Weinstein L, Schlesinger JJ: **Pathoanatomic, pathophysiologic and clinical correlations in endocarditis (second of two parts)**. *N Engl J Med*. 1974; **291**(21): 1122–1126.
[PubMed Abstract](#) | [Publisher Full Text](#)
- Matsumoto M, Konishi Y, Miwa S, *et al.*: **Mycotic aneurysm of the left coronary artery**. *Ann Thorac Surg*. 1998; **65**(3): 841–2.
[PubMed Abstract](#) | [Publisher Full Text](#)
- Elieson M, Mixon T, Carpenter J: **Coronary stent infections: a case report and literature review**. *Tex Heart Inst J*. 2012; **39**(6): 884–9.
[PubMed Abstract](#) | [Free Full Text](#)
- Roubelakis A, Rawlins J, Baliulis G, *et al.*: **Coronary artery rupture caused by stent infection: a rare complication**. *Circulation*. 2015; **131**(14): 1302–1303.
[PubMed Abstract](#) | [Publisher Full Text](#)
- Singh H, Singh C, Aggarwal N, *et al.*: **Mycotic aneurysm of left anterior descending artery after sirolimus-eluting stent implantation: a case report**. *Cathet Cardiovasc Interv*. 2005; **65**(2): 282–285.
[PubMed Abstract](#) | [Publisher Full Text](#)

Open Peer Review

Current Peer Review Status:  

Version 1

Reviewer Report 15 October 2019

<https://doi.org/10.5256/f1000research.20896.r49820>

© 2019 Boukhris M. This is an open access peer review report distributed under the terms of the [Creative Commons Attribution License](#), which permits unrestricted use, distribution, and reproduction in any medium, provided the original work is properly cited.



Marouane Boukhris

Cardiology Department, Centre Hospitalier de l'Université de Montréal, Montréal, Canada

In the current manuscript, the authors reported a rare infective complication following percutaneous coronary intervention. They underlined the difficulty of the diagnosis, particularly when neither surgery nor autopsy is performed.

Generally, the manuscript is well written and the topic is quite interesting for the reader. The paper seems suitable for indexing in its actual version.

Is the background of the case's history and progression described in sufficient detail?

Yes

Are enough details provided of any physical examination and diagnostic tests, treatment given and outcomes?

Yes

Is sufficient discussion included of the importance of the findings and their relevance to future understanding of disease processes, diagnosis or treatment?

Yes

Is the case presented with sufficient detail to be useful for other practitioners?

Yes

Competing Interests: No competing interests were disclosed.

Reviewer Expertise: Interventional cardiology

I confirm that I have read this submission and believe that I have an appropriate level of expertise to confirm that it is of an acceptable scientific standard.

Reviewer Report 10 July 2019

<https://doi.org/10.5256/f1000research.20896.r49816>

© 2019 Amabile N. This is an open access peer review report distributed under the terms of the [Creative Commons Attribution License](#), which permits unrestricted use, distribution, and reproduction in any medium, provided the original work is properly cited.



Nicolas Amabile

Institut Mutualiste Montsouris, Paris, France

In this paper, Ben Messaoud and colleagues reported a very unusual case of a patient who developed a subacute stent thrombosis in the setting of a tricuspid acute endocarditis. The ST was associated with an image of aneurysm on the distal edge of the stent. Although there are other causes of coronary artery aneurysm (including iatrogenic media disruption, stent fracture or severe stent malapposition) that could appear after initial thrombus dissolution, the authors concluded to a mycotic aneurysm. This conclusion makes sense regarding the clinical context, CT scan data and subsequent evolution following antibiotics therapy. The main limitation of the report is the lack of pathology analyses and was acknowledged by the authors.

The manuscript in this current version raises the following issues:

1. What was the antiplatelet drug regimen of the patient after the first STEMI ? What about the patient compliance?
2. The CT scan initial data could be better explained and a cross sectional image of the RCA showing the hematoma might be a nice addition.
3. Do the authors have a 1 year CT scan or angio to illustrate the aneurysm disappearance (or no)?
4. What is the authors opinion about implanting a new device in an actively infected stent?

Is the background of the case's history and progression described in sufficient detail?

Yes

Are enough details provided of any physical examination and diagnostic tests, treatment given and outcomes?

Yes

Is sufficient discussion included of the importance of the findings and their relevance to future understanding of disease processes, diagnosis or treatment?

Yes

Is the case presented with sufficient detail to be useful for other practitioners?

Yes

Competing Interests: No competing interests were disclosed.

Reviewer Expertise: interventional cardiology

I confirm that I have read this submission and believe that I have an appropriate level of expertise to confirm that it is of an acceptable scientific standard.

Author Response 10 Jul 2019

Mejdi Ben Messaoud, Fattouma Bourguiba University Hospital, Monastir, Monastir, Tunisia

I would like to thank Dr Amabile for his precious comments.

The answers for his questions are as follows:

1. The antiplatelet therapy included aspirin 100 mg once a day and Clopidogrel 75 mg once a day. There was no history of DAPT discontinuation.
2. I agree that a cross sectional image of the RCA showing the hematoma might be a nice addition.
3. No CT scan was performed after 1-year follow up. The follow up was based on clinical exam, biological tests and echocardiography.
4. We think that implanting a new device in an actively infected stent is not recommended, but in our case, we have performed an ad-hoc angioplasty because the diagnosis of stent infection was not confirmed.

Competing Interests: No competing interests were disclosed.

The benefits of publishing with F1000Research:

- Your article is published within days, with no editorial bias
- You can publish traditional articles, null/negative results, case reports, data notes and more
- The peer review process is transparent and collaborative
- Your article is indexed in PubMed after passing peer review
- Dedicated customer support at every stage

For pre-submission enquiries, contact research@f1000.com

F1000Research