

Received: 2021.10.15

Accepted: 2022.04.11

Available online: 2022.05.23

Published: 2022.07.03

Pharmacological and Behavioral Strategies to Improve Vision in Acquired Pendular Nystagmus

Authors' Contribution:
Study Design A
Data Collection B
Statistical Analysis C
Data Interpretation D
Manuscript Preparation E
Literature Search F
Funds Collection G

BCDEF 1 **Hassen Kerkeni**
ABCDE 2 **Dominik Brügger**
BDE 3 **Georgios Mantokoudis**
CDE 2 **Mathias Abegg**
ABCDE 4,5 **David S. Zee**

1 Department of Neurology, Inselspital, Bern University Hospital, University of Bern, Bern, Switzerland
2 Department of Ophthalmology, Inselspital, Bern University Hospital, University of Bern, Bern, Switzerland
3 Department of Otorhinolaryngology, Head and Neck Surgery, Inselspital, Bern University Hospital, University of Bern, Bern, Switzerland
4 Department of Neurology, Ophthalmology, Otolaryngology-Head and Neck Surgery, Johns Hopkins Hospital, Baltimore, MD, USA
5 Department of Neuroscience, Division of Neuro-Visual and Vestibular Disorders, Johns Hopkins Hospital, Baltimore, MD, USA

Corresponding Author: Hassen Kerkeni, e-mail: hassen.kerkeni@insel.ch
Financial support: GM was supported by the Swiss National Science Foundation (Grant #320030_173081)
Conflict of interest: None declared

Patient: Female, 49-year-old
Final Diagnosis: Acquired pendular nystagmus • multiple sclerosis
Symptoms: Oscillopsia
Medication: —
Clinical Procedure: Blink • visual acuity
Specialty: Neurology • Ophthalmology

Objective: Unusual setting of medical care

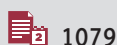Background: Acquired pendular nystagmus (APN) is a back and forth, oscillatory eye movement in which the 2 oppositely directed slow phases have similar waveforms. APN occurs commonly in multiple sclerosis and causes a disabling oscillopsia that impairs vision. Previous studies have proven that symptomatic therapy with gabapentin or memantine can reduce the nystagmus amplitude or frequency. However, the effect of these medications on visual acuity (VA) is less known and to our knowledge the impact of non-pharmacological strategies such as blinking on VA has not been reported. This is a single observational study without controls (Class IV) and is meant to suggest a future strategy for study of vision in patients with disabling nystagmus and impaired vision.

Case Report: A 49-year-old woman with primary progressive multiple sclerosis with spastic paraparesis and a history of optic atrophy presented with asymmetrical binocular APN and bothersome oscillopsia. We found that in the eye with greater APN her visual acuity improved by 1 line (from 0.063 to 0.08 decimals) immediately after blinking. During treatment with memantine, her VA without blinking increased by 2 lines, from 0.063 to 0.12, but improved even more (from 0.12 to 0.16) after blinking. In the contralateral eye with a barely visible nystagmus, VA was reduced by 1 line briefly (~500 ms) after blinking.

Conclusions: In a patient with APN, blinking transiently improved vision. The combination of pharmacological treatment with memantine and the blinking strategy may induce better VA and less oscillopsia than either alone.

Keywords: Attentional Blink • Multiple Sclerosis, Chronic Progressive • Nystagmus, Pathologic • Optic Atrophy

Full-text PDF: <https://www.amjcaserep.com/abstract/index/idArt/935148>



1079



—



2



1



21



Background

Pendular nystagmus is a back and forth, involuntary oscillatory eye movement in which the 2 oppositely directed slow phases have similar waveforms. Pendular nystagmus may be congenital or acquired. Acquired pendular nystagmus (APN) occurs in disorders affecting the visual system, or with lesions involving the dentato-rubro-olivary tract (Guillain-Mollaret triangle) and consequent inferior olivary hypertrophy [1-3]. APN occurs commonly in multiple sclerosis and causes a disabling oscillopsia that impairs vision [4,5].

APN usually consists of pseudo-sinusoidal oscillations at a single frequency (in the range of 1 to 8 Hz) and may be asymmetric and sometimes monocular [2,6,7].

APN often briefly stops for a few hundred ms after saccades and blinks [8-12]. Based on objective ocular motor measures, including nystagmus amplitude and/or frequency, previous studies [13-18] showed that gabapentin or memantine is an effective treatment for APN. Thurtell et al and Nerrant et al [17,18] also showed treatment with memantine or gabapentin improved visual acuity (VA).

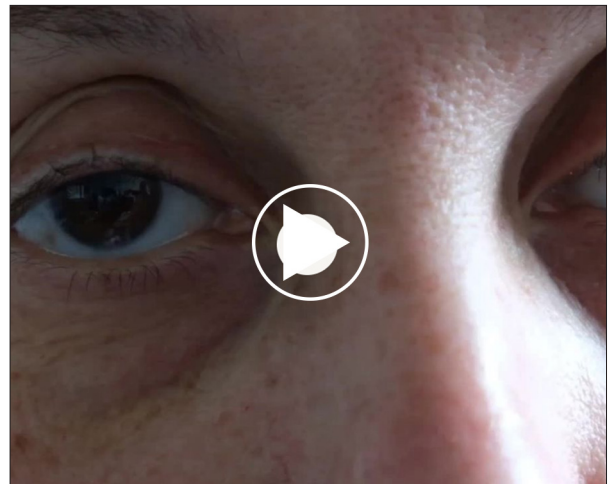
To our knowledge, however, the impact of blinking on visual acuity has not been investigated. Here, we describe a 49-year-old woman with primary progressive multiple sclerosis with spastic paraparesis and a history of optic atrophy who presented with asymmetrical binocular APN and bothersome oscillopsia. We found her visual acuity improved by 1 line (from 0.063 to 0.08) immediately after blinking in the eye with greater APN. In the contralateral eye, with a barely visible nystagmus, visual acuity was reduced by 1 line briefly after blinking.

This is a single observational study without controls (Class IV) and is meant to suggest a future strategy for study of vision in patients with disabling nystagmus and impaired vision.

Case Report

A 49-year-old woman with primary progressive multiple sclerosis with spastic paraparesis and a history of optic atrophy in both eyes presented with binocular horizontal acquired pendular nystagmus (APN) and bothersome oscillopsia. She was myopic (-1.5 and -1.0 diopters, right and left eye, respectively). Best corrected visual acuity (measured on a Snellen chart at 5 meters) was 0.5 in the right eye and 1.0 in the left eye. She had temporal pallor of both optic discs, and a reduced thickness of the temporal peripapillary nerve fiber layer more pronounced in the right eye.

The pendular nystagmus was most visible in the right eye, with a peak-to-peak amplitude of 2° to 5° horizontally and 2°



Video 1. Binocular asymmetrical horizontal acquired pendular nystagmus most visible in the right eye. Notice the decrease of the nystagmus intensity after a blink of the right eye.

to 6° vertically, and a frequency of ~5.5Hz. Nystagmus in the left eye was barely noticeable, with amplitudes <1° (Video 1).

We recorded the movements of both eyes with an Eye Link SR1000 eye tracker (SR Research, CA). An infrared bandpass filter was used to cover the opposite eye for monocular viewing conditions, while still enabling binocular recording. We measured the visual acuity without correction in 2 conditions: (1) Independent of blinking – these trials were initiated by a button press at the discretion of the patient; and (2) immediately after a blink event – these trials were triggered automatically by the end of a blink. In both conditions, a Landolt ring on a screen positioned at 3 m distance was shown for 500 ms immediately after the trigger. The patient was asked to report the orientation of the opening in the Landolt ring without correction. Visual acuity was defined as the smallest Landolt ring at which at least 5 of 8 trials were correctly recognized.

The patient was evaluated twice – before taking memantine, and then 3 months later while taking 20 mg of memantine per day. In both sessions, on video-oculography each blink was followed by a short period of about 400 ms with a diminished oscillation and a reset of the oscillatory phase (Figure 1 row c, second column during the stimulus period and also in the video which shows the decreased intensity of the nystagmus after a blink). Likewise, visual acuity improved in both sessions with blinking, and the patient noticed less oscillopsia and better vision for a brief period after blinking. Before treatment with memantine, the blinking strategy increased vision from 0.063 (without blinks) to 0.08 (measured with blinks). During treatment with memantine, visual acuity without blinking increased by 2 lines, from 0.063 to 0.12. With blinking, vision further increased from 0.12 to 0.16. Based on our video-oculography

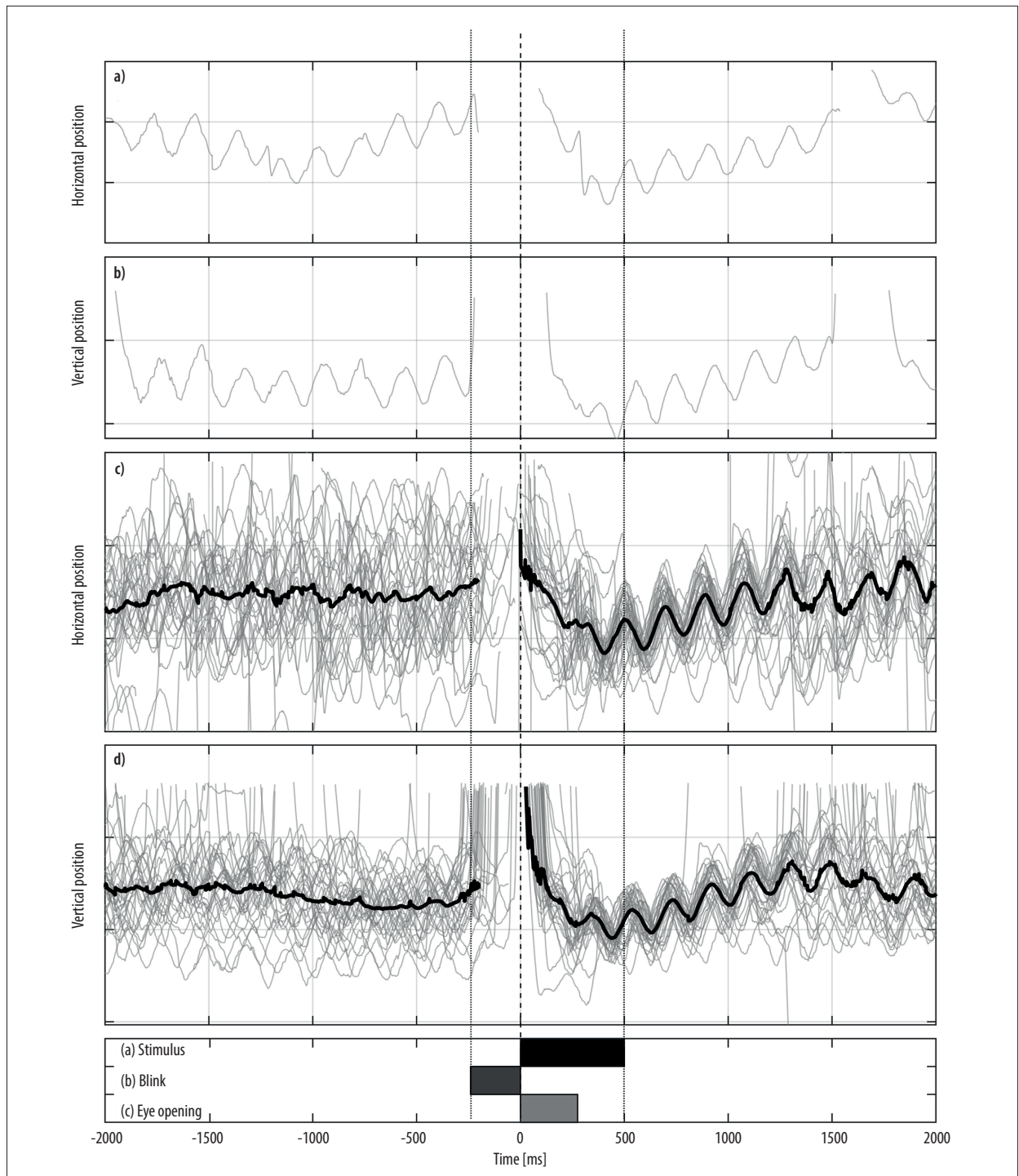


Figure 1. Video-oculography findings of the right eye during the first session (before beginning with memantine); the x-axis represents time in milliseconds and the y-axis represents the eye position; **a)** Horizontal component of the pendular nystagmus in the right eye in one trial while examining the visual acuity before and after stimulus; **b)** Vertical component of the same trial; **c)** Horizontal component of the pendular nystagmus in the right eye in all 32 trials (superimposed grey lines) with a black line indicating the mean horizontal component of the APN; **d)** Corresponding vertical eye movements. Vertical dashed line represents the end of the blink preceded by the lightly shaded bar reflecting the period of the blink. The period during which the visual acuity stimulus was presented is indicated by the black bar. Note the suppression of the nystagmus and the consistent resetting of the phase of the oscillations with blinks (c, second column).

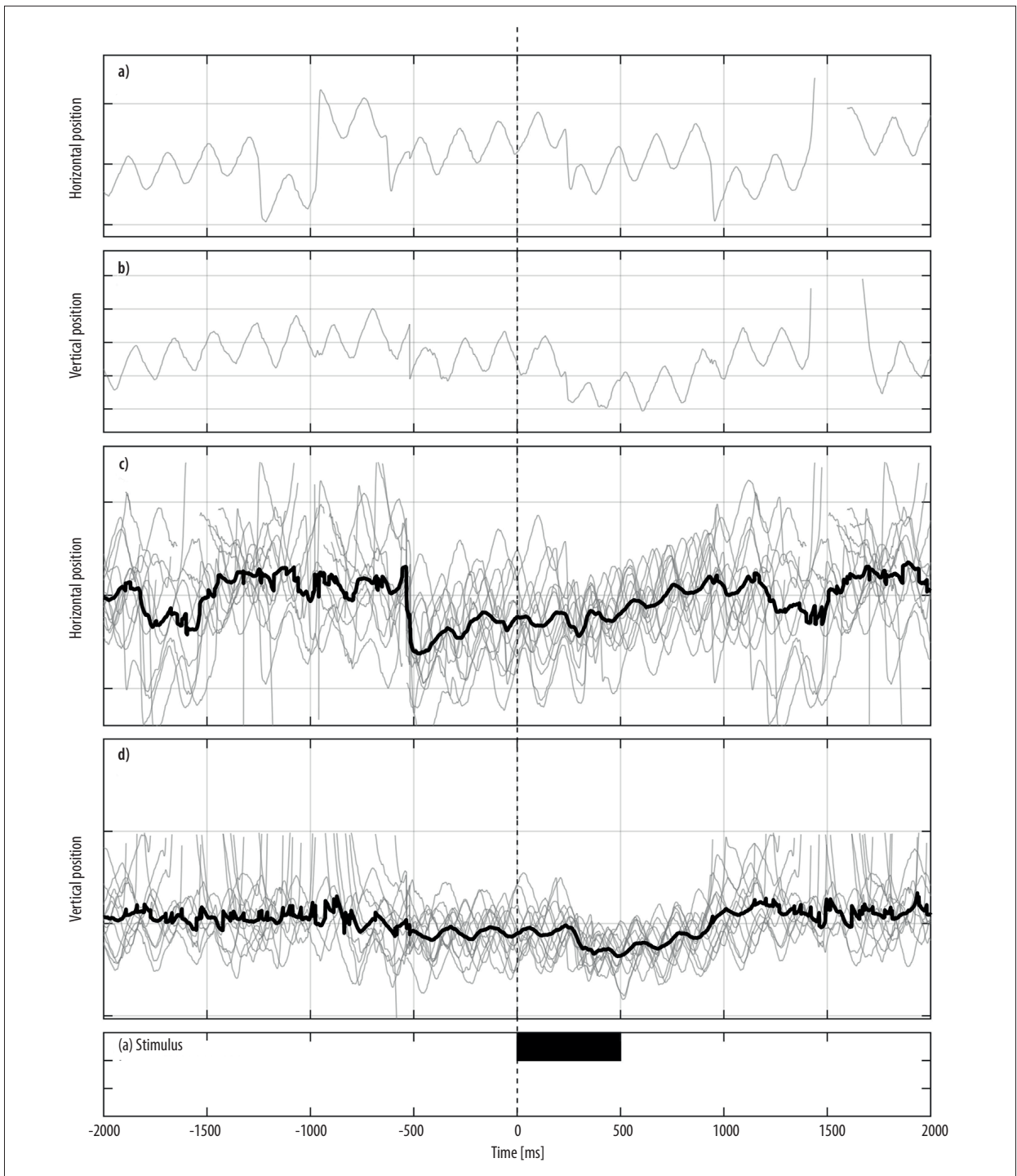


Figure 2. Video-oculography findings of the right eye during the first session (before beginning with memantine); the x-axis represents time in milliseconds and the y-axis represents the eye position; **a)** Horizontal component of the pendular nystagmus in the right eye in one trial while examining the visual acuity before and after blinking; **b)** Vertical component of the same trial; **c)** Horizontal component of the pendular nystagmus in the right eye in all 32 trials (superimposed grey lines) with a black line indicating the mean horizontal component of the APN; **d)** Corresponding vertical eye movements. Vertical dashed line represents the begin of the stimulus. The period during which the visual acuity stimulus was presented is indicated by the black bar.

data, visual fixation alone (without blink) did not influence the oscillations of the right eye (Figure 2).

In the left eye with minimal APN, there was a slight decrease in visual acuity with blinking (before memantine treatment vision decreased from 0.25 to 0.125; during memantine treatment vision decreased from 0.3 to 0.25 with the blinking strategy). Using the same blink paradigm in 5 healthy participants, there was a similar decrease (mean of 1 line of visual acuity) immediately after blinking.

Discussion

The main finding in this patient with acquired pendular nystagmus from multiple sclerosis was that blinking could transiently improve vision. A similar transient suppression of nystagmus has been reported after a saccade, both in patients with APN [19] and patients with infantile, “congenital” nystagmus [20,21]. In the latter, there is a brief “foveation” period in which the slow-phase velocity of the nystagmus drops to zero for up to a few hundred ms.

In our patient the combination of pharmacological treatment with memantine and the blinking strategy induced better visual acuity and less oscillopsia than either alone. Whether this can be helpful to other patients is not yet known, but our results suggest: (1) a quantitative approach to monitoring the

functional effects of therapy of nystagmus on vision and (2) vision (and quality of life) can be improved for patients using the blink strategy. The latter effect seems to be due only to blinking and is not influenced by visual fixation alone.

Conclusions

A blink can lead to a transient but beneficial increase in visual acuity in patients with acquired pendular nystagmus. Our findings might have implications for patient counseling; however, it is still not clear whether patients with APN already use the blink strategy consciously (or unconsciously) to transiently improve their vision. Even if the salutary effect lasts for only a few hundred milliseconds after a blink, visual tasks that require fine-grained acuity, for example, threading a needle, might be easier to accomplish using a blinking strategy.

Department and Institution Where Work Was Done

The study was conducted in the Department of Ophthalmology, Inselspital, Bern University Hospital, Bern, Switzerland.

Declaration of Figures' Authenticity

All figures submitted have been created by the authors who confirm that the images are original with no duplication and have not been previously published in whole or in part.

References:

1. Dufour A, Guccione G, Tamburrino V. [Electronystagmographic considerations on 2 cases of monocular nystagmus]. *Rev Otoneuroophthalmol.* 1972;44(1):125-34 [in French]
2. Farmer J, Hoyt CS. Monocular nystagmus in infancy and early childhood. *Am J Ophthalmol.* 1984;98(4):504-9
3. Kim JS, Moon SY, Choi KD, et al. Patterns of ocular oscillation in oculopalatal tremor: imaging correlations. *Neurology.* 2007;68(14):1128-35
4. Aschoff JC, Conrad B, Kornhuber HH. Acquired pendular nystagmus with oscillopsia in multiple sclerosis: A sign of cerebellar nuclei disease. *J Neurol Neurosurg Psychiatry.* 1974;37(5):570-77
5. Barton JJ, Cox TA. Acquired pendular nystagmus in multiple sclerosis: Clinical observations and the role of optic neuropathy. *J Neurol Neurosurg Psychiatry.* 1993;56(3):262-67
6. Leigh RJ, Thurston SE, Tomsak RL, et al. Effect of monocular visual loss upon stability of gaze. *Invest Ophthalmol Vis Sci.* 1989;30(2):288-92
7. Lopez LI, Bronstein AM, Gresty MA, et al. Clinical and MRI correlates in 27 patients with acquired pendular nystagmus. *Brain.* 1996;119(Pt 2):465-72
8. Jasse L, Vighetto A, Vukusic S, et al. Unusual monocular pendular nystagmus in multiple sclerosis. *J Neuroophthalmol.* 2011;31(1):38-41
9. Singhvi JP, Singh AS. Unilateral vertical pendular nystagmus in multiple sclerosis: A distinctive neuro-ophthalmological sign. *Ann Indian Acad Neurol.* 2019;22(1):116-17
10. Averbuch-Heller L, Zivotofsky AZ, Das VE, et al. Investigations of the pathogenesis of acquired pendular nystagmus. *Brain.* 1995;118(Pt 2):369-78
11. Gresty MA, Ell JJ, Findley LJ. Acquired pendular nystagmus: Its characteristics, localising value and pathophysiology. *J Neurol Neurosurg Psychiatry.* 1982;45(5):431-39
12. Leigh RJ, Zee DS. *The neurology of eye movements:* Oxford University Press; 2015
13. Averbuch-Heller L, Tusa RJ, Fuhry L, et al. A double-blind controlled study of gabapentin and baclofen as treatment for acquired nystagmus. *Ann Neurol.* 1997;41(6):818-25
14. Bandini F, Castello E, Mazzella L, et al. Gabapentin but not vigabatrin is effective in the treatment of acquired nystagmus in multiple sclerosis: How valid is the GABAergic hypothesis? *J Neurol Neurosurg Psychiatry.* 2001;71(1):107-10
15. Starck M, Albrecht H, Pöllmann W, et al. Acquired pendular nystagmus in multiple sclerosis: An examiner-blind cross-over treatment study of memantine and gabapentin. *J Neurol.* 2010;257(3):322-27
16. Starck M, Albrecht H, Pöllmann W, et al. Drug therapy for acquired pendular nystagmus in multiple sclerosis. *J Neurol.* 1997;244(1):9-16
17. Thurtell MJ, Joshi AC, Leone AC, et al. Crossover trial of gabapentin and memantine as treatment for acquired nystagmus. *Ann Neurol.* 2010;67(5):676-80
18. Nerrant E, Abouaf L, Pollet-Villard F, et al. Gabapentin and memantine for treatment of acquired pendular nystagmus: Effects on visual outcomes. *J Neuroophthalmol.* 2020;40(2):198-206
19. Jung I, Kim SH, Kim HJ, et al. Modulation of acquired monocular pendular nystagmus in multiple sclerosis: A modeling approach. *Prog Brain Res.* 2019;249:227-34
20. Dell'Osso LF, Leigh RJ, Sheth NV, Daroff RB. Two types of foveation strategy in 'latent' nystagmus: Fixation, visual acuity and stability. *Neuroophthalmology.* 1995;15(4):167-86
21. Jacobs JB, Dell'Osso LF. Congenital nystagmus: hypotheses for its genesis and complex waveforms within a behavioral ocular motor system model. *J Vis.* 2004;4(7):604-25