



Contents lists available at ScienceDirect

## International Journal of Surgery Case Reports

journal homepage: [www.casereports.com](http://www.casereports.com)

## Ovarian serous cystadenoma with ectopic adrenal tissue in a 65-year-old patient: A case report



Çağdaş Şahin<sup>a</sup>, Enes Taylan<sup>a,\*</sup>, Ali Akdemir<sup>a</sup>, Osman Zekioglu<sup>b</sup>, Parvane Seyidova<sup>a</sup>, Ahmet Mete Ergenoglu<sup>a</sup>

<sup>a</sup> Department of Obstetrics and Gynecology, Ege University School of Medicine, Izmir, Turkey

<sup>b</sup> Department of Pathology, Ege University School of Medicine, Izmir, Turkey

### ARTICLE INFO

#### Article history:

Received 18 November 2016

Received in revised form 23 February 2017

Accepted 23 February 2017

Available online 27 February 2017

#### Keywords:

Adrenal tissue

Ectopia

Ovarian cystadenoma

Case report

### ABSTRACT

**INTRODUCTION:** Ectopic adrenal tissue is a very rare entity in adult females, especially in the ovary, and is generally diagnosed incidentally during surgery. Although it can present at various sites during childhood, it becomes atrophic by adulthood due to normally functioning adrenal glands. Patients are predominantly asymptomatic; however, in some cases endocrine symptoms such as hypertension and fasciotruncal obesity due to hormonal activity can be seen or neoplastic transformation can appear.

**PRESENTATION OF CASE:** A 65-year-old patient with progressive pelvic pain and postmenopausal vaginal bleeding was evaluated by transvaginal ultrasound, which revealed bilateral adnexal masses measuring 5 cm in size and a normal uterus with an increased endometrial thickness of 7 mm. Initially the endometrial sampling result was reported as benign. The patient underwent abdominal hysterectomy and bilateral salpingo-oophorectomy and the pathological diagnosis was again benign, with serous ovarian cystadenoma being found in both ovaries. The pathologist also reported incidental ectopic adrenal tissue on the wall of the left ovarian cystadenoma.

**DISCUSSION:** Ectopic adrenal tissue is infrequent in female genital organs especially at older ages. Only a few cases of ovarian ectopic adrenal tissue have been reported. To the best of our knowledge the present case is the fourth report in the English literature, and is of additional importance given the patient's age.

**CONCLUSION:** Ectopic adrenal tissues are generally asymptomatic and revealed incidentally during surgery; however some cases have demonstrated the risk of neoplastic transformation. Therefore, surgeons must be aware of this rare entity that bears the risk of malignancy, and should surgically remove all suspicious lesions.

© 2017 The Author(s). Published by Elsevier Ltd on behalf of IJS Publishing Group Ltd. This is an open access article under the CC BY-NC-ND license (<http://creativecommons.org/licenses/by-nc-nd/4.0/>).

## 1. Introduction

Since the first case of ectopic adrenal tissue described by Morgagni in 1740, many cases have been reported involving various sites in the abdominopelvic cavity, most frequently associated with urogenital structures [1]. The reported settlement areas for ectopic adrenal tissue are the kidney, liver, pancreas, colon, celiac plexus, testis, broad ligament, placenta, ovary and retroperitoneal area [2–15]. Ectopic adrenal tissue is more common in male than female genital organs, particularly during childhood, and the most common site is the spermatic cord [10–12]. It has been proposed by various authors that ectopic adrenal tissue can be identified in

approximately 50% of newborns. However, most ectopic adrenal tissues become atrophic with age [12].

Although ectopic adrenal tissue can also occur in female genital structures, ovaries are rarely involved. There are only a few cases of ovarian ectopic adrenal tissue reported in Medline and to the best of our knowledge this case is the fourth one [6,7,16]. In this case report we present a very rare localization of ectopic adrenal tissue in the ovary of a 65-year-old patient and also draw attention to the risk of neoplastic transformation [14].

This work has been reported in line with SCARE Criteria [17].

## 2. Presentation of case

A 65-year-old patient was admitted to our clinic with complaints of postmenopausal vaginal bleeding and progressive pelvic pain for almost 6 months. Hypertension and asthma were recorded in the history and physical examination was unremarkable with the exception of bilateral lower quadrant tenderness. Laboratory tests including tumor markers were normal. Transvaginal ultrasound

\* Corresponding author. Present Address: Laboratory of Molecular Reproduction and Fertility Preservation, Department of Obstetrics and Gynecology, New York Medical College, 10595, Valhalla, NY, United States.

E-mail addresses: [enestaylanmd@gmail.com](mailto:enestaylanmd@gmail.com), [Enes.Taylan@nymc.edu](mailto:Enes.Taylan@nymc.edu) (E. Taylan).

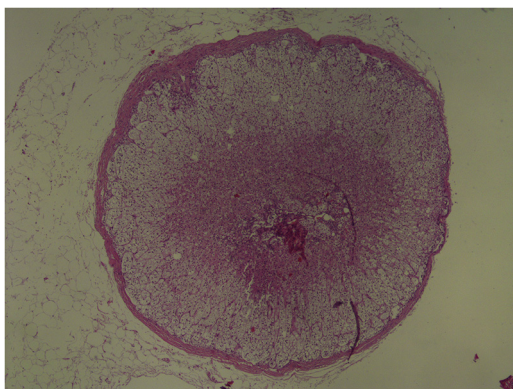


Fig. 1. H-E stained image of ectopic adrenal tissue in the ovary.

revealed a uterus with homogenous myometrium and increased endometrial thickness of 7 mm. The adnexa included 5 cm ovarian cysts with a benign appearance. Initial endometrial sampling was performed to examine possible underlying pathologies and the result indicated benign endometrial histology. Subsequently hysterectomy and bilateral salpingo-oophorectomy were performed via laparotomy. Frozen sections and the final pathological diagnosis were benign, indicating serous ovarian cystadenoma of both ovaries. The pathologist also reported that there was ectopic adrenal tissue on the wall of the left ovarian cystadenoma. Ectopic tissue and the left ovary were stained with hematoxylin-eosin (Fig. 1). Peritoneal cytology was also benign and the patient was discharged from hospital 3 days after surgery in a good condition.

### 3. Discussion

The adrenal glands are an important component of the endocrine system that have two embryological origins. While the adrenal cortex arises from the mesoderm, the adrenal medulla develops from the ectoderm. During embryological development medullary tissue invades the cortex along the central vein [1,2]. Defects in this penetration process may lead to small fragments, which subsequently separate and migrate with descent of the gonads [2,3]. This theory explains why the most common site for ectopic adrenal tissue is the spermatic cord region. Other reported localizations are in the retroperitoneal area, kidney, liver, pancreas, placenta, broad ligament, ovary and testis [2–15].

Ectopic adrenal tissue has been widely reported in different mammalian species, while in humans it has been reported that approximately 50% of newborns present with hormonally inactive or asymptomatic ectopic adrenal tissue [12,13]. However, these ectopic adrenal tissues become atrophic with age due to normally functioning adrenal glands and very rarely occur in adulthood. In some cases ectopic tissue may be hormonally active and cause corticotropin-independent Cushing's Syndrome [4]. Neoplastic transformation of ectopic adrenal tissue has also been reported [14]. As a consequence, it has been suggested that ectopic adrenal tissues should be excised if incidentally encountered during surgery [15].

Ectopic adrenal tissue is less frequent in female genital organs than in males, especially at older ages. The reported cases of ovarian ectopic adrenal tissue are limited to the papers published by Usta et al., Kim et al. and Yasar et al. [6,7,16]. To the best of our knowledge the case presented herein will be the fourth report in the English literature. Another important feature of our case is related to the age of the patient, who was 65 years old. As mentioned above, ectopic tissue generally disappears due to normally functioning adrenal

glands. In our case, despite the absence of endocrine symptoms, ectopic adrenal tissue presented at a late stage of life.

### 4. Conclusion

In conclusion, ectopic adrenal tissue is a very rare entity in elderly females. It may cause endocrine symptoms such as fasciotruncal obesity, hypertension and easy bruising, but it is generally asymptomatic and revealed incidentally during surgery. Although ectopic adrenal tissues are mostly nonfunctional, some cases have demonstrated the risk of neoplastic transformation. Therefore, surgeons must be aware of this rare entity, which bears the risk of malignancy, and surgically remove all suspicious lesions.

### Conflict of interest

The authors report no conflict of interest.

### Funding

No special funding.

### Ethical approval

None.

### Consent

Written informed consent was obtained from the patient for publication of this case report and accompanying images. A copy of the written consent is available for review by the Editor-in-Chief of this journal.

### Author contributions

Cagdas Sahin, Enes Taylan; study concept, data analysis and interpretation, writing the paper.

Ali Akdemir, Osman Zekioglu, Pervana Seyidova; data collection, data analysis and interpretation.

Ahmet M. Ergenoglu; study concept and design, data analysis, writing the paper.

### Guarantor

Ahmet M. Ergenoglu MD is the guarantor of this study.

### References

- [1] D.C. Schechter, Aberrant adrenal tissue, *Ann. Surg.* 167 (1968) 421–426.
- [2] J. Rosai, Adrenal gland and other paraganglia, in: J. Rosai (Ed.), *Rosai and Ackerman's Surgical Pathology*, 9th ed., Mosby Year Book, Edinburgh, 2004, pp. 1115–1118.
- [3] H. Bruning, G. Kootstra, F.J. Walther, J.W. Arends, Ectopic adrenocortical tissue along the spermatic cord, *Z. Kinderchir.* 39 (1984) 269–270.
- [4] J. Leibowitz, D. Pertsemlidis, J.L. Gabrilove, Recurrent Cushing's syndrome due to recurrent adrenocortical tumor fragmentation or tumor in ectopic adrenal tissue, *J. Clin. Endocrinol. Metab.* 83 (1998) 3786–3789.
- [5] L. Ventura, P. Leocata, A. Hind, I. Greco, T. Ventura, Ectopic adrenal tissue in the spermatic cord: case report and review of the literature, *Arch. Ital. Urol. Androl.* 70 (1998) 15–18.
- [6] T.H. Kim, D.S. Cha, K. Han, H.S. Youm, N.N. Hyon, Y. Chong, et al., Ectopic adrenal tissue in right uterine adnexa, *Korean J. Obstetr. Gynecol.* 51 (2008) 1562–1565.
- [7] L. Yasar, M. Ekin, C. Kaya, Y. Ozkan, A rare case of adrenal tissue in the left ovary in a patient with a granulosa cell tumor of the right ovary, *J. Gynecol. Surg.* 28 (2012) 220–222.
- [8] J.N. Cox, F. Chavrier, Heterotopic adrenocortical tissue within a placenta, *Placenta* 1 (1980) 131–133.
- [9] J.R. Anderson, A.H. Ross, Ectopic adrenal tissue in adults, *Postgrad. Med. J.* 56 (1980) 806–808.

- [10] H. Okur, M. Küçükaydin, A. Kazez, et al., Ectopic adrenal tissue in the inguinal region in children, *Pediatr. Pathol. Lab. Med.* 15 (1995) 763–767.
- [11] P. Oguzkurt, S. Oz, F. Kayaselcuk, Ectopic adrenal tissue: an incidental finding during inguinoscrotal operations in children, *Hernia* 6 (2002) 62–63.
- [12] C. Savas, O. Candir, M. Bezir, M. Cakmak, Ectopic adrenocortical nodules along the spermatic cord of children, *Int. Urol. Nephrol.* 32 (2001) 681–685.
- [13] G. Marino, M. Quartuccio, S. Rizzo, V. Lo Presti, A. Zanghi, Ectopic adrenal tissue in equine gonads: morphofunctional features, *Turk. J. Vet. Anim. Sci.* 36 (2012) 560–565.
- [14] E. Goren, I.S. Engelberg, A. Eidelman, Adrenal rest carcinoma in hilum of kidney, *Urology* 38 (1991) 187–190.
- [15] R. Mendez, M.G. Tellado, I. Somoza, J. Liras, A. Sanchez-Abuin, E. Pais, et al., Ectopic adrenal tissue in the spermatic cord in pediatric patients: surgical implications, *Int. Braz. J. Urol.* 32 (2006) 202–207.
- [16] U. Usta, E. Turkmen, N.E. Aydin, Adrenal ectopia within the wall of an ovarian serous cystadenoma, *Trakya Univ. Tip Fak. Derg.* 23 (2006) 95–98.
- [17] R.A. Agha, A.J. Fowler, A. Saetta, I. Barai, S. Rajmohan, Orgill DP and the SCARE Group. The SCARE Statement: consensus-based surgical case report guidelines, *Int. J. Surg.* 34 (2016) 180–186.

#### Open Access

This article is published Open Access at [sciencedirect.com](https://www.sciencedirect.com). It is distributed under the [IJSCR Supplemental terms and conditions](#), which permits unrestricted non commercial use, distribution, and reproduction in any medium, provided the original authors and source are credited.