

# Precautions for using a Filter Protection Device with a Flow Reversal Method during Carotid Artery Stenting: A Case Report on In-Filter Thrombus

## Abstract

The combination of a flow reversal with two balloons and a filter protection device is one of the safest methods that can be used during carotid artery stenting (CAS). Although major adverse events did not occur under restrict protection, we experienced a case of in-filter thrombus during the procedure. A 68-year-old male presented with temporary right hemiparesis. The radiological examinations revealed 95% stenosis on the origin of the left internal carotid artery (ICA). The patient underwent left CAS of wherein a proximal common carotid artery balloon, an external carotid artery balloon, and a distal ICA filter, with continuous flow reversal to the femoral vein, were used. Although the reversal circulation was established, a massive newly developing thrombus was found in the proximal side of the filter. After an additional systemic heparinization, the thrombus disappeared. The procedure was performed without any complications. Physicians should be aware of the risk of developing intraprocedural thrombosis in a filter protection device. Because the filter protection device is designed for the antegrade flow, it may promote the development of thrombus against the retrograde flow. Thus, the filter protection device should be retrieved first under the flow reversal circumstance to avoid the distal migration of a clot around the filter device.

**Keywords:** Carotid artery stenting, filter protection device, thrombus

## Introduction

Embolic protection devices (EPDs) are beneficial during carotid artery stenting (CAS).<sup>[1]</sup> Therefore, surgeons at most institutions select protection devices based on risk factors, expected tolerance of the patients to flow cessation by temporarily clamping the carotid artery, and plaque vulnerabilities. To avoid distal embolization of a plaque during procedures, some authors have recently reported the efficacy of using the combined protective method wherein a common carotid artery (CCA) balloon, an external carotid artery (ECA) balloon, and an internal carotid artery (ICA) filter, with continuous reversal flow to the femoral vein, are utilized.<sup>[2-4]</sup> Here, we present a case of CAS, wherein the combination of flow reversal method and the distal filter was used. Moreover, a massive intraprocedural thrombus was found in the filter device. Because the filter protection device is designed under the antegrade flow condition, the manufacture and seller never consider such usage. The possible causes of

intraprocedural in-filter thrombus and the management of patients are discussed to prevent subsequent catastrophic ischemic events.

## Case Report

A 68-year-old male patient presented with frequent temporary right hemiparesis that lasts for approximately 5 min. The patient had been taking medication for hypertension, diabetes mellitus, and hyperlipidemia. The radiological examinations revealed 95% stenosis of the origin of the left ICA [Figure 1a]. We have obtained a written informed consent from the patient. The patient was prescribed 75 mg/day of clopidogrel and 200 mg/day of cilostazol for 2 weeks before CAS. The patient underwent left CAS under local anesthesia.

A 4-Fr short sheath was first inserted into the right femoral vein prepared with the flow reverse circulation. An 8-Fr short sheath was introduced into the right femoral artery. Then, intravenous heparin was then administered to achieve an activated clotting time (ACT)

**Tomotaka Ohshima,  
Shigeru Miyachi,  
Naoki Matsuo<sup>1</sup>,  
Reo Kawaguchi<sup>1</sup>,  
Masakazu  
Takayasu<sup>1</sup>**

*Neuroendovascular Therapy Center, Aichi Medical University, <sup>1</sup>Department of Neurosurgery, Aichi Medical University, Yazakokarimata, Nagakute, Aichi, Japan*

### Address for correspondence:

*Dr. Tomotaka Ohshima,  
Neuroendovascular Therapy Center, Aichi Medical University, 1-1 Yazakokarimata, Nagakute, Aichi 480-1195, Japan.  
E-mail: tmtkoh@gmail.com*

### Access this article online

**Website:** [www.asianjns.org](http://www.asianjns.org)

**DOI:** 10.4103/ajns.AJNS\_296\_18

### Quick Response Code:



**How to cite this article:** Ohshima T, Miyachi S, Matsuo N, Kawaguchi R, Takayasu M. Precautions for using a filter protection device with a flow reversal method during carotid artery stenting: A case report on in-filter thrombus. *Asian J Neurosurg* 2019;14:1008-10.

This is an open access journal, and articles are distributed under the terms of the Creative Commons Attribution-NonCommercial-ShareAlike 4.0 License, which allows others to remix, tweak, and build upon the work non-commercially, as long as appropriate credit is given and the new creations are licensed under the identical terms.

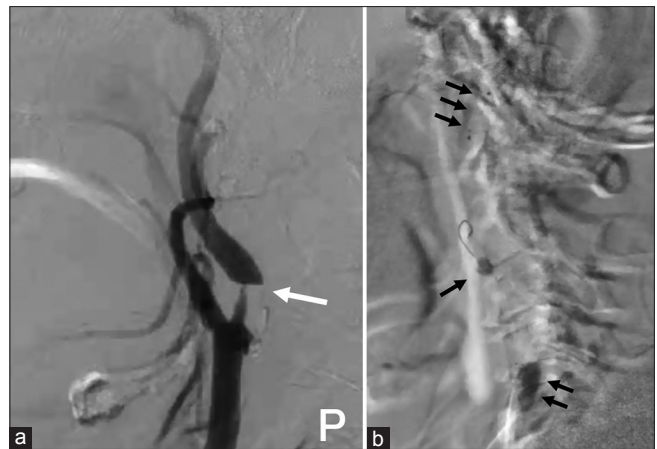**For reprints contact:** [reprints@medknow.com](mailto:reprints@medknow.com)

>250 s. An 8-Fr Cello balloon guiding catheter (Medtronic, Minneapolis, MN, USA) was advanced into the left common carotid artery. A PercuSurge Guardwire (200 cm; Medtronic) was navigated into ECA. When both balloons were inflated, reversal flow was established from the distal ICA to the femoral vein through the guiding catheter. Then, a Spider FX embolic protection device (Medtronic) was cautiously navigated to the distal ICA through the stenotic lesion with Chikai 14 micro guidewire (Asahi Intecc, Aichi, Japan) under road-mapping guidance [Figure 1b]. Although the retrograde flow was spontaneously collected, a massive newly developing thrombus was found in the basket of the filter [Figure 2]. Because ACT was 288 s, we added 2000 U of heparin intravenously. After we waited and observed the thrombus for 5 min, it became smaller and moved proximally out of the filter and then, completely disappeared. ACT was 330 s at that time. Although we checked the forced aspiration of the blood, there was no visible thrombus in the collected blood. We decided to continue with the procedure. A pre-stenting balloon (3.5 mm × 40 mm angioplasty balloon) was inflated at the stenotic lesion. A Carotid WALLSTENT that was 8 mm × 21 mm in size (Boston Scientific, Natick, MA, USA) was then used. Poststenting dilatation was performed at the narrowest area using a 4.5 mm × 30 mm angioplasty balloon until nominal pressure was achieved. The filter was retrieved under the reversal flow circulation. Then, both balloons were deflated. Complete carotid reconstruction was achieved [Figure 3a]. Postoperative intracranial angiography showed no embolism [Figure 3b]. Magnetic resonance imaging on the postoperative day 1 showed no abnormal lesion correlating to the procedure. The patient's postoperative course was uneventful, and he was discharged from the hospital on the postoperative day 6.

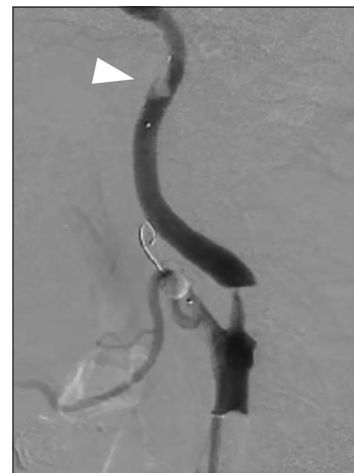## Discussion

Since the introduction of CAS, the treatment options for carotid stenosis have changed. CAS is increasingly utilized in patients with carotid artery stenosis.<sup>[5]</sup> Several EPDs are widely used. However, each device has its own disadvantages, which limit the universal application of any device. Some authors have recently reported the efficacy of the combined protective method that used a CCA balloon, an ECA balloon, and an ICA filter, with continuous reversal flow to the femoral vein.<sup>[2-4]</sup> Goto *et al.* have reported that the incidence rate of both distal embolization and unexpected intraprocedural complications was low when the combined protective method, namely, the universal protection method (UPM) rather than other distal or proximal protective methods are used.<sup>[4]</sup> We entirely agree with the efficacy of the UPM according to our experiences; however, previous studies have not shown that the use of the filter device was not recommended.

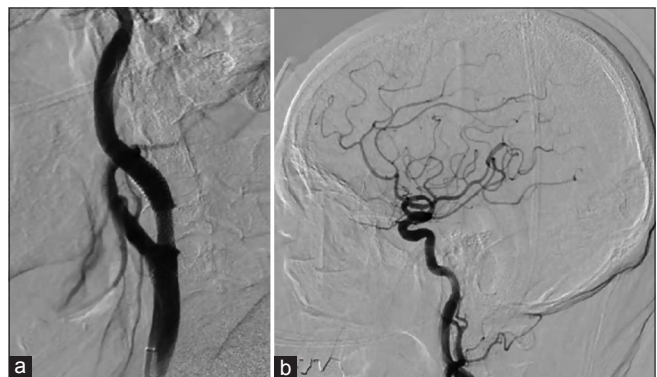
The filter protection device is designed to restore the blood flow during procedures. The filter works under the antegrade flow that is similar to a parachute. When the



**Figure 1:** (a) Preoperative lateral view of left carotid angiography showing 95% stenosis of the origin of the internal carotid artery (white arrow). P: posterior. (b) Intraoperative road-mapping image showing the universal protection method. Single arrow, balloon in the external carotid artery; double arrows, balloon in the common carotid artery; triple arrows, filter device in the internal carotid artery




**Figure 2:** Intraoperative lateral view of left carotid angiography showing in-filter thrombus (white arrow head). The contrast medium was collected automatically from the guiding catheter to the femoral vein through the external shunt



**Figure 3:** (a) Postoperative lateral view of left carotid angiography showing a complete reconstruction. (b) Postoperative left intracranial carotid angiography showing no major arterial thrombosis

parachute receives the retrograde flow, it must be collapsed. The filter protection device may collapse under retrograde




**Figure 4:** Photographs of the experiments with a FilterWire EZ. The arrows indicate the direction of the fluid flow. (a) Under the antegrade flow, the filter showing enough expansion. (b) Under the retrograde flow, the filter showing shrinking. The arrowheads indicate a collapsed filter

circulation. Because the filter protection device is designed under the antegrade flow condition, the manufacture and seller never consider such usage. Figures 4 and 5 show *in vitro* experiments on the relationship between the filter device and flow direction. When the direction of the fluid flow was antegrade, the filter showed enough expansion. However, when the fluid flow was retrograde, the filter showed irregularly shrinking. Indeed, the use of the filter device under the retrograde circulation is contraindicated. These findings were more obvious with the FilterWire EZ (Boston Scientific, Natick, MA, USA) of which design was a thin membrane than with the Spider FX of which design was a fine net. This study has some limitations. First, current flow circulating vascular model showed an approximately 20 cm/s flow velocity. We have to evaluate under the precise flow condition of antegrade and retrograde, respectively. Second, the viscosity of the fluid becomes another important factor for receiving the filter device. Finally, computed fluid dynamics might be clear the turbulent flow pattern around the filter device.

In this case, when we confirmed the massive thrombus in the filter, we primarily chose to perform an intensification of systemic heparinization rather than mechanical clot retrieval. If the thrombus is retrieved through forced aspiration, other thrombus might gush out from the filter one by one. Moreover, the massive thrombus may spill over into ICA or the guiding catheter during the filter retrieval. The thrombus was located only on the proximal side of the filter. If the patient's coagulability was further promoted, the thrombus might advance to the distal side of the filter.

Although the in-filter thrombus was confirmed in this case, there was no complication associated with the procedure. UPM can be safely used again. We recommend that the filter protection device should be released and first retrieved under the flow reversal circumstance with the two balloons because the thrombus might advance to the distal side of the filter.



**Figure 5:** Photographs of the experiments with a Spider FX. The arrows indicate the direction of the fluid flow. (a) Under the antegrade flow, the ring showing enough expansion and adapted. (b) Under the retrograde flow, the filter showing slightly elongated

UPM is one of the most theoretical reliable protection methods during CAS; however, physicians should be aware of the risk of developing intraprocedural thrombosis inside the filter protection device. Because these devices are designed to work under antegrade flow, they may not work well with the off-label usage. Thus, the filter protection device should be first retrieved under the flow reversal circumstance to prevent the distal migration of a clot around the filter device.

#### Declaration of patient consent

The authors certify that they have obtained all appropriate patient consent forms. In the form the patient(s) has/have given his/her/their consent for his/her/their images and other clinical information to be reported in the journal. The patients understand that their names and initials will not be published and due efforts will be made to conceal their identity, but anonymity cannot be guaranteed.

#### Financial support and sponsorship

Nil.

#### Conflicts of interest

There are no conflicts of interest.

#### References

1. Macdonald S. New embolic protection devices: A review. *J Cardiovasc Surg (Torino)* 2011;52:821-7.
2. Harada K, Kakumoto K, Morioka J, Saito T, Fukuyama K. Combination of flow reversal and distal filter for cerebral protection during carotid artery stenting. *Ann Vasc Surg* 2014;28:651-8.
3. Ohshima T, Bishnori I, Ishikawa K, Goto S, Yamamoto T, Kato Y, *et al.* The feasibility and safety of separate carotid artery stenting using the restrict protective method for bilateral carotid stenosis. *World Neurosurg* 2017;102:235-9.
4. Goto S, Ohshima T, Kato K, Izumi T, Wakabayashi T. Efficacy of carotid artery stenting by the universal protection method. *J Stroke Cerebrovasc Dis* 2018;27:2187-91.
5. Phatouros CC, Higashida RT, Malek AM, Meyers PM, Lempert TE, Dowd CF, *et al.* Carotid artery stent placement for atherosclerotic disease: Rationale, technique, and current status. *Radiology* 2000;217:26-41.