

Application of intraoperative navigation in 3D laparoscopic pancreaticoduodenectomy: A case report

HANZHANG DONG¹, MINGJIAN LUO¹, SHAOBIAO KE¹, JIULIN ZHAN¹, XI LIU^{1,2} and ZHIWEI LI¹

¹Department of Hepatobiliary and Pancreatic Surgery, Kanghua Hospital, Dongguan, Guangdong 523080;

²Second Clinical Medical College, Guangzhou University of Chinese Medicine, Guangzhou, Guangdong 510006, P.R. China

Received March 16, 2022; Accepted May 5, 2022

DOI: 10.3892/etm.2022.11380

Abstract. Laparoscopic pancreaticoduodenectomy is one of the most challenging operations in abdominal surgery, with a high risk and numerous potential complications. Laparoscopy can magnify the surgical field, improving vision, but it cannot see through and identify the internal structures of the surgical field. Intraoperative navigation is a technology currently being developed; it projects the three-dimensional (3D) image established before surgery onto the surgical area during surgery, locates the anatomical landmarks, matches the 3D image with the actual image, and then displays the relationship between the tumor and the surrounding blood vessels. The important structures such as tumors, blood vessels, bile ducts and pancreatic ducts are quickly identified. Secondary injuries are reduced, the operation speed is increased and the surgical safety is improved. The present study describes the use of surgical navigation technology in the 3D laparoscopic pancreaticoduodenectomy of a 64-year-old man. The present paper reports the treatment process of the case, the application of surgical navigation technology in the operation and discusses the advantages of surgical navigation technology in 3D laparoscopic pancreaticoduodenectomy.

Introduction

Pancreatic cancer is a highly malignant tumor, and pancreaticoduodenectomy is currently the effective treatment for pancreatic cancer (1). Based on the GLOBOCAN 2012 estimates, pancreatic cancer ranked as the 7th cause of cancer-associated mortality and the 11th most common type of cancer in the world. The estimated 5-year survival rate for pancreatic cancer is <5% (2). Pancreatic head cancer can

invade the portal vein, superior mesenteric vein and other blood vessels. Sometimes it is difficult to judge whether the tumor can be resected. Three-dimensional (3D) reconstruction imaging of the surgical site prior to surgery plays an important role in judging whether the pancreatic head cancer can be resected. 3D laparoscopic pancreaticoduodenectomy has the advantages of a stereoscopic view, accurate spatial positioning and a clear view of the anatomy, which are beneficial to the dissection of lymph nodes and the reconstruction of the digestive tract (3). Intraoperative navigation can accurately identify the blood vessels around the tumor, prevent unnecessary damage, reduce bleeding and shorten the surgical duration (4). Intraoperative navigation has obvious advantages in 3D laparoscopic pancreaticoduodenectomy. The current study discusses the use of intraoperative navigation in the 3D laparoscopic pancreaticoduodenectomy of a 64-year-old man.

The chief surgeon who performed the surgery in the present case has experience of >100 cases of open pancreaticoduodenectomy and 32 cases of laparoscopic pancreaticoduodenectomy. The average duration of these laparoscopic pancreaticoduodenectomy surgeries is ~9 h (range, 7 h and 22 min to 12 h and 37 min). The average blood loss is ~170 ml (range, 40-600 ml).

Case report

Patient information. A 64-year-old man with an ~10-year medical history of type 2 diabetes mellitus was referred on January 11, 2022, to the Department of Hepatobiliary and Pancreatic Surgery of Kanghua Hospital (Dongguan, China) complaining of upper abdominal pain without nausea or vomiting for 1 day.

Physical examination revealed that there was no yellowing of the skin and sclera. The abdomen was flat, the abdominal muscle was not tense, abdominal tenderness and rebound tenderness were negative, and bowel sounds were heard three times every minute. The results of the laboratory examinations are presented in Table I; no abnormality was revealed in the laboratory examination. For blood routine testing, an automatic hemocytometer (model, BC 5000; Mindray) was used, while an automatic biochemical analyzer (model, ADVIA 2400; Siemens AG) was used for blood biochemical testing and a blood coagulation analyzer (model, CS 5100; Sysmex Corporation) was used for blood coagulation testing. An

Correspondence to: Professor Zhiwei Li, Department of Hepatobiliary and Pancreatic Surgery, Kanghua Hospital, 1000 Dongguan Avenue, Dongguan, Guangdong 523080, P.R. China
E-mail: lizhiwei67@126.com

Key words: laparoscopic pancreaticoduodenectomy, surgical navigation technology, 3D laparoscopic, pancreatic neoplasms, 3D image

electrocardiogram and chest X-ray showed no obvious abnormalities. Abdominal computed tomography (CT) showed an oval low-density shadow on the head of the pancreas, ~19x22 mm in size, with clear edges and the internal texture was heterogeneous (Fig. 1). Enhanced CT showed that the edge of the shadow was enhanced, with no enhancement internally (Fig. 2).

The preoperative diagnosis was pancreatic head mass, and pathological results were required for a definitive diagnosis. The treatment plan, operative risks and possible postoperative complications were explained to the patient and their family members. The risks of surgery mainly included the injury of important blood vessels during the operation, such as the inferior mesenteric vein, portal vein, splenic vein and superior mesenteric artery. Postoperative complications mainly included pancreaticoenteric anastomotic leakage, biliary-enteric anastomotic leakage, gastrointestinal anastomotic leakage, bleeding, abdominal infection, intestinal obstruction, pulmonary infection, atelectasis, lower extremity venous thrombosis and tumor recurrence. Written informed consent was obtained for the procedure.

Methods

3D reconstruction imaging of the surgical site. High quality thin-section CT images of the patient were acquired before surgery. Plain and enhanced CT examinations of the upper abdomen were performed by 256-slice spiral CT (Philips Healthcare). The images were input into the medical image 3D visualization system (MI-3DVS; software copyright no., 2008SR18798; Software School of South China University of Technology; Guangzhou, China) for 3D reconstruction imaging to judge the relationships of the tumor and the peripheral blood vessels, common bile duct and pancreatic duct, and to evaluate whether the tumor was resectable (Figs. 3 and 4).

3D laparoscopic navigation system. During the operation, the surgical image of from the 3D high-definition laparoscope (model, 22204011U114; Karl Storz SE and Co. KG) was input into the video parser, and then output to the 3D laparoscope navigation system (software copyright no., 2018SR840555; Software School of South China University of Technology; Guangzhou, China) in the computer by the video acquisition card in line-by-line format. The 3D reconstruction image of the artery, vein, pancreas and pancreatic duct was rendered and color-set in the 3D laparoscopic navigation system. The transparency of the 3D reconstructed image was initially set to 0.5, and the transparency of the tumor, artery, vein, pancreas and pancreatic duct could be adjusted according to the needs of the operation during the navigation process. During the operation, the 3D reconstructed image was projected into the 3D laparoscopic operation view to assist in the navigation during the operation.

Navigation process during surgery. The operation was performed using the five-hole method. After the establishment of a pneumoperitoneum, the abdominal cavity was first examined to determine whether there was tumor metastasis. The gastrocolic ligament was incised to expose the pancreas, and then the pancreas was matched with the 3D reconstructed pancreas image established before surgery in the

3D laparoscopic navigation system according to the shape of the pancreas. The course of the superior marginal artery of the pancreas was shown, and the common hepatic artery, the proper hepatic artery and the gastroduodenal artery were dissected by navigation (Fig. 5). The lymph nodes in group 8a were removed for rapid pathological examination (Fig. 6). The proper hepatic artery and gastroduodenal artery were used as markers to match with the 3D reconstructed image to navigate the portal vein. The transparency of the pancreas was adjusted to 0.2-0.3. The superior mesenteric vein was navigated with the marker of the portal vein (Fig. 7), and then the posterior pancreatic tunnel was established (Fig. 8). The pancreatic duct, superior mesenteric artery, inferior pancreaticoduodenal artery, and veins of the pancreatic uncinate process draining back to the portal vein were navigated (Fig. 9), and then the uncinate process was excised (Fig. 10). After a tumor specimen was removed (Fig. 11), the superior mesenteric artery and superior mesenteric vein were used as markers to navigate the lymph node dissection. An ~5-cm incision was made in the transverse mesocolon, and the jejunum stump was sent to the pancreas stump and the common hepatic duct stump through the transverse mesocolon incision, and a pancreaticojejunostomy and a cholangiojejunostomy were performed (Figs. 12 and 13). The gastrointestinal anastomosis was performed at a distance of ~50 cm from the cholangiojejunostomy (Fig. 14). A drainage tube was placed near the pancreaticojejunostomy and another one was placed near the cholangiojejunostomy.

Results. The operation took 520 min, the intraoperative blood loss was ~50 ml, and antibiotics were used before and during the operation. Intraoperative frozen rapid pathological examination of lymph nodes in group 8a showed lymph node inflammatory reaction. Somatostatin and albumin were used after surgery. The patient was treated with 45 ml normal saline plus 0.3 mg somatostatin, pumped intravenously, at 4 ml per hour for 3 days, in addition to intravenous infusion of albumin at 20 g per day, for 6 days. An insulin pump was used to control the blood glucose level under the guidance of an endocrinologist after surgery. The post-surgery drainage volumes obtained from the tubes near the pancreaticojejunostomy and cholangiojejunostomy are shown in Fig. 15. On the 1st day after the operation, 65 ml of fluid was drained from near the pancreaticojejunostomy, 70 ml of fluid was drained from near the cholangiojejunostomy, and the amylase in the drainage fluid of the pancreaticojejunostomy was measured at 610 U/l. On the 2nd day after the operation, 10 ml was drained from near the pancreaticojejunostomy, 15 ml was drained from near the cholangiojejunostomy, and the amylase in the drainage fluid of the pancreaticojejunostomy was measured at 1,436 U/l. On the 3rd day after the operation, there was no liquid from the drainage tubes. On the 5th day after the operation, the patient ate food. On the 10th day after the operation, no peritoneal effusion was found in the abdominal cavity by B-ultrasound examination, and the abdominal drainage tubes were removed. The increase of drainage volume cannot be determined to be caused by eating, as it may also be caused by the unobstructed drainage tube. The patient was discharged on the 12th day after the operation with

Table I. Results of laboratory examinations.

Variable	Result	Reference interval
Hemoglobin, g/l	136	130-175
Albumin, g/l	39.6	40-55
Aspartate aminotransferase, U/l	11	15-40
Alanine aminotransferase, U/l	12	9-50
Total bilirubin, μ mol/l	8.4	0-26
Direct bilirubin, μ mol/l	3	0-8
Plasma prothrombin time, sec	10	9.8-12.1
Activated partial thromboplastin time, sec	25	25-31.3
Blood amylase, U/l	289	25-100
Blood lipase, U/l	422	13-60
Sugar chain antigen-199, U/ml	25.59	≤ 34
Blood sugar, mmol/l	5.73	4.1-5.9

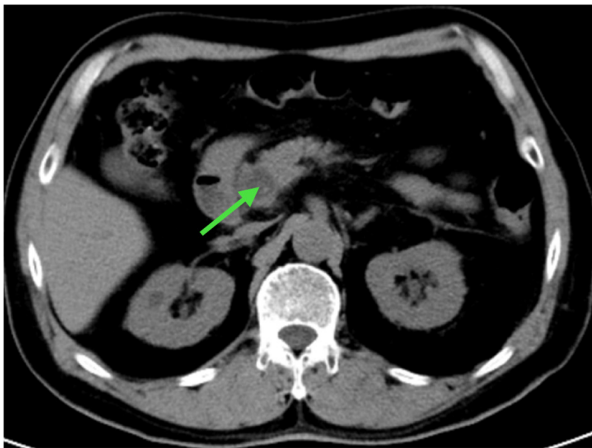


Figure 1. Abdominal computed tomography scan showing an oval low-density shadow on the head of the pancreas, ~19x22 mm in size, with clear edges and an heterogenous internal texture (arrow).

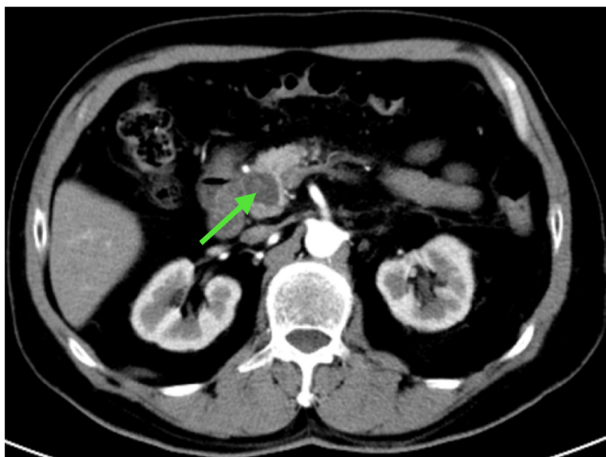


Figure 2. Enhanced computed tomography scan showing the enhanced edge of the shadow, with no enhancement inside (arrow).

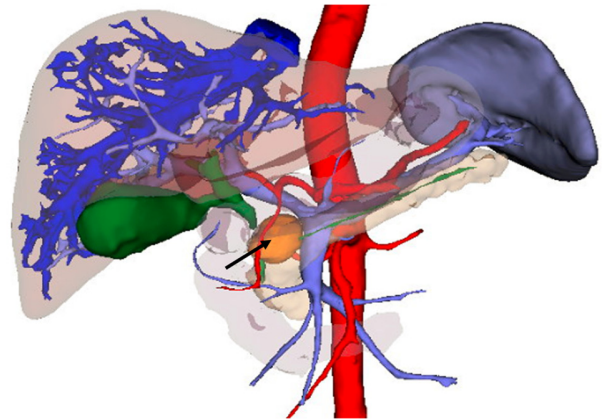


Figure 3. Three-dimensional reconstruction of the frontal image of the surgical area. The tumor is indicated by an arrow. The gallbladder and biliary tract are green, the arteries are red, the veins of the liver are dark blue and the portal vein, superior mesenteric vein and splenic vein are light blue.

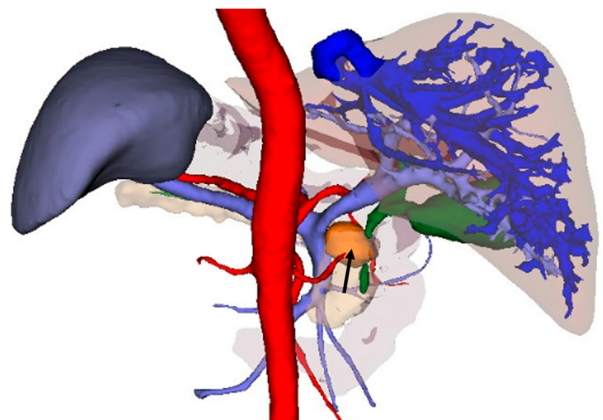


Figure 4. Three-dimensional reconstruction of the posterior image of the surgical area. The tumor is indicated by an arrow. The gallbladder and biliary tract are green, the arteries are red, the veins of the liver are dark blue and the portal vein, superior mesenteric vein and splenic vein are light blue.

no postoperative complications. The patient was followed up in the 1st month and 3rd month after the operation, and

there was no abnormality. The patient will follow up every year for 5 consecutive years. Pathological results revealed

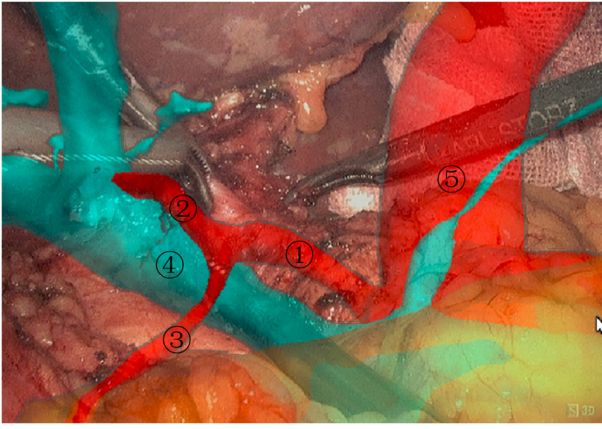


Figure 5. Separation of the common hepatic artery by navigation, and the dissection of the eighth group of lymph nodes. 1, common hepatic artery; 2, proper hepatic artery; 3, gastroduodenal artery; 4, portal vein; 5, aorta abdominalis.

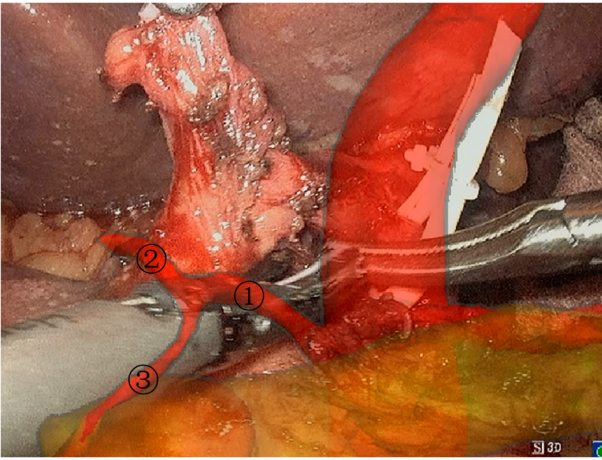


Figure 6. Separation of the gastroduodenal artery by navigation. 1, common hepatic artery; 2, proper hepatic artery; 3, gastroduodenal artery.

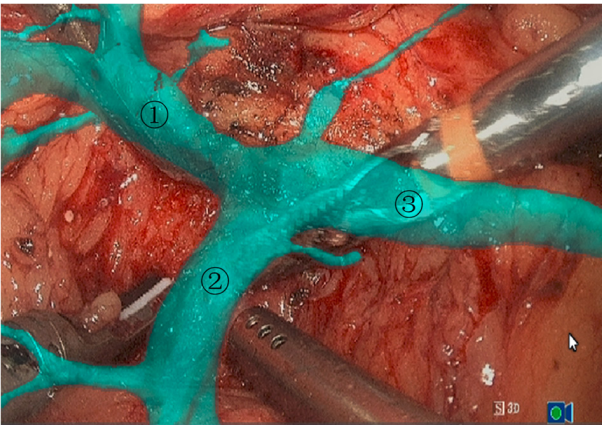


Figure 7. Separation of the inferior border of the pancreas and the superior mesenteric vein by navigation. 1, portal vein; 2, superior mesenteric vein; 3, splenic vein.

chronic pancreatitis, pancreatic pseudocyst, focal necrosis of duodenal mucosa and chronic cholecystitis.

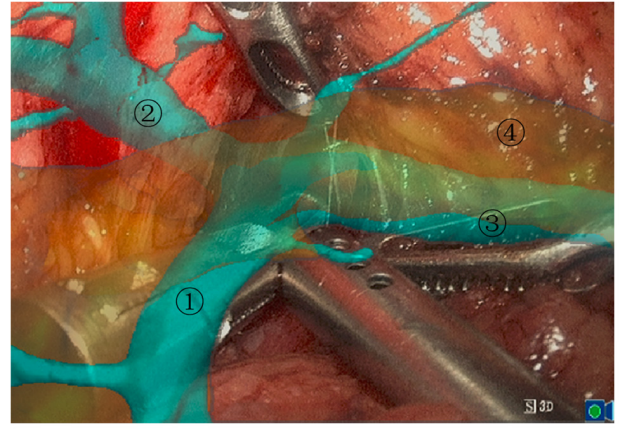


Figure 8. Pancreatic tunnel established by navigation. 1, superior mesenteric vein; 2, portal vein; 3, splenic vein; 4, tail of the pancreas.

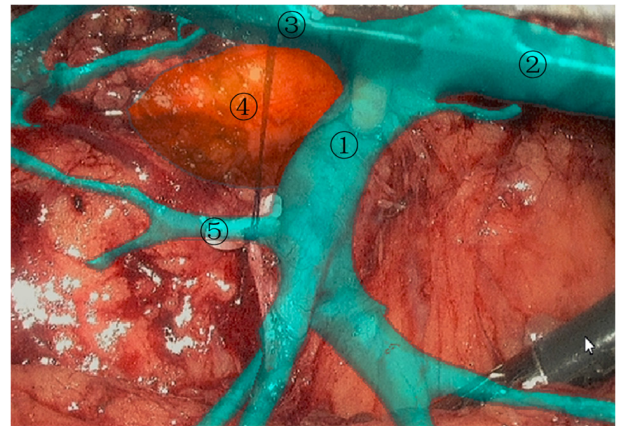


Figure 9. Separation of the inferior pancreaticoduodenal vein by navigation. 1, superior mesenteric vein; 2, splenic vein; 3, portal vein; 4, tumor; 5, inferior pancreaticoduodenal vein.

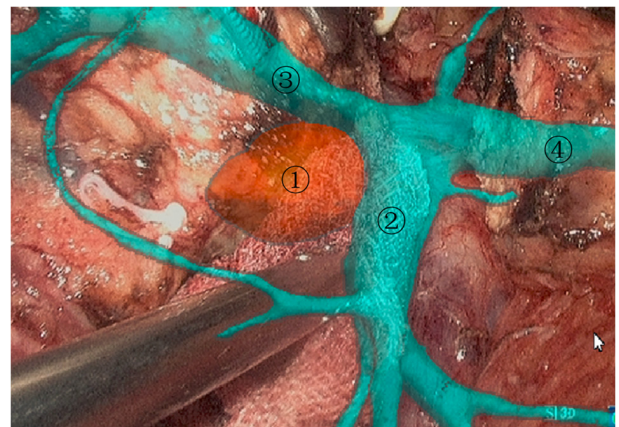

Figure 10. Separation of the superior mesenteric vein and tumor by navigation. 1, tumor; 2, superior mesenteric vein; 3, portal vein; 4, splenic vein.

Discussion

The anatomical structure of the pancreaticoduodenal region is complex. Pancreaticoduodenectomy has the characteristics of being a difficult operation, with a high risk and numerous

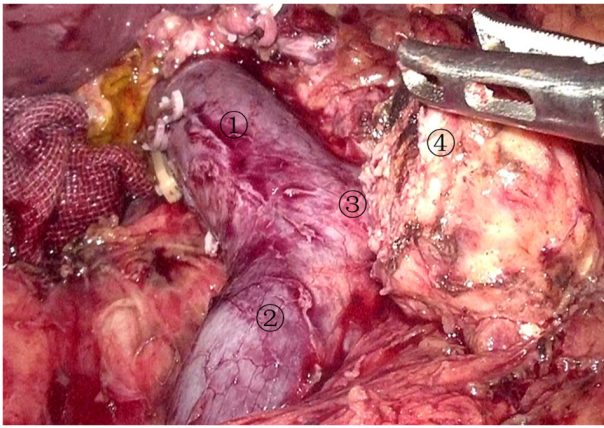


Figure 11. Image after specimen resection. 1, portal vein; 2, superior mesenteric vein; 3, splenic vein; 4, the pancreas stump.

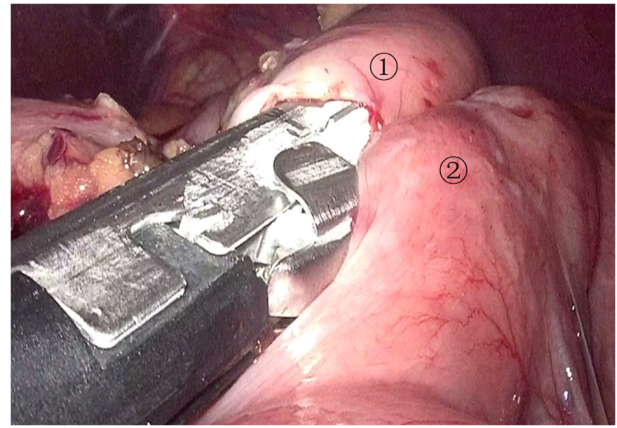


Figure 14. Gastrointestinal anastomosis by three-dimensional laparoscopy. 1, stomach; 2, jejunum.

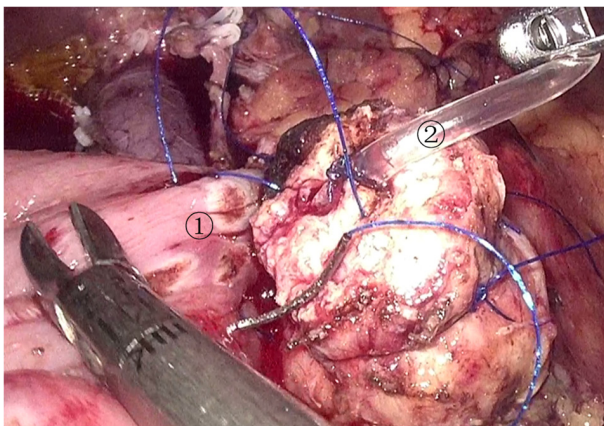


Figure 12. Pancreaticojejunostomy by three-dimensional laparoscopy. 1, jejunum; 2, supporting catheter in the pancreatic duct.

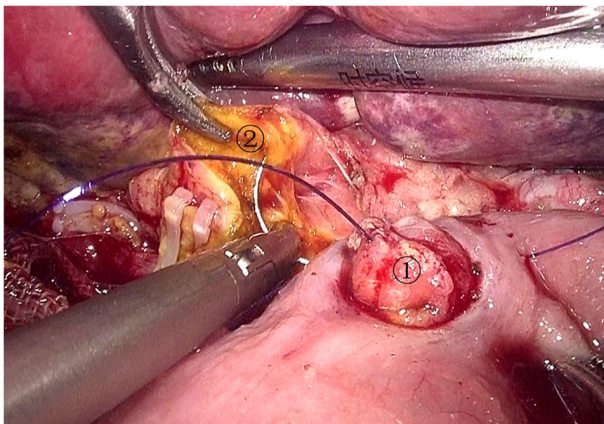


Figure 13. Cholangiojejunostomy by three-dimensional laparoscopy. 1, jejunum; 2, common hepatic duct stump.

potential complications. At present, laparoscopic or robotic pancreaticoduodenectomy is still one of the most challenging operations in abdominal surgery (5).

The relationships between the tumor and surrounding structures, such as the portal vein, superior mesenteric artery, superior mesenteric vein, celiac trunk, common hepatic artery,

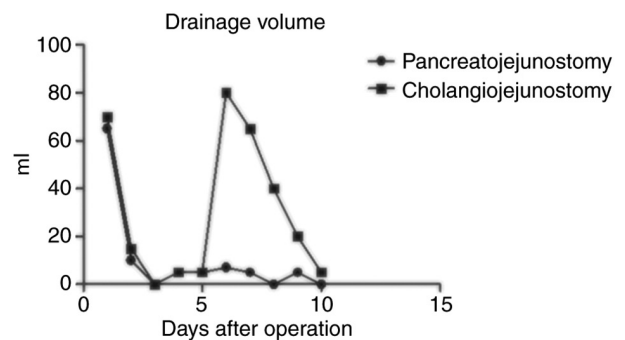


Figure 15. Post-surgery drainage volume recorded from the tubes placed near the pancreaticojejunostomy and the cholangiojejunostomy.

common bile duct and pancreatic duct, need to be accurately judged before evaluating whether the tumor can be resected (6). At present, CT and MRI are the main imaging examinations before surgery, and both techniques provide two-dimensional images, which cannot display the relationship between the tumor and important pipelines in a three-dimensional manner. It is also difficult to differentiate between blood vessels in the surgical area (7). The 3D reconstructed image can stereoscopically display the relationship between the tumor and the surrounding structures, and display the variation in the blood vessels in the operative area, which is helpful for selecting the surgical plan, for reducing accidental injuries during the operation and for shortening the surgical duration (8).

The main reason for the poor surgical outcome of pancreatic cancer is tumor recurrence and metastasis. Lymph node dissection and negative resection margins are of great significance for improving the surgical effect and prolonging the survival time of patients (9,10). There are fat, lymph, nerve and other tissues behind the pancreatic head, which is the site where tumors are prone to metastasize and recur. The 3D reconstructed image plays an important role in the complete removal of fat, lymph, nerves and other tissues behind the pancreatic head. The diameter and position of the pancreatic duct can be displayed on the 3D reconstructed image, which is helpful for revealing the pancreatic duct during surgery. For patients who need vascular resection and reconstruction, the 3D reconstructed image can display information such as the

position of tumor invasion, the deformed length and angle of the involved blood vessel, which is helpful for choosing the method of vascular resection and reconstruction.

In laparoscopic or robotic pancreaticoduodenectomy, the 3D reconstructed image is matched with the actual image by image projection in order to aid navigation in the operation. The shape of the navigation image is adjusted by computer software according to the actual image, so that the actual image and the navigation image are accurately matched. The tumor, pancreatic duct, common bile duct and surrounding blood vessels can be made 3D and visualized, so that surgeons can quickly identify important anatomical structures, reduce accidental injuries, reduce intraoperative bleeding and increase the speed of the operation. The position of pancreatic dissection determined before surgery can also be projected to the intraoperative image to guide the dissection of the pancreas.

The difficulty and risk of the operation are increased for the variant hepatic artery. If the variant hepatic artery is damaged, the blood perfusion of the liver and biliary tract in the corresponding area will be affected, and complications such as liver dysfunction, bile leakage and bleeding may be incurred after surgery (11,12). Navigation can display the shape, course and adjacent relationship of the variant hepatic artery, which is of great significance for preventing the damage of variant blood vessels. There are small branches of the pancreatic duct in pancreatic tissue, and postoperative pancreatic leakage is hard to avoid. The 3D reconstructed image can show the course of the pancreatic duct, as well as the number and shape of the main pancreatic duct and the auxiliary pancreatic duct. Knowledge of the exact location of the pancreatic duct is helpful to prevent pancreatic leakage after surgery.

There is currently rapid development of laparoscopic and robotic pancreatic surgery techniques (13,14), which provide the advantages of less trauma, faster recovery and fewer complications (15,16). After surgery, patients can receive comprehensive treatment earlier and thus the prognosis is improved. Laparoscopic and robotic surgery can magnify the view of the surgical field, but cannot see through important anatomical structures in the surgical field and do not have the sense of touch of the human hand. The risk of surgery is increased due to tumor growth that deforms vital anatomical structures around the tumor and deviates some important pipelines from their original positions, and also due to the variation of anatomical structures, especially ectopic important pipelines. In the operation of 3D laparoscopic tumor resection, the use of navigation technology can quickly identify important anatomical structures, identify the deformation and ectopic anatomical structures, avoid unnecessary injuries, and make the operation more convenient and safe.

Acknowledgements

Not applicable.

Funding

No funding was received.

Availability of data and materials

The datasets used and/or analyzed during the current study are available from the corresponding author on reasonable request.

Authors' contributions

HD and ZL were involved in data analysis and interpretation, conception and design of the study, and drafted the manuscript. ML, SK, XL and JZ participated in the operation, collected the data and confirm the authenticity of the raw data. All authors have read and approved the final manuscript.

Ethics approval and consent to participate

The present study was approved by the Ethics Committee of Kanghua Hospital (Dongguan, China; approval no. 22015). Written informed consent was obtained from the patient.

Patient consent for publication

The patient provided written consent and agreed for their data (shown in the figures) to be published.

Competing interests

The authors declare that they have no competing interests.

References

1. Karim SAM, Abdulla KS, Abdulkarim QH and Rahim FH: The outcomes and complications of pancreaticoduodenectomy (Whipple procedure): Cross sectional study. *Int J Surg* 52: 383-387, 2018.
2. Ilic M and Ilic I: Epidemiology of pancreatic cancer. *World J Gastroenterol* 22: 9694-9705, 2016.
3. Zhang H, Guo X, Xia J, Zhu F, Shen M, Wang X, Wang M and Qin R: Comparison of Totally 3-Dimensional laparoscopic pancreaticoduodenectomy and open pancreaticoduodenectomy. *Pancreas* 47: 592-600, 2018.
4. Sabri SA and York PJ: Preoperative planning for intraoperative navigation guidance. *Ann Transl Med* 9: 87, 2021.
5. Zimmerman AM, Roye DG and Charpentier KP: A comparison of outcomes between open, laparoscopic and robotic pancreaticoduodenectomy. *HPB (Oxford)* 20: 364-369, 2018.
6. Kumar RP, Pelanis E, Bugge R, Brun H, Palomar R, Aghayan DL, Fretland AA, Edwin B and Elle OJ: Use of mixed reality for surgery planning: Assessment and development workflow. *J Biomed Inform* 112S: 100077, 2020.
7. Gabrielli ME, Saun TJ, Jung JJ and Grantcharov TP: Assessment of 3-Dimensional vs 2-Dimensional imaging and technical performance using a multiport intraoperative data capture and analytic system for patients undergoing laparoscopic Roux-en-Y gastric bypass surgery. *JAMA Netw Open* 3: e1920084, 2020.
8. Simpfendorfer T, Li Z, Gasch C, Drosdzol F, Fangerau M, Müller M, Maier-Hein L, Hohenfellner M and Teber D: Three-Dimensional reconstruction of preoperative imaging improves surgical success in laparoscopy. *J Laparoendosc Adv Surg Tech A* 27: 181-185, 2017.
9. Aiolfi A, Lombardo F, Bonitta G, Danelli P and Bona D: Systematic review and updated network meta-analysis comparing open, laparoscopic, and robotic pancreaticoduodenectomy. *Updates Surg* 73: 909-922, 2021.
10. Bencini L, Urciuoli I, Trafeli M, Paolini C, Moraldi L, Tribuzi A, Pacciani S and Coratti A: Robotic pancreatic surgery: Minimally invasive approach to challenging operations. *Minerva Surg* 76: 138-145, 2021.
11. Subar D, Gobardhan PD and Gayet B: Laparoscopic pancreatic surgery: An overview of the literature and experiences of a single center. *Best Pract Res Clin Gastroenterol* 28: 123-132, 2014.

12. Kawaida H, Kono H, Hosomura N, Amemiya H, Itakura J, Fujii H and Ichikawa D: Surgical techniques and postoperative management to prevent postoperative pancreatic fistula after pancreatic surgery. *World J Gastroenterol* 25: 3722-3737, 2019.
13. Xu DB, Zhao ZM, Xu Y and Liu R: Hybrid pancreatoduodenectomy in laparoscopic and robotic surgery: A single-center experience in China. *Surg Endosc* 35: 1703-1712, 2021.
14. Nassour I, Paniccia A, Moser AJ and Zureikat AH: Minimally invasive techniques for pancreatic resection. *Surg Oncol Clin N Am* 30: 747-758, 2021.
15. Chalikonda S, Aguilar-Saavedra JR and Walsh RM: Laparoscopic robotic-assisted pancreaticoduodenectomy: A case-matched comparison with open resection. *Surg Endosc* 26: 2397-2402, 2012.
16. Kabir T, Tan HL, Syn NL, Wu EJ, Kam JH and Goh BKP: Outcomes of laparoscopic, robotic, and open pancreatoduodenectomy: A network meta-analysis of randomized controlled trials and propensity-score matched studies. *Surgery* 171: 476-489, 2022.



This work is licensed under a Creative Commons Attribution-NonCommercial-NoDerivatives 4.0 International (CC BY-NC-ND 4.0) License.