

Rare Presentation of Right Adrenal Mass: Extramedullary Haematopoiesis in a Patient with Thalassaemia Intermedia

Poh Shean Wong,¹ Lit Sin Yong,¹ Nor Afidah Binti Karim,¹ Ee Leng Gan,² See Guan Toh,² Noor Lita Binti Adam¹

¹Endocrinology Unit, Department of Medicine, Hospital Tuanku Ja'afar Seremban, Malaysia

²Haematology Unit, Department of Medicine, Hospital Tuanku Ja'afar Seremban, Malaysia

Abstract

Extramedullary hematopoiesis (EMH) is a rare cause of adrenal mass. We present a 44-year-old woman who has thalassaemia intermedia, referred to Endocrinology clinic for huge adrenal mass. Along with a paraspinal lesion discovered in this patient, the leading diagnosis was EMH. The patient was treated with hypertransfusion and hydroxyurea, which led to a reduction in the size of the right adrenal mass and paraspinal mass.

This case highlights the challenges in managing this rare condition. Although EMH is a rare cause of adrenal mass, the diagnosis must be considered in any patient with a history of a congenital hemolytic disorder, to avoid unnecessary surgical procedures.

Key words: adrenal mass, adrenal incidentaloma, extramedullary hematopoiesis, thalassaemia, congenital haemolytic disorder

INTRODUCTION

Thalassaemia is one of the most common autosomal recessive disorders and is highly prevalent in countries within the tropical belt, including Malaysia.^{1,2} In Malaysia, thalassaemia is the most common inherited blood disorder.³

Extramedullary hematopoiesis (EMH) is a well-documented manifestation of thalassaemia, as well as other severe disorders of hematopoiesis.⁴ The usual sites involved include the liver, spleen and paraspinal regions. The adrenal as a site of extramedullary haematopoiesis is rarely seen.⁵

Herein, we report a rare case of huge right adrenal mass in a 44-year-old woman who has inherited hemoglobinopathy.

CASE

A 44-year-old female with underlying essential hypertension since 2016, was diagnosed to have thalassaemia intermedia since 2002 at the age of 27 years old. She required infrequent blood transfusion until 2017.

Her DNA analysis of alpha and beta globin genes detected the presence of a single alpha gene deletion, together with compound heterozygous state for β^+ -thalassaemia and Siriraj $^c\gamma(^A\gamma\delta\beta)^0$ -thalassaemia. This patient has a vague abdominal mass since 2016. The ultrasound of hepatobiliary system showed a right liver lobe mass.

A computed tomography of the abdomen was performed which revealed incidental finding of a right adrenal mass. The patient was then referred to the Endocrinology clinic for further workup of the adrenal mass.

Otherwise, the patient did not have symptoms of anaemia. She did not experience excessive weight gain, easy bruising or fracture. She denied headache, palpitation, flushing, abdominal pain, tremor or anxiety. Her menses were regular with no history of menorrhagia or dysmenorrhea. She had no history of surgery. Her younger brother was diagnosed to have thalassaemia intermedia and was on regular blood transfusion. She is a housewife. She neither smokes nor drinks alcohol.

On physical examination, she had mild pallor and jaundice but no cushingoid feature. Her weight was 56.1 kg, height was 158 cm, with BMI of 22.5 kg/m². Abdominal examination revealed fullness of the abdominal right upper quadrant with large palpable firm mass, and huge splenomegaly extending inferomedially to umbilical level. Cardiovascular and respiratory examinations were unremarkable. There was no neurological deficit.

Blood investigation showed chronic microcytic hypochromic anemia with hemoglobin level of 7.6–9.9 g/dL on different occasions. Other blood parameters are shown in Table 1. Her adrenal hormone assessment was normal (Table 2).

Table 1. Initial blood investigations		
	Value	Reference value
Total bilirubin	54	5-21 µmol/L
Alanine transaminase	21	10-49 U/L
Alkaline phosphatase	52	46-116 U/L
Albumin	44	32-48 g/L
Sodium	141	136-145 mmol /L
Potassium	3.5	3.5 to 5.1 mmol /L
Creatinine	45 µmol/L	
Serum ferritin	1313.65	10-291 µg/L
Tumor marker	CA125: 5.1 CA19-9: 7.7 Alpha fetoprotein: < 1.1 CEA: 3.3	CA 125: <35 U/mL CA19-9: <37 U/mL Alpha fetoprotein: < 6.7 IU/mL CEA: <5 ug/L
TSH	2.96	0.55 to 4.78 mIU /L
Free T4	15.7	11.5-22.7 pmol/L

Table 2. Adrenal hormonal investigations		
	Value	Reference value
Cortisol	212.7	119-618 nmol/L
ACTH level	3.7	<10.2 pmol/L
Serum Dehydroepian- drosterone sulphate	<0.41	0.95-11.70 µmol/L
Testosterone level	<0.1	0.30-1.70 nmol/L
24 hour - urine catecholamine	Dopamine: 510ug/ day (mild elevation of dopamine, not diagnostic of pheochromocytoma) Epinephrine: not detected Norepinephrine: 58.8 ug/day	Dopamine: 64-400 ug/day
Overnight dexamethasone suppression test	16.8 (cortisol suppressed)	<50 nmol/L
Renin	Renin: 11.1	Renin (mU/L): Supine: 4.2 -59.7
Aldosterone	Aldosterone: <103 (Not suggestive of primary aldosteronism)	Upright: 5.3-99.1 Aldosterone (pmol/L): Supine: 102.5-858.7 Upright: 102.5-1196.6

Computed tomography (CT) of the thorax, abdomen, pelvis, including adrenal protocol done in year 2018, showed a large heterogenous enhancing mass with necrotic area arising from the right adrenal gland, measuring 11.0x9.8x14.8 cm (Figure 1), with average attenuation of 40 HU from non-contrast CT, absolute and relative washout were 24% and 12% respectively. The adrenal mass was indenting on the segment VI of the liver and right kidney, with the right kidney displaced inferiorly. The left adrenal gland was normal. The radiologist concluded that the right adrenal mass was indeterminate and in view of the patient’s history of thalassaemia, the adrenal lesion likely represented adrenal extramedullary hematopoiesis. Besides this, the paraspinal mass also noted from the CT scan was in keeping with extramedullary hematopoiesis (Figures 2 and 3).

A multidisciplinary discussion was held between endocrinologists and haematologists and they concluded that the patient was not suitable for operation owing to high bleeding risk. Subsequently, she was given hypertransfusion, with the aim of achieving a level more than 12 g/dL. Furthermore, this patient was started on iron chelating agent due to iron overload. Hydroxyurea was

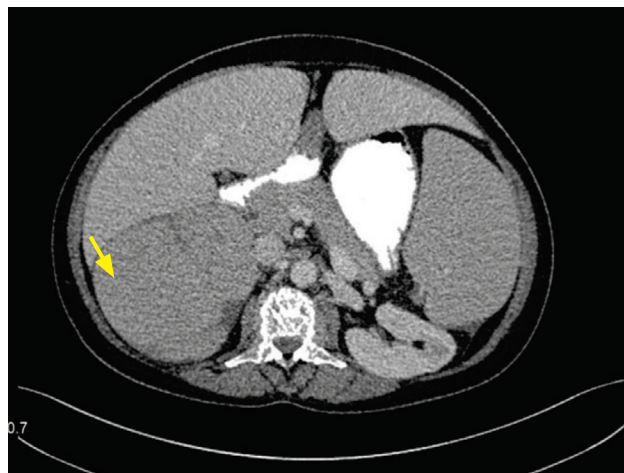


Figure 1. CT scan of the abdomen in 2018 showing large heterogenous enhancing right adrenal mass 11.0x9.8x14.8 cm (yellow arrow).

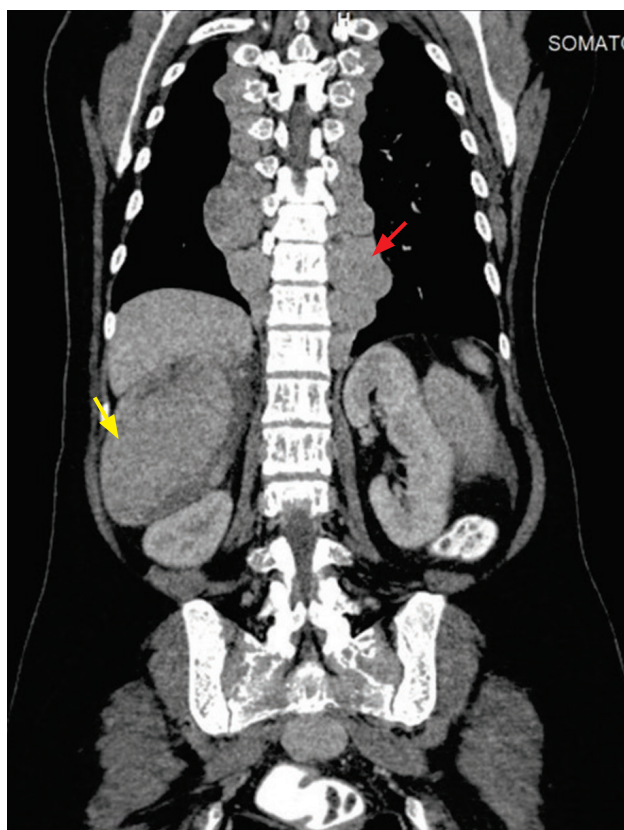


Figure 2. CT scan of thorax, abdomen, pelvis in 2018 revealing paraspinal mass (red arrow). Right kidney is displaced inferiorly by the huge right adrenal mass (yellow arrow).

commenced as part of the treatment for extramedullary haematopoiesis. Computed tomography scan of the abdomen was repeated in year 2020 and showed size reduction of the right adrenal mass and paraspinal mass (Figure 4).

DISCUSSION

The proportion of adrenal mass discovered incidentally on imaging studies was estimated to be 1–5% of all

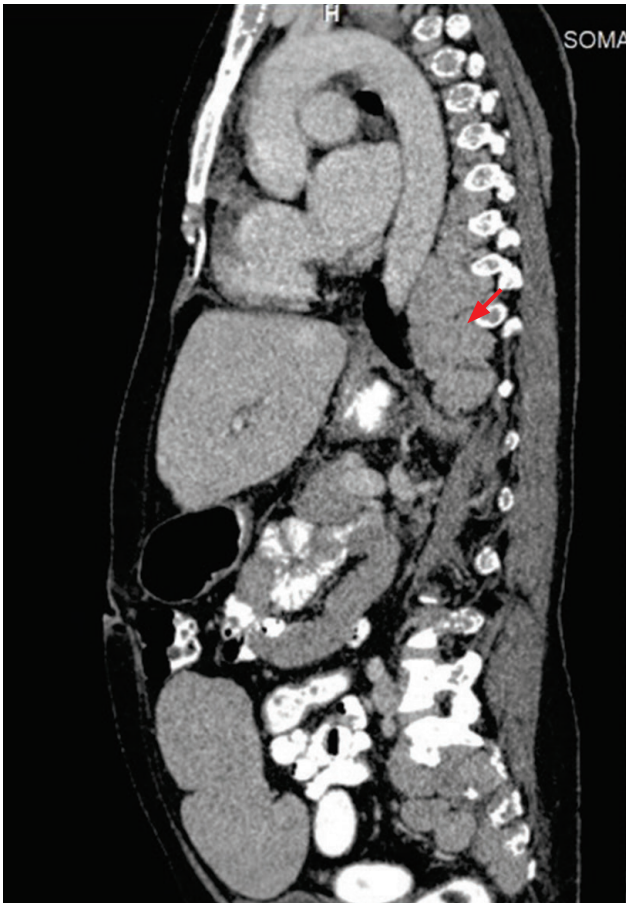


Figure 3. CT scan of thorax, abdomen, pelvis in 2018 (sagittal view) showing paraspinal mass (red arrow).

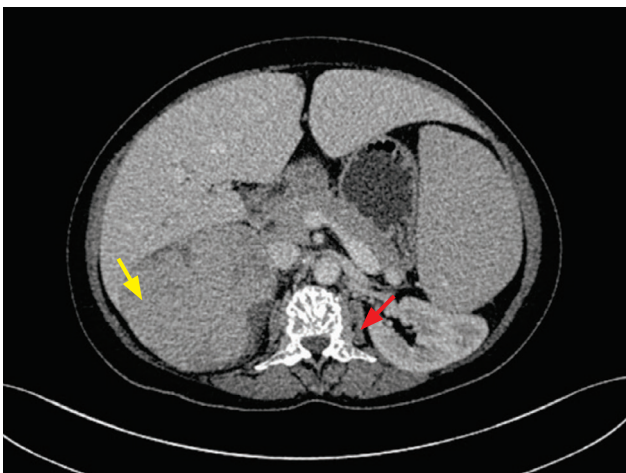

Figure 4. CT scan of the abdomen in 2020 showing size reduction of the right adrenal mass 9.8 x 8.8 x 13.2 cm (yellow arrow) and paraspinal mass (red arrow).

abdominal CT scans performed.⁶ In our case, the patient was referred to endocrinology team for an adrenal incidentaloma. Given the imaging findings of the incidental adrenal lesion and paraspinal lesion discovered in a patient with thalassaemia, the leading diagnosis is extramedullary hematopoiesis.

This patient did not have underlying primary malignancy to suggest metastatic disease as one of the differential

diagnoses. Adrenal adenoma is unlikely in this case, nor is it associated with paraspinal lesion. The adrenal lesion is huge with its attenuation of 40 HU from the non-contrast CT. Although the adrenal lesion in this patient is huge, other CT features are not suggestive of adrenocortical carcinoma, where irregular shaped, stellar central hypodensity and capsular enhancement are expected.

Extramedullary hematopoiesis (EMH) is a physiological compensatory phenomenon in response to altered hematopoiesis occurring secondary to inadequate bone marrow function. EMH in the medical literature was commonly found in the liver and spleen whereas it is rarely seen in adrenal glands, breast, dura mater, and bowel.^{5,7-9}

It often occurs in hemoglobinopathies, hemolytic anemias and myeloproliferative disorders.¹⁰

Pathological causes of EMH in the adrenal gland were described in multiple case reports, which included the defects in hemoglobin production associated with sickle-cell disease,⁹ hemoglobin H constant spring disease,¹¹ thalassaemia^{8,12-16} and impaired red blood cell membrane production linked with hereditary spherocytosis.¹⁷

The exact mechanism of EMH in the adrenal gland is unknown, but several hypotheses are suggested. The adrenal gland has hematopoietic capacity during the fetal period and EMH may develop from primitive rests in disease conditions. Other scientists believe that embolization of hematopoietic stem cells and homing in adrenal gland may occur. Chronic hypoxia is another presumptive cause of EMH.^{12,18,19}

Adrenal EMH might be clinically detected as incidentaloma, as happened in our case.¹² Adrenal incidentaloma in association with hematologic disorders, e.g., agnogenic myeloid aplasia or beta thalassaemia, needs careful imaging as well as adrenal hormonal investigations, in order to exclude malignancy and subclinical hypersecretory syndromes. Although EMH is a rare cause of an adrenal mass, the diagnosis must be considered in any patient with a history of a congenital haemolytic disorder, to avoid unnecessary surgical procedures.¹³

CT adrenal of this patient showed a large heterogenous enhancing mass with necrotic area arising from the right adrenal gland. There are no specific diagnostic findings of extramedullary haematopoiesis in imaging studies.²⁰ Adrenal EMH may appear as a homogeneous mass in ultrasonography (USG)/CT or as a heterogeneous mass with cystic change and calcification.^{8,11}

Although biopsy remains the gold standard for establishing a tissue diagnosis, it is an invasive procedure that carries the risk of catastrophic haemorrhage and is therefore not usually advocated.²¹⁻²³ The Clinical Practice Guideline of the European Society of Endocrinology recommended against the use of an adrenal biopsy in the diagnostic work-up of patients with adrenal masses unless there is history of extra-adrenal malignancy.²⁴ In this case, along with the paraspinal lesion, the leading diagnosis is extramedullary hematopoiesis. Hence, the patient's clinical details and radiological pictures are extremely crucial in diagnosis.

In our case, EMH involved the right adrenal gland. It is interesting that our literature review on EMH also reported right-side predilection, where 13 out of 17 cases of EMH involved the right adrenal gland,^{8,11-15,17,25-30} two cases involved the left adrenal gland^{6,9} and two cases involved bilateral adrenal glands.^{16,31}

A rather striking right-sided predominance was noted in a study done by Kenney et al., where 53 of 72 adrenal myelolipomas involved the right adrenal glands.³² Besides, in an analysis of adrenal myelolipoma conducted by Decmann et al., 260 tumors (59.2%) were on the right side, 111 on the left side (25.3%), while 54 tumors (12.3%) were bilateral.³³

Although speculative, a possible explanation is that asymptomatic right-sided adrenal masses are more likely to be detected incidentally, particularly at ultrasound, owing to the fact that the right adrenal region is seen clearly during ultrasound examination of the gallbladder. It is not always possible to visualize the normal adrenal glands (especially on the left side) with an ultrasound.^{34,35}

Treatment options for patients with EMH are described for thalassaemia patients and depend on the location and symptoms. Different approaches included surgery, local radiation, blood transfusion and hydroxyurea.

There are published reports of incidentally detected adrenal masses in patients with haematological disorders, where adrenalectomy was performed, resulting in the histological surprise of EMH.^{8,11,12,17,25} Surgical excision is recommended in patients who are symptomatic and resistant to other modalities.¹⁵ However, the disadvantages of the surgical intervention include risk of excessive bleeding due to the high vascularity of the mass and high incidence of recurrence.³⁶ In this case, patient is asymptomatic and hence, she was treated medically.

The medical approach involves hypertransfusion and oral hydroxyurea. Blood transfusion corrects the anaemia, and therefore the need for extramedullary haematopoiesis decreases, resulting in the relative inactivity of these tissues and their shrinkage. This is probably due to a decrease in blood flow in these tissues, rather than their actual atrophy.³⁷

Hydroxyurea is a ribonucleotide reductase enzyme inhibitor. By reducing the globin chain imbalance through stimulating synthesis of fetal hemoglobin and cytochrome reduction, hydroxyurea contributes to a decrease in ineffective erythropoiesis and the associated EMH.^{38,39} To date, there is no reported data on radiotherapy of the adrenal gland.

For paraspinal/epidural lesions, asymptomatic disease may require no specific treatment, whereas relative low dose radiation therapy is suggested in symptomatic cases because the hematopoietic tissue is notably radiosensitive and can lead to marked shrinkage of the mass and rapid neurologic improvement.⁴⁰ However, Aliberti et al., reported two thalassaemic patients with spinal cord compression due to extramedullary haematopoiesis who achieved complete regression with blood hypertransfusion therapy.⁴¹ In the case presented above, the

patient was given hypertransfusion and hydroxyurea. There was subsequent reduction in size of the right adrenal mass and paraspinal mass.

CONCLUSION

In conclusion, we presented a patient with thalassaemia intermedia who was referred due to an adrenal incidentaloma. With the background history of thalassaemia along with the presence of a paraspinal lesion, the leading diagnosis is extramedullary hematopoiesis. Although EMH is a rare cause of adrenal mass, the diagnosis must be considered in any patient with a history of a congenital hemolytic disorder, to avoid unnecessary surgical procedures.

Ethical Consideration

Patient consent was obtained before submission of the manuscript.

Statement of Authorship

All certified fulfilment of ICMJE authorship criteria.

Author Disclosure

The authors declared no conflict of interest.

Funding Source

None.

References

- Cao A, Kan YW. The prevention of thalassaemia. *Cold Spring Harb Perspect Med.* 2013;3(2):a011775. PMID: 23378598. PMCID: PMC3552345. <https://doi.org/10.1101/cshperspect.a011775>.
- Weatherall DJ. The evolving spectrum of the epidemiology of thalassaemia. *Hematol Oncol Clin North Am.* 2018;32(2):165-75. PMID: 29458724. <https://doi.org/10.1016/j.hoc.2017.11.008>.
- Ibrahim HM, Muda Z, Othman IS, et al. Observational study on the current status of thalassaemia in Malaysia: A report from the Malaysian Thalassaemia Registry. *BMJ Open.* 2020;10(6):e037974. PMID: 32601117. PMCID: PMC7328811. <https://doi.org/10.1136/bmjopen-2020-037974>.
- Rivella S. The role of ineffective erythropoiesis in non-transfusion-dependent thalassaemia. *Blood Rev.* 2012;26 Suppl 1(0 1):S12-5. PMID: 22631035. PMCID: PMC3697110. [https://doi.org/10.1016/S0268-960X\(12\)70005-X](https://doi.org/10.1016/S0268-960X(12)70005-X).
- Sohawon D, Lau KK, Lau T, Bowden DK. Extra-medullary haematopoiesis: A pictorial review of its typical and atypical locations. *J Med Imaging Radiat Oncol.* 2012;56(5):538-44. PMID: 23043573. <https://doi.org/10.1111/j.1754-9485.2012.02397.x>.
- Arkadopoulos N, Kyriazi M, Yiallourou AI, et al. A rare coexistence of adrenal cavernous hemangioma with extramedullary hemopoietic tissue: A case report and brief review of the literature. *World J Surg Oncol.* 2009;7:13. PMID: 19193247. PMCID: PMC2647540. <https://doi.org/10.1186/1477-7819-7-13>.
- Boucher A, Puech P, Kharroubi D, et al. Renal extramedullary hematopoietic tumor revealing a hereditary spherocytosis in an adult patient. *Rev Med Interne.* 2015;36(12):848-53. PMID: 25795467. <https://doi.org/10.1016/j.revmed.2015.02.007>.
- Karami H, Kosaryan M, Taghipour M, Sharifian R, Aliasgharian A, Motalebi M. Extramedullary hematopoiesis presenting as a right adrenal mass in a patient with beta thalassaemia. *Nephrourol Mon.* 2014;6(5):e19465. PMID: 25695031. PMCID: PMC4318012. <https://doi.org/10.5812/numonthly.19465>.
- Azarpira N, Esfahani MH, Paydar S. Extramedullary hematopoiesis in adrenal gland. An uncommon cause of adrenal incidentaloma in sickle cell disease. *Iran J Pediatr.* 2014;24(6):784-6. PMID: 26019789. PMCID: PMC4442845.
- Castelli R, Graziadei G, Karimi M, Cappellini MD. Intrathoracic masses due to extramedullary hematopoiesis. *Am J Med Sci.* 2004;328(5):299-303. PMID: 15545849. <https://doi.org/10.1097/00000441-200411000-00012>.
- Lau HY, Lui DC, Ma JKF, Wong RWC. Sonographic features of adrenal extramedullary hematopoiesis. *J Ultrasound Med* 2011;30(5):706-13. PMID: 21527620. <https://doi.org/10.7863/jum.2011.30.5.706>.
- Porcaro AB, Novella G, Antonioli SZ, et al. Adrenal extramedullary hematopoiesis: Report on a pediatric case and update of the literature. *Int Urol Nephrol.* 2001;33(4):601-3. PMID: 12452605. <https://doi.org/10.1023/a:1020578501167>.

13. Chuang CK, Chu SH, Fang JT, Wu JH. Adrenal extramedullary hematopoietic tumor in a patient with beta-thalassemia. *J Formos Med Assoc.* 1998;97(6):431-3. PMID: 9650475.
14. Papavasiliou C, Gouliamos A, Deligiorgi E, Vlahos L, Cambouris T. Masses of myeloid adipose tissue: Radiological and clinical considerations. *Int J Radiat Oncol Biol Phys.* 1990;19(4):985-93. PMID: 2211267. [https://doi.org/10.1016/0360-3016\(90\)90023-d](https://doi.org/10.1016/0360-3016(90)90023-d).
15. Keikhaei B, Shirazi AS, Pour MM. Adrenal extramedullary hematopoiesis associated with β -thalassemia major. *Hematol Rep.* 2012;4(2):e7. PMID: 22826797. PMID: PMC3401136. <https://doi.org/10.4081/hr.2012.e7>.
16. Wat NM, Tse KK, Chan FL, Lam KS. Adrenal extramedullary haemopoiesis: Diagnosis by a non-invasive method. *Br J Haematol.* 1998;100(4):725-7. PMID: 9531340. <https://doi.org/10.1046/j.1365-2141.1998.00619.x>.
17. Calhoun SK, Murphy RC, Shariati N, Jacir N, Bergman K. Extramedullary hematopoiesis in a child with hereditary spherocytosis: An uncommon cause of an adrenal mass. *Pediatr Radiol.* 2001;31(12):879-81. PMID: 11727025. <https://doi.org/10.1007/s002470100011>.
18. Bastounis EA, Karayiannakis AJ, Anapliotou ML, Nakopoulou L, Makri GG, Papalambros EL. Incidentalomas of the adrenal gland: Diagnostic and therapeutic implications. *Am Surg.* 1997;63(4):356-60. PMID: 9124759.
19. Asnani M, Char G, Reid M, Nanton PM. Intrathoracic and pelvic extramedullary hematopoiesis in sickle cell disease: A case report. *West Indian Med J.* 2007;56(6):540-3. PMID: 18646500.
20. Orphanidou-Vlachou E, Tziakouri-Shiakalli C, Georgiades CS. Extramedullary hemopoiesis. *Semin Ultrasound CT MR.* 2014;35(3):255-62. PMID: 24929265. <https://doi.org/10.1053/j.sult.2013.12.001>.
21. De Klippel N, Dehou MF, Bourgain C, Schots R, De Keyser J, Ebinger G. Progressive paraparesis due to thoracic extra-medullary hematopoiesis in myelofibrosis. Case report. *J Neurosurg.* 1993;79(1):125-7. PMID: 8315451. <https://doi.org/10.3171/jns.1993.79.1.0125>.
22. Cone SM. Bone marrow occurring in intercostal veins. *JAMA* 1925; 84: 1732-3.
23. Oustwani MB, Kurtides ES, Christ M, Ciric I. Spinal cord compression with paraplegia in myelofibrosis. *Arch Neurol.* 1980;37(6):389-90. PMID: 7387474. <https://doi.org/10.1001/archneur.1980.00500550091019>.
24. Fassnacht M, Arlt W, Bancos I, et al. Management of adrenal incidentaloma: European Society of Endocrinology Clinical Practice Guideline in collaboration with the European Network for the Study of Adrenal Tumors. *Eur Journal of Endocrinol.* 2016;175(2):G1-34. PMID: 27390021. <https://doi.org/10.1530/EJE-16-0467>.
25. Banerji JS, Kumar RM, Devasia A. Extramedullary hematopoiesis in the adrenal: Case report and review of literature. *Can Urol Assoc J.* 2013;7(5-6):e436-8. PMID: 23826059. PMID: PMC3699094. <https://doi.org/10.5489/auaj.1389>.
26. Al-Thani H, Al-Sulaiti M, El-Mabrok G, Tabeb A, El-Menyar A. Adrenal extramedullary haematopoiesis associated with beta-thalassaemia trait in an adult woman: A case report and review of literature. *Int J Surg Case Rep.* 2016;24:83-7. PMID: 27232291. PMID: PMC4885136. <https://doi.org/10.1016/j.ijscr.2016.05.024>.
27. Tanner J, Malhotra S., El-Daly H., Godfrey E.M. Case 243: Extra-medullary hematopoiesis in an adrenal myelolipoma. *Radiology* 2017;284(1):292-6. PMID: 28628416. <https://doi.org/10.1148/radiol.2017142993>.
28. Kolev NH, Genov PP, Dunev VR, Stoykov BA. A rare case of extramedullary hematopoiesis in adrenal mass. *Urol Case Rep.* 2020;30:101120. PMID: 32055448. PMID: PMC7005413. <https://doi.org/10.1016/j.eucr.2020.101120>.
29. Kannan S, Kulkarni P, Lakshmikantha A, Gadabanahalli K. Extramedullary haematopoiesis presenting as an adrenal mass. *J Clin Diagn Res.* 2017;11(3):TJ01. PMID: 28511479. PMID: PMC5427405. <https://doi.org/10.7860/JCDR/2017/25086.9448>.
30. Sekar S, Burad D, Abraham A, Paul MJ. Adrenal incidentaloma caused by extramedullary haematopoiesis: conservative management is optimal. *BMJ Case Rep.* 2015;2015:bcr.2015211014. PMID: 26392447. PMID: PMC4577657. <https://doi.org/10.1136/bcr-2015-211014>.
31. King BF, Kopecky KK, Baker MK, Clark SA. Extramedullary hematopoiesis in the adrenal glands: CT characteristics. *J Comput Assist Tomogr.* 1987;11(2):342-3. PMID: 3819139. <https://doi.org/10.1097/00004728-198703000-00030>.
32. Kenney PJ, Wagner BJ, Rao P, Heffess CS. Myelolipoma: CT and pathologic features. *Radiology.* 1998;208(1):87-95. PMID: 9646797. <https://doi.org/10.1148/radiology.208.1.9646797>.
33. Decmann Á, Perge P, Tóth M, Igaz P. Adrenal myelolipoma: A comprehensive review. *Endocrine.* 2018;59(1):7-15. PMID: 29164520. <https://doi.org/10.1007/s12020-017-1473-4>.
34. Günther RW, Kelbel C, Lenner V. Real-time ultrasound of normal adrenal glands and small tumors. *J Clin Ultrasound.* 1984;12(4):211-7. PMID: 6427284. <https://doi.org/10.1002/jcu.1870120408>.
35. Dietrich CF, Wehrmann T, Hoffmann C, Herrmann G, Caspary WF, Seifert H. Detection of the adrenal glands by endoscopic or transabdominal ultrasound. *Endoscopy.* 1997;29(9):859-64. PMID: 9476771. <https://doi.org/10.1055/s-2007-1004322>.
36. Habibzadeh F, Yadollahie M, Haghshenas M. Extramedullary haematopoiesis in beta-thalassaemia. *J Postgrad Med.* 2005;51(1):45-6. PMID: 15793340.
37. Parsa K, Oreizy A. Nonsurgical approach to paraparesis due to extramedullary hematopoiesis: Report of two cases. *J Neurosurg.* 1995;82(4):657-60. PMID: 7897533. <https://doi.org/10.3171/jns.1995.82.4.0657>.
38. Cianciulli P, di Toritto TC, Sorrentino F, Sergiacomi L, Massa A, Amadori S. Hydroxyurea therapy in paraparesis and cauda equina syndrome due to extramedullary haematopoiesis in thalassaemia: Improvement of clinical and haematological parameters. *Eur J Haematol.* 2000;64(6):426-9. PMID: 10901597. <https://doi.org/10.1034/j.1600-0609.2000.9c165.x>.
39. Cario H, Wegener M, Debatin KM, Kohne E. Treatment with hydroxyurea in thalassaemia intermedia with paravertebral pseudotumors of extramedullary hematopoiesis. *Ann Hematol.* 2002;81(8):478-82. PMID: 12224008. <https://doi.org/10.1007/s00277-002-0501-4>.
40. Dore F, Pardini S, Gaviano E, et al. Recurrence of spinal cord compression from extramedullary hematopoiesis in thalassaemia intermedia treated with low doses of radiotherapy. *Am J Hematol.* 1993;44(2):148. PMID: 8266922. <https://doi.org/10.1002/ajh.2830440216>.
41. Aliberti B, Patrikiou A, Terentiu A, Frangatos S & Papadimitrou A. Spinal cord compression due to extramedullary hematopoiesis in two patients with thalassaemia: Complete regression with blood transfusion therapy. *J Neurol.* 2001;248(1):18- 22. PMID: 11266014. <https://doi.org/10.1007/s004150170264>.

Authors are required to accomplish, sign and submit scanned copies of the JAFES Author Form consisting of: (1) Authorship Certification, that authors contributed substantially to the work, that the manuscript has been read and approved by all authors, and that the requirements for authorship have been met by each author; (2) the Author Declaration, that the article represents original material that is not being considered for publication or has not been published or accepted for publication elsewhere, that the article does not infringe or violate any copyrights or intellectual property rights, and that no references have been made to predatory/suspected predatory journals; (3) the Author Contribution Disclosure, which lists the specific contributions of authors; (4) the Author Publishing Agreement which retains author copyright, grants publishing and distribution rights to JAFES, and allows JAFES to apply and enforce an Attribution-Non-Commercial Creative Commons user license; and (5) the Conversion to Visual Abstracts (*optional for original articles only) to improve dissemination to practitioners and lay readers. Authors are also required to accomplish, sign, and submit the signed ICMJE form for Disclosure of Potential Conflicts of Interest. For original articles, authors are required to submit a scanned copy of the Ethics Review Approval of their research as well as registration in trial registries as appropriate. For manuscripts reporting data from studies involving animals, authors are required to submit a scanned copy of the Institutional Animal Care and Use Committee approval. For Case Reports or Series, and Images in Endocrinology, consent forms, are required for the publication of information about patients; otherwise, appropriate ethical clearance has been obtained from the institutional review board. Articles and any other material published in the JAFES represent the work of the author(s) and should not be construed to reflect the opinions of the Editors or the Publisher.