

Lymphangiography as a Treatment for Refractory Congenital Chylothorax Due to RASopathies: A Report of Two Cases

1) Department of Radiology, Hyogo College of Medicine, Japan

2) Department of Radiology, Ashiya Municipal Hospital, Japan

3) Department of Radiology, Shimane University, Japan

4) Department of Pediatrics, Hyogo College of Medicine, Japan

Naoya Kinota¹⁾, Hiroshi Kodama²⁾, Taiki Moriyama¹⁾, Junichi Taniguchi¹⁾, Mitsunari Maruyama³⁾,
Atsushi Ogasawara¹⁾, Yasukazu Kako¹⁾, Kaoru Kobayashi¹⁾, Haruyuki Takaki¹⁾, Akio Shibata⁴⁾,
Kyoko Minagawa⁴⁾, Yasuhiro Takeshima⁴⁾, Koichiro Yamakado¹⁾

Abstract

In this study, we report two cases in which intranodal lymphangiography helped improve congenital chylothorax due to RASopathies. We performed lymphangiography after conservative treatments failed to improve chylothorax in an 8-year-old girl with cardiofaciocutaneous syndrome and a 2-month-old boy with Noonan syndrome. Inguinal lymph nodes were punctured with 25-gauge needles under ultrasonographic guidance, and 4 and 1 mL of iodized oil were injected, respectively, showing a backflow of iodized oil into the lungs. Chylothorax had improved in both patients after nodal lymphangiography. However, the second child experienced worsening of disease-associated extremity edema and died of sepsis 4 months later.

Key words: Lymphangiography, Rasopathies, Pediatrics, Chylothorax, Chyle leak

(Interventional Radiology 2022; 7: 17-20)

Introduction

RASopathies are a group of syndromes caused by mutations in genes related to the Ras/mitogen-activated protein kinase pathway. This group of disorders includes Noonan syndrome, cardiofaciocutaneous syndrome, Costello syndrome, neurofibromatosis type 1, and Legius syndrome [1].

Although chylothorax is less commonly associated with RASopathies, it can be a life-threatening condition [2, 3]. Conservative and/or surgical treatments, including diet therapy, total parenteral nutrition, octreotide administration, fluid drainage, pleural pleurodesis, and thoracic duct ligation, are usually applied but are not always successful in controlling the chylothorax [4].

Lymphangiography has been used for diagnosing lymphatic disease and as a treatment for many types of lymphorrhea.

It is useful in controlling traumatic or postsurgical chylothorax [5, 6]. We encountered two children with RASopathies who suffered from refractory chylothorax despite conservative treatment.

Herein, we present the results of using lymphangiography as a treatment for refractory chylothorax in two children with RASopathy.

Case Reports

Lymphangiography

The inguinal lymph nodes were punctured using 25-gauge needles under ultrasonographic guidance under general anesthesia. Iodized oil (Lipiodol, Guerbet Japan, Tokyo, Japan) was injected using a syringe pump (Terufusion syringe pump; Terumo, Tokyo, Japan) at an injection rate of 0.2 mL/

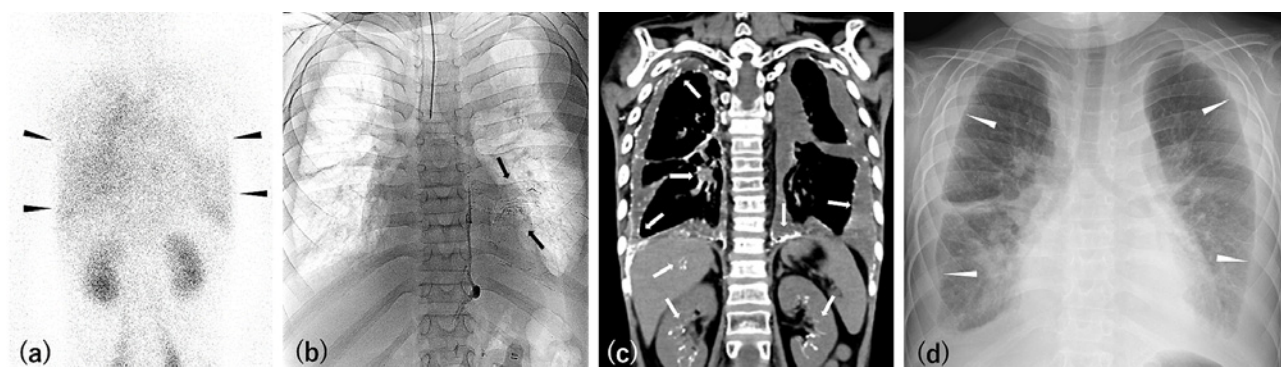


Figure 1. (a) A lymphoscintigraphy at 3 h post subcutaneous injection of technetium-99m diethylenetriaminepentaacetic acid human serum albumin showed abnormal uptake in the chest, implying pulmonary lymphatic backflow (black arrowheads). (b) A fluoroscopic image captured during lymphangiography, showing abnormal ionized oil flow to the left intrapulmonary lymphatics (black arrows). Bilateral pleural effusion is also observed. (c) A computed tomographic (CT) image captured after lymphangiography, showing ionized oil deposition in visceral pleural, peribronchovascular, renal hilar, and intrahepatic lymphatics (white arrows). (d) A chest radiograph taken 4 months after the lymphangiography, showing a decrease in the pleural effusion (white arrowheads).

min. Lymphangiography by fluoroscopy was performed, and computed tomography (CT) was performed just after the procedure and on the next day to evaluate the lymphatic anatomy and lymphatic leakage point.

Case 1

An 8-year-old girl with cardiofaciocutaneous syndrome (*KRAS* point mutation, Gly60Arg) was referred to our department to treat congenital bilateral chylothorax. Hypertrophic cardiomyopathy, craniosynostosis, mental retardation, and difficulty in swallowing were also observed. Conservative treatment, including a fat-restricted diet, octreotide, corticosteroid administration, and pleural pleurodesis with minocycline, was started, but the chylothorax gradually worsened, requiring repeated drainage. The last bilateral chest tube insertion was performed at the age of 7 years, approximately 1 year prior. The chylous drainage at the time of tube insertion was 900 mL in total, and the daily drainage was <100 mL, enabling tube removal within 2 weeks. After the tube removal, a gradual increase of pleural effusion was observed. A lymphoscintigraphy using technetium-99m diethylenetriaminepentaacetic acid human serum albumin showed abnormal uptake in the chest (**Fig. 1a**).

Intranodal lymphangiography was performed by puncturing the bilateral inguinal nodes and injecting 4 mL of ionized oil in total (0.25 mL/kg). Fluoroscopy and CT images showed reflux of iodized oil into the pleural, peribronchovascular, chest wall, renal hilar, and intrahepatic lymphatics (**Fig. 1b and c**).

The chylothorax had decreased after the lymphangiography. Although a low level of chylothorax remained, no further treatments were required during the 2.5 years of follow-up (**Fig. 1d**).

Case 2

A 2-month-old boy with Noonan syndrome (*RAF1* point mutation, Ser259Pro) was cared for under intubation because severe neonatal asphyxia and plastic bronchitis were associated with the syndrome. Lymphatic malformations of the neck, hypertrophic cardiomyopathy, pulmonary hypertension, extremity edema, and ascites were also observed. Total parenteral nutrition and octreotide administration were attempted to control chylothorax, but both were unsuccessful and continuous chest drainage was required. The total daily drainage remained between 100 and 200 mL.

Intranodal lymphangiography was performed to control for bilateral chylothorax. We injected 1 mL of iodized oil via the left inguinal node. Imaging indicated iodized oil reflux to bilateral peribronchovascular, mesenteric, retroperitoneal, and left abdominal wall lymphatics (**Fig. 2a and b**).

The chylothorax had decreased after lymphangiography, and chest tubes were removed 14 days later (**Fig. 2c**). However, plastic bronchitis did not improve and the extremity edema was exacerbated, requiring periodic percutaneous subcutaneous drainage. The infant died of sepsis 4 months after the lymphangiography. Any specific bacteria or infection site was not identified, but the surgical procedure of tracheotomy, long-term central venous catheter placement, or frequent percutaneous drainage for subcutaneous edema was considered to be the cause of sepsis.

Discussion

Through these two cases, we show that lymphangiography is effective in controlling congenital chylothorax due to RASopathies. The therapeutic effect mechanism is not fully understood, but inflammatory and granulomatous reactions and ionized oil embolization effects were suggested [6]. In a

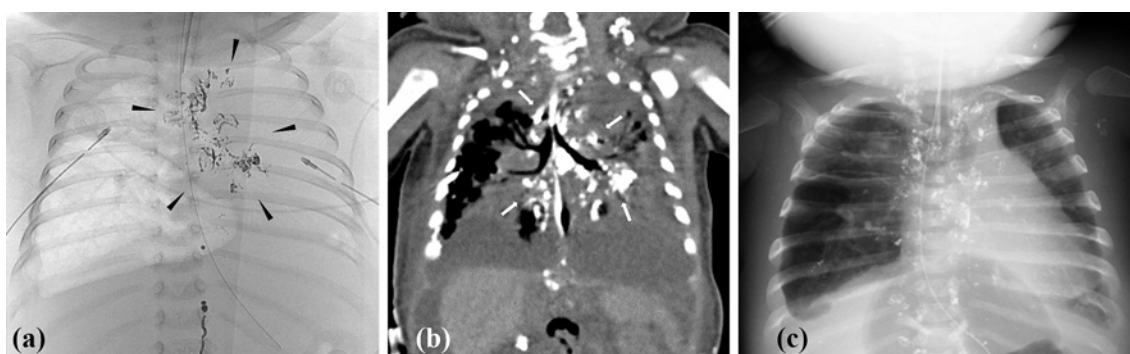


Figure 2. (a) A fluoroscopic image captured during lymphangiography, showing backflow of ionized oil into the left peribronchovascular lymphatics (black arrowheads). The air content of the left lung was reduced. (b) A CT image captured after the lymphangiographic procedure, showing ionized oil deposition in the bilateral peribronchovascular lymphatics (white arrows). (c) A chest radiograph taken 1 month after the lymphangiography procedure, showing the resolution of the pleural effusion. Chest drainage tubes had been removed before this stage. Ionized oil deposition in the mediastinal and left axillary lymph nodes was also observed.

meta-analysis, the technical and clinical success rates of intranodal lymphangiography for nontraumatic chylothorax were reported to be 92% and 41%, respectively [5]. Chyle leakage in patients with congenital chylothorax is reportedly caused by the abnormal formation of the systematic lymphatic system [7, 8]. Iodized oil flows to the leaking point, where it could stop the leakage from the abnormal lymphatic system, even in RASopathy patients.

Another therapeutic option is thoracic duct embolization (TDE), which has technical and clinical success rates of 71% and 50%, respectively, in nontraumatic chylothorax [5]. Although TDE is technically challenging, it is an alternative in case lymphangiography fails to control the chylothorax [7, 8].

When TDE is difficult to perform, thoracic duct disruption (TDD) can be an alternative treatment option. The clinical success rate of TDD is reported to be approximately 60% [5].

For congenital chylothorax, it is not well established what kind of lymphatic intervention will be required in certain situations. As congenital chylothorax tends to follow a chronic course, lymphangiography alone as the least invasive treatment might be reasonable as the initial intervention when the amount of leakage is relatively small. Repeated lymphangiography or advanced intervention can be considered when initial lymphangiography does not improve the situation. When the amount of leakage is large (i.e., >1000 mL/day), TDE or TDD can be considered the initial intervention as the lymphangiography alone has been reported to have an insufficient therapeutic effect for a large amount of chylous leakage [9].

When a patient has broad pulmonary lymphatic backflow, the so-called pulmonary lymphatic perfusion syndrome (PLPS), the situation changes. The embolization of the thoracic duct, not the visceral lymphatics, will be required to treat PLPS, and TDE or TDD becomes the initial intervention [7, 8]. In case 2, we did not perform any other addi-

tional interventions on the basis of the multidisciplinary discussion because the patient suffered from subcutaneous edema in extremities that needed frequent percutaneous drainage after the lymphangiography. Consequently, control of chylothorax was achieved, but the plastic bronchitis was prolonged. Even if TDE was challenging, the addition of TDD might have improved his plastic bronchitis.

It is still not clear which children with congenital chylothorax will benefit from lymphatic interventions. In Noonan syndrome, patients with complex lymphatic abnormalities in multiple organs had an inadequate response to intervention and a poor prognosis, whereas those with localized lymphatic abnormalities in the chest responded well to intervention [10]. There is also a report about successfully treating localized lymphorrhea with lymphatic embolization in a child with Noonan syndrome [11]; hence, children with congenital lymphatic abnormalities in a limited area will be a good candidate for intervention. In contrast, the indication of intervention for those with broad lymphatic abnormality in multiple organs should be determined carefully, considering their comorbidities and prognosis.

In conclusion, we note that the procedure improves chylothorax in children with RASopathies.

The cases were presented at Kansai IVR workshop in February 2019.

Conflict of Interest: None

Disclaimer: Haruyuki Takaki is one of the Senior Editors of *Interventional Radiology* and on the journal's Editorial Board. He was not involved in the editorial evaluation or decision to accept this article for publication at all.

References

1. Simanshu DK, Nissley DV, McCormick F. RAS proteins and their regulators in human disease. *Cell* 2017; 170: 17-33.
2. Ebrahimi-Fakhari D, Freiman E, Wojcik MH, et al. Congenital

- chylothorax as the initial presentation of PTPN11-associated Noonan syndrome. *J Pediatr* 2017; 185: 248.
3. Bulow L, Lissewski C, Bressel R, et al. Hydrops, fetal pleural effusions and chylothorax in three patients with CBL mutations. *Am J Med Genet A* 2015; 167: 394-399.
 4. Bellini C, Cabano R, De Angelis LC, et al. Octreotide for congenital and acquired chylothorax in newborns: a systematic review. *J Paediatr Child Health* 2018; 54: 840-847.
 5. Kim PH, Tsao J, Shin JH. Lymphatic interventions for chylothorax: a systematic review and meta-analysis. *J Vasc Interv Radiol* 2018; 29: 194-202.
 6. Matsumoto T, Yamagami T, Kato T, et al. The effectiveness of lymphangiography as a treatment method for various chyle leakages. *Br J Radiol* 2009; 82: 286-290.
 7. Nadolski G. Nontraumatic chylothorax: diagnostic algorithm and treatment options. *Tech Vasc Interv Radiol* 2016; 19: 286-290.
 8. Itkin M. Interventional treatment of pulmonary lymphatic anomalies. *Tech Vasc Interv Radiol* 2016; 19: 299-304.
 9. Alexandre-Lafont E, Krompiec C, Rau WS, Krombach GA. Effectiveness of therapeutic lymphography on lymphatic leakage. *Acta Radiol* 2011; 52: 305-311.
 10. Biko DM, Reisen B, Otero HJ, et al. Imaging of central lymphatic abnormalities in Noonan syndrome. *Pediatr Radiol* 2019; 49: 586-592.
 11. Yamamoto M, Kondo H, Shigeru F, et al. Intranodal lymphatic embolization for chylocolporrhea caused by chylous reflux syndrome in Noonan syndrome. *J Vasc Interv Radiol* 2019; 30: 769-772.

Interventional Radiology is an Open Access journal distributed under the Creative Commons Attribution-NonCommercial 4.0 International License. To view the details of this license, please visit (<https://creativecommons.org/licenses/by-nc/4.0/>).