

Insufficient Augmentation of Bone Cement Causes Recompression of Augmented Vertebra after Balloon Kyphoplasty

Motoya Kobayashi^{1,2)}, Yasumitsu Toribatake¹⁾, Shunpei Okamoto¹⁾, Satoshi Kato²⁾ and Hiroyuki Tsuchiya²⁾

1) Department of Orthopaedic Surgery, JA Toyama Kouseiren Takaoka Hospital, Takaoka, Japan

2) Department of Orthopaedic Surgery, Kanazawa University School of Medicine, Kanazawa, Japan

Abstract:

Introduction: Balloon kyphoplasty (BKP) is one of the most frequently used clinical methods to relieve pain caused by osteoporotic vertebral compression fracture (OVCF); it can effectively improve the body height of the vertebra. However, recompression of the augmented vertebra (RAV) is often observed after BKP. This study aimed to report factors that are associated with RAV in terms of cement augmentation.

Methods: A total of 78 patients (women, 60; men, 18) were included in this study. RAV was defined as anterior vertebral height loss (VHL), between immediate postoperation and 3 or 6 months after BKP, of more than 5.0 mm. Cement augmentation ratio (CAR) was calculated as the ratio of the maximal height of polymethylmethacrylate (PMMA) to the maximal distance between both end plates. Age, gender, fracture age, CAR, presence of medication for osteoporosis, intervertebral cleft (IVC), and cement leakage were evaluated using Fisher's exact test or Mann-Whitney U test to compare between RAV and non-RAV groups. Aforementioned variables were also analyzed using multiple logistic regression test. A $P < 0.05$ was considered statistically significant.

Results: The incidence rates for RAV at 3 and 6 months were 35.9% (28/78) and 38.5% (30/78), respectively. Age (80.1 vs 74.7) was significantly higher in the RAV group, whereas CAR (69.4% vs 77.6%) was lower in the non-RAV group. A multivariate regression analysis revealed that age (odds ratio (OR)=1.12, $P=0.001$) and CAR (OR=0.91, $P=0.001$) were independently associated with RAV.

Conclusions: RAV was observed in 38.5% of patients in this study. Older age and low CAR were independently associated with RAV. To prevent RAV, especially in the elderly, augmented PMMA should come in contact with both end plates.

Keywords:

balloon kyphoplasty, recompression, osteoporotic vertebral compression fracture, augmented vertebra, cement, PMMA

Spine Surg Relat Res 2021; 5(6): 375-380

dx.doi.org/10.22603/ssrr.2020-0019

Introduction

Osteoporotic vertebral compression fracture (OVCF) is one of the most common complications of osteoporosis in the elderly population¹⁾ and has a significant negative impact on the quality of life of patients. In Japan, the percentage of elderly individuals (age ≥ 65 years) in the population reached 25% in 2013; it is expected to exceed 30% by 2025²⁾. In 2008, the incidence of painful OVCF was estimated to be 880,000, and approximately 40% of patients with painful OVCF are hospitalized owing to pain severity^{3,4)}.

Because pain from acute fractures usually lasts 4-8 weeks⁵⁾, conservative medical therapy is employed in most

OVCF cases. However, traditional conservative treatments for elderly patients with OVCF are associated with high mortality⁶⁾. In addition, progressive vertebral collapse or insufficient union following conservative treatment can trigger continuous back pain or delayed neurologic complications⁷⁻⁹⁾.

Percutaneous vertebroplasty (PVP) is one of the most frequently used clinical methods in relieving pain caused by OVCF¹⁰⁻¹³⁾. In addition, balloon kyphoplasty (BKP), which was derived from PVP, can effectively improve the body height of the vertebra and is well documented in surgical literature¹⁴⁻¹⁸⁾. Vertebral augmentation leads to an instantaneous recovery of stability and strength; thus, it prevents continuous micromotion and further collapse.

Corresponding author: Motoya Kobayashi, kobamoto1220@gmail.com

Received: February 28, 2020, Accepted: December 26, 2020, Advance Publication: February 9, 2021

Copyright © 2021 The Japanese Society for Spine Surgery and Related Research

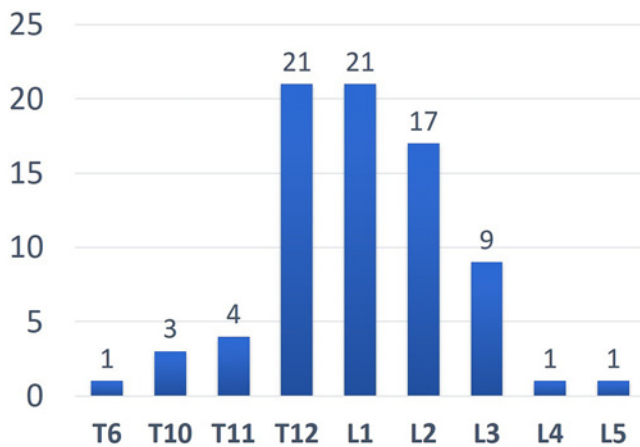


Figure 1. Vertebral body distribution treated by BKP.

However, during patients' follow-up, recompression of the augmented vertebra (RAV) with significant loss of vertebral height and aggravation of local kyphotic deformity was observed after BKP. Although a few studies discuss about recompression after successful BKP¹⁹⁻²²⁾, the risk factor related to recompression and the clinical significance of recompression remain vague. In our cases after BKP, recompression mainly occurred at the polymethylmethacrylate (PMMA)-unsupported portion of the vertebral body. Hence, we hypothesized that these residual unfilled spaces within the vertebrae may lead to recompression during the follow-up periods if the vertebrae are inadequately filled. The present study aimed to report factors that correlated with RAV after BKP in terms of cement augmentation.

Materials and Methods

This study was approved by institutional review board. To rule out bias in the selection of patients and extravertebral effects, the inclusion criteria included the following: (1) single-level OVCF diagnosed by plain radiography and magnetic resonance imaging, (2) patients suffering severe fracture pain with failure of adequate conservative treatment, (3) treatment with single-level BKP via bilateral portals, (4) follow-up period of at least 6 months, and (5) no additional history of trauma after surgery. The exclusion criteria were as follows: (1) non-OVCF, including fractures related to malignancy or infection; (2) patients with hyperparathyroidism, hyperthyroidism, pituitary adenoma, hypercortisolism, or other bone metabolic disease; (3) life-threatening systemic disease such as malignancy, systemic infection, or serious disorder of a vital organ; and (4) patients whom we could not collect complete medical record or radiographic data.

Overall, this study retrospectively reviewed 122 patients receiving BKP from January 2011 to October 2014 in our single institution. After excluding 44 patients, data from 78 eligible patients (women, 60; men, 18) were analyzed. The average age was 76.8 years (range, 59-89 years). The average duration between the time of injury and surgery (fracture age) was 60.7 days. Vertebral bodies treated by BKP

were distributed between the T6 and L5 levels, which were most prevalent in the thoracolumbar junction (Fig. 1).

The BKP was performed using specialized instruments (Kyphon[®], Medtronic, Minneapolis, MN, USA) and PMMA cement via bilateral portals under general anesthesia according to routine procedures. The use of a tailor-made soft corset was prescribed for all patients after surgery for 2-3 months. Osteoporotic medications, including bisphosphonates, vitamin D, teriparatide, or raloxifene, were post-operatively used.

Each augmented vertebra was sequentially measured for its height of anterior vertebra (HA). HA was defined as the distance between the upper and lower end plates at the anterior vertebra. Data were obtained from lateral radiographs and analyzed at four different time points: preoperative, immediate postoperative, 3 months after the procedure, and 6 months after the procedure. A lateral radiograph was taken in prone position at immediate postoperation, in standing position at preoperation, and 3 and 6 months after the procedure. The vertebral height loss (VHL), which indicated RAV, was then calculated as the difference of HA between immediate postoperation and 3 or 6 months after the procedure. RAV was defined as VHL of more than 5.0 mm (Fig. 2). Moreover, as an indicator of cement augmentation, we defined a cement augmentation ratio (CAR) that was calculated as the ratio of the maximal height of PMMA to the maximal distance between the upper and lower end plates in immediate postoperative radiograph (Fig. 3). The presence of intervertebral cleft (IVC), cement leakage, and reoperation was also checked after the BKP procedure. An IVC was defined as an abnormal linear or cystic lucent region on preoperative lateral radiographs or an intravertebral fluid-/gas-filled transverse zone on preoperative CT scans. Cement leakage was evaluated using immediate postoperative front and lateral radiographs. To investigate the risk factor of RAV, clinical data, such as age, gender, fracture age, presence of medication for osteoporosis, presence of IVC, CAR and presence of cement leakage, were evaluated using chi-square test or Fisher's exact test to compare between the two patient groups (RAV and non-RAV). Descriptive statistics were expressed as mean±standard deviation for continuous variables and as percentages for categorical variables. The mean age, fracture age and CAR between the two groups were analyzed using Mann-Whitney U test. Regardless of their statistical significance, the abovementioned variables were included in the multivariate analysis. Odds ratios (ORs) for RAV and their 95% confidence intervals were calculated using multiple logistic regression test and backward selection. A $P < 0.05$ was considered statistically significant. The SPSS 23.0 statistical software (SPSS, Inc., Chicago, IL) was used for the analysis.

Results

The incidence rates for RAV at 3 and 6 months after the BKP procedure were 35.9% (28/78) and 38.5%, respectively.

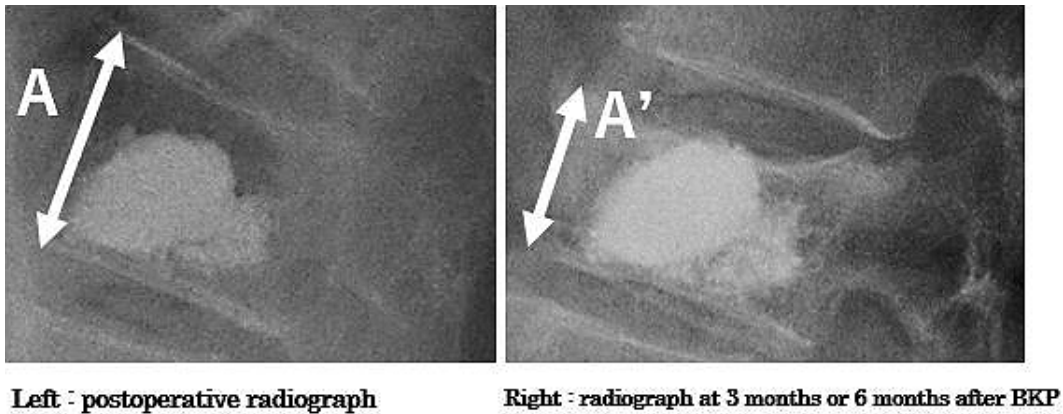


Figure 2. The measurement of HA, calculation of VHL, and definition of RAV and non-RAV.

Height of anterior vertebra (HA): A, A'.

Vertebral height loss (VHL): A-A'.

Recompression of augmented vertebra (RAV): $VHL \geq 5\text{mm}$.

Non-RAV: $VHL < 5\text{mm}$.

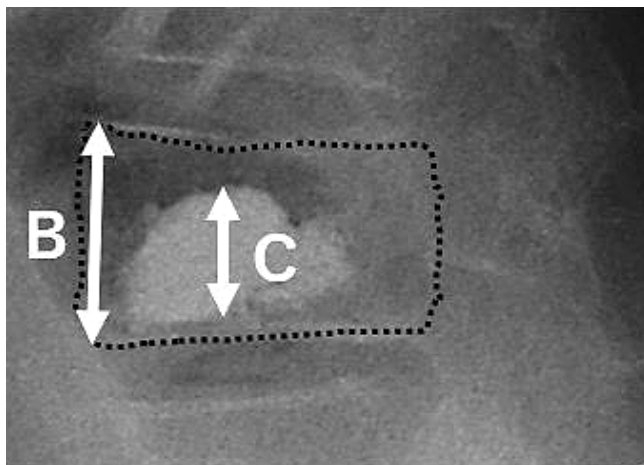


Figure 3. The calculation of CAR.

B: Max distance between the upper and lower endplates.

C: Max height of PMMA.

Cement augmentation ratio (CAR) = $C/B \times 100$.

Table 1 presents baseline characteristics of RAV and non-RAV groups and results of the univariable analysis. There were no statistical differences in gender, presence of medication for osteoporosis, IVC, and cement leakage. Age in the RAV group was significantly higher (age, 80.1 years vs 74.7 years, $P < 0.01$), while CAR and fracture age were lower compared with the non-RAV group (CAR, 69.4% vs 77.6%, $P < 0.01$; fracture age, 49.3 days vs 67.8 days, $P < 0.01$). A multivariate regression analysis revealed that age (OR=1.12, $P = 0.001$), and CAR (OR=0.91, $P = 0.001$) were independently associated with RAV (Table 2). Two reoperations were performed in the RAV group. In both cases, posterior decompression and instrumented fusion were performed for paraplegia associated with RAV (Fig. 4).

Discussion

Although BKP can effectively restore the collapsed vertebral body height, RAV could also occur after the procedure. Li et al.²² revealed that the recompression rate was higher in patients who underwent BKP than those receiving PVP treatment. In this study, RAV after BKP was observed in 38.5% of the patients who underwent BKP in our single institution. Kim et al.¹⁹ and Niu et al.²¹ reported that the incidence rate for RAV was 14.0% and 12.5%, respectively. Although the definition of RAV in their studies was stricter than ours, the incident rate for RAV in our study (38.5%) was higher than that in their study. The high incidence rate in our study may be derived from differences in the intervention times. The mean fracture age in the study by Kim et al.¹⁹ was 16.6 days, and almost all vertebrae (76.9%) in the study by Niu et al.²¹ were treated within 42 days after the onset of symptoms. In contrast, the mean fracture age in our study was 60.7 days (Table 3). In cases of older fractured vertebra with a sclerotic bone environment, the augmented PMMA mass volume is prone to be restricted by the sclerotic bone area, and the remaining non-augmented cancellous bone area consequently results in RAV after the procedure. Takahashi et al.²³ suggested that delayed surgery was related to the progression of vertebral recompression after BKP.

This study was the first to analyze CAR as an index of cement augmentation, which identified low CAR as a risk factor for RAV. Previous studies have reported that inadequate augmentation with residual unfilled spaces within the vertebrae was an important factor related to recompression. Kim et al.¹⁹ found that there were non-augmented bony areas between PMMA and the two end plates, which resulted in greater height loss in BKP. Li et al.²⁰ also revealed that the distance between PMMA and the end plates was an important risk factor for RAV after BKP. Kim et al.²⁴ conducted a biomechanical study using osteoporotic cadaveric

Table 1. Univariate Analysis of Clinical Data Between RAV and Non-RAV Groups.

| Clinical data | RAV group (n=30) | Non-RAV group (n=48) | P-value |
|--|---------------------|-------------------------|---------|
| Age (years), mean±SD | 80.1±5.1 | 74.7±6.8 | <0.01* |
| Gender, n (%) | | | 1.00 |
| Male | 7 (23.3) | 11 (23.0) | |
| Female | 23 (76.7) | 37 (77.1) | |
| Fracture age (days), mean±SD | 49.3±97.7 | 67.8±64.1 | <0.01* |
| Presence of medication for osteoporosis, n (%) | | | 0.50 |
| Yes | 25 (83.3) | 43 (89.6) | |
| No | 5 (16.7) | 5 (10.4) | |
| Presence of intervertebral cleft, n (%) | | | 0.574 |
| Yes | 25 (83.3) | 36 (75.0) | |
| No | 5 (16.7) | 12 (25.0) | |
| CAR (%), mean±SD | 69.4±12.1 | 77.6±7.4 | <0.01* |
| Leakage of bone cement, n (%) | | | 1.00 |
| Yes | 5 (16.7) | 7 (14.6) | |
| No | 25 (83.3) | 41 (85.4) | |

RAV, recompression of augmented vertebra; CAR, cement augmentation ratio; *, P<0.05

Table 2. Multivariate Logistic Regression Analysis of Factors Correlated with RAV.

| Variables | B | SE | Wald | P | ORs (95% CIs) |
|-----------|-------|------|------|-------|------------------|
| Age | 0.18 | 0.06 | 10.4 | 0.001 | 1.12 (1.07–1.34) |
| CAR | -0.99 | 0.03 | 10.1 | 0.001 | 0.91 (0.85–0.96) |

B, regression coefficient; SE, standard error; ORs, odds ratios; CAR, cement augmentation ratio; CI, confidence intervals

Table 3. Comparison of Incidence Rates for RAV, Definitions of RAV, and Fracture Ages Between Previous Studies and Our Study.

| Study | Incidence rate for RAV | Definition of RAV | Fracture age |
|---|---|---|--|
| Kim et al. 2010 ¹⁹⁾ (n=80) | 12.5% (n=10) | A decrease in HA of more than 1 mm between immediate postoperation and final follow-up | 16.6 days on average |
| Niu et al. 2015 ²¹⁾ (n=131) | 14.0% (n=17) | A decrease in anterior, middle, or posterior vertebral height of more than 4 mm between 1 day after surgery and final follow-up | <42 days (n=93/76.9%) >42 days (n=38/23.1%) |
| Our study (n=78) | 35.9% (n=28) (at 3 months after BKP) | A decrease in HA of more than 5 mm between immediate postoperation and 3 or 6 months after surgery | 60.7 days on average |
| | 38.5% (n=30) (at 6 months after BKP) | | |

RAV, recompression of augmented vertebra; BKP, balloon kyphoplasty; HA, height of the anterior vertebra

fractured vertebral bodies to investigate the behavior of fractured osteoporotic vertebral bodies treated with either PVP or BKP under repetitive loading conditions. In their study, they found that cyclic loading compressed the osteoporotic cancellous bone between PMMA and the end plates and resulted in VHL. Consistently, this study found that low CAR with residual cancellous bone within the augmented vertebra contributed to RAV after BKP.

This is the first report that identified older age as risk factor for RAV. In adjacent vertebral fractures after vertebral

kyphoplasty, a retrospective study analyzed with multivariate analysis by Takehara et al. reported that older age contributed to recompression of adjacent vertebra after BKP, and elderly people often showed bone fragility due to osteoporosis¹²⁾. In addition, in the augmented vertebra, we speculated that the vertebral bone fragility due to aging would make the residual cancellous bone between the cement and end plates easily collapse. Further, we should pay attention to cement augmentation in elderly people to avoid postoperative RAV.

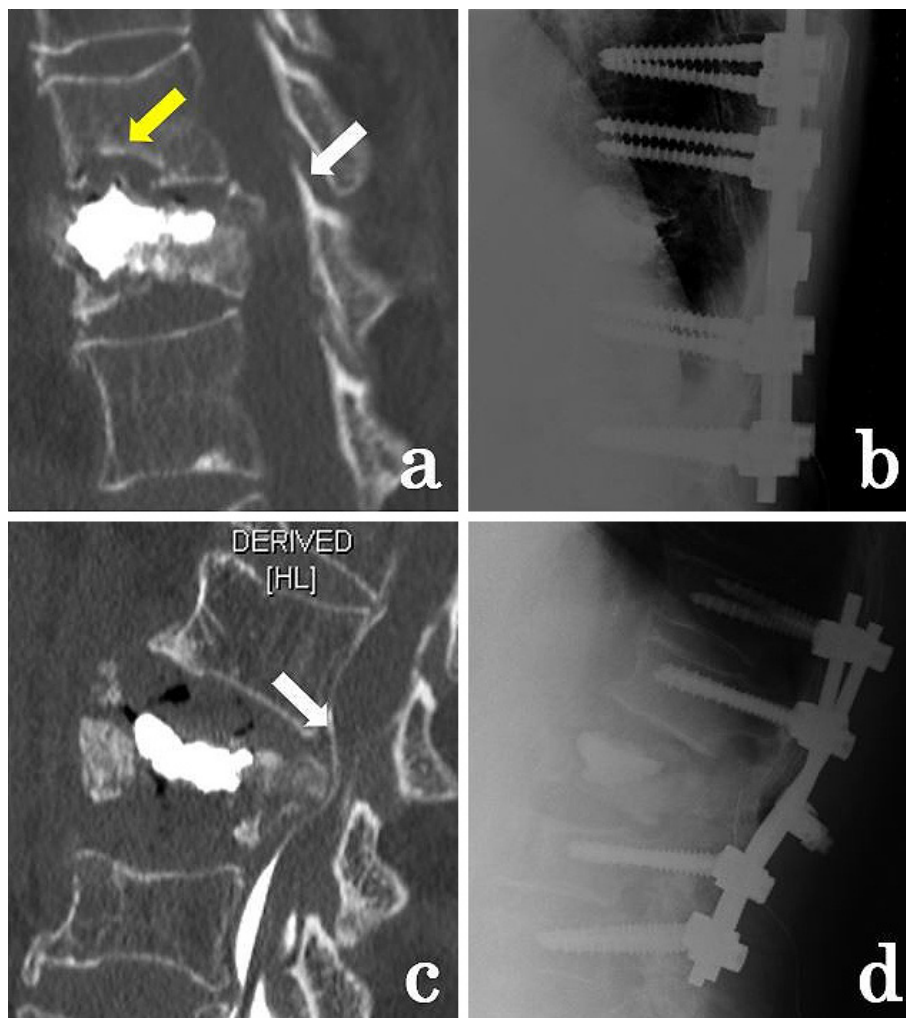


Figure 4. Two cases in which reoperations were performed due to paraplegia after BKP. (a–b) A 76-year-old female. (a) Sagittal CT image showing spinal cord compression due to recompression of the augmented L1 vertebra (white arrow). The superior adjacent vertebra was also fractured due to the augmented PMMA mass (yellow arrow). (b) Postoperative lateral radiograph showing posterior decompression and instrumented fusion from T11 to L3. (c–d) A 86-year-old female. (c) Sagittal CT image showing spinal cord compression due to recompression of the augmented T12 vertebra (white arrow). (d) Postoperative lateral radiograph showing posterior decompression and instrumented fusion from T10 to L2.

In an ideal cement augmentation, the inserted PMMA should come in contact with both the upper and lower end plates, inducing better cement augmentation with higher CAR. In cases with sclerotic bone environments, using a curette to scrape and score sclerotic cancellous bone that may hinder vertebral body height restoration, or early intervention before the formation of sclerotic bone, would be favorable. Furthermore, in accordance with fracture type, an inflatable bone tamp should be inserted into an appropriate position where the inflated balloon comes in contact with both the upper and lower end plates. These attempts for “end plate to end plate cement augmentation” are important for the prevention of RAV.

The present study has the following limitations: (1) The number of patients who developed recompression was small, and further studies with larger sample sizes are needed to

ensure the generalizability of our conclusions. (2) BMD, which may influence the prognosis of the augmented vertebrae, could not be evaluated among all patients. (3) Cement augmentation was evaluated in only the S-I direction using lateral radiograph as CAR. Further study using postoperative CT scan is needed to perform a three-dimensional analysis including the L-R and A-P directions for accurate evaluation of cement augmentation. Despite these limitations, this study presents the informative data about RAV that are useful in clinical practice, especially for spine surgeon who performs BKP.

Conclusion

In this study, RAV was observed in 38.5% of patients who underwent BKP in our single institution. Older age and

low CAR were independently associated with RAV. For the prevention of RAV, especially in cases of elderly people, augmented PMMA should come in contact with both the upper and lower end plates.

Conflicts of Interest: The authors declare that there are no relevant conflicts of interest.

Sources of Funding: None

Author Contributions: Motoya Kobayashi, MD, wrote and prepared the manuscript, and all of the authors participated in the study design.

Ethical Approval: Unnecessary

References

1. Strom O, Borgstrom F, Kanis JA, et al. Osteoporosis: burden, health care provision and opportunities in the EU: a report prepared in collaboration with the International Osteoporosis Foundation (IOF) and the European Federation of Pharmaceutical Industry Associations (EFPIA). *Arch Osteoporos*. 2011;6:59-155.
2. Arai H, Ouchi Y, Toda K, et al. Japan as the front-runner of super-aged societies: perspectives from medicine and medical care in Japan. *Geriatr Gerontol Int*. 2015;15(6):673-87.
3. Kono S, Togawa D, Kamae I, et al. Burden of illness of conservative medical management to vertebral compression fracture osteoporosis patients. *Seikeigeka*. 2009;60:1033-8. Japanese.
4. Takahashi S, Hoshino M, Yasuda H, et al. Cost-effectiveness of balloon kyphoplasty for patients with acute/ subacute osteoporotic vertebral fractures in the super-aging Japanese society. *Spine*. 2019;44(5):E298-305.
5. Silverman SL. The clinical consequences of vertebral compression fracture. *Bone*. 1992;13(Suppl 2):27-31.
6. Edidin AA, Ong KL, Lau E, et al. Mortality risk for operated and nonoperated vertebral fracture patients in the medicare population. *J Bone Miner Res*. 2011;26(7):1617-26.
7. Ito Y, Hasegawa Y, Toda K. Pathogenesis and diagnosis of delayed vertebral collapse resulting from osteoporotic spinal fracture. *Spine J*. 2002;2(2):101-6.
8. Ha KY, Kim YH. Risk factors affecting progressive collapse of acute osteoporotic spinal fractures. *Osteoporos Int*. 2013;24(4):1207-13.
9. Tsujio T, Nakamura H, Terai H, et al. Characteristic radiographic or magnetic resonance images of fresh osteoporotic vertebral fractures predicting potential risk for nonunion: a prospective multi-center study. *Spine*. 2011;36(15):1229-35.
10. Martincic D, Brojan M, Kosel F, et al. Minimum cement volume for vertebroplasty. *Int Orthop*. 2015;39(4):727-33.
11. Zhu SY, Zhong Zm, Wu Q, et al. Risk factors for bone cement leakage in percutaneous vertebroplasty: a retrospective study of four hundred and eighty five patients. *Int Orthop*. 2016;40(6):1205-10.
12. Takahara K, Kamimura M, Moriya H, et al. Risk factors of adjacent vertebral collapse after percutaneous vertebroplasty for osteoporotic vertebral fracture in postmenopausal women. *BMC Musculoskelet Disord*. 2016;17:12.
13. Zhang L, Liu Z, Wang J, et al. Unipedicular versus bipedicular percutaneous vertebroplasty for osteoporotic vertebral compression fractures: a prospective randomized study. *BMC Musculoskelet Disord*. 2014;16:145.
14. Civelek E, Cansever T, Yilmaz C, et al. The retrospective analysis of the effect of balloon kyphoplasty to the adjacent-segment fracture in 171 patients. *J Spinal Disord Tech*. 2014;27(2):98-104.
15. Atalay B, Caner H, Gokce C, et al. Kyphoplasty: 2 years of experience in a neurosurgery department. *Surg Neurol*. 2005;64(Suppl 2):72-6.
16. Lieberman I, Reinhardt MK. Vertebroplasty and kyphoplasty for osteolytic vertebral collapse. *Clin Orthop Relat Res*. 2003;415(Suppl):176-86.
17. Zhai W, Jia Y, Wang J, et al. The clinical application and efficacy of percutaneous kyphoplasty via unilateral pedicular approach guided by CT image measurement. *Int J Clin Exp Med*. 2015;8(11):20861-8.
18. Chang X, Lv YF, Chen B, et al. Vertebroplasty versus kyphoplasty in osteoporotic vertebral compression fracture: a meta-analysis of prospective comparative studies. *Int Orthop*. 2015;39(3):491-500.
19. Kim YY, Rhyu KW. Recompression of vertebral body after balloon kyphoplasty for osteoporotic vertebral compression fracture. *Eur Spine J*. 2010;19(11):1907-12.
20. Li D, Wu Y, Huang Y, et al. Risk factors of recompression of cemented vertebrae after kyphoplasty for osteoporotic vertebral compression fractures. *Int Orthop*. 2016;40(6):1285-90.
21. Niu J, Zhou H, Meng Q, et al. Factors affecting recompression of augmented vertebrae after successful percutaneous balloon kyphoplasty: a retrospective analysis. *Acta Radiol*. 2015;56(11):1380-7.
22. Li YX, Guo DQ, Zhang SC, et al. Risk factor analysis for re-collapse of cemented vertebrae after percutaneous vertebroplasty (PVP) or percutaneous kyphoplasty (PKP). *Int Orthop*. 2018;42(9):2131-9.
23. Takahashi S, Hoshino M, Terai H, et al. Differences in short-term clinical and radiological outcomes depending on timing of balloon kyphoplasty for painful osteoporotic vertebral fracture. *J Orthop Sci*. 2018;23(1):51-6.
24. Kim MJ, Lindsey DP, Hannibal M, et al. Vertebroplasty versus kyphoplasty: biomechanical behavior under repetitive loading conditions. *Spine*. 2006;31(18):2079-84.

Spine Surgery and Related Research is an Open Access journal distributed under the Creative Commons Attribution-NonCommercial-NoDerivatives 4.0 International License. To view the details of this license, please visit (<https://creativecommons.org/licenses/by-nc-nd/4.0/>).