

Available online at www.sciencedirect.com

ScienceDirect

journal homepage: www.elsevier.com/locate/radcr

Case Report

Long term survival after multiple microwave ablations for colorectal cancer lung metastases: A case report [☆]

Victoria T. Y Lee^a, Yueh-Hsin Lin^a, Derek Glenn, MD^b, Suhrid Lodh, MD^c, David L. Morris, MD^{a,d,*}

^a Department of Medicine, University of New South Wales, Sydney, NSW 2052, Australia

^b Department of Radiology, St George Hospital, Sydney, NSW 2217, Australia

^c Department of Interventional Radiology, St George Hospital, Sydney, NSW 2217, Australia

^d Department of Surgery, St George Hospital, Sydney, NSW 2217, Australia

ARTICLE INFO

Article history:

Received 9 March 2022

Accepted 13 March 2022

Keywords:

Pulmonary microwave ablation

Colorectal cancer

Pulmonary metastases

Long term prognosis

ABSTRACT

Colorectal cancer is one of the leading causes of cancer-associated morbidity and mortality in the world, with lower survival rates when metastases are present. We present a case of a 69-year-old man, diagnosed with metastatic rectal cancer to the lungs in 2015. Over the course of 5 years, he was treated with 4 microwave ablation procedures to both his lungs. Despite this, he does not have any local recurrence or any symptoms since he was first diagnosed 7 years ago. This case highlights the potential for microwave ablation to be used for curative intent in pulmonary metastases in colorectal cancer as an alternative to more invasive and complex procedures such as metastasectomies or lung resection, as well as the benefit of using microwave ablation for disease control to improve patients' quality of life.

© 2022 Published by Elsevier Inc. on behalf of University of Washington.

This is an open access article under the CC BY-NC-ND license

(<http://creativecommons.org/licenses/by-nc-nd/4.0/>)

Introduction

Colorectal cancer (CRC) is one of the leading causes of cancer-associated morbidity and mortality in the world [1]. Despite the evidence of a 90% 5-year survival rate when CRC is diagnosed at an early stage, more than 60% of cases are diagnosed when the cancer has already metastasized [2]. Recurrence after surgery is major reason for both morbidity and mortality,

with lung metastases being the most common site of extra-abdominal metastases from CRC [2]. Therapeutic advances in patients with metastatic CRC have been associated with prolonged survival rates. In 1965, Thomford et al. [3] reported principles for resection of lung lesions, and these have been accepted as an appropriate therapy by most surgeons [4].

Although resection of solitary lung metastases has been accepted by physicians, resection of multiple or bilateral lesions remains controversial, and the role of repeated resection for recurrent pulmonary metastasis has not been

[☆] Competing Interests: None.

* Corresponding author

E-mail address: david.morris@unsw.edu.au (D.L. Morris).

<https://doi.org/10.1016/j.radcr.2022.03.059>

1930-0433/© 2022 Published by Elsevier Inc. on behalf of University of Washington. This is an open access article under the CC BY-NC-ND license (<http://creativecommons.org/licenses/by-nc-nd/4.0/>)

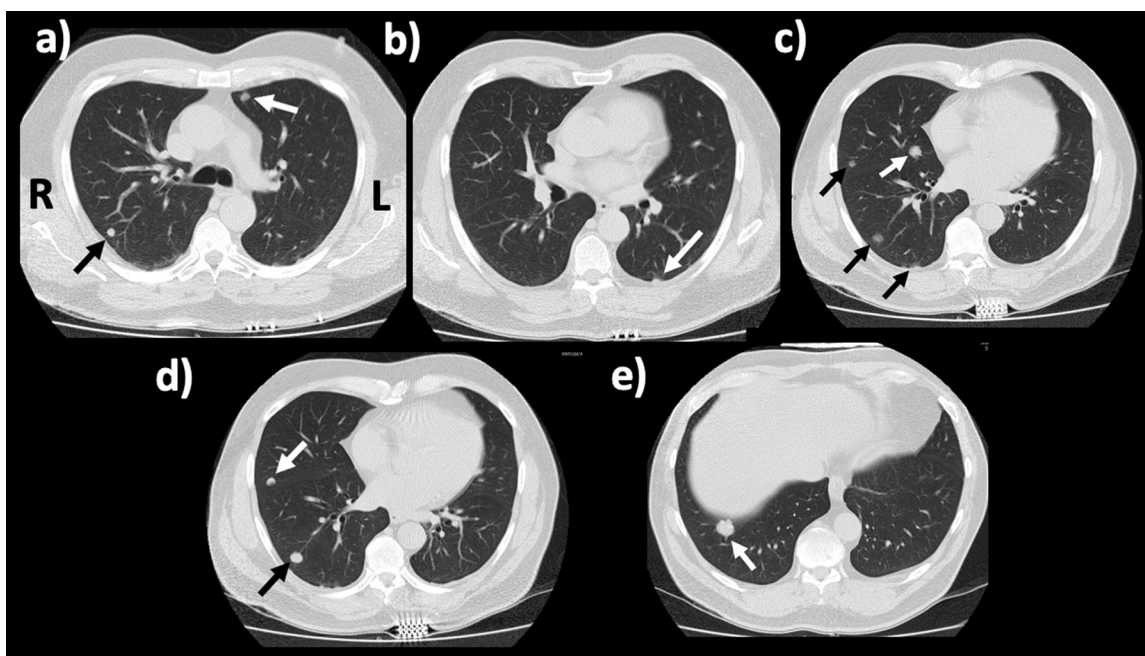


Fig. 1 – CT guided tissue ablation performed on June 23, 2017. (A-E) Multiple lung lesions, from superior to inferior. A total of 8 metastases were targeted by microwave ablation using a 20-cm 14-gauge Covidien system.

well defined [5]. Studies have shown that an increasing number of metastases predicted higher rates of recurrence [6]. Pulmonary resection has the risk of respiratory function compensation, hence comprehensive pre-operative planning is important in weighing the potential benefits to harm for the patient [7]. Lung ablation for metastatic colorectal cancer was first described in 2003 by a team of doctors in Australia [8]. Procedures are done under CT guidance, and are quick and often without complications. Lung ablations are generally preferred over pulmonary metastasectomy and lobectomy due to lower rates of morbidity and better local tumor control [9].

To the best of our knowledge, patients with solitary pulmonary metastases have a better prognosis than those affected by multiple lesions. On the contrary, this present case involves multiple pulmonary metastases secondary to colorectal cancer with survival of more than 6 years post multiple pulmonary ablations to both lungs. The role of number of lesions and recurrence of lesions in prognosis is less well established, and hence this case may be of interest.

Case report

A 69-year-old man presented with 12 months of changes in bowel movements and a positive fecal occult blood test. Subsequent follow-up colonoscopy revealed a rectal tumor, and the patient was diagnosed with T3N2a (stage IIIB) rectal cancer, moderately differentiated mucinous adenocarcinoma in November 2015. He was treated with 5 weeks of radiation therapy in February 2016, before undergoing an anterior

resection in March 2016. Between July and December 2016, he received 9 cycles of chemotherapy.

In April 2017, a biopsy of a right mid-zone lung nodule was taken after incidental finding of a suspicious lesion noted on a follow-up scan. The pathology report revealed malignant glandular structures with goblet cells lined by tall columnar malignant cells associated with mucinous secretions. Immunohistochemistry confirmed CEA consistent with metastatic colorectal adenocarcinoma. A subsequent positron emission topography (PET) scan was performed, showing uptake in a total of 5 lesions across both lungs – 1 in the right upper lobe, 2 in the right middle lobe, 1 in the right lower lobe, and 1 in the left upper lobe. All of these lesions had increased in size and/or metabolism since the last PET scan in June 2016, but there was no evidence of local recurrence or metastatic adenopathy. At this point, a multidisciplinary team decision was made against a right pneumonectomy due to the number of lesions present, and the patient was booked for ablation. The patient underwent a first microwave ablation (MWA) procedure in June 2017 (Fig. 1). A total of 8 metastases across both lungs were targeted by microwave ablation using a 20-cm 14-gauge Covidien system. The multiple treatments in the right lung precipitated a right pneumothorax which was treated by placement of a 14-French non-self-retaining Thal-quick intercostal drain.

In March the following year, we found an untreated lesion within the lateral segment of the right middle lobe which had increased in size from 4mm previously to 10 mm, and a decision to retreat was made. A second MWA was performed in March 2018 (Fig. 2). The initially selected lesion laterally in the middle lobe was targeted first at 75 watts for 90 seconds. The lesion at the right lung base appeared to be a local recurrence of a previously treated lesion, and was targeted second, at 100

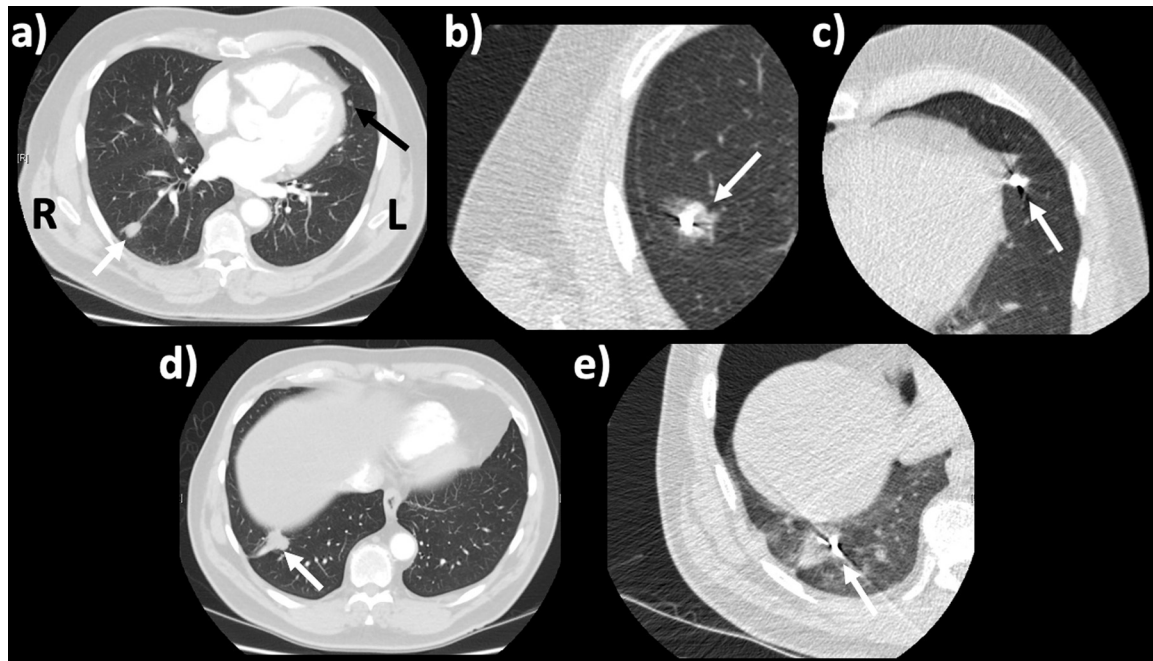


Fig. 2 – CT guided microwave ablation performed on March 28, 2018. (A) Pulmonary lesions located at the lateral middle lobe and the left upper lobe near the cardiac apex. (B) Right middle lobe lesion received 75 watts for 90 seconds. (C) Lesion near the cardiac apex received 45 watts for 90 seconds. (D) Right lung base lesion appears to be local recurrence. (E) Right lung base lesion targeted with 100 watts for 3.5 minutes.

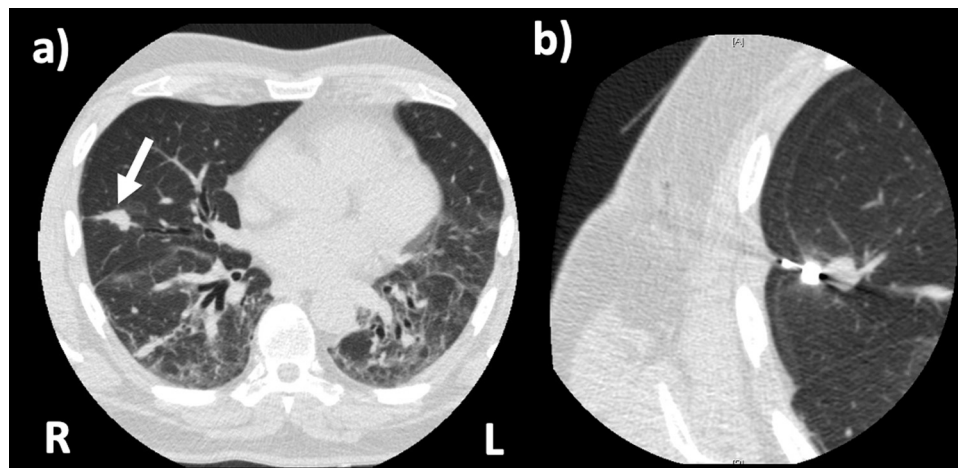


Fig. 3 – CT guided microwave ablation performed on December 5, 2018. (A) Right middle lobe lesion. (B) Right middle lobe lesion targeted with 75 watts for 7 minutes to achieve a 3 cm destruction zone.

watts for 3.5 minutes. A third lesion in the left upper lobe near the cardiac apex was targeted third, at 45 watts for 90 seconds. In December 2018, the lesion in the right middle lobe had increased in size again, and the patient was planned for another ablation (Fig. 3). Seventy-five watts was applied for 7 minutes to achieve a 3 cm destruction zone and a single right middle lobe lesion was ablated.

The patient had a resection of the left upper lobe wedge of lung in November 2021. The pathology report noted a malignant mass with morphology that was compatible with

metastatic adenocarcinoma that was a primary colorectal. The mass was completely excised.

A follow-up scan done in January 2022 revealed increase in size of a right lung lesion. The patient subsequently underwent another MWA procedure to a lesion in the right middle lobe in February 2022 (Fig. 4). The lesion was treated with 100W for 5 minutes inferiorly and 100W for 3 minutes superiorly. 80W for 40 seconds was performed for tract ablation.

In total, the patient had 4 MWA procedures across 5 years that targeted 14 lesions. Despite this, he did not have any

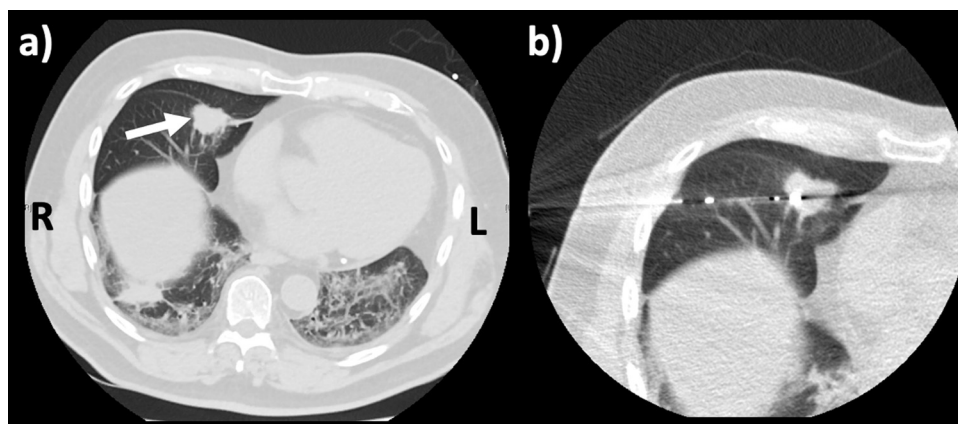


Fig. 4 – Microwave ablation performed on February 2, 2022. (A) Right lung base pulmonary nodule. (B) Right lung base lesion targeted with 100 watts for 5 minutes inferiorly, 10 watts for 3 minutes superiorly and 80 watts for 40 seconds for tract ablation.

local recurrence since he was first diagnosed with rectal cancer 7 years ago. He currently has no symptoms, including respiratory symptoms, and has a good quality of life.

Discussion

Local recurrence of pulmonary metastases from CRC after pulmonary metastectomy is a crucial problem during follow-up, and the indication for operation is controversial. In our study, we reported a case of a 69-year-old man with an ongoing 6-year survival post colorectal cancer diagnosis, complicated by multiple pulmonary metastases that was treated with multiple MWA procedures. This case highlights the potential for MWA to be used for curative intent in pulmonary metastases in CRC, as well as the benefit of using MWA for disease control. Despite recurring pulmonary metastases, the patient's condition did not decline further, and the MWA treatments seemed to have played a part in this.

This is a unique case which shows multiple pulmonary metastases without extrapulmonary lesions, which is uncommon as CRC metastases usually develop first in the liver, then in the lungs, and subsequently in other sites [10]. Despite the fact that pulmonary metastases are often surgically incurable, surgical resection has been accepted as the only radical treatment available, and benefits have been shown in cases where metastases confined in lungs were treated with a complete resection [11]. Others have suggested that better prognosis is dependent on the aggressiveness of the tumor. For example, synchronous lung nodules are known for having significantly lower survival rate than metachronous lesions, given that metachronous lung metastases benefit more from pulmonary lung resections [7,12]. Patients with solitary metastasis are also more likely to benefit more from pulmonary resection than those with multiple pulmonary metastases [10]. However, several studies have suggested that there is no significant association between prognosis and number and size of metastatic pulmonary lesions [13].

The low mortality and morbidity rate from surgical pulmonary resection, combined with the lack of other effective

therapies justify surgical management in patients with primary CRC, and pulmonary metastases [12]. Studies reported that the 5-year survival for patients who underwent a second thoracotomy was around 30% to 50%, whereas the median survival length was less than 5 months with a survival rate of less than 5% for patients who did not receive any treatment [5,7]. However, recurrence rate is still as high as 68% after pulmonary metastasectomy, with the remaining lung tissues often being the sites of recurrence [7]. Surgical resection of pulmonary metastases from CRC is a safe and feasible approach, but only 24% of patients with metachronous lung-only metastases were managed with a curative intent [14]. Despite this, it is appropriate to evaluate the prognostic factors for this population, as general criteria for pulmonary metastasectomy in CRC have not been consensually established [14].

Improving long-term survival whilst also ensuring quality of life is the ultimate goal of cancer treatment. Ablation therapy is another therapeutic option in patients with unresectable metastatic disease. Compared to surgical pulmonary metastasectomy, percutaneous radiofrequency ablation (RFA) has proven to provide potential higher survival benefit and lower morbidity and mortality for patients with CRC [15]. RFA is the predominant and most frequently used method among ablation techniques [16]. Recently, there is growing evidence supporting the use of MWA for its minimally invasive techniques and effectiveness in eradicating unresectable pulmonary metastases [17]. Animal models have shown better ablative results with MWA as compared to RFA in terms of width and regularity of ablation zones, higher rate of complete ablation and tumor control, less susceptibility to the “heat sink effect” and diminished thermal conductivity of ventilated lungs, which are essential for ablating larger lesions with uniform ablation zones with adequate margins [15–17]. Additionally, MWA has shorter ablation times, and larger ablation zones than RFA [17].

Theoretically, although MWA is better than RFA, the treatment efficacies of the 2 approaches remain questionable. Meta-analysis of clinical outcomes after RFA and MWA for lung cancer and pulmonary metastases shows RFA is associated with longer survival than MWA, and patients with pulmonary metastases showed better survival after RFA com-

pared with MWA-treated patients [16]. However, other studies have observed that there is increased chance of survival among MWA-treated CRC patients with small pulmonary metastases size that are equal to or less than 3 centimetres [18,19]. Although the current data seems promising, there are limited research regarding the use of MWA in treating CRC lung metastases, and the absence of controlled trials has resulted in the limited interpretation of the gain for patients [20,21].

Conclusion

In conclusion, the presented case shows optimized outcomes for patients with repeated MWA in treating multiple pulmonary metastases secondary to CRC. Early screening and advanced CT scans have been recognized as the cornerstone of a successful outcome by allowing early detection of lung metastases from CRC and evaluating the number and size of the nodules. This may improve diagnostic accuracy for therapy planning in a timely manner. As MWA is an up-and-coming treatment modality with a growing body of evidence showing potential benefits, further research with large randomized controlled trials could facilitate better clinical outcomes for pulmonary metastases from CRC.

Patient consent

Written, informed consent was obtained from the patient.

REFERENCES

- [1] Siegel RL, Miller KD, Jemal A. Cancer statistics, 2018. *CA Cancer J Clin* 2018;68:7–30.
- [2] Brenner H, Kloor M, Pox C. Colorectal cancer. *Lancet* 2014;383:1490–502.
- [3] Thomford NR, Woolner LB, Clagett OT. The surgical treatment of metastatic tumors in the lungs. *J Thorac Cardiovasc Surg* 1965;49:357–63.
- [4] Sundermeyer ML, Meropol NJ, Rogatko A, Wang H, Cohen SJ. Changing patterns of bone and brain metastases in patients with colorectal cancer. *Clin Colorectal Cancer* 2005;5:108–13.
- [5] Rena O. Pulmonary resection for metastases from colorectal cancer: factors influencing prognosis. Twenty-year experience. *Eur J Cardiothorac Surg* 2002;21:906–12.
- [6] Blackmon SH. Predictors of recurrent pulmonary metastases and survival after pulmonary metastasectomy for colorectal cancer. *Ann Thorac Surg* 2012;94:1802–9.
- [7] Inoue M. Benefits of surgery for patients with pulmonary metastases from colorectal carcinoma. *Ann Thorac Surg* 2004;78:238–44.
- [8] Steinke K, King J, Glenn D, Morris DL. Radiologic appearance and complications of percutaneous computed tomography-guided radiofrequency-ablated pulmonary metastases from colorectal carcinoma. *J Comput Assist Tomogr* 2003;27:750–7.
- [9] Kurilova I. Microwave ablation in the management of colorectal cancer pulmonary metastases. *Cardiovasc Interventi Radiol* 2018;41:1530–44.
- [10] Mityr E. Epidemiology, management and prognosis of colorectal cancer with lung metastases: a 30-year population-based study. *Gut* 2010;59:1383–8.
- [11] Ihn MH. Curative resection for metachronous pulmonary metastases from colorectal cancer: analysis of survival rates and prognostic factors. *Cancer Res Treat* 2017;49:104.
- [12] Rama N, Monteiro A, Bernardo JE, Eugénio L, Antunes MJ. Lung metastases from colorectal cancer: surgical resection and prognostic factors. *Eur J Cardiothorac Surg* 2009;35:444–9.
- [13] Iizasa T. Prediction of prognosis and surgical indications for pulmonary metastasectomy from colorectal cancer. *Ann Thorac Surg* 2006;82:254–60.
- [14] King J. Percutaneous radiofrequency ablation of pulmonary metastases in patients with colorectal cancer. *Br J Surg* 2004;91:217–23.
- [15] Lyons N, Pathak S, Daniels IR, Spiers A, Smart NJ. Percutaneous management of pulmonary metastases arising from colorectal cancer; a systematic review. *Eur J Surg Oncol* 2015;41:1447–55.
- [16] Yuan Z, Wang Y, Zhang J, Zheng J, Li W. A meta-analysis of clinical outcomes after radiofrequency ablation and microwave ablation for lung cancer and pulmonary metastases. *J Am Coll Radiol* 2019;16:302–14.
- [17] Ferguson CD, Luis CR, Steinke K. Safety and efficacy of microwave ablation for medically inoperable colorectal pulmonary metastases: Single-centre experience. *J Med Imaging Radiat Oncol* 2017;61:243–9.
- [18] Cheng G. The safety and efficacy of microwave ablation for the treatment of CRC pulmonary metastases. *Int J Hyperth* 2018;34:486–91.
- [19] Matsui Y. Long-term survival following percutaneous radiofrequency ablation of colorectal lung metastases. *J Vasc Interv Radiol* 2015;26:303–10.
- [20] Belfiore G. Patients' survival in lung malignancies treated by microwave ablation: our experience on 56 patients. *Eur J Radiol* 2013;82:177–81.
- [21] Vogl TJ. Microwave ablation therapy: clinical utility in treatment of pulmonary metastases. *Radiology* 2011;261:643–51.