

A case of cutaneous necrosis due to intra-articular hyaluronic acid and treated with hyaluronidase

SAGE Open Medical Case Reports
Volume 9: 1–4
© The Author(s) 2021
Article reuse guidelines:
sagepub.com/journals-permissions
DOI: 10.1177/2050313X211025110
journals.sagepub.com/home/sco



Michelle Aaron^{1,2}, Yu Qing Huang³, Danielle Bouffard⁴,
Jean-Pascal Costa³ and Benoît Côté^{1,2}

Abstract

A 66-year-old woman presented to the hospital with cutaneous necrosis of her right ankle and foot. Her symptoms began immediately after an intra-articular injection of hyaluronic acid for ankle osteoarthritis, which was performed 6 days before. Histopathology showed an intra-vascular hyaluronic acid embolus. The initial treatment approach was conservative, but the patient's clinical state degraded. She was thus treated with sub-cutaneous hyaluronidase, the enzyme that degrades hyaluronic acid, which yielded a moderate improvement even though it was administered 22 days after the initial hyaluronic acid injection. Although hyaluronic acid embolism and subsequent cutaneous necrosis are well-known complications of dermal fillers, there are few reported cases of embolism following intra-articular injection. To our knowledge, this is the first time hyaluronidase has been used in this setting.

Keywords

Embolism, hyaluronic acid, hyaluronidase, adverse effects, necrosis

Date received: 19 February 2021; accepted: 5 April 2021

Introduction

In a dermatological setting, hyaluronidase (HYAL) is primarily used for treatment of skin necrosis caused by hyaluronic acid (HA) dermal fillers.^{1,2} The exact mechanism of this serious complication is understood to be caused by direct HA embolization, with intra-vascular occlusion and chemical damage to the endothelial lining, and extra-vascular factors such as external vascular compression by HA and inflammation-induced edema.^{1,3} Similarly, a handful of cases^{4–6} of skin necrosis caused by intra-articular (IA) injection of HA have been described, but recognition of this complication is often delayed and treatment is not well established. This report presents a case of cutaneous necrosis following IA HA injection successfully treated with HYAL.

Case report

A 66-year-old woman received a fluoroscopy guided IA injection of 3 mL of non-animal stabilised HA (Durolane[®], 20 mg HA/mL, 0.5%–1% cross-linked HA) and 20 mg of triamcinolone acetonide in her right ankle. She presented to the hospital 6 days later with edema and painful violaceous

patches with livedoid purpuric macules of her foot, ankle and shin (Figure 1(a)) which began a few hours after the procedure. Her vital signs, neurovascular exam and duplex ultrasonography were normal. All her blood analyses were normal, including blood cell count, biochemical assay, C-reactive protein, coagulation profile, autoantibodies and antiphospholipid profiles. The computed tomography angiography showed no visible emboli or signs of vasculitis. The fluoroscopic images were reviewed, confirming that the injection technique was intra-articular. Given the rapid development of symptoms following her IA injection, our most likely diagnosis was HA arterial embolism. The punch

¹Department of Dermatology, Université de Montréal, Montreal, QC, Canada

²Centre hospitalier de l'Université de Montréal, Montreal, QC, Canada

³Department of Internal Medicine, Université de Montréal, Montreal, QC, Canada

⁴Department of Pathology, Université de Montreal, Montréal, QC, Canada

Corresponding Author:

Michelle Aaron, Centre hospitalier de l'Université de Montréal, 1000 Saint-Denis Street, Montreal, QC H2X 0C1, Canada.

Email: michelle.aaron@umontreal.ca



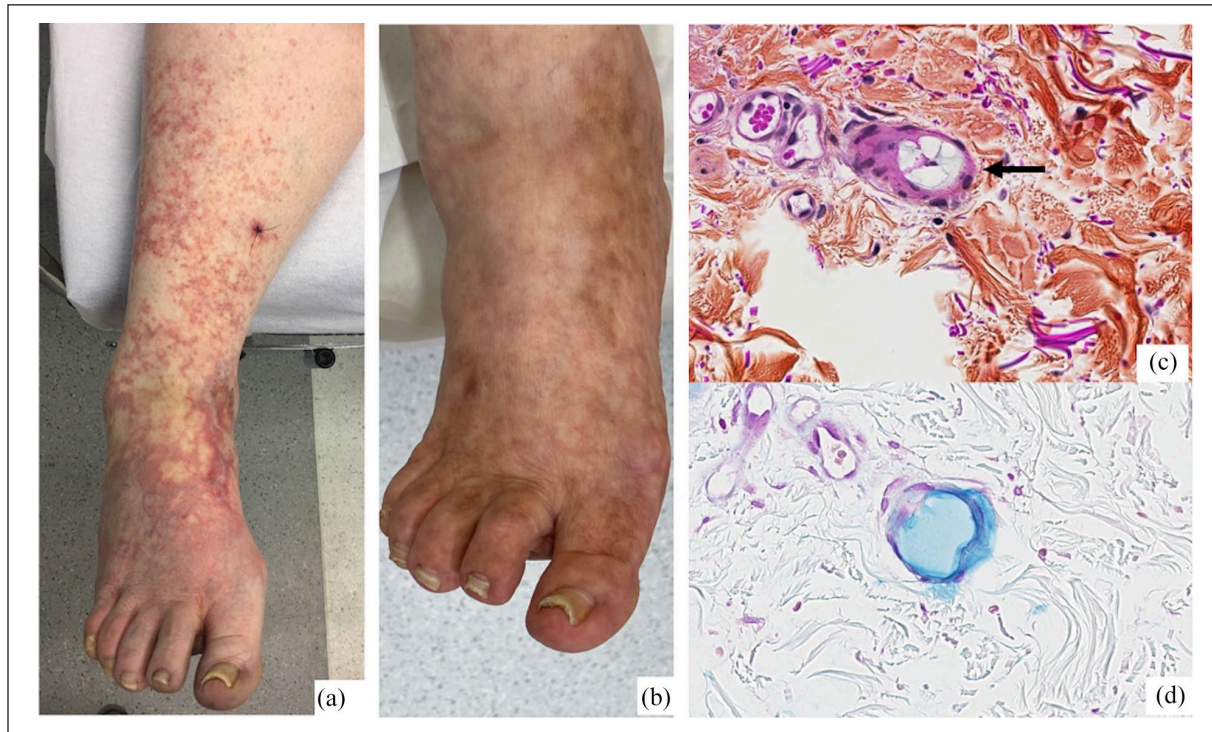


Figure 1. Clinical and histopathological images of our patient. (a) Anterior view of right foot and calf on day of first dermatology visit (Day 7 post intra-articular hyaluronic acid injection). (b) Anterior view at follow-up, 5 months later. (c) Small, rounded blood vessel in the reticular dermis showing mucinous slightly basophilic material in the vessel lumen (HPS stain) (black arrow). (d) Hyaluronic acid in blood vessel lumen positive with Alcian blue stain at pH of 2.5.

biopsy showed intra-vascular HA embolus (Figure 1(c) and (d)). She was initially managed with analgesics. Two days later, she was hospitalized due to increasing pain causing inability to walk, and expansion of the rash.

With the diagnosis confirmed by histopathology, given the patient's pain, which was not controlled with increasing doses of opioids, and the prognosis of degradation of HA emboli over 4–6 months,⁴ we opted to treat her with HYAL, which degrades HA. With the patient's consent, 22 days after the initial IA injection, we proceeded to regularly spaced (1 cm) subcutaneous (SC) injection of 3 mL of HYAL (150 IU/mL, total of 450 IU), divided between the two most painful areas, the dorsum of her foot and internal malleolus. A small but notable lessening of the pain and of the violaceous patches was observed immediately after the treatment. No adverse events were noted. Her lesions resolved within 5 months (Figure 1(b)).

Discussion

Although HYAL is well described in the management of vascular complications of HA fillers,^{1,2} it has not been described previously in the treatment of IA HA vascular embolism. Few articles (Table 1) report HA cutaneous embolism following IA injection, but none used HYAL, although many suggested it as a potential treatment.^{4–6} The proposed mechanism of HA

embolism, apart from inadvertent intra-arterial injection, is that HA escapes the joint through a vessel wall defect due to microtrauma or endothelial activation.^{4,5} Conservative treatment was our preferred initial approach. Due to the patient's deteriorating clinical state, we decided to treat her with HYAL 22 days after the IA injection to hasten the degradation of the HA emboli even though animal and in vitro data suggest limited benefits after a delay of 4–24 h.^{1,7} Administration route was based on studies showing that SC HYAL can penetrate vessels to dissolve HA and is preferable to intra-arterial injection.^{2,7,8} The SC approach is also technically more feasible. Regarding the amount of HYAL injected, our decision to administer a conservative dose (450 IU) was based on the quantity of HA injected, the novelty of this treatment approach and the tolerability of multiple SC injections for the patient. However, given that stabilised HA is more difficult to degrade, that the ischemic zone was extensive and that the quantity of HYAL used for vascular complications of cosmetic HA fillers can be much higher, a larger dose could have been considered and might have yielded better results.^{1–3,7}

This case highlights the importance for clinicians to be cognizant of this rare, albeit severe complication of IA HA injection. To our knowledge, this is the first time HYAL has been used in this setting. We observed clinical improvement and no side-effects. Early recognition and treatment of this adverse event will likely yield better outcomes.

Table 1. Summary of cases of cutaneous hyaluronic acid embolism following intra-articular injection.

Source, Year	Age (years), Sex (M, F)	Injection site	Site affected	Onset of symptoms (days)	Clinical presentation	Skin biopsy findings	Treatment	Evolution
Borrógn-Nofuentes et al. ⁴	63, M	Both knees	Right knee	25	Pain, livedo reticularis and two areas of skin necrosis	Intra-arterial foreign bodies of amorphous basophilic material, Alcian blue positive, PAS negative, pH 2.5	LMWH, rest, observation	Fading of lesions after 1 month, resolution after 6 months
Kim et al. ⁵	64, M	Both knees	Right knee	2	Pain, livedoid patch with necrosis	Mixture of reactive and necrotic keratinocytes in epidermis. Presence of foreign body amorphous basophilic material in the dermal stroma and in a medium-sized vein, with associated thrombus.	Topical fusidic acid dressings	Resolution in 4 months
de Azevedo Campos et al. ⁶	74, M	Both knees	Left knee	7	Pain, livedo reticularis without necrosis	Emboli of amorphous basophilic foreign material, with thrombus associated formation.	Rest, analgesics	Resolution after 4 weeks
Our patient, 2020	66, F	Right ankle (fluoroscopy guided)	Right ankle, foot and toes	1	Pain, livedo reticularis with bullae	Emboli of amorphous basophilic foreign material in the reticular dermis	Hyaluronidase injection (see text), analgesics, LMWH prophylactic dose	Resolution after 5 months

M: male; F: female; PAS: periodic acid–Schiff; LMWH: low molecular weight heparin.

Declaration of conflicting interests

The author(s) declared no potential conflicts of interest with respect to the research, authorship and/or publication of this article.

Funding

The author(s) received no financial support for the research, authorship and/or publication of this article.

Patient consent

The patient has provided an informed written consent for publication of her clinical information and images.

References

1. Kim DW, Yoon ES, Ji YH, et al. Vascular complications of hyaluronic acid fillers and the role of hyaluronidase in management. *J Plast Reconstr Aesthet Surg* 2011; 64(12): 1590–1595.
2. Wang M, Li W, Zhang Y, et al. Comparison of intra-arterial and subcutaneous testicular hyaluronidase injection treatments and the vascular complications of hyaluronic acid filler. *Dermatol Surg* 2017; 43(2): 246–254.
3. DeLorenzi C. New high dose pulsed hyaluronidase protocol for hyaluronic acid filler vascular adverse events. *Aesthet Surg J. Jul* 2017; 37(7): 814–825.
4. Borregón-Nofuentes P, Avilés-Izquierdo JA, Martínez-Izquierdo M, et al. Livedo reticularis and skin necrosis due to hyaluronic acid embolism. *JAMA Dermatol* 2013; 149(3): 373–375.
5. Kim WB and Alhusayen RO. Skin Necrosis from Intra-articular Hyaluronic Acid Injection. *J Cutan Med Surg* 2015; 19(2): 182–184.
6. de Azevedo Campos SL, Brasileiro A, João A, et al. Livedo reticularis after intra-articular hyaluronic acid injection. *Indian J Dermatol Venereol Leprol* 2017; 83(5): 602–603.
7. Li J, Xu Y, Wang Y, et al. The role of hyaluronidase for the skin necrosis caused by hyaluronic acid injection-induced embolism: a rabbit auricular model study. *Aesthetic Plast Surg* 2019; 43(5): 1362–1370.
8. DeLorenzi C. Transarterial degradation of hyaluronic acid filler by hyaluronidase. *Dermatol Surg* 2014; 40(8): 832–841.