




Contents lists available at ScienceDirect

International Journal of Surgery Case Reports

journal homepage: www.casereports.com

Combined arthroscopic and open operative management of an intramuscular supraspinatus lipoma in the treatment of subacromial impingement syndrome: A case report

Jarrold Greenhalgh^{a,*}, Andrew Whan^{a,b}, Richard S. Page^{a,c,d}

^a University Hospital Geelong, Barwon Health, Geelong, VIC, Australia

^b Barwon Medical Imaging, Barwon Health, Geelong, VIC, Australia

^c Barwon Centre of Orthopaedic Research and Education (B-CORE), Barwon Health and St John of God Hospital, Geelong, VIC, Australia

^d School of Medicine, Deakin University, Waurn Ponds, Geelong, VIC, Australia

ARTICLE INFO

Article history:

Received 27 March 2018

Received in revised form 14 June 2018

Accepted 6 August 2018

Available online 13 August 2018

Keywords:

Subacromial impingement
Subacromial impingement syndrome
Supraspinatus impingement
Intramuscular lipoma
Lipoma

ABSTRACT

INTRODUCTION: Subacromial impingement syndrome (SAIS) is one cause of shoulder pain and encompasses a spectrum of pathologies and is not an isolated entity.

PRESENTATION OF CASE: We present a rare case where a 40 year old male presented with a 3 year history of right shoulder tip pain with limited abduction to 30°, external rotation to 45°, preserved internal rotation and forward flexion and a painful arc with positive Neers and Hawkins-Kennedy signs for impingement consistent with SAIS. The presentation occurred in the setting of a supraspinatus intramuscular lipoma demonstrated on shoulder MRI. This was managed operatively with a combined arthroscopic and open approach to allow performance of a bursectomy, debridement of mild acromioclavicular joint degeneration and lipoma excision. The patient was discharged on the first post-operative day. He was managed in a sling for 4 weeks with a graduated exercise program over the first 12 weeks with full shoulder strength and function maintained at 12 months.

DISCUSSION: Lipoma as a cause of SAIS is rare but an important diagnosis that needs to be considered in the preoperative evaluation of SAIS to guide appropriately targeted surgical management.

CONCLUSION: This case reinforces the diversity of pathologies in SAIS and the breadth of differential diagnoses that need to be considered when evaluating and determining the appropriate surgical approach to maximise chance of symptom resolution in SAIS.

© 2018 The Authors. Published by Elsevier Ltd on behalf of IJS Publishing Group Ltd. This is an open access article under the CC BY-NC-ND license (<http://creativecommons.org/licenses/by-nc-nd/4.0/>).

1. Introduction

Shoulder pain is a common musculoskeletal complaint, often presenting as subacromial impingement syndrome (SAIS), which encompasses a spectrum of pathologies and is not an isolated entity [1,2]. It includes any anatomical and functional anomaly that results in encroachment on the subacromial tissues causing pain, typically on elevation with impaired shoulder function [3]. Management options include conservative treatment measures and operative management for failure of resolution [4]. SAIS is typically diagnosed clinically but further evaluated and confirmed using shoulder X-rays, dynamic shoulder ultrasound, with local anaesthetic and steroid injection to the bursa often used to confirm the diagnosis. These investigations however will not always determine who will respond to conservative management and who will require surgical management [5].

We present a rare case reported in line with the SCARE criteria where failure of conservative treatment led to an MRI that uncovered a lesion associated with SAIS, unlikely to improve with further non-operative management [6]. This facilitated operative planning, resulting in combined arthroscopic and open operative management, with complete resolution of his symptoms.

2. Presentation of case

A 40 year old, right hand dominant, sales manager presented with a 3 year history of right shoulder tip pain with limited abduction to 30°, external rotation to 45° with preserved internal rotation and forward flexion. He had a painful arc with positive Neers and Hawkins-Kennedy signs for impingement. Plain radiographs failed to reveal a cause for the patient's symptoms, showing only mild acromioclavicular joint degenerative changes and a type 2 acromion with no subacromial spur. Shoulder ultrasound showed normal appearing rotator cuff tendons with a trace of fluid in the subacromial bursa and bursal bunching on shoulder abduction.

Following six months of failed conservative management a 3-T MRI (Trio, Siemens Medical Systems, Erlangen, Germany) was per-

* Corresponding author at: University Hospital Geelong, Barwon Health, Geelong, VIC, 3228, Australia.

E-mail address: jgreenhalgh@barwonhealth.org.au (J. Greenhalgh).

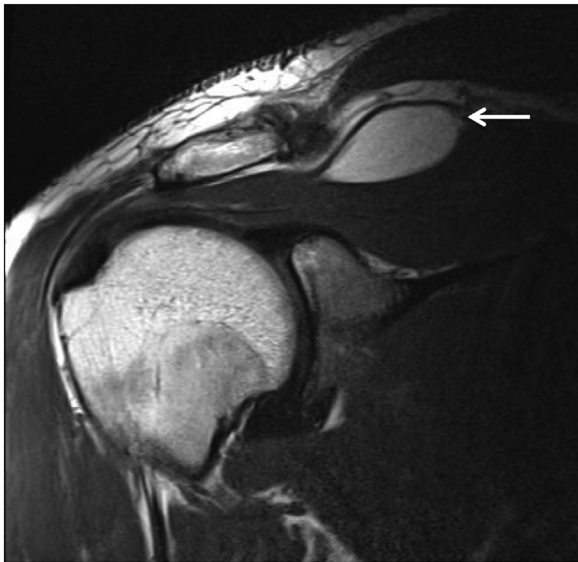

Fig. 1. Coronal Oblique Proton Density Image demonstrates an elliptical intramuscular mass (white arrow) in the superior aspect of the right supraspinatus muscle. The signal is homogeneous and identical to subcutaneous fat signal.

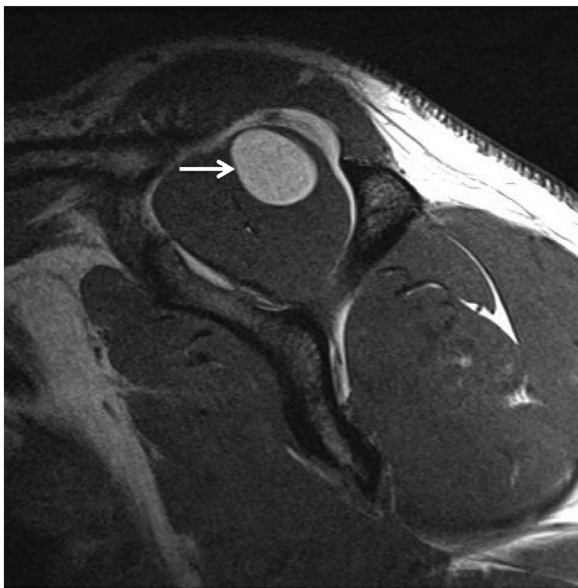

Fig. 2. Sagittal Oblique T1 weighted image demonstrates the fat signal mass within the supraspinatus muscle belly (arrow).

formed to further evaluate the patient's shoulder and assess for rotator cuff tears not evident on the ultrasound. The MRI identified a $35 \times 17 \times 18$ mm ovoid intramuscular mass lesion within the superior aspect of the supraspinatus muscle (Fig. 1). The lesion followed fat signal on all sequences including fat saturated sequences and did not contain any thick septations or nodular components, consistent with a benign intramuscular lipoma (Fig. 2). Co-existing pathology demonstrated on the MRI included a small intrasubstance delamination tear of the infraspinatus tendon and moderate acromioclavicular joint degeneration with an inferior acromioclavicular joint osteophyte causing mild impingement on the supraspinatus.

A shoulder arthroscopy was performed under general anaesthesia with the patient in the lateral position, with the arm held in a Spider 2 (Smith and Nephew) traction device. The arthroscopy was undertaken through standard posterior, anterior and lateral por-

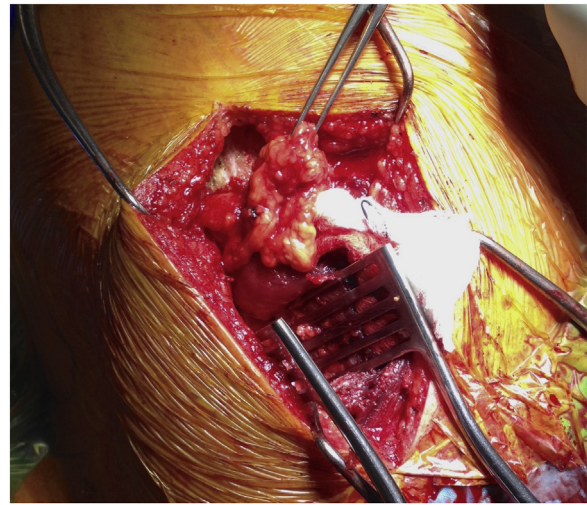


Fig. 3. Intra-operative view with the lipoma partially dissected out from the supraspinatus muscle belly via a supraspinous approach.

tals. There was no rotator cuff, biceps tendon or articular pathology. There was bursal impingement on abduction, with a corresponding subacromial lesion. A bursectomy was undertaken and mild acromioclavicular joint degeneration was noted and debrided.

An open approach to the intramuscular lipoma was undertaken in the same position. The lipoma was approached through an incision superior to the spine of the scapula with reflection of the trapezius off the scapula spine. The supraspinatus was exposed and a small perimuscular component of the lipoma was excised prior to excision of the intramuscular lipoma in the substance of the body of supraspinatus via a longitudinal split in the muscle, taking care to protect the suprascapular nerve (Fig. 3). The trapezius was repaired with transosseous sutures to the scapula and a local anaesthetic wound infusion catheter was placed deep to trapezius for post-operative regional pain relief. The patient was discharged on the first post-operative day, with a shoulder immobiliser sling with the anaesthetic pump removed on the second post-operative day as an outpatient. The affected shoulder was kept in a supportive sling for 4 weeks to protect the trapezius repair, coming out to do pendular and active assisted range of motion exercises. A graduated strengthening program was followed over twelve weeks and return to activity thereafter. The patient was followed up until 12 months post operatively and was asymptomatic with normal shoulder strength and function at the final review.

The macroscopic specimen is shown in Fig. 4. Histological examination revealed a $35 \times 20 \times 15$ mm lipomatous nodule enclosed by a thin rim of muscle with fat cells infiltrating between muscle fibres consistent with the appearance of an intramuscular supraspinatus lipoma. The appearance of the extramuscular lesion revealed mature adipose tissue with intersecting collagenous trabeculae and muscular vessels consistent with benign fatty tissue.

3. Discussion

Despite lipomas being the most common benign mesenchymal lesion they are usually superficial, are painless and of little clinical significance [7,8]. This case highlights how infrequently lipomas can be located in deeper tissue planes and can become clinically significant in the setting of compression of local tissue structures. Lipoma as a cause of SAIS is rare but an important consideration. Nine other cases of SAIS in the setting of a benign lipoma have been reported in the literature and only two of which have involved an intramuscular lipoma within the supraspinatus muscle [9–17]. They have all been diagnosed on MRI imaging of the shoulder following

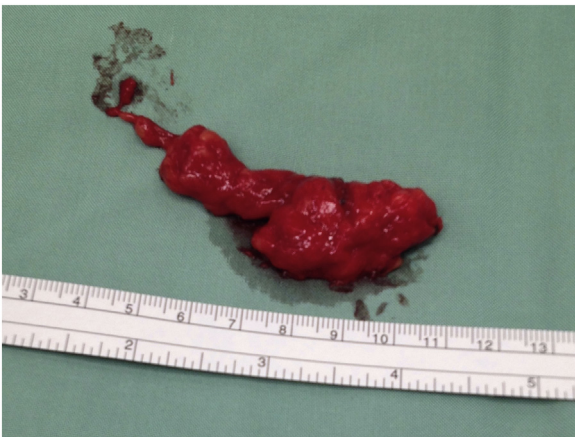

Fig. 4. Post-operative macroscopic image of excised intramuscular lipoma from the substance of the body of supraspinatus.

a failed period of conservative management and in the planning stages for operative management. This case is the first case reported that has utilised combined arthroscopic and open operative management, to address both the subacromial impingement as well as the excision of an intramuscular lipoma within the supraspinatus muscle, with normal function at 12-month review.

This case reinforces the diversity of underlying pathologies in SAIS and how rare causes need to be considered in the preoperative evaluation of SAIS to guide appropriate treatment. The MRI findings formed the basis for combined arthroscopic and open operative management enabling treatment of both subacromial and intramuscular pathology. The combined approach would not have otherwise been performed, risking incomplete resolution of the impingement symptoms and potential secondary surgery.

4. Conclusion

Intramuscular lipoma is an uncommon cause of SAIS, however is a pathology requiring consideration when there is a discrepancy between patient's presentation and simple imaging. This case reinforces the diversity of pathologies in SAIS and the breadth of differential diagnoses that need to be considered when evaluating and determining the appropriate surgical approach to maximise chance of symptom resolution in SAIS.

Conflict of interest

The authors have no financial conflicts of interest.

Funding

The research had no sources of funding.

Ethical approval

The case report has been registered with and complies with the ethical requirements of the Barwon Health Research Ethics Governance Integrity Unit. Registration no. 18/13.

Consent

Written informed consent was obtained from the patient for publication of this case report and accompanying images. A copy

of the written consent is available for review by the Editor-in-Chief of this journal on request.

Author contribution

Professor Richard Page conducted patient care and performed the operation. All authors contributed to conception and design of the study. Associate Professor Andrew Whan reviewed diagnostic imaging and provided relevant written contribution. Dr Jarrod Greenhalgh performed literature review and completed primary drafting. All authors provided editions to final draft. The finalised case report was read and approved by all authors.

Registration of research studies

The research project was registered with the Research Registry with the following UIN: researchregistry3705.

Guarantor

Professor Richard Page.

References

- [1] H. Britt, G.C. Miller, J. Charles, J. Henderson, C. Bayram, Y. Pan, L. Valenti, C. Harrison, J. O'Halloran, S. Fahridin, General Practice Activity in Australia 2009–10. General Practice Series no. 27. Cat. No. GEP 27, AIHW, Canberra, 2010, pp. 1–199.
- [2] M.C. Koester, M.S. George, J.E. Kuhn, Shoulder impingement syndrome, *Am. J. Med.* 118 (January (5)) (2005) 452–455.
- [3] S. Simons, D. Kruse, J.B. Dixon, Shoulder impingement syndrome, in: D.S. Basow (Ed.), Up-to-Date [Database on the Internet], UpToDate, Waltham (MA), 2016 [cited 15 December 2016]. Available from: <http://www.uptodate.com>.
- [4] C. Hawk, A.L. Minkalis, R. Khorsan, C.J. Daniels, D. Homack, J.A. Gliedt, J.A. Hartman, S. Bhalerao, Systematic review of nondrug, non-surgical treatment of shoulder conditions, *J. Manipulat. Physiol. Ther.* 40 (5) (2017) 293–319.
- [5] A. TaheriAzam, M. Sadatsafavi, A. Moayyeri, Outcome predictors in nonoperative management of newly diagnosed subacromial impingement syndrome: a longitudinal study, *Med. Gen. Med.* 7 (February (1)) (2005) 63.
- [6] R.A. Agha, A.J. Fowler, A. Saetta, I. Barai, S. Rajmohan, D.P. Orgill, for the SCARE Group, The SCARE statement: consensus-based surgical case report guidelines, *Int. J. Surg.* 34 (October) (2016) 180–186.
- [7] C.D.M. Fletcher, J.A. Bridge, P.C.W. Hogendoorn, F. Mertens, WHO Classification of Soft Tissue Tumours, IARC Press, 2013.
- [8] J.R. Goldblum, A.L. Folpe, S.W. Weiss, *Soft Tissue Tumors*, 6th ed., Elsevier, New York, 2014, pp. 443–483.
- [9] A.P. Conesa, C.V. Aznar, M.R. Herrera, F.A. Lopez-Prats, Arthroscopic marginal resection of a lipoma of the Supraspinatus muscle in the subacromial space, *Arthrosc. Tech.* 4 (August (4)) (2015) 371–374.
- [10] M. Lenza, M.V. Lenza, E.F. Carrerra, M. Ferretti, Subdeltoid lipoma causing shoulder impingement syndrome—a case report, *Einstein* 12 (3) (2014) 351–354.
- [11] J.C. Murray, S. Pelet, Subacromial impingement syndrome caused by a voluminous subdeltoid lipoma, *Case Rep. Orthop. Res.* 2014 (February) (2014) 1–3.
- [12] M. Ui, K. Ogawa, Subdeltoid lipoma: a case with symptoms mimicking glenohumeral instability and subacromial impingement, *Orthopedics* 33 (June (6)) (2010) 443.
- [13] L. Ferrari, P. Haynes, J. Mack, G.S. DiFelice, Intramuscular lipoma of the supraspinatus causing impingement syndrome, *Orthopedics* 32 (August (8)) (2009).
- [14] J. Martinez, J. Mena, Lipoma of the supraspinatus muscle causing impingement syndrome: a case report, *J. Shoulder Elbow Surg.* 18 (2009) 3–5.
- [15] J. Relwani, W. Ogufero, S. Orakwe, Subacromial lipoma causing impingement syndrome of the shoulder: a case report, *J. Shoulder Elbow Surg.* 12 (2) (2003) 202–203.
- [16] J. Warner, N. Madsen, C. Gerber, Intramuscular lipoma of the deltoid causing shoulder pain. Report of two cases, *Clin. Orthop. Relat. Res.* 253 (April) (1990) 110–112.
- [17] J.T. Rohrbough, C.M. Jobe, Subdeltoid lipoma presenting as subluxation of the glenohumeral joint, *J. Shoulder Elbow Surg.* 4 (3) (1995) 225–227.

Open Access

This article is published Open Access at sciendo.com. It is distributed under the [IJSCR Supplemental terms and conditions](#), which permits unrestricted non commercial use, distribution, and reproduction in any medium, provided the original authors and source are credited.