

A multicenter evaluation of a new EUS core biopsy needle: Experience in 200 patients

Douglas G. Adler, V. Raman Muthusamy¹, Dean S. Ehrlich¹, Gulshan Parasher², Nirav C. Thosani³, Ann Chen⁴, Jonathan M. Buscaglia⁵, Anoop Appannagari⁵, Eduardo Quintero⁵, Harry Aslanian⁶, Linda Jo Taylor, Ali Siddiqui⁷

Department of Gastroenterology and Hepatology, University of Utah School of Medicine, Salt Lake City, Utah, ¹Department of Gastroenterology and Hepatology, University of California, Los Angeles, ⁴Department of Gastroenterology and Hepatology, Stanford Health Care, Stanford, California, ²Department of Gastroenterology and Hepatology, University of New Mexico, Albuquerque, New Mexico, ³Department of Gastroenterology and Hepatology, Memorial Hermann Hospital, Houston, Texas, ⁵Department of Gastroenterology and Hepatology, Stony Brook School of Medicine, Stony Brook, New York, ⁶Department of Gastroenterology and Hepatology, Yale School of Medicine, New Haven, Connecticut, ⁷Department of Gastroenterology and Hepatology, Thomas Jefferson University, Philadelphia, Pennsylvania, USA

ABSTRACT

Background and Objectives: We present a multicenter study of a new endoscopic ultrasound-guided fine-needle biopsy (EUS-FNB) needle (Acquire, Boston Scientific, Natick, MA). The aim of the study was to analyze the needle's clinical performance when sampling solid lesions and to assess the safety of this device. **Methods:** We performed a multicenter retrospective study of patients undergoing EUS-FNB during July 1–November 15, 2016. **Results:** Two hundred patients (121 males and 79 females) underwent EUS-FNB of solid lesions with the Acquire needle. Lesions included solid pancreatic masses ($n = 109$), adenopathy ($n = 45$), submucosal lesions ($n = 34$), cholangiocarcinoma ($n = 8$), liver lesions ($n = 6$), and other ($n = 8$). Mean lesion size was 30.6 mm (range: 3–100 mm). The mean number of passes per target lesion was 3 (range: 1–7). Rapid onsite cytologic evaluation (ROSE) by a cytologist was performed in all cases. Tissue obtained by EUS-FNB was adequate for evaluation and diagnosis by ROSE in 197/200 cases (98.5%). Data regarding the presence or absence of a core of tissue obtained after EUS-FNB were available in 145/200 procedures. In 131/145 (90%) of cases, a core of tissue was obtained. Thirteen out of 200 patients (6.5%) underwent some form of repeat EUS-based tissue acquisition after EUS-FNB with the Acquire needle. There were no adverse events. **Conclusion:** Overall, this study showed a high rate of tissue adequacy and production of a tissue core with this device with no adverse events seen in 200 patients. Comparative studies of different FNB needles are warranted in the future to help identify which needle type and size is ideal in different clinical settings.

Key words: Acquire, EUS, fine-needle biopsy, lesions, tissue core

This is an open access journal, and articles are distributed under the terms of the Creative Commons Attribution-NonCommercial-ShareAlike 4.0 License, which allows others to remix, tweak, and build upon the work non-commercially, as long as appropriate credit is given and the new creations are licensed under the identical terms.

For reprints contact: reprints@medknow.com

How to cite this article: Adler DG, Muthusamy V, Ehrlich DS, Parasher G, Thosani NC, Chen A, *et al.* A multicenter evaluation of a new EUS core biopsy needle: Experience in 200 patients. *Endosc Ultrasound* 2019;8:99-104.

Access this article online

Quick Response Code:



Website:

www.eusjournal.com

DOI:

10.4103/eus.eus_53_17

Address for correspondence

Dr. Douglas G. Adler, Department of Gastroenterology and Hepatology, University of Utah School of Medicine, Huntsman Cancer Center, 30N 1900E 4R118, Salt Lake City, Utah 84132, USA. E-mail: douglas.adler@hsc.utah.edu

Received: 2017-01-24; **Accepted:** 2017-07-03; **Published online:** 2018-04-04

INTRODUCTION

EUS-FNA is a well-established technique to evaluate solid and cystic lesions within or adjacent to the gastrointestinal tract. It is widely regarded as safe, accurate, and has a low complication rate.^[1,2] Despite extensive research and clinical experience, it has been difficult to identify meaningful differences between different FNA needle types and sizes from different manufacturers.^[3]

Recent years have seen the development and commercial release of several fine-needle biopsy (FNB) needles, which are designed primarily to obtain core tissue samples. These FNB needles allow acquisition of larger tissue samples which in turn are helpful for both histologic and cytologic evaluation. To date, there have only been limited studies on EUS-guided FNB (EUS-FNB) needles with regard to their uses, safety, and tissue acquisition capabilities.

We present a multicenter study of a new EUS-FNB needle (Acquire, Boston Scientific, Natick, MA). The aim of the study was to analyze the needle's clinical performance when sampling solid lesions and to assess the safety of this device.

METHODS

We performed a multicenter and retrospective study of patients undergoing EUS-FNB with the Acquire needle between July 1 and November 15, 2016. Patients were included if they were >18 years of age and had a solid lesion identified that warranted biopsy. Patients were excluded if they were <18 years of age, pregnant, prisoners, or were undergoing EUS-guided biopsy of a cystic lesion. Liver biopsies to evaluate for parenchymal disease were excluded from the study.

Needle tip echogenicity was graded on a scale of 1–4, with 1 being the most echogenic and 4 being the least echogenic. Nearly 95% of users rated the needle tip echogenicity as a 1 and 5% rated it as a 2. Ease of puncture was graded on a scale of 1–4, with 1 being the easiest and 4 being the most difficult. These factors were assessed in regards to the needle under study and not in comparison to other needles.

Tissue was felt to be adequate if a cytologist could render a final diagnosis based on the supplied tissue. The presence of a core was assessed grossly and

microscopically by the presence of a solid tissue core (not a clot) that produced histology when evaluated after formal processing by pathology.

An excel spreadsheet that enumerated data parameters for all patients was completed at each site. This spreadsheet included but was not limited to demographic information about the patients; the type, size, and location of the target lesion; the needle size, number of passes; and information about the tissue analysis including how passes were used (cytologic analysis, histologic analysis, or both), the presence or absence of ROSE, the adequacy of the specimen, and the final diagnosis; as well as the presence or absence of any adverse events.

The study was Institutional Review Board approved at all sites.

RESULTS

Over the study period, 200 patients (121 males and 79 females) with a mean age of 63 years underwent EUS-FNB of solid lesions with the Acquire needle [Table 1]. Some patients underwent biopsies of multiple sites during their procedures. Eight patients (4%) required EUS-FNB after a prior nondiagnostic EUS-FNA procedure. Seven patients (3.5%) underwent repeat EUS-FNB after a prior nondiagnostic EUS-FNB procedure. No data are available regarding the type or size of needle used in these nondiagnostic EUS-FNA and FNB procedures. One hundred and eighty-six patients underwent FNB with a 22-gauge needle and 14 patients underwent FNB with a 25-gauge needle. No patients underwent FNB with a 19-gauge needle as it was not available commercially at the time of the study.

Target lesions undergoing FNB included solid pancreatic masses ($n = 109$), adenopathy ($n = 45$), submucosal lesions ($n = 34$), cholangiocarcinoma ($n = 8$), liver lesions ($n = 6$), and other sites ($n = 8$) [Table 2]. Sixty-two pancreatic masses were located in the head of the gland, 3 were located in the uncinate process, 4 were located in the genu, 27 were located in the body, and 13 were located in the tail. Eleven pathologically enlarged nodes were located in the mediastinum, 7 were celiac nodes, 2 were gastrohepatic ligament nodes, 11 were porta hepatis nodes, 9 were peripancreatic nodes, and 3 were perirectal nodes. In two patients, the location of the adenopathy was not specified. One submucosal lesion

was in the esophagus, 24 were in the stomach, 2 were in the duodenum, and 7 were in the rectum.

The overall mean target lesion size was 30.6 mm (range: 3–100 mm). The mean number of passes per target lesion was 3 (range: 1–7).

The technique of tissue acquisition during the FNB procedure was left to the discretion of the individual endoscopists. The “slow pull” technique whereby the stylet was slowly withdrawn a distance of 6–12 inches during needle actuations was used in 74% of biopsies, a dry needle with a vacuum syringe was used in 22% of biopsies, and, in 4% of biopsies, the stylet was completely removed, and the needle was flushed with saline before starting actuations. In addition to the technique for needle biopsy utilized, the “fanning” approach to needle actuations was performed in 65/200 (32.5%) patients.

Ninety-four percent of users rated the ease of puncture as a 1 with 6% of users rating it a 2. Ease of needle actuation was graded on a scale of 1–4, with 1 being the easiest and 4 being the most difficult. Ninety-three percent of users rated the ease of needle actuation a 1 and 7% of users rated ease of needle actuation a 2.

ROSE by a cytologist was performed in all cases. Tissue obtained by EUS-FNB was felt to be adequate for evaluation and diagnosis by ROSE in 197/200 cases (98.5%). Data regarding the presence or absence of a core of tissue obtained after EUS-FNB were available in 145/200 procedures. In 131/145 (90%) of cases, a core of tissue was obtained [Figures 1-3]. In 14/145 (10%) of cases, a visible core of tissue was not obtained. Thirteen out of 200 patients (6.5%) underwent some form of repeat EUS-based tissue acquisition after undergoing EUS-FNB with the Acquire needle.

Twelve patients (6%) had FNB samples sent for histologic analysis only. One hundred and three out of 200 (51.5%) patients had their samples divided between cytologic and histologic analysis, and 85/200 patients (42%) had their samples sent for evaluation by cytology only.

A final histologic diagnosis was available for 198/200 patients (99%). A final diagnosis of pancreatic adenocarcinoma was made in 86 patients (43%), pancreatic neuroendocrine tumor in 21 patients (10.5%),

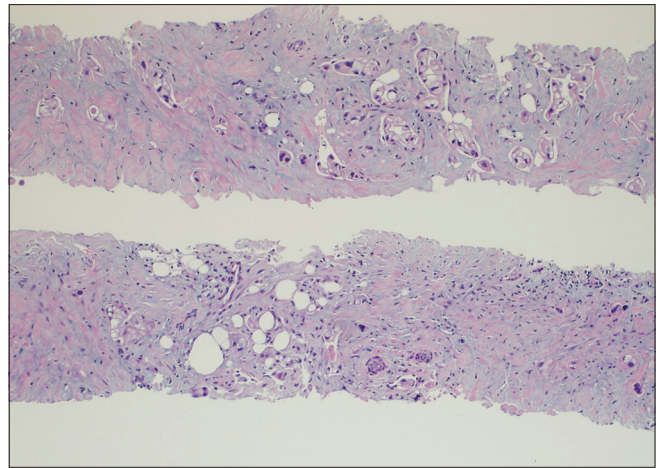


Figure 1. Cell block from an Acquire needle biopsy showing intact cores with infiltrating malignant glands and single cells, consistent with adenocarcinoma (H and E, $\times 10$)

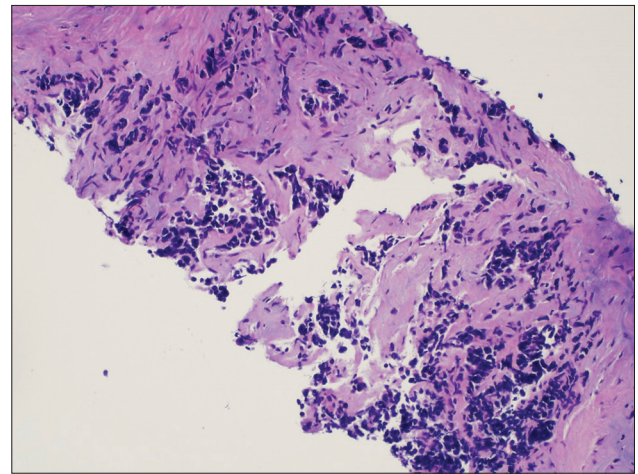


Figure 2. Cell block from an Acquire needle biopsy showing an intact core harboring malignant cells with scant cytoplasm and heavy crush artifact within a fibrous background. The morphology is suggestive of small cell (poorly differentiated) neuroendocrine carcinoma (H and E)

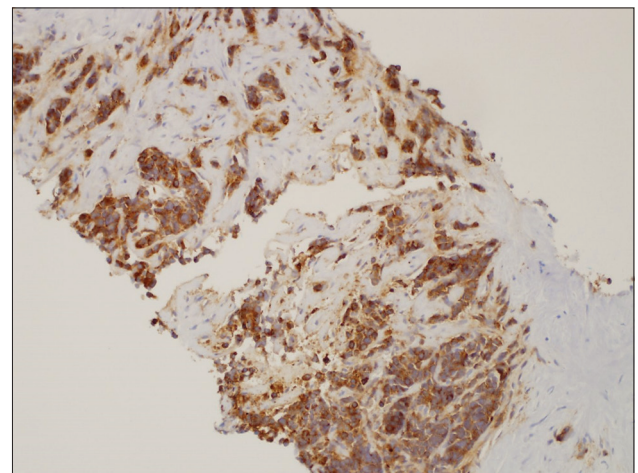


Figure 3. Photomicrograph of the same patient as Figure 2 cells showing diffuse cytoplasmic staining for synaptophysin, supporting the diagnosis of small cell carcinoma ($\times 10$)

Table 1. Demographics (total sample size=200)

	<i>n</i>
Age	
Mean±SD	63.025±14.54
Median	63
Range	82
Male, <i>n</i> (%)	
Female	79 (39.50)
Male	121 (60.50)

SD: Standard deviation

Table 2. Results (total sample size=200)

	Summary
Target lesions, <i>n</i> (%)	
Solid pancreatic masses	109 (0.55)
Head	62 (0.57)
Uncinate process	3 (0.03)
Genu	4 (0.03)
Body	27 (0.25)
Tail	13 (0.12)
Adenopathy	45 (0.23)
Mediastinum	11 (0.24)
Celiac	7 (0.16)
Gastrohepatic ligament	2 (0.04)
Porta hepatis	11 (0.24)
Peripancreatic	9 (0.20)
Perirectal	3 (0.07)
Not specified	2 (0.04)
Submucosal lesions	34 (0.17)
Esophagus	1 (0.03)
Stomach	24 (0.71)
Duodenum	2 (0.06)
Rectum	7 (0.21)
Cholangiocarcinoma	8 (0.04)
Liver lesions	6 (0.03)
Other sites	8 (0.04)
Target lesion (mean, range)	
Size	30.6 mm (3-100 mm)
Number of passes	3 (1-7)
Technique of tissue acquisition, <i>n</i> (%)	
Slow pull	0.74
Dry needle with vacuum syringe	0.22
Stylet removed and needle flushed with saline	0.04
Final diagnosis, <i>n</i> (%)	0.99
Pancreatic adenocarcinoma	86 (0.43)
Pancreatic neuroendocrine tumor	21 (0.105)
GIST	13 (0.065)
Lymphoma	5 (0.025)
Lesions metastases of established malignancies	11 (0.055)
No evidence of malignancy	39 (0.195)
Other (leiomyomas, lipomas, ectopic pancreas, and granulomatous disease)	23 (0.115)

GIST: Gastrointestinal stromal tumors

gastrointestinal stromal tumor in 13 patients (6.5%), and lymphoma in five patients (2.5%). In 11 patients (5.5%),

lesions were found to be metastases of established malignancies. Thirty-nine patients (19.5%) had no evidence of malignancy seen in their specimens and 23 patients (11.5%) had a variety of other diagnoses including leiomyomas, lipomas, ectopic pancreas, and granulomatous disease/sarcoidosis.

There were no adverse events reported in any patient undergoing EUS-FNB.

DISCUSSION

The introduction of FNB needles to clinical practice has produced a shift within the practice of EUS. Formerly, all lesions (with rare exceptions) were sampled by FNA and FNB was rarely performed in practice. An older core needle (TruCut, Cook Endoscopy, Winston Salem NC) has been commercially available for years and is an effective tool but never saw widespread adoption. This was likely related to somewhat cumbersome nature of the device and limited maneuverability of this needle when the echoendoscope is in a flexed position.¹⁴⁻⁷¹

A 2013 pilot study from our group on an early EUS-FNB needle (ProCore, Cook Endoscopy, Winston Salem, NC) that evaluated 36 patients (18 of whom underwent EUS-FNA and 18 of whom underwent EUS-FNB in matched lesion types) showed that the mean number of passes to achieve adequacy varied between the groups (2.94 for the standard 22-gauge needle group *vs.* 2.11 for the core needle group [$P = 0.03$]) with no meaningful difference in case duration between needle groups. Overall, the two needle groups in this study demonstrated similar results for the cytology parameters, amount of diagnostic cell block material, adequacy, and accuracy. Another study of this needle reached similar results when comparing it to standard FNA needles.¹⁸¹ Additional data regarding this needle have been more encouraging.¹⁹⁻¹¹¹

A different pilot study from our group published in 2016 using a different FNB needle (Shark Core, Covidien, Dublin, Ireland) evaluated thirty patients, 15 of whom underwent EUS-FNA and 15 of whom underwent EUS-FNB in matched lesion types. The core needle required fewer needle passes to obtain diagnostic adequacy than the standard needle ($\chi^2(1) = 11.3, P < 0.001$). The core needle required 1.5 passes to reach adequacy, whereas the standard needle required three passes. For cases with cell

blocks, the core needle produced diagnostic material in 85% of cases (95% confidence interval (CI): 54–98), whereas the standard needle produced diagnostic material in 38% of the cases (95% CI: 9–76). The core needle produced actual tissue cores 82% of the time (95% CI: 48–98) and the standard needle produced no tissue cores (95% CI: 0–71) ($P = 0.03$).^[8]

A larger multicenter study of the SharkCore needle was published in 2016. This was a multicenter, retrospective study of 226 patients. Median size of all lesions (mm): 26 (2–150). Overall, a final cytologic diagnosis was rendered in 81% of specimens with a median of three passes. When ROSE was used, diagnostic yield was 126/149 (85%) with a median number of three passes; without ROSE, diagnostic yield was 31/45 (69%, $P = 0.03$) with a median of three passes. Overall, a diagnosis was rendered in 130/147 (88%) specimens with a median of two passes. The yield of this needle was felt to be high with a low number of passes.^[9]

This study is the first analysis to date of a new EUS-FNB needle. The Acquire needle is similar in design to the SharkCore needle but has differences as well. The SharkCore and the Acquire needles both have an opposing bevel design. The SharkCore needle has two opposing bevels, whereas the Acquire needle has three opposing bevels. By means of contrast, the ProCore needle has a laterally placed, reverse facing bevel. Clearly, this reflects the fact that the ideal design for an FNB needle is still unknown, and to date, no prospective studies comparing different FNB needle types exist.

Our study included 200 patients from seven centers and all procedures were performed by experienced endosonographers. As would be expected, solid pancreatic masses and concerning lymph nodes were the two most common targets for FNB. The mean number of needle passes was three procedures, similar to that seen in other studies of FNB.

One interesting facet of this study was that it reveals that the so-called “slow pull” technique of withdrawing the stylet during needle actuations was the most common method utilized, encompassing 74% of the procedures. Limited published data to date suggest that this technique may increase diagnostic yield and accuracy when performing FNA and FNB.^[10,11] Still, it must be said that, at the present time, the ideal method for operating FNB needles remains unknown.

Our study produced a 90% rate of visible tissue cores, similar to or slightly better than that seen in other studies of FNB needles.^[4,7,12] It should be noted that the presence of a visible core of tissue does not always correlate with a true histologic core, as the visualize core may contain tissue distortion, blood clot, or necrosis. Adequate tissue was obtained for analysis in just under 98% of patients.

Strengths of this study include its multicenter nature and multiple experienced endosonographers performing the studies. Limitations include the retrospective nature of the study and the lack of uniform pathologic specimen processing at different sites.

Our study utilized the FNB needle in consecutive patients with solid lesions of varying kinds. It is unclear at this time if FNB is warranted in all solid lesions or if this should be reserved for patients suspected of having uncommon or unusual lesions wherein additional tissue or histologic evaluation would be warranted. It is the practice at many institutions to utilize FNB needles for all solid lesions as was done in the context of this study as the tissue obtained is felt to be of larger quantity than what can be obtained through routine FNA. The cost of FNB needles, including the Acquire needle, is, in general, higher than for FNA needles from the same vendors. We suspect that, as the cost of FNB needles fall, they may become the standard needle for EUS-guided tissue acquisition of solid lesions, leaving FNA needles to be predominately used for the aspiration of cystic lesions, etc.

Overall, this study showed a high rate of tissue adequacy and production of a tissue core with this device with no adverse events seen in 200 patients. Comparative studies of different FNB needles are warranted in the future to help identify which needle type and size is ideal in different clinical settings.

CONCLUSION

Overall, this study showed a high rate of tissue adequacy and production of a tissue core with this device with no adverse events seen in 200 patients. Comparative studies of different FNB needles are warranted in the future to help identify which needle type and size is ideal in different clinical settings.

Financial support and sponsorship

Nil.

Conflicts of interest

There are no conflicts of interest.

REFERENCES

1. Folkers ME, Adler DG. Endoscopic ultrasound for non-gastroenterologists: What you need to know. *Hosp Pract* 2011;39:56-69.
2. Adler DG, Jacobson BC, Davila RE, et al. ASGE guideline: Complications of EUS. *Gastrointest Endosc* 2005;61:8-12. Erratum in: *Gastrointest Endosc* 2005;61:502.
3. Affolter KE, Schmidt RL, Matynia AP, et al. Needle size has only a limited effect on outcomes in EUS-guided fine needle aspiration: A systematic review and meta-analysis. *Dig Dis Sci* 2013;58:1026-34.
4. Levy MJ, Wiersema MJ. EUS-guided Trucut biopsy. *Gastrointest Endosc* 2005;62:417-26.
5. Ginès A, Wiersema MJ, Clain JE, et al. Prospective study of a Trucut needle for performing EUS-guided biopsy with EUS-guided FNA rescue. *Gastrointest Endosc* 2005;62:597-601.
6. Thomas T, Kaye PV, Ragunath K, et al. Efficacy, safety, and predictive factors for a positive yield of EUS-guided Trucut biopsy: A large tertiary referral center experience. *Am J Gastroenterol* 2009;104:584-91.
7. Lee JH, Choi KD, Kim MY, et al. Clinical impact of EUS-guided Trucut biopsy results on decision making for patients with gastric subepithelial tumors ≥ 2 cm in diameter. *Gastrointest Endosc* 2011;74:1010-8.
8. Adler DG, Witt B, Chadwick B, et al. Pathologic evaluation of a new endoscopic ultrasound needle designed to obtain core tissue samples: A pilot study. *Endosc Ultrasound* 2016;5:178-83.
9. DiMaio CJ, Kolb JM, Benias PC, et al. Initial experience with a novel EUS-guided core biopsy needle (SharkCore): Results of a large North American multicenter study. *Endosc Int Open* 2016;4:E974-9.
10. Chen JY, Ding QY, Lv Y, et al. Slow-pull and different conventional suction techniques in endoscopic ultrasound-guided fine-needle aspiration of pancreatic solid lesions using 22-gauge needles. *World J Gastroenterol* 2016;22:8790-7.
11. Nakai Y, Isayama H, Chang KJ, et al. Slow pull versus suction in endoscopic ultrasound-guided fine-needle aspiration of pancreatic solid masses. *Dig Dis Sci* 2014;59:1578-85.
12. Lee JH, Cho CJ, Park YS, et al. EUS-guided 22-gauge fine needle biopsy for the diagnosis of gastric subepithelial tumors larger than 2 cm. *Scand J Gastroenterol* 2016;51:486-93.