

Case report of a bilateral adrenal myelolipoma associated with Cushing disease

Se Yoon Park, MD^a, Mi Kyung Kwak, MD^{a,c}, Hye Jeong Kim, MD^a, Hyeong Kyu Park, MD^a, Kyo-II Suh, MD^a, Myung Hi Yoo, MD^a, So Young Jin, MD^b, Sumi Yun, MD^d, Dong Won Byun, MD^{a,*}

Abstract

Rationale: Adrenal myelolipomas are rare benign tumors, composed of a variable mixture of mature adipose tissue and hematopoietic tissue. These tumors are frequently detected incidentally and are usually asymptomatic, and hormonally inactive.

Patient Concerns: During a routine health checkup, a 52-year-old man was found to have a tumor on the bilateral adrenal glands. Abdominal computed tomography revealed a well-defined, heterogeneously enhanced bilateral adrenal mass, suggesting a myelolipoma.

Diagnoses: The hormonal evaluation revealed adrenocorticotropic hormone (ACTH) dependent Cushing syndrome.

Interventions: The patient underwent left adrenalectomy, and transsphenoidal resection of a pituitary mass. The final diagnosis was adrenal myelolipoma associated with Cushing disease.

Outcomes: Growth of right adrenal myelolipoma was detected during the 7-year follow-up. There were enhancing pituitary lesions in repeat magnetic resonance imaging of the sellar region, which implies persistent or recurrent pituitary adenoma. This case reinforces relationship between Cushing disease and adrenal myelolipoma.

Lessons: To the best of our knowledge, this is the first reported pathologically confirmed bilateral adrenal myelolipoma associated with Cushing disease. This report supports the idea that ACTH is associated with the development of adrenal myelolipoma.

Abbreviations: ACTH = adrenocorticotropic hormone, CT = computed tomography, IPSS = inferior petrosal sinus sampling, MRI = magnetic resonance imaging.

Keywords: adrenal myelolipoma, Cushing disease, pituitary adenoma

1. Introduction

Adrenal myelolipomas are rare benign tumors, composed of a variable mixture of mature adipose tissue and hematopoietic tissue. It usually occurs as a single, unilateral lesion, ranging from 1 to 34 cm.^[1,2] Adrenal myelolipoma is found incidentally in 0.08% to 0.25% subjects during autopsy.^[3] Recently, myelolipomas are

increasingly detected in living patients by incidental imaging, such as ultrasonography, computed tomography (CT), and magnetic resonance imaging (MRI).^[4,5] Most adrenal myelolipomas do not show symptoms and are rarely reported with hormonal disorders such as Cushing syndrome, congenital adrenal hyperplasia, or aldosterone-producing adenoma.^[1,6] We incidentally found a suspected splenic mass by abdominal ultrasonography during a health checkup and through additional examination, confirmed bilateral adrenal myelolipomas associated with Cushing disease. The authors obtained approval from the institutional review board of Soonchunhyang University, Seoul Hospital, South Korea (2017-12-001), and informed consent was waived by the institutional review board.

2. Case presentation

A 52-year-old man was found to have a splenic mass by abdominal ultrasonography during a health checkup. An abdominal CT revealed bilateral adrenal masses that lead to the patient being hospitalized for additional examination. The patient had an operation for cerebral hemorrhage because of a car accident 22 years ago and was taking anticonvulsant medication (phenytoin 400 mg) because of epilepsy after this accident. Family history was unremarkable. Vital signs during the examination showed 140/80 mmHg blood pressure, 36.6°C body temperature, pulse rate of 80 beats/min and respiratory rate of 20 breaths/min. The patient's body weight was 130.2 lb, with a body mass index of 22.2 kg/m². The patient looked healthy and showed no cushingoid features. The abdominal mass was not palpable and hepatosplenomegaly was not observed.

Editor: Suman Srinivasa.

SYP and MKK contributed equally to this work.

This research was supported by the Soonchunhyang University Research Fund.

The authors declare no conflicts of interest.

Supplemental Digital Content is available for this article.

^a Division of Endocrinology and Metabolism, Departments of Internal Medicine,

^b Departments of Pathology, Soon Chun Hyang University College of Medicine,

^c Division of Endocrinology and Metabolism, Asan Medical Center, University of Ulsan College of Medicine, ^d Department of Diagnostic Pathology, Samkwang Medical Laboratories, Seoul, Korea.

* Correspondence: Dong Won Byun, Division of Endocrinology and Metabolism, Department of Internal Medicine, Soon Chun Hyang University College of Medicine, 657-58 Hannam-dong, Yonsan-gu, Seoul 140-743, Korea (e-mail: byundw@schmc.ac.kr).

Copyright © 2017 the Author(s). Published by Wolters Kluwer Health, Inc.

This is an open access article distributed under the Creative Commons Attribution-NoDerivatives License 4.0, which allows for redistribution, commercial and non-commercial, as long as it is passed along unchanged and in whole, with credit to the author.

Medicine (2017) 96:52(e9455)

Received: 20 May 2017 / Received in final form: 5 December 2017 / Accepted: 6 December 2017

<http://dx.doi.org/10.1097/MD.00000000000009455>

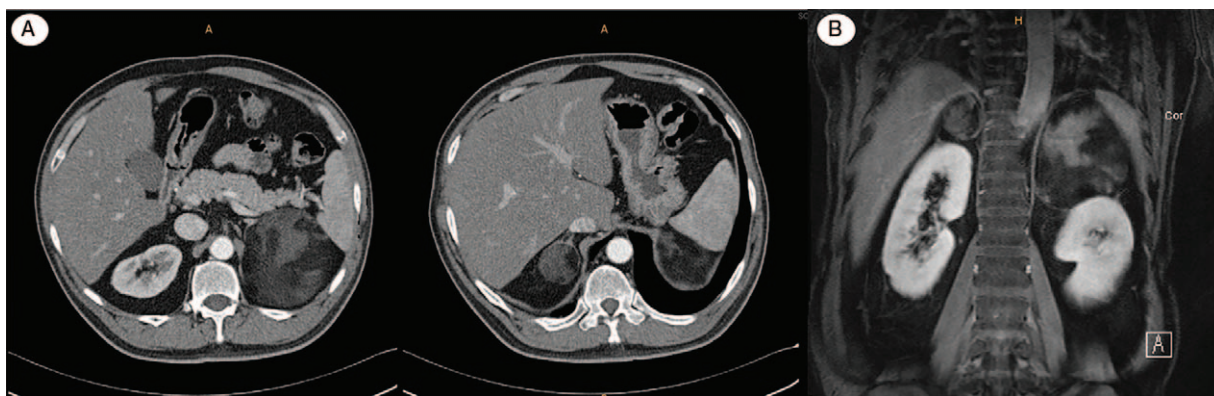


Figure 1. A, Abdomen and pelvic CT (C E) scan finding shows heterogenous fatty masses at both adrenal gland areas. B, Abdomen dynamic MRI (C E) scan finding shows $8.7 \times 8.0 \times 9.2$ cm left adrenal mass and $3.4 \times 3.0 \times 3.5$ cm right adrenal mass containing large amount of fat.

Follow-up abdominal CT and MRI imaging displayed heterogeneous, enhanced bilateral adrenal masses with large amounts of fat components (right: 3.4×3.2 and left: 8.2×8.1 cm) consistent with bilateral adrenal myelolipomas (Fig. 1A and B).

Hormonal evaluation revealed metanephrine 0.19 mg/d (normal; <1.3 mg/d), normetanephrine 0.32 mg/d, vanillylmandelic acid 2.10 mg/d (normal: <8 mg/d), epinephrine 2.41 μ g/d (normal; <50 μ g/d), norepinephrine 30.03 μ g/d (normal; 15–89 μ g/d), dehydroepiandrosterone-sulfate 30.45 μ g/dL (normal; 10–619 μ g/dL), adrenocorticotropic hormone (ACTH) 148.45 pg/mL (normal; 6–76 pg/mL), serum cortisol 31.99 μ g/mL (normal; 5–25 μ g/mL), and 24-hour urine cortisol excretion 245.44 μ g/d (normal; 0–70 μ g/d). The serum cortisol level was not suppressed by low-dose dexamethasone suppression test (23.30 μ g/mL). The suppressed level of serum cortisol following high-dose dexamethasone suppression test was 1.64 μ g/dL, whereas the 24-hour urine cortisol secretion was suppressed to 31.20 μ g/d.

To identify any other possible ACTH tumors, a thoracic CT scan was performed, subsequently showing no evidence of tumor. Pituitary MRI examination revealed no mass lesions in the sellar area. A bilateral inferior petrosal sinus sampling (IPSS) was performed and revealed that the blood ACTH level on the right IPSS was 255.8 pg/mL whereas the left IPSS was 25.63 pg/mL. The peripheral ACTH level was 30.92 pg/mL. In the baseline BIPSS, a ratio of central to peripheral ACTH of right side was 2

times more than normal. Therefore, these results strongly suggest pituitary secretion, that is, Cushing disease.^[7] Next, the patient underwent laparoscopic left adrenalectomy, and also received navigation guided pituitary tumor mass removal. The resected adrenal tumor appeared a well-defined, solid mass, measuring $9.0 \times 7.5 \times 6.0$ cm. The cut surface of tumor was yellow with multiple hemorrhagic foci (Supplemental Figure 1, <http://links.lww.com/MD/C43>). Histologically, it consisted of mature adipose cells interspersed with some scattered areas of hematopoietic cells, which are similar to those that form the normal bone marrow (Fig. 2A and B). This tumor was diagnosed as adrenal myelolipoma. Microscopic examination of the pituitary gland biopsy demonstrated proliferation of round to polygonal cells forming the acinar structures. This lesion showed disruption of the reticulin network. Immunohistochemical staining of ACTH tumor revealed Cushing disease (Fig. 3).

At day-3 after surgery (September 2010), the ACTH and serum cortisol levels were 45.34 pg/mL and 22.36 μ g/d, respectively. However, 5 months later (February 2011), follow-up examination found ACTH level was 306.7 pg/mL and serum cortisol level was 12.35 μ g/mL. The ACTH and serum cortisol levels were checked every 6 months for 7 years (September 2010 to April 2017). The size of right adrenal gland grew from 3.4 cm to 4.7 cm during a 5-year period (Supplemental Figure 2, <http://links.lww.com/MD/C43>). In April 2017, a follow-up sella MRI examination was performed. There was an approximately 2.5 mm sized

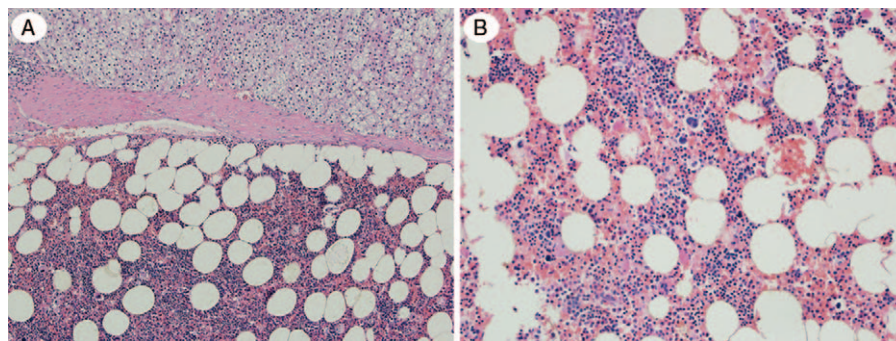


Figure 2. A, Microscopic findings of the left adrenal tumor. The tumor is separated from the hyperplastic adrenal cortex (upper) by thin fibrous capsule. B, The tumor consists of mature adipose cells interspersed with some scattered areas of hematopoietic cells, which is similar to those that form the normal bone marrow (A: H-E $\times 100$ and B: H-E $\times 200$).

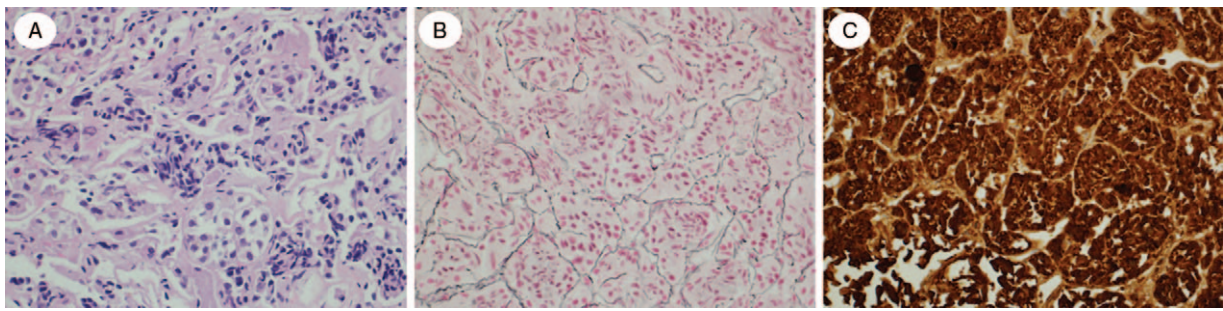


Figure 3. Microscopic findings of the pituitary gland biopsy. A, Pituitary gland biopsy demonstrated proliferation of round to polygonal cells. B, This lesion showed the disruption of reticulin network. C, Tumor cells are strongly positive for ACTH (A: H-E \times 400; B: Reticulin stain \times 400; C: Immunohistochemical stain for ACTH) \times 400).

enhancing lesion in the right side of the pituitary gland and an approximately 4.7 mm sized delayed enhancing lesion in the left pituitary gland.

3. Discussion

Adrenal myelolipoma is mostly a unilateral tumor without symptoms of endocrine disorder, with bilateral masses occurring in about 10% of cases.^[8,9] In 1886, Arnold first reported myeloid tissue in the adrenal gland^[10] and in 1905, Gierk described it as a tumor which has both adipose and hematopoietic tissue.^[11] Oberling first named it myelolipoma in 1929.^[11] Adrenal myelolipoma was generally found on the right side because this side of the adrenal gland is easier to detect during abdominal ultrasonography.^[8] In the past, it was usually found through biopsy, but improvements in medical imaging have increased the frequency of detection.

The pathogenesis of adrenal myelolipoma is highly controversial. Cushing disease has been suggested as a possible cause of adrenal myelolipoma due to prolonged stimulation of the adrenals by high levels of ACTH (Table 1).^[12–14] However, there was little information of the clinical course in patients with adrenal myelolipoma associated with Cushing disease who underwent pituitary tumor removal. We presented 7 years of follow-up for this patient after resection of the pituitary tumor. This case showed the growth of adrenal myelolipoma, with sustained high levels of ACTH. Recurrent or persistent pituitary adenoma was found in repeat sella MRI examination. The growth of the right adrenal myelolipoma, coupled with prolonged elevation of ACTH levels, reinforces the idea that Cushing disease may have a role in the pathogenesis of adrenal

myelolipoma (Supplemental Figure 2, <http://links.lww.com/MD/C43>). Most previous cases were observed in patients with chronic disease such as severe burn, hepatitis, arteriosclerosis, and malignant tumor. Selye and Stone^[15] reported that the zona reticularis of a mature rat's adrenal gland turned into myeloid tissue after being treated with testosterone and pituitary gland extracts. This supports the hypothesis that hyperstimulation caused by increased ACTH, owing to continuous stress, may be related to myelolipoma.^[12,16]

The ultrasound of an adrenal myelolipoma typically shows a hyperechoic mass with hypoechoic parts of myeloid tissue. However, diagnosis through imaging alone is difficult because of the tumor's nonuniform architecture. Calcification and hemorrhage also makes diagnosis through imaging difficult. A diagnosis of adrenal myelolipoma can be made through CT when visible fat is observed in the adrenal mass.^[12,17] MRI could be added when a differential diagnosis is required or a diagnosis is particularly difficult. Mass with fat has 2 classifications: adenoma, which has intracellular fat, and myelolipoma, which has macroscopic fat. Macroscopic fat shows loss of signal intensity in fat-saturated imaging. Signal of myelolipoma is high in nonfat-suppressed T1-weighted images. Signal loss of fat under fat suppression is useful for diagnosis.^[18]

Epilepsy increases adrenal cortical hormone secretion that can affect the hypothalamic-pituitary axis. Anti-epilepsy drugs, such as carbamazepine, phenytoin, and phenobarbitone, induce the liver P450 cytochrome enzyme system, which promotes the removal of steroids. These drugs also increase corticosteroid-binding globulin levels, but the total and unbound cortisol level has minimal change. Therefore, patients with Cushing syndrome can show false-positive dexamethasone suppression tests.^[19] In

Table 1
Reported cases of Cushing's disease with adrenal myelolipoma^[12–14].

References	Sex/Age	Side	Size (cm)	Treatment
Bennett et al ^[12]	M/18	Lt	20 \times 15 \times 8	NR
Yoshioka et al ^[13]	F/51	Lt	3 \times 2	Left adrenalectomy with TSA pituitary tumor remove
Chakraborty et al ^[14]	64/M	Both	Rt (1.3 \times 1.1) Lt (14.4 \times 11.4)	TSA pituitary tumor remove
Present case	M/58	Both	Rt (3.4 \times 3.0 \times 3.5) Lt (8.7 \times 8.0 \times 9.2)	Left adrenalectomy with TSA pituitary tumor remove

NR = not reported, TSA = transsphenoidal approach.

this case, the patient took phenytoin, raising the possibility of a false-positive test. However, ACTH secretion in a pituitary adenoma was observed in the tissue biopsy. Therefore, ACTH secreting pituitary adenoma was confirmed.

Surgical treatment for adrenal myelolipoma should be decided individually. Surgery should not be decided based on tumor size without symptoms when an adrenal myelolipoma is diagnosed through solely imaging. If the tumor becomes symptomatic or has increased size, then surgical treatment should be considered.^[8] Asymptomatic tumors over 10cm also need surgical treatment due to the possibility of spontaneous hemorrhagic shock. Perioperative glucocorticoid treatment is recommended after a successful surgery for Cushing disease. In the case of this patient, glucocorticoids were not administered during the perioperative periods.^[20] The patient did not report any symptoms of anorexia, nausea, or fatigue after resection of a pituitary adenoma. Serum cortisol levels were monitored and found to be normal 3 days postsurgery. This could be due to some portion of the pituitary adenoma remaining after resection.

In 1958, Plaut et al^[21] reported that Cushing syndrome was related to adrenal myelolipoma. Bennett et al performed bilateral adrenalectomy on a patient who had adrenal cortical hyperplasia. Thirteen years later, the patient was treated for excessive cortisol secretion symptoms. An adrenal mass was confirmed as the adrenal myelolipoma reappeared in this patient. In this case, the bilateral adrenal myelolipoma was accompanied by ACTH secreting pituitary tumors, with the myelolipoma possibly being a result of stimulation by ACTH.^[15] However, we could not confirm any direct effect by ACTH on the adrenal myelolipoma, as we lacked immunohistochemical data regarding antibodies of the ACTH receptors. Further studies are needed to clarify the neuroendocrine function of adrenal myelolipomas.

Adrenal myelolipoma with ACTH secreting pituitary adenoma was reported in 3 cases with unilateral tumor but only one case with bilateral tumors (Table 1).^[12–14] Adrenal myelolipoma related to hormonal imbalance is rare, with a bilateral case being even rarer. To the best of our knowledge, this is the first case report of pathologically-confirmed bilateral adrenal myelolipomas associated with Cushing disease. This case confers valuable information about the clinical course of adrenal myelolipoma associated with Cushing disease, and supports the notion that ACTH can be associated with the development of bilateral adrenal myelolipomas.

References

- [1] Umpierrez MB, Fackler S, Umpierrez GE, et al. Adrenal myelolipoma associated with endocrine dysfunction: review of the literature. *Am J Med Sci* 1997;314:338–41.
- [2] Han M, Burnett AL, Fishman EK, et al. The natural history and treatment of adrenal myelolipoma. *J Urol* 1997;157:1213–6.
- [3] Olsson CA, Krane RJ, Klugo RC, et al. Adrenal myelolipoma. *Surgery* 1973;73:665–70.
- [4] Musante F, Derchi LE, Bazzocchi M, et al. MR imaging of adrenal myelolipomas. *J Comput Assist Tomogr* 1991;15:111–4.
- [5] Vick CW, Zeman RK, Mannes E, et al. Adrenal myelolipoma: CT and ultrasound findings. *Urol Radiol* 1984;6:7–13.
- [6] Caliumi C, De Toma G, Bossini A, et al. A rare combination consisting of aldosterone-producing adenoma and adrenal myelolipoma in a patient with heterozygosity for retinoblastoma (RB) gene. *J Renin Angiotensin Aldosterone Syst* 2004;5:45–8.
- [7] Zampetti B, Grossrubatscher E, Dalino Ciaramella P, et al. Bilateral inferior petrosal sinus sampling. *Endocr Connect* 2016;5:R12–25.
- [8] Meyer A, Behrend M. Presentation and therapy of myelolipoma. *Int J Urol* 2005;12:239–43.
- [9] Kenney PJ, Wagner BJ, Rao P, et al. Myelolipoma: CT and pathologic features. *Radiology* 1998;208:87–95.
- [10] Rubin HB, Hirose F, Benfield JR. Myelolipoma of the adrenal gland. Angiographic findings and review of the literature. *Am J Surg* 1975;130:354–8.
- [11] Whittaker LD. Myelolipoma of the adrenal gland. Surgical removal. *Arch Surg* 1968;97:628–31.
- [12] Bennett BD, McKenna TJ, Hough AJ, et al. Adrenal myelolipoma associated with Cushing's disease. *Am J Clin Pathol* 1980;73:443–7.
- [13] Yoshioka M, Fujimori K, Wakasugi M, et al. Cushing's disease associated with adrenal myelolipoma, adrenal calcification and thyroid cancer. *Endocr J* 1994;41:461–6.
- [14] Chakraborty PP, Bhattacharjee R, Mukhopadhyay P, et al. Bilateral adrenal myelolipoma in Cushing's disease: a relook into the role of corticotropin in adrenal tumorigenesis. *BMJ Case Rep* 2016;doi: 10.1136/bcr-2016-14965.
- [15] Selye H, Stone H. Hormonally induced transformation of adrenal into myeloid tissue. *Am J Pathol* 1950;26:211–33.
- [16] Kanj HA, Noronha J, D'Aguillo AF, et al. Bilateral adrenal myelolipomas with Cushing's syndrome. *JAMA* 1988;259:3034–6.
- [17] Shin NY, Kim MJ, Chung JJ, et al. The differential imaging features of fat-containing tumors in the peritoneal cavity and retroperitoneum: the radiologic-pathologic correlation. *Korean J Radiol* 2010;11:333–45.
- [18] Elsayes KM, Mukundan G, Narra VR, et al. Adrenal masses: mr imaging features with pathologic correlation. *Radiographics* 2004;24(Suppl 1): S73–86.
- [19] Putignano P, Kaltsas GA, Satta MA, et al. The effects of anti-convulsant drugs on adrenal function. *Horm Metab Res* 1998;30:389–97.
- [20] Nieman LK, Biller BM, Findling JW, et al. Treatment of Cushing's syndrome: an endocrine society clinical practice guideline. *J Clin Endocrinol Metab* 2015;100:2807–31.
- [21] Plaut A. Myelolipoma in the adrenal cortex; myeloidipose structures. *Am J Pathol* 1958;34:487–515.