



Case Report

About an unusual penetrating cervical wound:Iron bar

Asmae Bazzout^{a,b,*}, Azzeddine Lachkar^{a,b}, Drissia Benfadil^{a,b}, Adil abdenbi Tsen^{a,b},
Fahd El ayoubi^{a,b}, Rachid Ghailan^{a,b}

^a University Hospital Center Mohamed VI, Oujda, Morocco

^b Faculty of Medicine and Pharmacy, Oujda, Morocco

ARTICLE INFO

Keywords:

Injury
Penetrating injuries
Neck
Iron bar

ABSTRACT

Introduction: The majority of cervical wounds are linked to aggressions and attempted autolysis by knives or firearms.

Case presentation: the story is about a 35 -year-old man admitted to the emergency room for a penetrating cervical wound following an accidental fall in the workplace. The extremely long iron bar (concrete)has penetrated its neck on the right side.upon admission, the patient was conscious,hemodynamically and respiratory stable without sensory-motor deficit.

Surgical exploration is urgently decided under general anesthesia, from wich the foreign body is successfully removed.A follow -up examination at 4 months was without particularity.

Discussion: Penetrating neck injuries caused by objects such as rods or iron bars pose a significantly high risk of serious neurological damage.

Penetrating neck injuries can be life-threatening and functional.the extent of the lesions must be assessed precisely before removing the foreign body.

Conclusion: we report an exceptional case of a penetrating neck wound caused by a concrete iron bar.treatment should always be multidisciplinary and giving priority to vital structures and function.

1. Introduction

The neck is an extremely complex anatomical region wich contains blood vessels, the aerodigestive tract, the cervical vertebrae and the spinal cord.

The penetration of this region by a foreign body can lead to fatal injuries. mortality rates from penetrating cervical trauma are estimated at 3% to 6% [1].

Advances in diagnostic imaging technology have moved management of penetrating neck lesions from mandatory exploration to selective management [2,3].

Hemodynamic stability and the presence of intracranial lesions remain crucial factors in assessing the patient's stability and prognosis.

Here, we present a penetrating cervical trauma caused by a concrete bar.the bar had entered above the SCM muscle at the upper edge of the outgoing thyroid cartilage next to the homolateral ear lobule.the metallic foreign body was successfully removed without complications. this case report in line with the SCARE Criteria [4].

2. Case report

The story is of a 35-year-old man admitted to the emergency room for a penetrating cervical wound following an accidental fall in the workplace (Fig. 1).

The extremely long iron rod (concrete) had penetrated his neck on the right side.on arrival at the emergency room, the patient was conscious,hemodynamically and respiratory stable, without sensory-motor deficit.

Surgical exploration is urgently decided under general anesthesia, the patient is positioned per the foreign body location, the simple exploration through the current bar, would be enough to remove it thoroughly with irrigation by sterile saline.(Figs. 2 and 3).

During the surgical procedure,a vascular surgeon is called upon to help if necessary. Formost,a surgeon on ENT Head and Neck Surgery (otorhinolaryngology) with adequate skill level and 9 years of experience.

The patient had received a combined course of Amoxicillin and clavulanic acid after removal of the foreign body during 7 days after

* Corresponding author. Route JamiaL kada Lot 28D C ? Mohamed VI N3, Oujda, 60003, Morocco.

E-mail address: asmaebazzout1@gmail.com (A. Bazzout).

<https://doi.org/10.1016/j.amsu.2021.01.035>

Received 29 November 2020; Received in revised form 11 January 2021; Accepted 11 January 2021

Available online 20 January 2021

2049-0801/© 2021 The Authors. Published by Elsevier Ltd on behalf of IJS Publishing Group Ltd. This is an open access article under the CC BY-NC-ND license

(<http://creativecommons.org/licenses/by-nc-nd/4.0/>).

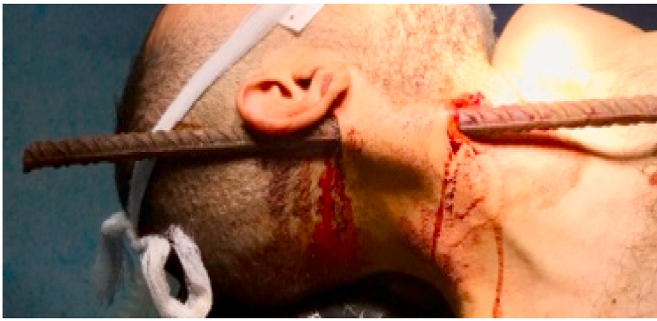

Fig. 1. Penetrating concrete bar on the right side.

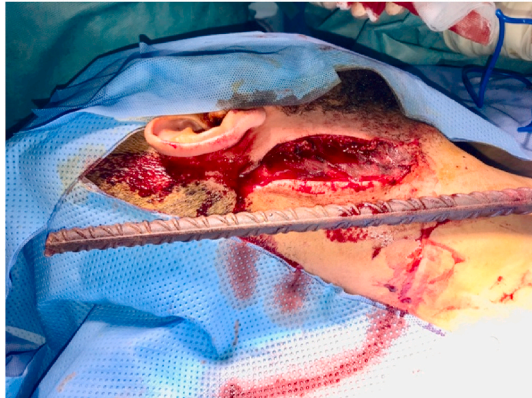


Fig. 2. The exploration found the SCM muscle intact with a protected vascular groove.

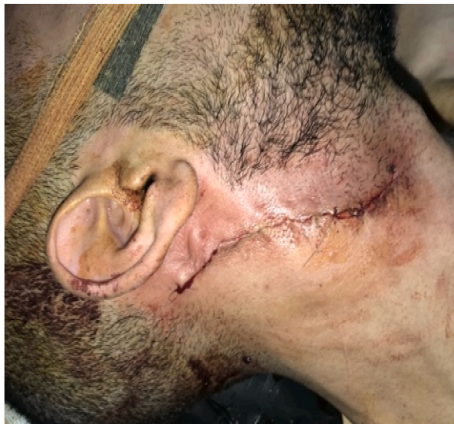

Fig. 3. Immediate post-operative appearance and at first week.

surgery and the anti-tetanus serum. A follow-up examination in Hospital via patient interview and physical examination at the first and the fourth months was without particularity.(Fig. 4).

3. Discussion

The cervical region is divided into three anatomical areas of which zone II is the widest and most exposed zone. It extends from the cricoid cartilage to the corner of the mandible and includes the common carotid arteries, internal and external jugular veins, various cranial nerves, larynx, hypopharynx and cervical esophagus [5].

Recently, the management of trauma to the penetrating neck has gone from compulsory exploration of the neck to selective management.

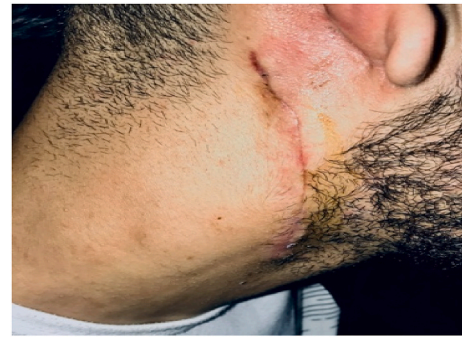

Fig. 4. The appearance of the wound 1 month post-operative.

This is largely due to advances in diagnostic imaging technology, as well as the consideration that exploration of the neck can lead to unnecessary complications [6,11].

The case presentation of the patient and the foreign body did not necessitate carrying out the radiological exploration.

The rate of major vascular lesions due to penetrating cervical trauma can reach up to 50% in zone II. In particular, an injury to the carotid sheath can lead to fatal haemorrhaging [7].

Angiography is considered the standard method for examining suspected vascular lesions [8].

However, the interpretation of angiographic images by computed tomography (CTA) may be limited by metallic fragments retained in the neck [9,10]. In our case CTA imaging could not completely exclude vascular lesions due to an artifact caused by metallic foreign body [11].

4. Conclusion

Cervical trauma remains a worrying surgical emergency. These pathologies are more common in young adult male in connection with the activities with high traumatic risk that he exercises.

The care is multidisciplinary because it calls upon several stakeholders to know: the ENT doctor, psychiatrist and anesthesiologist and only an early appropriate treatment can reduce the sequel.

Declaration of competing interest

The authors state that they do not have competing interests.

Sources of funding

We have any financial sources for our research.

Ethical approval and consent to participate

The study committee of the university hospital center approves the favorable opinion to publish this work.

Consent to publication

The consent to publish this information was obtained from study participants. We confirm that written proof of consent to publish study participants are available when requested and at any time.

Author's contributions

Dr. AB analysed and performed the literature research, Pr. AL, Pr. FE and Pr. RG, performed the examination and performed the scientific validation of the manuscript. Asmae Bazzout was the major contributors to the writing of the manuscript. All authors read and approved the manuscript.

Registration of research studies

Name of the registry:

Unique Identifying number or registration ID:

Hyperlink to your specific registration (must be publicly accessible and will be checked).

Guarantor

Dr.Asmae Bazzout.

Availability of data and material

The datasets in this article are available in the repository of the ENT database, Chu Mohamed VI Oujda, upon request, from the corresponding author.

References

- [1] C.A. Burgess, O.T. Dale, R. Almeyda, et al., An evidence-based review of the assessment and management of penetrating neck trauma, *Clin. Otolaryngol.* 37 (2012) 44–52.
- [2] F. Teixeira, C.A. Menegozzo, S.D. Netto, et al., Safety in selective surgical exploration in penetrating neck trauma, *World J. Emerg. Surg.* 11 (2016) 32.
- [3] S. Prichayudh, J. Choadrachata-anun, S. Sriussadaporn, et al., Selective management of penetrating neck injuries using “no zone” approach, *Injury* 49 (2015) 1720–1725.
- [4] R.A. Agha, T. Franchi, C. Sohrabi, G. Mathew, for the SCARE Group, The SCARE 2020 guideline: updating consensus surgical CAse REport (SCARE) guidelines, *Int. J. Surg.* 84 (2020) (article in press).
- [5] reportPenetrating Cervical Wound Following a Wild Boar Attack: Report of Case S. Tritar, R. Mani, S. Ayachi, H. Khochtali, Service de stomatologie et chirurgie maxillo-faciale. CHU Sahloul. Sousse.
- [6] K. Inaba, B.C. Branco, J. Menaker, et al., Evaluation of multidetector computed tomography for penetrating neck injury: a prospective multicenter study, *J Trauma Acute Care Surg* 72 (2012) 576–583, discussion 583-4; quiz 803-4.
- [7] M. Bladergroen, R. Brockman, G. Luna, et al., A twelve-year survey of cervicothoracic vascular injuries, *Am. J. Surg.* 157 (1989) 483–486.
- [8] T.M. Osborn, R.B. Bell, W. Qaisi, et al., Computed tomographic angiography as an aid to clinical decision making in the selective management of penetrating injuries to the neck: a reduction in the need for operative exploration, *J. Trauma* 64 (2008) 1466–1471.
- [9] K. Inaba, F. Munera, M. McKenney, et al., Prospective evaluation of screening multislice helical computed tomographic angiography in the initial evaluation of penetrating neck injuries, *J. Trauma* 61 (2006) 144–149.
- [10] F. Munera, J.A. Soto, D.M. Palacio, et al., Penetrating neck injuries: helical CT angiography for initial evaluation, *Radiology* 224 (2002) 366–372.
- [11] D. Wang, Y. Zhao, B. Cha, P. Fang, Y. Liu, Penetrating neck trauma with common carotid artery injury caused by a percussive drill: a case report, *Medicine (Baltim.)* 98 (22) (2019 May), e15750.