

Editor's quiz: GI snapshot

Unusual cause of bloody stool with earache and saddle-nose deformity

CLINICAL PRESENTATION

A 41-year-old female patient was admitted to hospital with bloody stool and diarrhoea for 2 months, accompanied with fever, left earache, obvious saddle-nose deformity and red eyes for 2 weeks. She had history of repeated multiple sore joints for 6 months and hearing impairment in the left ear for 4 months. Laboratory tests showed elevated white cell count (WBC) of $15.57 \times 10^9/L$, neutrophil of 76.8% and C reactive protein (CRP) of 95.4 mg/L. Haemoglobin was decreased at 94 g/L. Antineutrophil cytoplasmic antibody was negative. Colonoscopy showed diffuse inflammation and ulcers in the left-sided colon (figure 1). Histological findings from sigmoid colon showed chronic inflammation without vasculitis appearance.

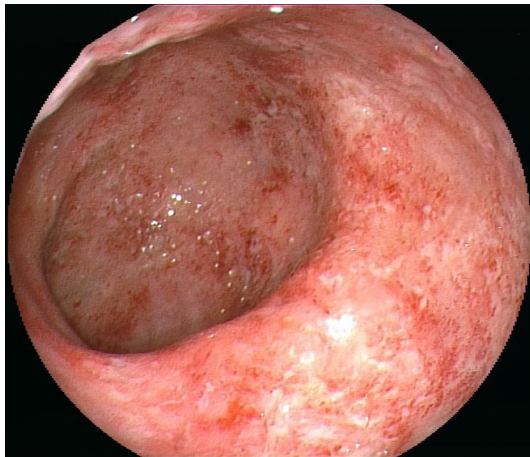


Figure 1 Diffuse inflammation and ulcers in the sigmoid colon.

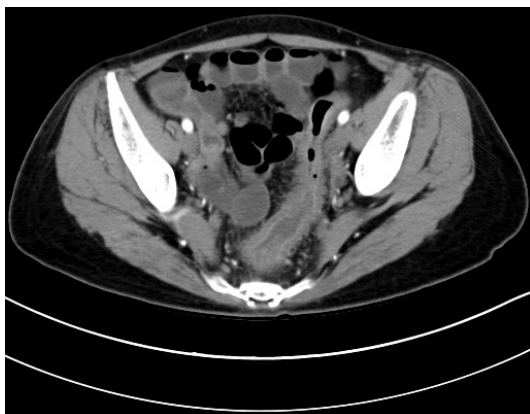


Figure 2 CT view of thick-walled left-sided colon with rich blood vessels and lymphadenopathy.

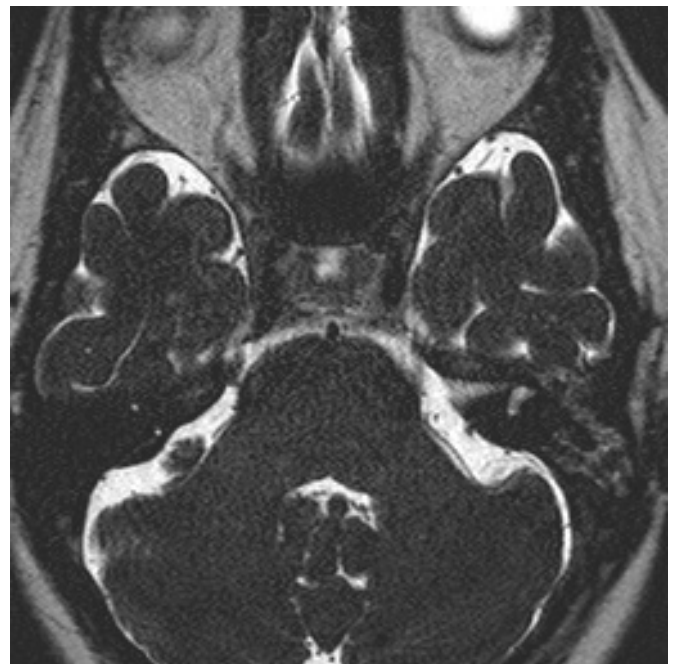

Figure 3 MRI of left middle ear mastoiditis.

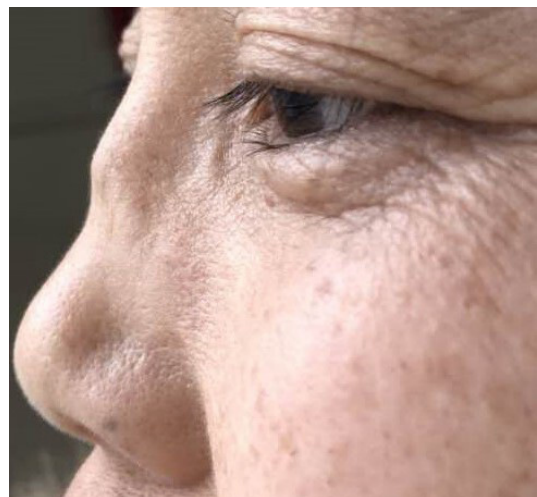


Figure 4 Saddle-nose deformity.

CT enterography revealed left-sided colon inflammation (figure 2). MRI of the internal auditory canal showed left middle ear mastoiditis (figure 3). Physical examination found swollen left auricle and obvious saddle-nose deformity (figure 4). Treatment of mesalamine, antibiotics and eye drops was started with subsequent symptomatic improvement (bloody stool improved, fever and swollen auricle disappeared), paralleled by a reduction in WBC to $5.0 \times 10^9/L$ (normal differential) and CRP to 20 mg/L. But earache, red eyes, saddle-nose deformity and sore joints still persisted. And she gradually appeared complete hearing loss in her left ear.

QUESTION

What is the diagnosis?

See page 356 for answer

Unusual cause of bloody stool with earache and saddle-nose deformity

See page 264 for question

ANSWER

The colon lesions were diagnosed as ulcerative colitis (UC). After comprehensive assessment, the symptoms of earache, saddle-nose deformity, red eyes, sore joints and hearing loss were diagnosed as relapsing polychondritis (RP). After 1 week of oral prednisone (30 mg/day) treatment, earache and red eyes disappeared, sore joints improved, but saddle-nose deformity and hearing loss had no improvement, and floppy eared gradually appeared. The dose of prednisone was gradually reduced when she was discharged from hospital and treatment of oral mesalazine was sustained. Three months later, colonoscopy showed endoscopic remission of UC (figure 5). She had no earache and sore joints, but saddle-nose deformity, cauliflower-like left ear (figure 6) and hearing loss persisted.

RP is a rare autoimmune rheumatic disorder characterised by episodic inflammation of cartilaginous tissue throughout the body.¹ Typical presenting features include chondritis of the nasal bridge, auricular cartilage, ocular inflammation and involvement of the tracheobronchial tree.² To date, diagnosis of RP is mainly based on typical clinical findings. UC with RP is rarely reported.³ Treatment for RP is usually with steroids and immunosuppressive drugs, but there are no standardised treatment options. The patient in our study is a rare example of UC with RP who responds to oral steroid.

Zhenzhen Liu,¹ Xiaolei Liu,² Jie Liang,¹ Yongquan Shi ,¹ Min Chen ¹

¹State key Laboratory of Cancer Biology, National Clinical Research Center for Digestive Diseases and Xijing Hospital of Digestive Diseases, Air Force Military Medical University, Xi'an, China

²Department of Medical Insurance, Xijing Hospital, Air Force Military Medical University, Xi'an, China

Correspondence to Dr. Min Chen, State key Laboratory of Cancer Biology, National Clinical Research Center for Digestive Diseases and Xijing Hospital of Digestive Diseases, Air Force Military Medical University, Xi'an, Shaanxi, China; yongheng_19860803@163.com

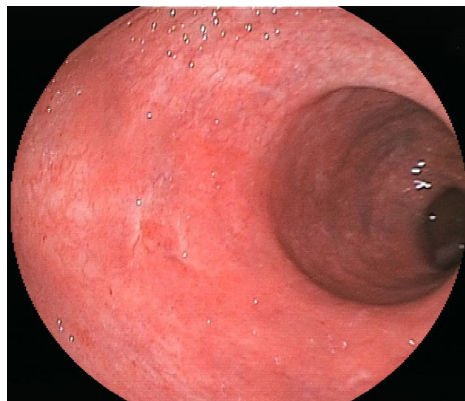


Figure 5 Endoscopic remission in the sigmoid colon.

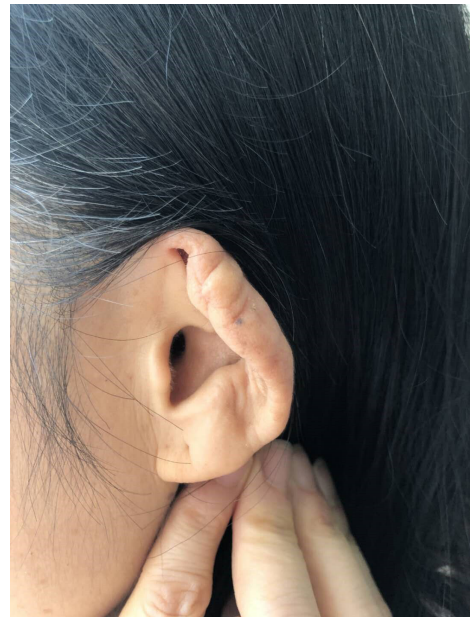


Figure 6 Cauliflower-like left ear.

Contributors MC performed the endoscopy, prepared the endoscopic figures and wrote the manuscript. ZL collected medical history, prepared the CT and MRI figures. XL revised the manuscript carefully. All authors contributed to the care of the patient.

Funding The case was funded by National Natural Science Foundation of China, Grant Number: 81600443, 81873554.

Competing interests None declared.

Patient consent for publication Obtained.

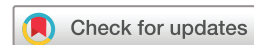Provenance and peer review Not commissioned; externally peer reviewed.



OPEN ACCESS

Open access This is an open access article distributed in accordance with the Creative Commons Attribution Non Commercial (CC BY-NC 4.0) license, which permits others to distribute, remix, adapt, build upon this work non-commercially, and license their derivative works on different terms, provided the original work is properly cited, appropriate credit is given, any changes made indicated, and the use is non-commercial. See: <http://creativecommons.org/licenses/by-nc/4.0/>.

© Author(s) (or their employer(s)) 2022. Re-use permitted under CC BY-NC. No commercial re-use. See rights and permissions. Published by BMJ.



To cite Liu Z, Liu X, Liang J, *et al.* *Gut* 2022;**71**:356.

Received 20 August 2020

Revised 8 September 2020

Accepted 15 September 2020

Published Online First 1 October 2020

Gut 2022;**71**:356. doi:10.1136/gutjnl-2020-322856

ORCID iDs

Yongquan Shi <http://orcid.org/0000-0001-7263-5919>

Min Chen <http://orcid.org/0000-0003-3004-2634>

REFERENCES

- 1 Lahmer T, Treiber M, von Werder A, *et al.* Relapsing polychondritis: an autoimmune disease with many faces. *Autoimmun Rev* 2010;**9**:540–6.
- 2 Trentham DE, Le CH. Relapsing polychondritis. *Ann Intern Med* 1998;**129**:114–22.
- 3 Rosen SW, MacKenzie MR, Cohen PJ, *et al.* A syndrome resembling relapsing polychondritis in a patient with ulcerative colitis. *Gastroenterology* 1969;**56**:323–30.