

SPECT/CT and pulmonary embolism

Jann Mortensen · Henrik Gutte

Received: 9 October 2013 / Accepted: 10 October 2013 / Published online: 9 November 2013
© The Author(s) 2013. This article is published with open access at Springerlink.com

Abstract Acute pulmonary embolism (PE) is diagnosed either by ventilation/perfusion (V/P) scintigraphy or pulmonary CT angiography (CTPA). In recent years both techniques have improved. Many nuclear medicine centres have adopted the single photon emission CT (SPECT) technique as opposed to the planar technique for diagnosing PE. SPECT has been shown to have fewer indeterminate results and a higher diagnostic value. The latest improvement is the combination of a low-dose CT scan with a V/P SPECT scan in a hybrid tomograph. In a study comparing CTPA, planar scintigraphy and SPECT alone, SPECT/CT had the best diagnostic accuracy for PE. In addition, recent developments in the CTPA technique have made it possible to image the pulmonary arteries of the lungs in one breath-hold. This development is based on the change from a single-detector to multidetector CT technology with an increase in volume coverage per rotation and faster rotation. Furthermore, the dual energy CT technique is a promising modality that can provide functional imaging in combination with anatomical information. Newer high-end CT scanners and SPECT systems are able to visualize smaller subsegmental emboli. However, consensus is lacking regarding the clinical impact and treatment. In the present review, SPECT and SPECT in combination with low-dose CT,

CTPA and dual energy CT are discussed in the context of diagnosing PE.

Keywords SPECT · SPECT/CT · Pulmonary CT angiography · Lung scintigraphy · Pulmonary embolism · Overview · Diagnostic test

Introduction

Acute pulmonary embolism (PE) is a common, often undiagnosed and potentially fatal disease. Mortality is between 10 % and 30 % if untreated, but can be reduced to 2 – 8 % with treatment [1]. Various clinical symptoms and findings together with knowledge of predisposing factors may strengthen or weaken the clinical suspicion. PE can be ruled out if the clinical suspicion is low and the D-dimer test is negative. However, in those patients in whom the clinical suspicion is moderate or high and/or the D-dimer test is positive, a conclusive imaging test such as a ventilation/perfusion (V/P) study or pulmonary CT angiography (CTPA) is needed to confirm or exclude the diagnosis of PE. There is increasing evidence of the improved accuracy of single photon emission CT (SPECT) and SPECT combined with low-dose CT (SPECT/CT) compared to planar V/P scintigraphy, and likewise of multidetector CTPA compared to single-detector CTPA. There is, however, less evidence concerning comparisons between SPECT and SPECT/CT and CTPA.

In this article, the clinical value and protocols of lung V/P studies with SPECT, SPECT/CT and CTPA are discussed.

Imaging agents

Ventilation

For ventilation studies with SPECT several kinds of agents can be used: the inert gas ^{81m}Kr , ^{99m}Tc -based agents such as the carbon suspension Technegas, or radioaerosols, e.g. ^{99m}Tc -DTPA.

J. Mortensen (✉) · H. Gutte
Department of Clinical Physiology, Nuclear Medicine & PET,
Rigshospitalet, Copenhagen University Hospital,
2100 Copenhagen, Denmark
e-mail: jann.mortensen@regionh.dk

J. Mortensen
Department of Medicine, The Faroese National Hospital, Torshavn,
Faroe Islands

H. Gutte
Department of Radiology, Herlev Hospital, Copenhagen University
Hospital, Copenhagen, Denmark

H. Gutte
Cluster for Molecular Imaging, Faculty of Health Sciences,
University of Copenhagen, Copenhagen, Denmark

$^{81\text{m}}\text{Kr}$ is delivered from a $^{81}\text{Rb}/^{81\text{m}}\text{Kr}$ generator. The short half-life of 13 s implies that $^{81\text{m}}\text{Kr}$ is inhaled continuously during imaging and that it disappears from the alveolar regions by decay much faster than by expiration. Hence, at normal breathing frequency the regional $^{81\text{m}}\text{Kr}$ concentration reflects regional ventilation. Due to the higher gamma energy (190.6 keV) of $^{81\text{m}}\text{Kr}$ compared to $^{99\text{m}}\text{Tc}$ (140 keV), a V/P scan can be acquired simultaneously. The effective radiation dose of $^{81\text{m}}\text{Kr}$ is very low (27 nSv/MBq, <0.2 mSv for 6,000 MBq). The use of $^{81\text{m}}\text{Kr}$ is mainly limited by the distance to a cyclotron since a cyclotron-produced generator only lasts 1 day ($T_{1/2}$ of 4.6 h for ^{81}Rb). $^{81\text{m}}\text{Kr}$ is very cost-effective if the number of patient examinations is high in a centre, whereas cost is a limitation if only a few patients are examined per generator. ^{133}Xe is rarely used in SPECT due to its low availability and energy.

The $^{99\text{m}}\text{Tc}$ -labelled Technegas (Cyclomedica Australia, Australia) consists of small $^{99\text{m}}\text{Tc}$ -graphite particles (5 – 200 nm) that are generated by burning solid graphite particles and $^{99\text{m}}\text{Tc}$ -pertechnetate in argon gas at a high temperature. The particles grow by aggregation and should therefore be administered within 3 min (no more than 10 min). The patient takes one to three deep breaths before imaging and most particles are deposited by diffusion in the alveolar regions, with a biological residence $T_{1/2}$ of 135 h. As a result, the time to start imaging, and the duration of image acquisition, are not time-critical [1]. However, due to sedimentation, hot-spots may occur in the larger airways and radioactivity may travel up through the airways by mucociliary and cough clearance during the SPECT. The effective radiation dose (15 $\mu\text{Sv}/\text{MBq}$, 0.5 – 0.8 mSv for 30 – 50 MBq) is higher than for $^{81\text{m}}\text{Kr}$ and radioaerosols, but lower than for the perfusion agent [1].

Radioaerosols are generated by a nebulizer, preferably creating particles of 1 – 3 μm (mass median aerodynamic diameter). If inhaled slowly they will deposit by sedimentation in the small airways and alveolar regions. The timing and length of imaging examination may be important since retention in the lung depends on the type of ventilation agent used. $^{99\text{m}}\text{Tc}$ -DTPA will clear through the alveolar capillary membrane (through tight-junctions) especially in the dependent lung zones with a $T_{1/2}$ of about 60 min in non-smokers, but two to five times faster in current smokers. Rapid clearance is reflected by the early depiction of radioactivity in the kidneys. Correction for clearance of $^{99\text{m}}\text{Tc}$ -DTPA during the time span of SPECT has been suggested and applied by some authors [2]. However, correction is not necessary for $^{99\text{m}}\text{Tc}$ -colloids (e.g. albumen, sulphur) since they have longer residence times in the lungs. Hot-spots in the larger airways occur more often with radioaerosols than with Technegas. The effective radiation dose from radioaerosols is low: 7 $\mu\text{Sv}/\text{MBq}$, 0.21 mSv for 30 MBq for $^{99\text{m}}\text{Tc}$ -DTPA; 4.7 $\mu\text{Sv}/\text{MBq}$, 0.15 mSv for 30 MBq for $^{99\text{m}}\text{Tc}$ -albumin colloid (Venticoll) [1]. In centres

with only a few V/P studies, radioaerosols are the most cost-effective ventilation agents.

Perfusion

$^{99\text{m}}\text{Tc}$ -labelled macroaggregated human albumin ($^{99\text{m}}\text{Tc}$ -MAA) is injected slowly while the patient breathes slowly and deeply to ensure a uniform perfusion distribution. The administered dose is between 100 and 220 MBq (effective dose 11 $\mu\text{Sv}/\text{MBq}$, 1.1 – 2.4 mSv for 100 – 220 MBq) and depends mainly on the choice of ventilation agent used [1, 3]. A larger dose is required if perfusion imaging is preceded by $^{99\text{m}}\text{Tc}$ -based ventilation imaging to overcome “background” radiation from the ventilation agent. Indeed, some centres use 300 MBq $^{99\text{m}}\text{Tc}$ -MAA [4] to obtain a required P/V ratio of ≥ 4 when using the ventilation agent Technegas, whereas a lower $^{99\text{m}}\text{Tc}$ -MAA dose can be used with $^{81\text{m}}\text{Kr}$ ventilation, or if the perfusion study is not preceded by a ventilation study [1]. About 400,000 MAA particles are injected, except in patients with pulmonary hypertension or a right-to-left cardiac shunt, and in children, in whom fewer particles are used [5].

Scanning protocols

V/P SPECT

The ventilation and perfusion agents for SPECT should be administered with the patient lying supine to reduce any gravitational influence upon distribution. If a $^{99\text{m}}\text{Tc}$ -based ventilation agent is used, sequential imaging is performed; usually ventilation first, then perfusion. To ensure alignment of the ventilation and perfusion imaging, the patient must not move between the two acquisitions. If $^{81\text{m}}\text{Kr}$ is used, V/P imaging can be performed simultaneously (applying a photopeak of 190 keV for $^{81\text{m}}\text{Kr}$ and 140 keV for $^{99\text{m}}\text{Tc}$ -MAA) ensuring optimal alignment and minimizing acquisition time; alternatively, $^{81\text{m}}\text{Kr}$ and $^{99\text{m}}\text{Tc}$ -MAA can be administered and imaged sequentially [1, 5].

Below are examples of different V/P SPECT scanning protocols (Table 1):

- A sequential V/P SPECT protocol using $^{99\text{m}}\text{Tc}$ -DTPA radioaerosol/ $^{99\text{m}}\text{Tc}$ -MAA [2]. First, the delivered dose from 30 MBq $^{99\text{m}}\text{Tc}$ -DTPA is inhaled into the lungs, and then the V SPECT is acquired. Immediately afterwards, 100 MBq $^{99\text{m}}\text{Tc}$ -MAA is given intravenously, and then the P SPECT is acquired. Both SPECT datasets are obtained with 64 projections per head over 180° , 10 s for ventilation and 5 s for perfusion, using low-energy general-purpose (LEGP) collimators and a 64×64 matrix. The protocol including both SPECT scans takes 20 min. Ordered-subsets expectation maximization (OSEM)

Table 1 Examples of ventilation/perfusion SPECT protocols

Reference	Simultaneous/sequential V/P SPECT	Ventilation agent, dose in lungs, effective dose	Perfusion agent, dose in lungs, effective dose	Projections per head, time, arc per head	Collimators, matrix size	Total V/P SPECT acquisition time (min)	Reconstruction
[2]	Sequential, first V SPECT, then P SPECT	^{99m} Tc-DTPA aerosol, 30 MBq, 0.2 mSv	^{99m} Tc-MAA, 110 MBq, 1.2 mSv	64 projections, V 10 s, P 5 s, 180°	LEGP, 64 × 64	20	Iterative, without attenuation correction, P corrected for V
[3]	Sequential, first V SPECT, then P SPECT	^{99m} Tc-Technegas, 50 MBq, 0.8 mSv	^{99m} Tc-MAA, 220 MBq, 2.4 mSv	60 projections, V 12 s, P 8 s, 180°	LEHR, 128 × 128	25 – 30	Iterative, without attenuation correction
[6]	Simultaneous V/P SPECT	^{81m} Kr-gas, 0.16 mSv	^{99m} Tc-MAA, 150 MBq, 1.7 mSv	36 projections, 20 s, 180°	LEGP, 128 × 128	13 (<10 ^a)	Iterative, with and without attenuation correction
[7]	Simultaneous V/P SPECT	^{81m} Kr-gas	^{99m} Tc-MAA, 200 MBq, 2.2 mSv	64 projections, 12 s, 180°	LEHR, 128 × 128	About 16	
[4]	Sequential, first V SPECT, then P SPECT	^{99m} Tc-Technegas, 100 MBq, 1.6 mSv	^{99m} Tc-MAA, 300 MBq, 3.3 mSv	32 projections, V 30 s, P 20 s, 180°	LEHR, 128 × 128	27	Filtered back projection, without attenuation correction
[8]	Sequential, first V SPECT, then P SPECT	^{99m} Tc-Technegas,	^{99m} Tc-MAA, 185 MBq, 2.0 mSv	60 projections, V 15 s, P 10 s, 180°	LEHR	30	

LEGP low-energy general-purpose, LEHR low-energy high-resolution, V ventilation, P perfusion

^a Currently it takes <10 min because each projection now takes 12 s

- reconstruction is performed (two iterations/eight subsets). Since 10 – 40 % of the ^{99m}Tc-DTPA is cleared from the lungs during the V SPECT acquisition, this is corrected for. In addition, P SPECT is corrected for “background” radioactivity remaining from the ^{99m}Tc-ventilation agent.
- A sequential V/P SPECT protocol using ^{99m}Tc-Technegas/^{99m}Tc-MAA [3]. First, a dose from 50 MBq ^{99m}Tc-Technegas is inhaled into the lungs, and then the V SPECT is acquired. Immediately afterwards, 220 MBq ^{99m}Tc-MAA is given intravenously, and then the P SPECT is acquired. Both SPECT datasets are obtained with 60 projections per head over 180°, 12 s for ventilation and 8 s for perfusion, using low-energy high-resolution (LEHR) collimators and a 128 × 128 matrix. The protocol including both SPECT scans takes 25 – 30 min. OSEM reconstruction is used (eight iterations/four subsets).
- A simultaneous V/P SPECT protocol using ^{81m}Kr/^{99m}Tc-MAA [6]. First, 150 MBq ^{99m}Tc-MAA is given intravenously, then the V/P SPECT scan is performed, during which ^{81m}Kr is inhaled. Dual energy SPECT is acquired as 36 projections per head of 20 s each over 180°, using LEGP (or medium-energy general-purpose) collimators and a 128 × 128 matrix. The protocol takes 13 min. Iterative reconstruction is performed (three iterations/16 subsets; Astonish, Philips) and images both with attenuation correction (based on a simultaneously obtained low-dose CT scan) and without attenuation correction are reviewed. Our present routine protocol is shortened to less than 10 min by using 12 s instead of 20 s per projection.

SPECT/CT

The introduction of hybrid SPECT/CT tomography has enabled simultaneous acquisition of V/P SPECT and CT scans of the lungs [9]. CT can be performed as a low-dose CT scan of the lungs and/or as CTPA [6, 9]. In our centre, the standard routine test for evaluation of PE is combined ^{81m}Kr/^{99m}Tc-MAA (V/P) SPECT/CT (16 slice Precedence; Philips); the CT is performed as a low-dose CT scan without contrast enhancement during free breathing (140 kVp, 20 mAs/slice, collimator 16 × 1.5 mm, rotation time 0.5 s, pitch 0.813, matrix 512 × 512) immediately before the V/P SPECT scan. The total time required for the combined study is <15 min. The effective radiation dose from the low-dose CT scan is about 1 mSv [6]. A similar dose of 0.9 mSv from a CT scan (110 kVp, 20 mAs/slice) has been reported from a V/P SPECT/CT study from Perth, Australia [10].

In a prospective study comparing simultaneously performed V/P SPECT, V/P SPECT/CT and CTPA [6], we included CTPA (80 ml iodine contrast agent, 350 mgI/ml) using the bolus tracking technique during a deep inspiration breath-hold (120 kVp, 230 mAs/slice, collimator 16 × 0.75 mm, rotation time 0.5 s, pitch 0.94, 512 × 512 matrix). In our daily

routine, we occasionally combine V/P SPECT/CT and CTPA in critically ill patients, and in such cases, we start with CTPA. If negative for central PE, we proceed with V/P SPECT/CT to detect any peripheral PE. The combined V/P SPECT/CT and CTPA can be performed in <20 min.

Pulmonary multidetector CT angiography

Over the past two decades, CT has undergone rapid development. From single-detector CT to an increasing number of rows of detectors (multidetector CT, MDCT), with an increase in volume coverage in one rotation time and a decrease in the time necessary to acquire the entire chest, all of which have made it possible to image the pulmonary arteries of the lungs in one breath-hold [11]. In the latest generation of CT systems several benefits have been achieved, such as: significant decrease in the volume of iodine contrast agent injected, faster scan time (<1 s) and lower radiation dose. With the introduction of iterative reconstruction algorithms and faster scan times, it is now possible to lower the peak kilovoltage from 120 to 80 kVp and, with the use of dose modulation software, to decrease the radiation dose in selected systems by >70 % without compromising the signal-to-noise ratio [12]. An effective dose for CTPA of ≤ 1 mSv is now achievable with the state-of-the-art systems available [13].

The development of faster scan times has further resulted in a decreased number of inconclusive scans from approximately 10 % to 2 %. These are most often due to patient movement or poor bolus enhancement [14–16]. Additionally, continuous improvement of the contrast agent injection protocols has to be achieved due to the shorter scan times. The paramount challenge is in timing the intravenous injection of the contrast agent bolus and accomplishing high contrast enhancement in the pulmonary vessels and at the same time lowering the volume of contrast agent administered to reduce the adverse effects of iodine (Fig. 1). Consequently, the volume of iodine contrast agent required can be reduced to 60–70 ml (300–400 mg I/ml) with the fast high-end systems compared to 150 ml with older systems (2–16 detectors). Nonetheless,

impairment of kidney function is still an important issue with iodine contrast agents.

The latest improvement in CT is the development of dual energy CT systems. A dual energy CT system with two independent tube detector systems (e.g. 140 kVp and 80 kVp) makes material differentiation possible. Iodine distribution can be visualized in the parenchyma of the lung and can reveal perfusion changes and has the potential to reveal subsegmental clots. In addition, stable xenon gas can be used in dual energy CT systems for CT ventilation imaging, mimicking the ventilation scan obtained in lung scintigraphy [17]. Hence, it is now feasible to accomplish functional information (perfusion/ventilation) combined with morphological imaging in the same lung CT scan [18, 19]. However, further studies have to be done before this can be applied in routine clinical practice.

Clinical value

V/P SPECT

V/P SPECT overcomes the superimposition of lung areas with normal perfusion onto areas with perfusion defects, which may mask PE. It also allows recognition of perfusion and ventilation defects typical of other diseases. Many studies demonstrate enhanced sensitivity and specificity, as well as a reduction in the nondiagnostic rate of V/P SPECT compared with planar V/P scintigraphy [4, 20–23] (Table 2). In clinical head-to-head comparisons of V/P SPECT and planar scintigraphy, more and smaller defects were seen on SPECT and higher sensitivity, specificity and accuracy were also observed: the median differences between SPECT and planar V/P scans in sensitivity, specificity and accuracy were 21 % (range 15 to 36 %), 6 % (range –7 to 15 %) and 7 % (range –2 to 20 %), respectively [20–22]. A substantial proportion of V/P planar studies are usually indeterminate (up to 73 % in PIOPED1), but the addition of V/P SPECT renders the test diagnostic in most patients [4]. V/P SPECT is diagnostic in ≥ 95 % of

Fig. 1 Bilateral central pulmonary emboli on the CT scan. Axial and coronal CT images with intravenous contrast agent administration show large contrast defects in the central pulmonary arteries (arrows). Note the lack of contrast enhancement in the small subsegmental pulmonary arteries

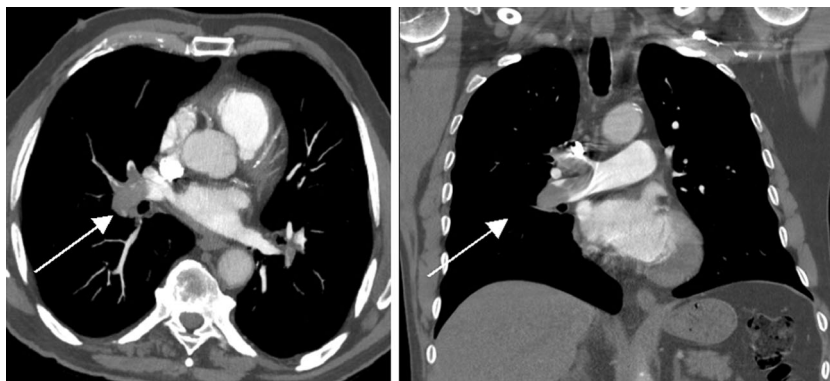


Table 2 Accuracy studies of V/P SPECT and V/P SPECT/CT

Reference	No. of patients	PE prevalence (%)	Comparison	Result	Sensitivity (%)		Specificity (%)		Accuracy (%)	Reference standard ^a	Time between studies (h)	Design	Conclusion
					Sensitivity (%)	Specificity (%)	Sensitivity (%)	Specificity (%)					
[21]	53	25	V/P SPECT V/P planar	100 85	93 100	94 96			Consensus, V/P scintigraphy, plain radiography, CTPA, follow-up	–	Prospective	No significant difference, except more defects seen on SPECT	
[24]	1,785	34	V/P SPECT	99	98	98			Consensus, SPECT, CTPA, follow-up	–	Retrospective	High diagnostic value, feasible in 99 %	
[20]	36 ^b	31	V/P SPECT V/P planar	100 64	87 72	90 70			Consensus, combined SPECT/CT + CTPA, clinical data, follow-up	<1/2	Prospective	V/P SPECT higher sensitivity and specificity than V/P planar scan	
[8]	87	26	V/P SPECT	83	98	94			Consensus, V/P planar, CTPA, follow-up	<24	Prospective	95 % agreement between SPECT and CTPA	
[7]	243	20	V/P SPECT ^e V/P SPECT ^f	88 93	88 98	88 97			Clinical score, lower limb compression ultrasonography, V/P planar, CTPA, follow-up	–	Prospective	V/P SPECT combined with clinical probability was diagnostic in 88 % of patients with 97 % accuracy	
[4]	95 ^c	21	V/P SPECT	79	83	80			CTPA, lower limb ultrasonography	<48	Prospective	V/P SPECT was diagnostic in almost all patients with inconclusive V/P planar scan	
[22]	83	45	V/P planar ^d V/P SPECT CTPA	76 97	85 91	81 94			Consensus, SPECT, CTPA	<72	Retrospective	No significant difference, except more defects found with V/P SPECT than with planar scan	
[6]	81	38	V/P SPECT V/P SPECT/CT P SPECT/CT CTPA	97 97 93	88 100 51	91 99 68			Consensus of combined SPECT/CT + CTPA, clinical data, follow-up	<1/2	Prospective	P SPECT/CT less specific and accurate. No significant difference between the other three	
[10]	106	26	V/P SPECT/CT	68 93	100 100	88 98			Composite V/P SPECT/CT, follow-up (a few CTPA)	–	Retrospective	In 27 % of patients, Low-dose CT gave information on alternative pathologies accounting for the symptoms	

^a Consensus is based on all available data (e.g. imaging, clinical and follow-up data)

^b These patients are also included in reference [6]

^c The included patients were indeterminate on planar V/P scans (about 36 % of V/P planar scan were indeterminate)

^d Planar was extracted from V/P SPECT

^e Patients in the intermediate and high V/P SPECT scan probability groups were considered positive for PE, and patients in the normal and low V/P SPECT scan probability groups were considered negative for PE

^f Concluded as diagnostic if clinical and SPECT probabilities were in concordance, and inconclusive if they disagreed

patients and is feasible in 97 – 99 % of patients referred for lung scintigraphy [6, 24–26]. V/P planar scintigraphy remains an alternative in the few patients in whom SPECT cannot be performed due to for example obesity or discomfort in the supine position [24].

Some patterns on V/P SPECT may suggest alternative diagnoses such as COPD, pneumonia, and left heart diseases [24, 27, 28] but even if these diseases are present it is possible to diagnose PE with V/P SPECT [1]. A recent study showed that if the reader has extensive experience with PISA-PED readings of perfusion scintigraphy, it is also possible to obtain high diagnostic accuracy (≥ 90 %) for PE from perfusion SPECT only without ventilation information [29].

Interpretation criteria of V/P SPECT

Iterative reconstruction is recommended (for example using OSEM, with e.g. eight subsets and two iterations) [1]. Perfusion and ventilation images in axial, coronal and sagittal projections and rotating 3-D images are read simultaneously. As an option, V/P ratio images can also be displayed [1] as well as low-dose CT images, if available [6] (Fig. 2).

Different diagnostic cut-off criteria have been used in the published V/P SPECT studies. Le Duc-Pennec et al. applied the revised PLOPED criteria as proposed by Gottschalk et al. for planar V/P scan interpretation [7, 30]. In a reanalysis of 249 V/P SPECT datasets assessing various combinations of mismatched defect numbers and sizes from segmental to subsegmental, the same authors found that a diagnostic cut-off of one segmental or two subsegmental mismatches was best for confirming or excluding acute PE with a sensitivity of 92 % and specificity of 91 % [31]. Combining pretest clinical probability with SPECT for a negative V/P SPECT result gave post-test probabilities of PE of 1 %, 4 % and 12 % for low, intermediate and high clinical probability, respectively. For a positive V/P SPECT result, post-test probabilities of PE were 53 %, 81 % and 94 % for low, intermediate and high clinical probability, respectively (Table 2).

Leblanc et al. applied the diagnostic criteria for PE of “any clear-cut vascular mismatch, regardless of size”, which had a negative predictive value of 98 % at 3 months [26]. An almost similar diagnostic cut-off of wedge-shaped pleural-based V/P mismatch of ≥ 0.5 segment has been used by others [6, 8] and has recently been shown to be the best value in a V/P planar study [32]. A third approach was a cut-off of the presence of > 50 % perfusion mismatch in an anatomical segment or two regions of perfusion mismatch, regardless of size [10].

The European (EANM) guidelines from 2009 recommend that “PE” is reported if there is V/P mismatch of one or more segments or two subsegments that conform to the pulmonary vascular anatomy. “No PE” is reported if there is a normal perfusion pattern conforming to the anatomic boundaries of the lung, matched or reversed mismatch V/P defects (any size,

shape, number), or a mismatch that does not have a subsegmental, segmental or lobar pattern. “Non-diagnostic for PE” is reported if there are multiple V/P abnormalities not typical of specific disease [1].

Clinical validity of PE-negative V/P SPECT studies and clinical outcome

The negative predictive value of V/P SPECT for PE is ≥ 97 % [6, 24–26]. The long-term outcome of withholding antithrombotic treatment after a negative SPECT scan has been studied [25, 26] in 1,159 and 405 patients and only 0.5 – 1.5 % of the scans were false-negative [24, 26], similar to reported values for V/P planar studies [33–35].

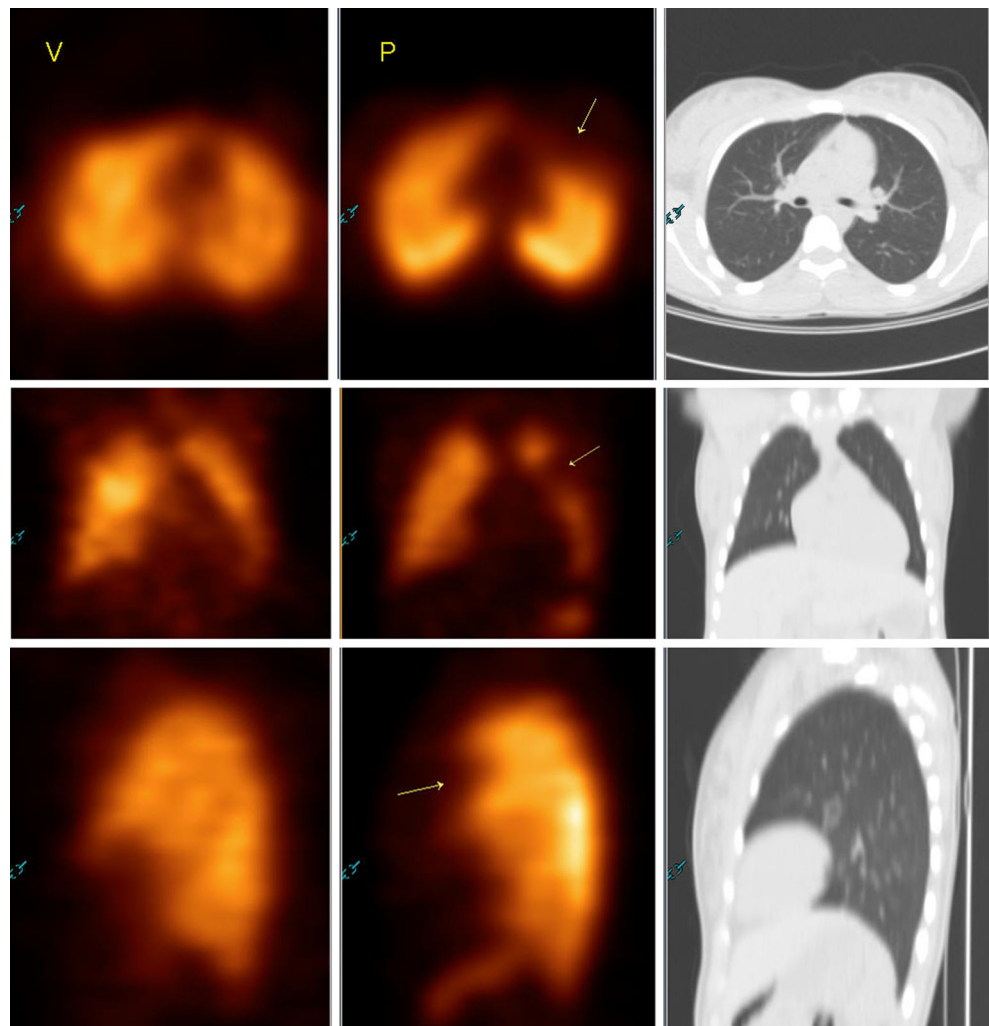
Follow-up with V/P SPECT

In the same manner as the use of V/P planar lung scintigraphy for follow-up after large PE, SPECT should be ideal for follow-up studies due to its higher resolution and accuracy. A prospective study of 23 patients with PE showed the feasibility of follow-up with V/P SPECT for evaluating treatment effectiveness and identifying patients who develop chronic PE. Resolution of perfusion defects after PE occurred within the first 3 months of treatment [36].

V/P SPECT/CT

The accuracy of V/P SPECT combined with low-dose CT has been assessed in two studies (Table 2). In a prospective study, simultaneously obtained V/P SPECT, V/P SPECT/CT and CTPA were compared and PE was diagnosed in 38 % using head-to-head comparisons and 6 months follow-up [6]. V/P SPECT and V/P SPECT/CT had the highest sensitivity (97 %), whereas V/P SPECT/CT and CTPA had the highest specificity (100 %), and V/P SPECT/CT had the highest accuracy (99 %). Differences were not significantly different, however, due to the relatively small number of patients. A test that included V/P SPECT gave the highest sensitivity, while a test that included CT, either CTPA or low-dose CT integrated with V/P SPECT, gave the best specificity and was always either positive or negative for PE (100 % diagnostic rate) and could often give alternative diagnoses. Adding low-dose CT to V/P SPECT increased specificity (from 88 % to 100 %) by reducing false-positive interpretations (from 18 % to 0 %), without affecting sensitivity (still 97 %). Low-dose CT improved confidence in reading and reduced the inconclusive assessments from 5 % to 0 %. The improvement in specificity was mainly due to low-dose CT findings providing alternative explanations for subtle perfusion defects such as small interlobar fissures, localized hyperinflated areas, paraseptal emphysema, pleural fluid, atelectasis and pneumonic infiltration, which would otherwise be read as PE on SPECT (Fig. 3).

Fig. 2 A pulmonary embolus is seen on the V/P SPECT/CT images. A wedge-shaped pleural-based large mismatched perfusion defect is seen anteriorly in the left lung (*yellow arrows*) on the axial (*upper row*), coronal (*middle row*) and sagittal (*lower row*) projections. No other explanations for the perfusion defect can be seen on the normal ventilation scan and low-dose CT images

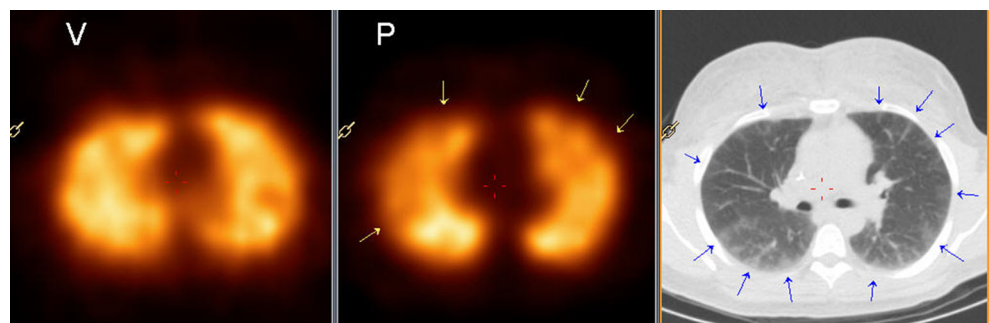


However, low-dose CT combined with perfusion SPECT (without ventilation SPECT) was suboptimal due to a low specificity (51 %) and positive predictive value (57 %) and a high nondiagnostic rate (17 %), while sensitivity and negative predictive value remained over 90 %. Hence, ventilation SPECT is needed in addition to perfusion SPECT when using low-dose CT.

Ling et al. performed V/P SPECT/CT in 106 patients using a composite reference standard for PE including a 6-month

follow-up, but CTPA was only used in a few patients with normal V/P scans but high clinical suspicion [10]. PE was diagnosed in 26 % of patients, including 2 % with a false-negative V/P SPECT/CT result. The negative predictive value of V/P SPECT for PE was 97 %. Abnormalities detected by low-dose CT were correlated with the V/P SPECT findings to suggest alternative diagnoses in those negative for PE. Low-dose CT was abnormal in 41 % of patients, and in 27 % of all patients low-dose CT provided information on alternative

Fig. 3 Very small mismatched perfusion defects (*yellow arrows*) are seen peripherally in both lungs, but the CT image shows widespread pleural based interstitial ground-glass abnormalities (*blue arrows*) compatible with inflammation, but not with PE



pathologies that accounted for the symptoms such as pneumonia, pulmonary oedema and ARDS, corresponding to the CTPA findings [37]. Performing low-dose CT allows attenuation correction of the SPECT data. The value of attenuation correction of V/P SPECT studies in PE is, however, unresolved [3].

Another potential combination of functional and structural information from V/P SPECT and CT is a fusion of SPECT and CTPA scan acquired on the same or separate systems [9, 38]. Accurate fusion of SPECT and CTPA may be clinically useful in nondiagnostic initial investigations, or where corroborative imaging is sought.

Pulmonary CT angiography

Several studies have demonstrated that CTPA has higher diagnostic accuracy and specificity than planar V/P scintigraphy [19, 37]. In a study with 179 patients, Blachere et al. demonstrated that sensitivity, specificity, positive predictive value and negative predictive value of CTPA and planar V/P scans were 94 % versus 80 %, 93 % versus 73 %, 95 % versus 82 % and 96 % versus 75 %, respectively [19]. Similar results were reported by Grenier and Beigelman [39] and Mayo et al. [40]. The strength of V/P scintigraphy is its high negative predictive value in patients with a low pretest probability and its high positive predictive value in patients with a high pretest probability [30]. Hence, it was part of the composite gold standard for diagnosing PE in the PIOPED2 study, in which CTPA had a sensitivity of 83 % and specificity of 96 % and was inconclusive in 6 % [14].

The number of head-to-head comparisons between V/P SPECT and CTPA is still limited (Table 2) [6, 8, 22]. There is a 95 % concordance between V/P SPECT and CTPA [8], with a higher sensitivity with SPECT, a higher specificity with CTPA, and equally high accuracy with both methods [6, 22]. The combination of V/P SPECT and low-dose CT may be even more accurate than V/P SPECT or CTPA, but more studies are warranted [6].

V/P SPECT and V/P SPECT/CT are available in many nuclear medicine departments, mostly during routine working hours. They can provide alternative diagnoses, have high interobserver agreement, and can be performed in almost all patients since there are no definitive contraindications [1, 41]. CTPA is available in most clinical centres round-the-clock. It is capable of providing alternative diagnoses, has faster scan times, has high interobserver agreement and could have a possible role in detecting right ventricular dysfunction. It does have contraindications, however, and cannot be performed in 10–30 % of inpatients [6, 11, 14, 42].

Patients with PE may have multiple scans due to the risk of recurrence or due to comorbidity, and therefore are at risk from cumulative exposure to ionizing radiation. Especially in young women, the radiation dose to the breast tissue is of

critical importance. Chest CT scanning results in relatively higher doses to the breast tissue than lung scintigraphy. However, the latest iterative reconstruction technique can lead to a 60–80 % reduction in dose, and at the same time, a 43–80 % improvement in low-contrast detectability and a 70–83 % reduction in image noise, compared with standard (filtered back projection) reconstruction. Therefore, radiation dose to the breast can be reduced [13, 43]. However, there is no broad consensus on this issue and further research is needed.

Clinical validity of PE-negative CT studies and clinical outcome

Carrier et al. demonstrated in a systematic review that multiple detector CTPA (2–64 detectors) might increase the rate of subsegmental PE diagnosis as compared with single detector CTPA. They also demonstrated that the 3-month thromboembolic risk in patients with suspected PE who were left untreated after a negative CTPA result was similar regardless of whether the patients underwent a single or multiple detector CTPA. Finally, they concluded that the incremental rate of subsegmental PE detected by multiple detector CTPA might not be clinically important [44].

A meta-analysis by Quiroz et al. with pooled results involving 15 studies and 3,500 patients with suspected PE suggested that clinical outcome is not adversely affected if anticoagulant therapy is withheld based on a negative CT scan with a negative predictive value of 99.1 % [45]. These studies were performed with older generation MDCT systems, and it is therefore possible that subsegmental pulmonary emboli remained undetected. Newer high-end CT systems have a higher spatial and temporal resolution and are therefore able to visualize smaller subsegmental emboli. However, consensus regarding the treatment of isolated subsegmental emboli in patients with suspected PE has not been established and whether this will result in improved clinical outcome is debatable [46]. Since subsegmental PE may precede recurrent large PE and may also increase the risk of development of chronic pulmonary hypertension, improvement in the detection of subsegmental PE is worth studying [18].

Conclusion

Compared with traditional V/P scintigraphy, both V/P SPECT and CTPA have a higher diagnostic value and fewer inconclusive results in the diagnosis of PE. V/P SPECT and CTPA are highly concordant and show similar diagnostic accuracy, with SPECT showing higher sensitivity and CTPA higher specificity. There is possibly a higher clinical value of negative SPECT studies compared to negative CTPA studies, but the clinical importance of finding a small subsegmental PE needs further elucidation. A combination of V/P SPECT and

CT may be even more accurate than V/P SPECT or CTPA alone. More comparisons are needed, however. Each of these excellent imaging methods has the highest predictive values when there is concordance between the clinical suspicion and the test result, whereas further imaging should be performed if there is discordance.

V/P SPECT or V/P SPECT/CT are available in many nuclear medicine departments, mostly during the day-time. They may provide an alternative diagnosis if PE is refuted, and are feasible in almost all patients, because there are no definitive contraindications. CTPA is usually available round-the-clock and a rapid PE or alternative diagnosis can be expected. Due to contraindications such as kidney impairment or allergy, CTPA cannot be performed in about 10–30 % of patients. Whereas radiation exposure was previously substantially higher for the patient with CTPA than with V/P SPECT or V/P SPECT/CT, a much lower radiation dose is now achievable with new generation CT technology.

Conflicts of interest None.

Open Access This article is distributed under the terms of the Creative Commons Attribution License which permits any use, distribution, and reproduction in any medium, provided the original author(s) and the source are credited.

References

- Bajc M, Neilly JB, Miniati M, Schuemichen C, Meignan M, Jonson B. EANM guidelines for ventilation/perfusion scintigraphy: Part 1. Pulmonary imaging with ventilation/perfusion single photon emission tomography. *Eur J Nucl Med Mol Imaging*. 2009;36(8):1356–70.
- Palmer J, Bitzen U, Jonson B, Bajc M. Comprehensive ventilation/perfusion SPECT. *J Nucl Med*. 2001;42(8):1288–94.
- Roach PJ, Bailey DL, Harris BE. Enhancing lung scintigraphy with single-photon emission computed tomography. *Semin Nucl Med*. 2008;38(6):441–9.
- Weinmann P, Moretti J-L, Brauner MW. Usefulness of tomographic versus planar lung scintigraphy in suspected pulmonary embolism in a daily practice. *Open Med Imaging J*. 2013;2:49–55.
- Bajc M, Neilly B, Miniati M, Mortensen J, Jonson B. Methodology for ventilation/perfusion SPECT. *Semin Nucl Med*. 2010;40(6):415–25.
- Gutte H, Mortensen J, Jensen CV, Johnbeck CB, von der Recke P, Petersen CL, et al. Detection of pulmonary embolism with combined ventilation-perfusion SPECT and low-dose CT: head-to-head comparison with multidetector CT angiography. *J Nucl Med*. 2009;50(12):1987–92.
- Le Duc-Pennec A, Le Roux PY, Cornily JC, Jaffrelot M, Delluc A, de Saint-Martin L, et al. Diagnostic accuracy of single-photon emission tomography ventilation/perfusion lung scan in the diagnosis of pulmonary embolism. *Chest*. 2012;141(2):381–7.
- Miles S, Rogers KM, Thomas P, Soans B, Attia J, Abel C, et al. A comparison of single-photon emission CT lung scintigraphy and CT pulmonary angiography for the diagnosis of pulmonary embolism. *Chest*. 2009;136(6):1546–53.
- Gutte H, Mortensen J, Jensen C, von der Recke P, Kristoffersen US, Kjaer A. Added value of combined simultaneous lung ventilation-perfusion single-photon emission computed tomography/multi-slice-computed tomography angiography in two patients suspected of having acute pulmonary embolism. *Clin Respir J*. 2007;1(1):52–5.
- Ling IT, Naqvi HA, Siew TK, Loh NK, Ryan GF. SPECT ventilation perfusion scanning with the addition of low-dose CT for the investigation of suspected pulmonary embolism. *Int Med J*. 2012;42(11):1257–61.
- Reid JH, Coche EE, Inoue T, Kim EE, Dondi M, Watanabe N, et al. Is the lung scan alive and well? Facts and controversies in defining the role of lung scintigraphy for the diagnosis of pulmonary embolism in the era of MDCT. *Eur J Nucl Med Mol Imaging*. 2009;36(3):505–21.
- Li Q, Yu H, Zhang L, Fan L, Liu S. Combining low tube voltage and iterative reconstruction for contrast-enhanced CT imaging of the chest – initial clinical experience. *Clin Radiol*. 2013;68(5):e249–53.
- Mehta D, Thompson R, Morton T, Dhanantwari A, Shefer E. Iterative model reconstruction: simultaneously lowered computed tomography radiation dose and improved image quality. *Med Phys Int J*. 2013;2(1):147–55.
- Stein PD, Fowler SE, Goodman LR, Gottschalk A, Hales CA, Hull RD, et al. Multidetector computed tomography for acute pulmonary embolism. *N Engl J Med*. 2006;354(22):2317–27.
- Jones SE, Wittram C. The indeterminate CT pulmonary angiogram: imaging characteristics and patient clinical outcome. *Radiology*. 2005;237(1):329–37.
- Pesavento R, de Conti G, Minotto I, Filippi L, Mongiat M, de Faveri D, et al. The value of 64-detector row computed tomography for the exclusion of pulmonary embolism. *Thromb Haemost*. 2011;105(5):901–7.
- Thieme S, Hoegl S, Nikolaou K, Fisahn J, Irlbeck M, Maxien D, et al. Pulmonary ventilation and perfusion imaging with dual-energy CT. *Eur Radiol*. 2010;20(12):2882–9.
- Pontana F, Faivre JB, Remy-Jardin M, Flohr T, Schmidt B, Tacelli N, et al. Lung perfusion with dual-energy multidetector-row CT (MDCT): feasibility for the evaluation of acute pulmonary embolism in 117 consecutive patients. *Acad Radiol*. 2008;15(12):1494–504.
- Blachere H, Latrabe V, Montaudon M, Valli N, Couffignal T, Raherisson C, et al. Pulmonary embolism revealed on helical CT angiography: comparison with ventilation-perfusion radionuclide lung scanning. *AJR Am J Roentgenol*. 2000;174(4):1041–7.
- Gutte H, Mortensen J, Jensen CV, von der Recke P, Petersen CL, Kristoffersen US, et al. Comparison of V/Q SPECT and planar V/Q lung scintigraphy in diagnosing acute pulmonary embolism. *Nucl Med Commun*. 2010;31(1):82–6.
- Bajc M, Olsson CG, Olsson B, Palmer J, Jonson B. Diagnostic evaluation of planar and tomographic ventilation/perfusion lung images in patients with suspected pulmonary emboli. *Clin Physiol Funct Imaging*. 2004;24(5):249–56.
- Reinartz P, Wildberger JE, Schaefer W, Nowak B, Mahnken AH, Buell U. Tomographic imaging in the diagnosis of pulmonary embolism: a comparison between V/Q lung scintigraphy in SPECT technique and multislice spiral CT. *J Nucl Med*. 2004;45(9):1501–8.
- Bajc M, Bitzen U, Olsson B, Perez de Sa V, Palmer J, Jonson B. Lung ventilation/perfusion SPECT in the artificially embolized pig. *J Nucl Med*. 2002;43(5):640–7.
- Bajc M, Olsson B, Palmer J, Jonson B. Ventilation/perfusion SPECT for diagnostics of pulmonary embolism in clinical practice. *J Intern Med*. 2008;264(4):379–87.
- Corbus HF, Seitz JP, Larson RK, Stobbe DE, Wooten W, Sayre JW, et al. Diagnostic usefulness of lung SPET in pulmonary thromboembolism: an outcome study. *Nucl Med Commun*. 1997;18(10):897–906.
- Leblanc M, Leveillee F, Turcotte E. Prospective evaluation of the negative predictive value of V/Q SPECT using 99mTc-Technegas. *Nucl Med Commun*. 2007;28(8):667–72.
- Jogi J, Palmer J, Jonson B, Bajc M. Heart failure diagnostics based on ventilation/perfusion single photon emission computed tomography

- pattern and quantitative perfusion gradients. *Nucl Med Commun.* 2008;29(8):666–73.
28. Bajc M, Jonson B. Ventilation/perfusion SPECT for diagnosis of pulmonary embolism and other diseases. *Int J Mol Imaging.* 2011;2011:682949.
 29. Bajc M, Miniati M, Jogi J, Stein PD. Perfusion SPECT in patients with suspected pulmonary embolism. *Eur J Nucl Med Mol Imaging.* 2013;40(9):1432–7.
 30. Gottschalk A, Sostman HD, Coleman RE, Juni JE, Thrall J, McKusick KA, et al. Ventilation-perfusion scintigraphy in the PLOPED study. Part II. Evaluation of the scintigraphic criteria and interpretations. *J Nucl Med.* 1993;34(7):1119–26.
 31. Le Roux PY, Robin P, Delluc A, Abgral R, Le Duc-Pennec A, Nowak E, et al. V/Q SPECT interpretation for pulmonary embolism diagnosis: which criteria to use? *J Nucl Med.* 2013;54(7):1077–81.
 32. Howarth DM, Booker JA, Voutnis DD. Diagnosis of pulmonary embolus using ventilation/perfusion lung scintigraphy: more than 0.5 segment of ventilation/perfusion mismatch is sufficient. *Int Med J.* 2006;36(5):281–8.
 33. Hull RD, Raskob GE, Coates G, Panju AA. Clinical validity of a normal perfusion lung scan in patients with suspected pulmonary embolism. *Chest.* 1990;97(1):23–6.
 34. van Beek EJ, Kuyler PM, Schenk BE, Brandjes DP, ten Cate JW, Buller HR. A normal perfusion lung scan in patients with clinically suspected pulmonary embolism. Frequency and clinical validity. *Chest.* 1995;108(1):170–3.
 35. Anderson DR, Kahn SR, Rodger MA, Kovacs MJ, Morris T, Hirsch A, et al. Computed tomographic pulmonary angiography vs ventilation-perfusion lung scanning in patients with suspected pulmonary embolism: a randomized controlled trial. *JAMA.* 2007;298(23):2743–53.
 36. Begic A, Jogi J, Hadziredzepovic A, Kucukalic-Selimovic E, Begovic-Hadzimiratovic S, Bajc M. Tomographic ventilation/perfusion lung scintigraphy in the monitoring of the effect of treatment in pulmonary embolism: serial follow-up over a 6-month period. *Nucl Med Commun.* 2011;32(6):508–14.
 37. Coche E, Verschuren F, Keyeux A, Goffette P, Goncette L, Hainaut P, et al. Diagnosis of acute pulmonary embolism in outpatients: comparison of thin-collimation multi-detector row spiral CT and planar ventilation-perfusion scintigraphy. *Radiology.* 2003;229(3):757–65.
 38. Harris B, Bailey D, Roach P, Bailey E, King G. Fusion imaging of computed tomographic pulmonary angiography and SPECT ventilation/perfusion scintigraphy: initial experience and potential benefit. *Eur J Nucl Med Mol Imaging.* 2007;34(1):135–42.
 39. Grenier PA, Beigelman C. Ventilation-perfusion scintigraphy in the PLOPED study. Part II. Evaluation of the scintigraphic criteria and interpretations. *J Nucl Med.* 1993;34(7):1119–26.
 40. Mayo JR, Remy-Jardin M, Muller NL, Remy J, Worsley DF, Hossein-Foucher C, et al. Pulmonary embolism: prospective comparison of spiral CT with ventilation-perfusion scintigraphy. *Radiology.* 1997;205(2):447–52.
 41. Bajc M, Neilly JB, Miniati M, Schuemichen C, Meignan M, Jonson B. EANM guidelines for ventilation/perfusion scintigraphy: Part 2. Algorithms and clinical considerations for diagnosis of pulmonary emboli with V/P(SPECT) and MDCT. *Eur J Nucl Med Mol Imaging.* 2009;36(9):1528–38.
 42. Gutte H, Mortensen J, Jensen CV, von der Recke P, Petersen CL, Kristoffersen US, et al. ANP, BNP and D-dimer predict right ventricular dysfunction in patients with acute pulmonary embolism. *Clin Physiol Funct Imaging.* 2010;30(6):466–72.
 43. Mettler Jr FA, Huda W, Yoshizumi TT, Mahesh M. Effective doses in radiology and diagnostic nuclear medicine: a catalog. *Radiology.* 2008;248(1):254–63.
 44. Carrier M, Righini M, Wells PS, Perrier A, Anderson DR, Rodger MA, et al. Subsegmental pulmonary embolism diagnosed by computed tomography: incidence and clinical implications. A systematic review and meta-analysis of the management outcome studies. *J Thromb Haemost.* 2010;8(8):1716–22.
 45. Quiroz R, Kucher N, Zou KH, Kipfmueller F, Costello P, Goldhaber SZ, et al. Clinical validity of a negative computed tomography scan in patients with suspected pulmonary embolism. A systematic review. *JAMA.* 2005;293(16):2012–7.
 46. Stein PD, Goodman LR, Hull RD, Dalen JE, Matta F. Diagnosis and management of isolated subsegmental pulmonary embolism: review and assessment of the options. *Clin Appl Thromb Hemost.* 2012;18(1):20–6.