

An Unusual Case of Colon Perforation Complicating Acute Pancreatitis

Anthony A. Aghenta^a Hack J. Kim^b

^aDepartment of Medicine, Unity Health System, Rochester, N.Y., and ^bDepartment of Gastroenterology and Hepatology, Mayo Clinic, Scottsdale, Ariz., USA

Key Words

Acute pancreatitis · Pancreatic pseudocyst · Colonic perforation

Abstract

Colonic complications of severe acute pancreatitis occur rarely. Although there have been several theories on how pancreatic pseudocysts rupture into the colon, the exact pathogenesis remains unknown. We report an unusual case of pseudocysts complicating severe acute pancreatitis presenting with colonic perforation in a 71-year-old man with a history of chronic mesenteric ischemia. Pressure effects from a giant pseudocyst and intravascular volume depletion with acute insult on chronic mesenteric ischemia are highlighted as possible etiologic factors.

Introduction

Acute pancreatic pseudocysts are amylase-rich, fluid-filled cavities surrounded by a wall of inflammatory or fibrous tissue, typically arising 4 weeks after an episode of acute pancreatitis [1]. The incidence of acute pancreatic pseudocysts is reported to be 5–15% [2, 3]. Complications of severe acute pancreatitis and untreated pancreatic pseudocysts occur infrequently, but with a wide spectrum that includes localized ileus, mechanical obstruction, abscess formation, rupture and perforation into the gastrointestinal tract, and fistula formation [4, 5]. There have been several published case reports and series highlighting the diagnostic and management dilemmas associated with perforations into the colon associated with pseudocysts. The etiology of this condition has remained undetermined, although there are several proposed theories. We report an unusual case of pseudocysts complicating acute pancreatitis presenting with colonic perforation in a patient with a history of chronic mesenteric ischemia.

Case

A 71-year-old man with a long history of alcohol abuse, chronic mesenteric ischemia (celiac and superior mesenteric artery stenosis) status post celiac artery stent placement 17 months prior, was admitted to the hospital with a 1-month history of epigastric pain, anorexia, and 20 lb weight loss. He also had been having worsening postprandial nausea, vomiting and nonbloody diarrhea. On examination he was febrile and tachycardic (heart rate was 102 beats per minute and regular). Abdominal examination was remarkable for diffuse tenderness without guarding or rebound tenderness. Pertinent laboratory values were as follows: hemoglobin 7.8 g/dl; WBC 22,500 cells/mm³ (neutrophils 90.7%); AST 151 IU/l; ALT 81 IU/l; alkaline phosphatase 180 IU/l; total bilirubin 0.5 mg/dl; serum amylase 327 U/l; serum lipase 140 U/l; and serum lactate 2.20 mmol/l. Fecal occult blood test was negative. Computerized axial tomography (CAT) scan of the abdomen confirmed acute pancreatitis with multiple peripancreatic pseudocysts, the largest one adjacent to the pancreatic tail measuring 10.5 cm in diameter (thus, a giant pseudocyst). Interestingly, the pseudocysts were also noted to surround the colon near the splenic flexure ([fig. 1](#)). The celiac artery stent appeared patent and the proximal superior mesenteric artery occlusion was noted to be stable and there was refilling of the more distal superior mesenteric artery by collaterals.

A diagnosis of acute pancreatitis with complex pseudocysts was made. Supportive medical treatment of aggressive hydration and pain management was begun. He was started on intravenous piperacillin-tazobactam for suspected infected pseudocysts. A subsequent magnetic resonance cholangiopancreatography (MRCP) was obtained to further investigate the complex pseudocysts, and this revealed the largest pseudocyst abutting the colon at the splenic flexure. At this location the colon wall appeared thickened with an interval development of air within the giant pseudocyst. In addition, there was a moderate amount of free intraperitoneal air ([fig. 2](#), [fig. 3](#)).

Therapeutic and diagnostic computed tomography (CT) guided percutaneous drainage of the giant pseudocyst was performed. Thick purulent fluid was drained and analysis revealed amylase activity of 119,000 U/l. Fluid culture yielded *Pseudomonas aeruginosa* and *Candida albicans*, confirming infection. Blood cultures remained negative. Intravenous levofloxacin and fluconazole were added to the treatment regimen.

The patient remained stable over several days. Surprisingly on day 5 his condition acutely deteriorated with respiratory distress. His condition gradually improved with conservative supportive management and further observation in the intensive care unit.

Follow-up CAT scan in week 2 revealed a marked decrease in the size of the giant pseudocyst and absence of free intraperitoneal air. His average daily drainage from the giant pseudocyst was down to 15 ml/day from an initial average of 60 ml/day. He was clinically stable for discharge to a skilled nursing facility after a 2.5-week hospital stay.

Discussion

Colonic complications of acute pancreatitis are uncommon. A recent analysis of pooled data reports the incidence of colonic complications from acute pancreatitis and severe acute pancreatitis as 3.3 and 15%, respectively [5]. Because knowledge about colon perforation from acute pancreatic pseudocysts exists mainly from case reports, diagnostic and management dilemmas still persist [5]. [Table 1](#) summarizes a review of published cases of acute pancreatic pseudocysts complicated by colon perforation [6–10].

The natural history of pancreatic pseudocysts varies depending on the cause and severity of the antecedent acute pancreatitis, and also the number, size and location of the pseudocysts [2, 11–14]. Although the exact pathogenesis by which pancreatic pseudocysts rupture into the colon is unknown, there have been several proposed theories [4–6, 9, 10, 15]. This case suggests several possible etiologic factors. First, perforation at the splenic flexure of the colon resulted from pressure exerted by the giant pseudocyst given its close proximity to the bowel. Second, acute mesenteric ischemia and/or acute insult to chronic mesenteric ischemia from intravascular volume depletion caused by severe acute

pancreatitis possibly contributed to acute colonic infarction and subsequent perforation. Third, the combination of the above two conditions.

Aldridge et al. [4] in reporting their experience on colonic complications of severe acute pancreatitis revealed some similar proposed mechanisms of damage to the colon. They suggested that colonic perforation occurs more commonly at the splenic flexure – a watershed area of the colon which closely abuts the pancreatic tail. Hypotension from severe pancreatitis aggravates the predisposition to ischemia at this watershed area. Also, the authors proposed that direct enzyme activity from the dispersion of pancreatic pseudocyst fluid leads to colon inflammation and necrosis. Lastly, they indicated that inflammation and necrosis of the colon may also result from thrombosis of mesenteric and submucosal vessels. This hypothesis according to the authors is based on the presumption that inflammation and edema in the transverse mesocolon when worsened by systemic hypotension precipitates thrombosis which then leads to the retardation of blood flow in the mesenteric vessels.

The management of colonic complications of severe acute pancreatitis relies on a high index of suspicion because the clinical presentation is varied, nonspecific, and could occur quite late in the disease process [5]. Because such cases mainly have been reported as case reports and series, there are no evidence-based guidelines for management [5]. The presentation of the patient as well as the site and severity of the colonic involvement determine whether the utilization of conservative measures such as drainage of the pseudocyst will suffice [5, 6]. Although surgical intervention with colon resection may be difficult and complicated, it remains the choice of treatment when perforation or nonviability of the colon is determined [4–6].

Conclusion

We report a rare case of severe acute pancreatitis with pseudocysts complicated by colon perforation in a patient with a history of chronic mesenteric ischemia. Pressure effects from a giant pseudocyst and intravascular volume depletion with acute insult on chronic mesenteric ischemia are possible etiologic factors.

Table 1.

Table 1. Review of published cases of acute pancreatic pseudocysts complicated by colon perforation

Author	Publi- cation	Age/ sex	Presentation	Alcohol abuse history	Diagnosis/ complication	Sequelae	Perforation site	Diagnostic study	Proposed etiology	Treatment	Out- come
Shatney et al. [6]	1973	63/ male	8 weeks of abdominal pain, weight loss; tender, firm abdominal mass	negative	acute pancreatitis/ pseudocyst; 12 cm diameter	spontaneous pseudocysto- duodenocolostomy	1. duodenum 2. junction of trans- verse colon and splenic flexure	1. EGD 2. barium enema 3. exploratory lap.	not addressed directly	temporary right transverse colostomy	resolved
Barnardo et al. [7]	1974	56/ male	6th episode of severe epigas- tric pain of 45 days duration; palpable left upper quadrant abdominal mass	negative	acute relapsing pancreatitis/ pseudocyst; 6 cm diameter	spontaneous pseudocyst rupture; subsequent fistulous tract from pseudocyst to colon	transverse colon	barium swallow	not addressed	pseudocystec- tomy, distal pancreatectomy	resolved
Khan [8]	1975	47/ male	1-day history of epigastric pain, hematemesis, melena; firm, tender abdominal mass in left upper quadrant	positive	acute pancreatitis/ pseudocyst; 9 cm diameter	spontaneous perfora- tion into colon with disappearance of abdominal mass	transverse colon	1. EGD 2. barium swallow and delayed films 3. barium enema	not addressed	conservative medical management	resolved
Gumaste et al. [9]	1995	45/ male	3 days of epigastric pain, fever, bloody diarrhea	positive	acute pancreatitis/ multiple pseudo- cysts	rectal bleeding	colon segment not specified	1. CT abdomen 2. flexible sigmoidoscopy 3. colonoscopy	not addressed directly	percutaneous needle aspiration	resolved
Jover et al. [10]	1996	28/ male	2 days of epigastric pain, fever, diarrhea	positive	acute pancreatitis/ pseudocyst; 27 cm diameter	spontaneous pseudo- cystocolostomy	colon segment not specified	CT abdomen	local pressure of pseudocyst on colon	CT-guided perforation and drainage	resolved

Fig. 1. CAT scan of the abdomen showing pseudocysts surrounding the colon near the splenic flexure.

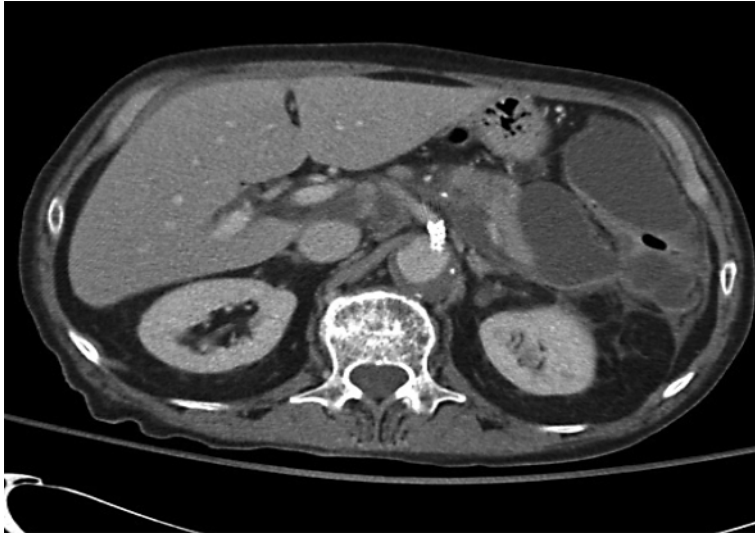

Fig. 2. MRCP showing interval development of free intraperitoneal air under the left hemidiaphragm.

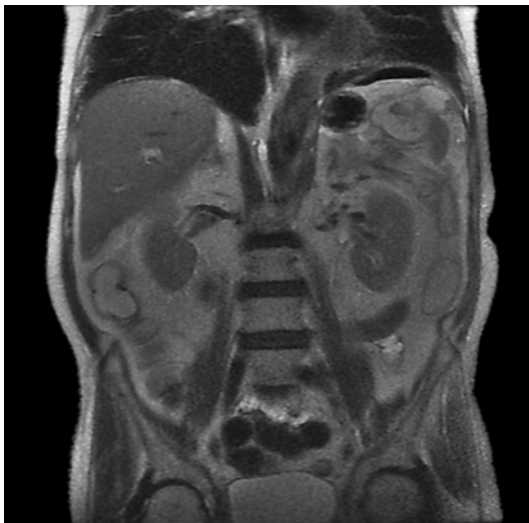
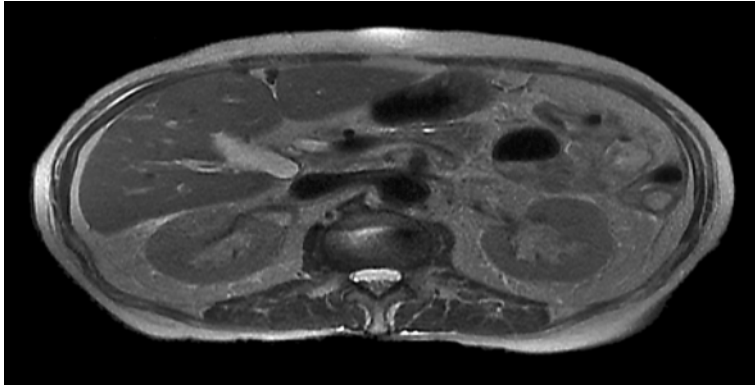


Fig. 3. MRCP showing interval development of air within the largest pseudocyst.



References

- 1 Aghdassi A, Mayerle J, Kraft M, Sielenkamper A, Heidecke C, Lerch M: Diagnosis and treatment of pancreatic pseudocysts in chronic pancreatitis. *Pancreas* 2008;36:105–112.
- 2 London NJ, Neoptolemos JP, Lavelle J, Bailey I, James D: Serial computed tomography scanning in acute pancreatitis: a prospective study. *Gut* 1989;30:397–403.
- 3 Maringhini A, Uomo G, Patti R, Rabitti P, Termini A, Cavallera A, Dardanoni G, Manes G, Ciambra M, Laccetti M, Biffarella P, Pagliaro L: Pseudocysts in acute nonalcoholic pancreatitis: incidence and natural history. *Dig Dis Sci* 1999;44:1669–1673.
- 4 Aldridge MC, Francis ND, Glazer G, Dudley HAF: Colonic complications of severe acute pancreatitis. *Br J Surg* 1989;76:362–367.
- 5 Mohamed SR, Siriwardena AK: Understanding the colonic complications of pancreatitis. *Pancreatol* 2008;8:153–158.
- 6 Shatney CH, Sosin H: Spontaneous perforation of a pancreatic pseudocyst into the colon and duodenum. *Am J Surg* 1973;126:433–438.
- 7 Barnardo DE, Grogono JL, Parks AG: Spontaneous rupture of a pancreatic pseudocyst into the colon. *Dig Dis* 1974;19:1165–1167.
- 8 Khan TA: Spontaneous resolution of a pancreatic pseudocyst by perforation into the colon. *Can J Surg* 1975;18:349–352.
- 9 Gumaste VV, Gupta R, Wasserman D, Dave PB, Vieux U: Colonic involvement in acute pancreatitis. *Am J Gastroenterol* 1995;90:640–641.
- 10 Jover R, Zarco A, Palazon JM: Perforation of pancreatic pseudocyst into the colon: another cause of colonic involvement in pancreatitis. *Am J Gastroenterol* 1996;91:2653.
- 11 Nguyen BT, Thompson JS, Edney JA: Influence of the etiology of pancreatitis on the natural history of pancreatic pseudocysts. *Am J Surg* 1991;162:527–531.
- 12 Behrman S, Melvin M, Ellison E: Pancreatic pseudocysts following acute pancreatitis. *Am J Surg* 1996;172:228–231.
- 13 Soliani P, Ziegler S, Franzini C, Dell'Abate P, Del Rio P, Di Mario F, Cavestro M, Sianesi M: The size of pancreatic pseudocyst does not influence the outcome of invasive treatments. *Dig Liver Dis* 2004;36:135–140.
- 14 Kourtesis G, Wilson SE, Williams RA: The clinical significance of fluid collections in acute pancreatitis. *Am Surg* 1990;56:796–799.
- 15 Adams DB, Davis DR, Anderson MC: Colonic complications of pancreatitis. *Am Surg* 1994;60:44–49.

A.A.A. was a visiting resident while H.J.K. is a consultant gastroenterologist at the Mayo Clinic, Scottsdale, Ariz. Both authors wrote the manuscript, reviewed it and agreed on the final draft. The authors have no financial interest in this work.