

# Vinblastine monotherapy induction prior to radiotherapy for patients with intracranial germinoma during the COVID-19 pandemic

Matthew J. Murray<sup>1,2</sup>  | Rafael Moleron<sup>3</sup> | Jennifer Adamski<sup>4</sup> | Martin English<sup>4</sup> |  
G. A. Amos Burke<sup>2</sup> | Justin Cross<sup>5</sup> | Thankamma Ajithkumar<sup>6</sup> | Sara Stoneham<sup>7</sup>  |  
James C. Nicholson<sup>2</sup>

<sup>1</sup> Department of Pathology, University of Cambridge, Cambridge, UK

<sup>2</sup> Department of Paediatric Haematology and Oncology, Cambridge University Hospitals NHS Foundation Trust, Cambridge, UK

<sup>3</sup> Department of Clinical Oncology, Aberdeen Royal Infirmary, Aberdeen, UK

<sup>4</sup> Department of Paediatric Haematology and Oncology, Birmingham Children's Hospital, Birmingham, UK

<sup>5</sup> Department of Radiology, Cambridge University Hospitals NHS Foundation Trust, Cambridge, UK

<sup>6</sup> Department of Oncology, Cambridge University Hospitals NHS Foundation Trust, Cambridge, UK

<sup>7</sup> Department of Paediatric and TYA Oncology, University College Hospital London, London, UK

## Correspondence

Matthew Murray, Department of Pathology, University of Cambridge, Tennis Court Rd, Cambridge, CB2 1QP, UK.  
Email: [mjm16@cam.ac.uk](mailto:mjm16@cam.ac.uk)

## Abstract

**Background:** Patients with localized intracranial germinoma have excellent survival. Reducing treatment burden and long-term sequelae is a priority. Intensive inpatient chemotherapy (e.g., carboPEI = carboplatin/etoposide/ifosfamide) has been effectively employed to reduce radiotherapy treatment volume/dose. Outpatient-based carboplatin monotherapy is associated with excellent outcomes in metastatic testicular seminoma (an identical pathology), and successful vinblastine monotherapy induction (with 77% tumor volume reduction after just two weekly vinblastine doses) has recently been reported in an intracranial germinoma patient.

**Methods:** Adapted UK guidelines for germ cell tumor management were distributed during the COVID-19 pandemic, including nonstandard treatment options to reduce hospital visits and/or admissions. This included vinblastine monotherapy for intracranial germinoma (6 mg/m<sup>2</sup> intravenously, or 4 mg/m<sup>2</sup> for moderate count suppression, delivered weekly). We describe two such patients treated using this approach.

**Results:** A 30-year-old male with a localized pineal tumor received 12-week vinblastine induction, with >60% volume reduction, prior to definitive radiotherapy. A 12-year-old female with a metastatic suprasellar tumor and progression at all sites of disease whilst awaiting proton radiotherapy received two vinblastine doses with good early response, including 36% primary tumor volume reduction. The patients tolerated vinblastine well.

**Conclusion:** Patients with intracranial germinoma have excellent outcomes, and reduction of late effects remains a priority. The description of vinblastine monotherapy in these intracranial germinoma patients warrants further exploration.

## KEYWORDS

carboPEI, carboplatin, germinoma, intracranial, monotherapy, vinblastine

## 1 | INTRODUCTION

Intracranial germ cell tumors (GCTs) are rare, and diagnosis and management are challenging due to their heterogeneity, for example, regarding differing tumor sites, histological subtypes, and marker expression. For germinoma patients, which comprise the majority of intracranial GCT cases,<sup>1</sup> the internationally agreed priority for future management is to maintain excellent overall survival whilst attempting to reduce treatment burden and minimize late effects and sequelae of treatment.<sup>2</sup> Historically, craniospinal irradiation (CSI) was used to treat all intracranial germinoma patients, regardless of metastatic status,<sup>3,4</sup> although the requirement for CSI in localized disease was questioned.<sup>5</sup> A chemotherapy-only approach for cure has also been attempted but was unsuccessful,<sup>6</sup> and thus radiotherapy remains the definitive treatment. However, use of intensive inpatient induction chemotherapy, prior to radiotherapy, for localized intracranial germinoma patients has been effective in reducing radiotherapy treatment volume and/or dose whilst maintaining survival.<sup>7-9</sup> In Europe, “carboPEI” (alternating courses of carboplatin/etoposide and ifosfamide/etoposide) has been used for this purpose.<sup>7,8</sup> CarboPEI involves prolonged inpatient stays and use of intravenous hydration. Given the common comorbidity of central diabetes insipidus (DI) in patients with neurohypophyseal-suprasellar germinoma, use of a chemotherapy regimen without concomitant intravenous hydration would be a major advantage.<sup>10</sup> Of note, in a study of 32 patients with intracranial GCT receiving cisplatin- and/or ifosfamide-based chemotherapy, 21 (66%) had DI and, furthermore, six of these 21 patients (29%) experienced serious complications.<sup>10</sup> In addition to the challenges of managing DI, carboPEI chemotherapy is associated with short-term toxicities of myelosuppression, vomiting and/or diarrhoea, electrolyte disturbances, which may lead to seizures, renal impairment and elevation of liver enzymes.<sup>8</sup> Long-term sequelae of these drugs include ototoxicity from cisplatin<sup>11</sup> and reduced fertility from alkylating agents (ifosfamide).<sup>12,13</sup> Current chemotherapy regimens also require the use of indwelling central venous access devices, which are associated with increased risk of infection<sup>14</sup> and thrombosis<sup>15</sup> and which may affect quality of life. In North America, the standard-of-care schedule to reduce radiotherapy treatment volume and/or dose is carboplatin–etoposide.<sup>9</sup> Similar to carboPEI, there is an associated, albeit small, second malignancy risk with etoposide.<sup>16</sup>

Of note, outpatient-based single-agent carboplatin chemotherapy is associated with excellent outcomes in metastatic testicular seminoma,<sup>17,18</sup> an identical pathology to intracranial germinoma (and ovarian dysgerminoma). Carboplatin monotherapy, at modest dosing, has also been successfully utilized in intracranial germinoma to allow a reduction in subsequent radiotherapy doses.<sup>19</sup> Furthermore, we recently reported successful vinblastine monotherapy induction, prior to radiotherapy, in a patient with intracranial germinoma.<sup>20</sup> The patient presented with complete loss of vision, and imaging demonstrated a suprasellar lesion, measuring 36 × 28 × 23 mm. The initial working diagnosis was low-grade glioma and accordingly, weekly vinblastine monotherapy was commenced. Vision returned within 4 days of starting vinblastine and after further review, the diagnosis was

revised to germinoma. After dramatic radiological reduction in tumor size after just two vinblastine doses (to 21 × 19 × 12 mm; a 77% volume reduction), a 12-week induction course was delivered, with excellent response, prior to radiotherapy.<sup>20</sup> Importantly, both carboplatin and vinblastine schedules can be successfully delivered peripherally without recourse to placement of a central venous access device.

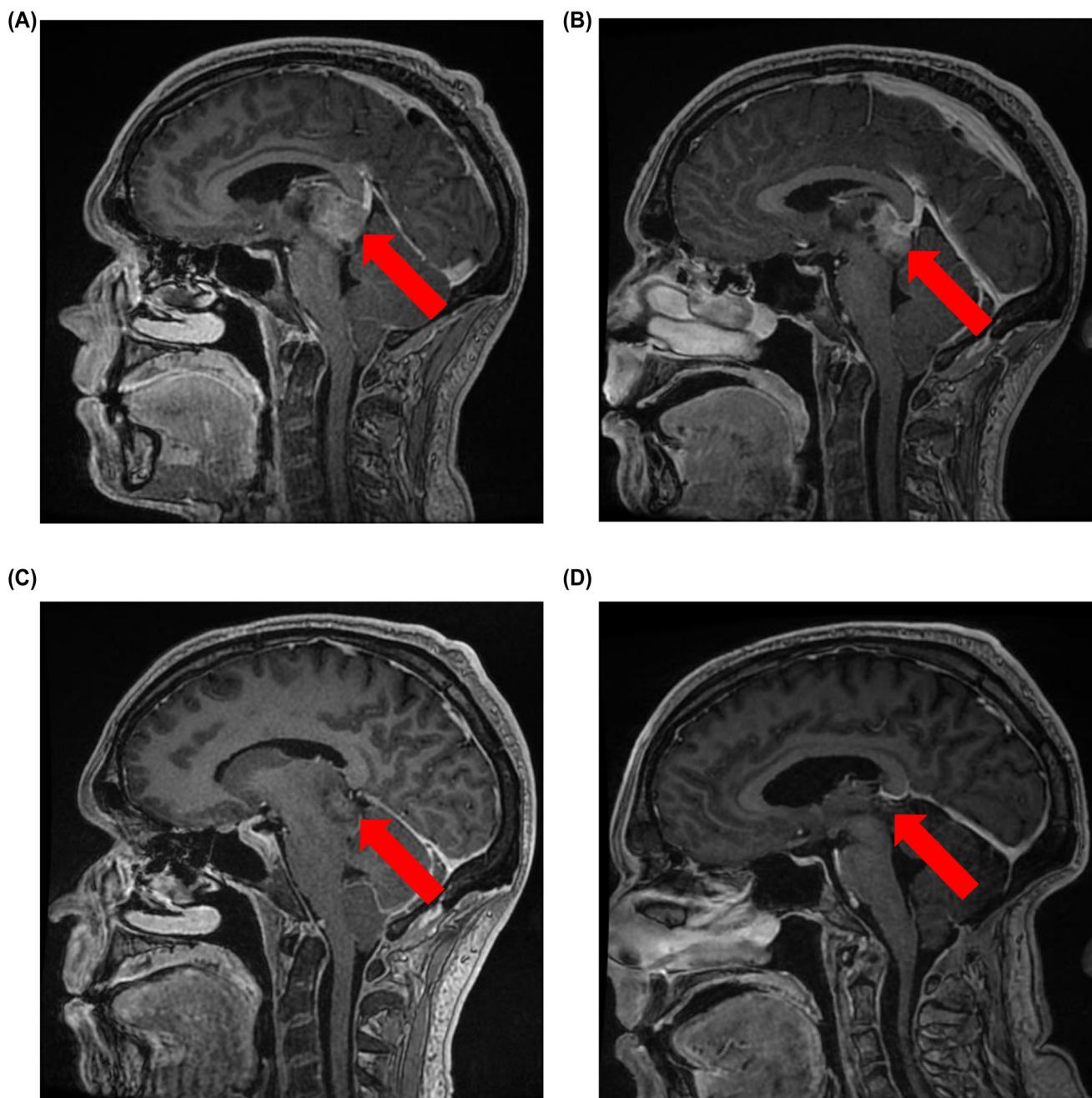
Due to the COVID-19 pandemic, adapted UK guidelines for GCT patient management were distributed to clinicians, including potential nonstandard treatment options that would reduce hospital visits and/or admissions. This included vinblastine monotherapy as an option for intracranial germinoma, based on our case report<sup>20</sup> and practical/pragmatic considerations. We describe two patients successfully treated using this approach. The experience of vinblastine monotherapy in these patients warrants further exploration.

## 2 | CASE REPORTS

### 2.1 | Case 1

A 30-year-old male patient presented with intermittent dizziness, headache, and blurred vision. MRI scan revealed a large, predominantly solid mass in the pineal region, with some cystic elements (Figure 1A). The solid enhancing component measured 28 × 27 (axial dimensions) × 32 mm anterior–posterior (AP) on sagittal images (enhancing tumor volume 12.7 cm<sup>3</sup>). The rest of the neuroaxis showed no evidence of dissemination on imaging. Serum and cerebrospinal fluid (CSF) alpha-fetoprotein (AFP) and human chorionic gonadotrophin (HCG) levels were normal. CSF cytology showed no malignant cells. Morphological and immunohistochemical features of the biopsy were those of a germinoma. The patient required no treatment with steroids.

At the time of the diagnosis, the United Kingdom was at the height of the first wave of the COVID-19 pandemic (April 2020). Options for treatment for this patient with intracranial localized germinoma included CSI or induction chemotherapy, followed by reduced field radiotherapy (focal and whole ventricular irradiation; WVI). However, the patient was very geographically distanced from the treating hospital and wished to minimize hospital admissions and/or visits. Daily travel was not feasible due to the distance from the patient's residence to the treating hospital. CSI or intensive prolonged inpatient chemotherapy would have required a protracted hospital stay at a time when the impact of COVID-19 in hospital and intensive care capacity was uncertain and both would have implied a risk of unplanned admissions with febrile neutropenia. These concerns were discussed with the treating clinician so alternative treatment options, or treatment deferral, were explored. After extensive discussion through the Children's Cancer and Leukaemia Group (CCLG) Germ Cell Tumour National Advisory Panel (GCTNAP; <https://www.cclg.org.uk/NAP/GCT>) and with our recent report of successful intracranial germinoma treatment with vinblastine induction prior to radiotherapy,<sup>20</sup> the joint decision was made with the patient to commence weekly peripheral vinblastine induction, with dosing and modifications as for low-grade glioma.<sup>21,22</sup> Typically, if the weekly full blood count



**FIGURE 1** Representative sagittal T1-weighted MRI head images with contrast for Case 1 (localized pineal germinoma) showing response to treatment. (A) At diagnosis, revealing a large, predominantly solid pineal lesion (arrow). (B) After 6 weeks of induction vinblastine monotherapy showing reduction in size of the pineal lesion (arrow). (C) After 12 weeks of vinblastine revealing further modest response to treatment (arrow). (D) Six months after the end of treatment with definitive radiotherapy, showing a small ill-defined focus of minimally enhancing T1 hyperintensity centered on the site of previous resection (arrow), consistent with further subtle regression of presumed postsurgical changes

(FBC) showed a neutrophil count of  $\geq 0.75 \times 10^9/L$  and platelet count  $\geq 75 \times 10^9/L$ , dosing was continued at  $6 \text{ mg}/\text{m}^2$ . If the neutrophil count was  $< 0.75 \times 10^9/L$  but  $\geq 0.5 \times 10^9/L$  and/or platelet count  $< 75 \times 10^9/L$  but  $\geq 50 \times 10^9/L$ , the dose was reduced to 66% ( $4 \text{ mg}/\text{m}^2$ ). Finally, if the neutrophil count was  $< 0.5 \times 10^9/L$  and/or platelet count  $< 50 \times 10^9/L$ , vinblastine was held until count recovery. Adequate renal and liver function was checked by monthly blood testing.

Appropriate consent for nonstandard treatment was obtained. Due to the older age of the patient (30 years) and anticipated reduction in tolerance, vinblastine was commenced at  $4 \text{ mg}/\text{m}^2$  dosing. This was well tolerated and therefore the dose for week 2 was increased to the standard  $6 \text{ mg}/\text{m}^2$  dose.<sup>21,22</sup> However, this resulted in neutropenia ( $0.5 \times 10^9/L$ ), and a further repeat level 3 days later confirmed ongoing neutropenia ( $0.4 \times 10^9/L$ ) and thus the week 3 dose was completely

omitted. Subsequent doses were all therefore delivered at 4 mg/m<sup>2</sup> and well tolerated, with only minor Common Terminology Criteria for Adverse Events (CTCAE) grade 1 fatigue reported in the final 3 weeks of therapy (weeks 10–12). Median neutrophil count was 1.3 × 10<sup>9</sup>/L (range 0.5–1.9) and platelet count 348 × 10<sup>9</sup>/L (range 255–373) during treatment.

Early-evaluation MRI scan after 6 weeks' vinblastine (five doses; four at 4 mg/m<sup>2</sup>) showed response of the solid enhancing aspect of the pineal lesion (Figure 1B) to 25 × 18 (axial) × 26 mm (AP) dimensions. Although the cystic areas were of similar size, this corresponded to a >50% volume reduction in the solid enhancing component to 6.1 cm<sup>3</sup>. MRI evaluation after 12 weeks of therapy showed a further modest response (Figure 1C), with the solid enhancing component now 20 × 20 (axial) × 23 mm (AP), corresponding to a >60% overall volume reduction to 4.8 cm<sup>3</sup>. Cystic areas of the tumor were still prominent. To exclude any teratoma component given the continued solid and cystic nature of the residual disease, and given nonstandard induction chemotherapy, following careful consideration and discussion, maximal safe resection of the residual pineal mass prior to radiotherapy was advocated and deemed to be feasible neurosurgically. This revealed residual germinoma. Repeat postoperative imaging confirmed complete resection and no other sites of disease. Following recovery from surgery, the patient proceeded safely to radiotherapy (24 Gy CSI with 16 Gy boost; European standard-of-care dosing) at a time when hospital admissions from COVID-19 were at a nadir. The rationale for CSI was that this was the original plan at diagnosis and only deferred due to the COVID-19 pandemic. Furthermore, following an incomplete response to nonstandard vinblastine induction chemotherapy, it was felt prudent, after GCTNAP discussion, to retain this approach. The patient remains well in uneventful clinical follow-up and most recent imaging, 6 months following completion of treatment, reveals only a small ill-defined focus of T1 and T2 hyperintensity with minor associated contrast enhancement centered on the site of previous resection, consistent with further subtle regression of presumed postsurgical changes (Figure 1D). T2/FLAIR sequences (Figure S1) did not provide additional information to that obtained with T1 sequences with contrast.

## 2.2 | Case 2

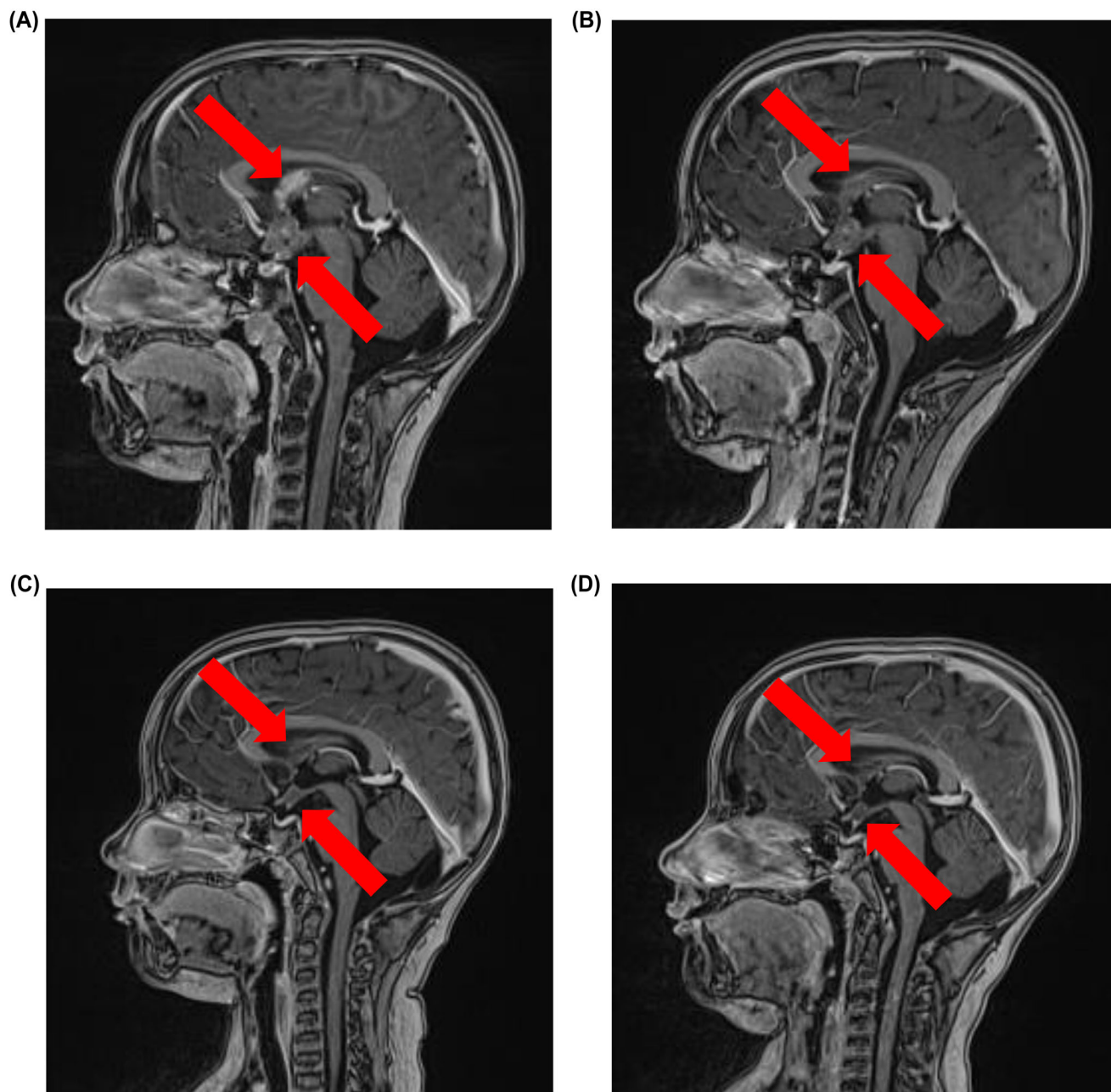
A 12-year-old female was referred to the pediatric endocrine service for growth failure over a 2-year period, with initially normal IGF-1 levels. During investigation DI evolved, and thus an MRI head was undertaken. This was performed during the COVID-19 pandemic and showed a primary neurohypophyseal-suprasellar tumor with contiguous extension involving areas including the cavum septum pellucidum, as well as separate metastatic foci in the anterior horns of the lateral ventricles. Serum and CSF AFP and HCG estimation were normal. MRI spine was normal and CSF cytology was clear. Stereotactic biopsy of the neurohypophyseal-suprasellar lesion, which was undertaken 5 weeks later, confirmed germinoma. A stress dose of hydrocortisone was electively commenced the day prior to surgery due to

a low random cortisol level (285 nmol/L) and continued for 48 hours postoperatively, before reducing to maintenance hydrocortisone treatment (which was continued and then stopped after a satisfactory synacthen test at the end of treatment). Referral for proton radiotherapy (CSI) was made shortly after biopsy (August 2020), for which there was an 8-week delay to start due to the COVID-19 pandemic. Three weeks after proton radiotherapy referral, and 5 weeks following biopsy, a further MRI was performed, which showed evidence of progressive disease at all sites, both primary and metastatic. For example, the primary neurohypophyseal-suprasellar lesion had increased to 20 × 19 × 21 mm diameter (4.2 cm<sup>3</sup>) compared with 19 × 17 × 14 mm (2.4 cm<sup>3</sup>) 9 weeks earlier (Figure 2A). Additional sites of disease progression involved the right anterior septal leaflet at the right foramen of Munro, measuring 7 mm transversely, previously 5 mm. The more midline deposits involving the cavum septum pellucidum had increased in size measuring up to 10 mm, previously 8 mm. The ependymal deposits lining the anterior horns had also increased in size compared with previous. Given the delay from diagnosis to starting CSI for metastatic intracranial germinoma and to prevent the onset of new comorbidities or hydrocephalus, the local multidisciplinary team felt that intervention with chemotherapy treatment prior to CSI was required. The patient did not have central access and due to concerns that myelosuppression from carboPEI chemotherapy may delay radiation planning and delivery, vinblastine was suggested based on our earlier report.<sup>20</sup> The case was discussed at the CCLG GCTNAP and it was agreed that it was reasonable to proceed with weekly vinblastine whilst awaiting the start of proton radiotherapy. Accordingly, two doses at 6 mg/m<sup>2</sup> were delivered peripherally, well tolerated, and allowed cessation with good blood counts in time for protons. The patient developed no new comorbidities during this time. A further MRI scan performed just 4 weeks later, prior to proton radiotherapy, showed a clear response to treatment at all sites, both primary and metastatic. For example, the primary neurohypophyseal-suprasellar lesion had reduced in size to 17 × 16 × 19 mm (2.7 cm<sup>3</sup>) from 4.2 cm<sup>3</sup> previously (a 36% volume decrease) (Figure 2B). Disease involving the cavum septum pellucidum measured 7 mm in diameter, previously 10 mm, and other metastatic disease was similarly reported as much less bulky and not easily measurable, with reduced enhancement. The patient proceeded to proton radiotherapy (24 Gy CSI with 16 Gy boost) and remains well in follow-up, with imaging at the end of treatment showing a further reduction in size of the primary neurohypophyseal-suprasellar lesion to 7 × 10 × 8 mm (0.29 cm<sup>3</sup>) and cavum septum pellucidum disease to a diameter of 6 mm (Figure 2C), with barely discernible/nonmeasurable other sites of metastatic disease. Further imaging 4 months later remained stable (Figure 2D). T2/FLAIR sequences (Figure S2) did not provide additional information to that obtained with T1 sequences with contrast.

## 3 | DISCUSSION

Patients with intracranial germinoma have excellent outcomes, but reducing treatment effects remains a priority.<sup>2</sup> In Europe, carboPEI<sup>7,8</sup>





**FIGURE 2** Representative sagittal T1-weighted MRI head images with contrast for Case 2 (metastatic suprasellar germinoma) showing response to treatment. (A) At initial progression following diagnosis, whilst awaiting proton craniospinal irradiation. Top arrow highlights representative disease of the cavum septum pellucidum and the lower arrow the primary suprasellar lesion. (B) After two doses of vinblastine, revealing a response at both the primary and metastatic sites (arrows). (C) After completion of proton radiotherapy, showing continued response (arrows). (D) Five months after the end of treatment showing stable residual (arrows)

is delivered with large volumes of intravenous hydration, can exacerbate pre-existing DI, particularly where no thirst mechanism is present, and is associated with prolonged inpatient admissions.<sup>20</sup> Such chemotherapy schedules are also associated with short-<sup>8</sup> and long-term<sup>11–13,16</sup> toxicities and, moreover, require central venous access devices for delivery, with associated infection and thrombosis risk.<sup>14,15</sup> A further UK intracranial germinoma case, in addition to the two formally described here, received two vinblastine doses to complete induction as a “bridge” to radiotherapy with stable radiological appear-

ances; this patient developed ifosfamide encephalopathy<sup>23</sup> during standard-of-care carboPEI chemotherapy and experienced a fall and subdural hematoma. Even the standard-of-care schedule in North America (carboplatin–etoposide)<sup>9</sup> is associated with the additional long-term toxicities of etoposide, which includes second malignancy.<sup>16</sup>

Regarding definitive radiotherapy, currently patients with metastatic intracranial germinoma receive 24 Gy CSI with boost of 16 Gy (to 40 Gy) for macroscopic disease. Although patients are eligible for proton beam therapy, due to the logistical challenges of travel

to a distant center, patients and parents may choose to have photon treatment more locally. In addition, during the COVID-19 pandemic, there were delays in starting timely radiotherapy, which necessitated a “bridging” strategy to prevent further tumor growth (Case 2). During this time, tumors may grow and cause additional comorbidities such as visual loss, hormone dysfunction, and/or hydrocephalus; consequently, there is interest in using gentle “window” chemotherapy to bridge individuals to radiotherapy. If successful, this may also facilitate a reduction in radiotherapy treatment volume for macroscopic disease at diagnosis.

The malignant GCT subtype germinoma and its extracranial testicular counterpart seminoma are indistinguishable pathologically, with biological evidence suggesting that these tumors share a common molecular pathogenesis.<sup>24</sup> Germinoma/seminoma are known to be exquisitely chemosensitive, in addition to their radiosensitivity. Carboplatin monotherapy has been successfully employed for metastatic testicular seminoma with excellent outcomes<sup>17,18</sup> and at modest dosing has been utilized in intracranial germinoma permitting radiotherapy dose reductions.<sup>19</sup> Vinblastine has also been used within multi-agent regimens to treat intracranial germinoma,<sup>25</sup> and the induction response to vinblastine monotherapy<sup>20</sup> is noteworthy. Weekly vinblastine monotherapy is well tolerated with minimal side effects for treatment of other central nervous system conditions such as low-grade glioma and Langerhans cell histiocytosis.<sup>21,22,26</sup> It can also be delivered peripherally as an intravenous bolus in an outpatient setting in some treatment centers.<sup>20</sup> Further potential advantages of monotherapy induction for intracranial germinoma include patient and carer benefit, consistent with recent patient and public involvement (PPI) work<sup>27</sup> and benefit for lower- and middle-income countries (Supporting Information: Discussion).

Our case series has a number of limitations. The numbers of patients described is very small and only one of the two patients received a “full” induction course. However, the cases described here during the COVID-19 pandemic, along with a previously described case,<sup>20</sup> suggest that further investigation is warranted to assess the role for induction monotherapy, prior to definitive radiotherapy, more formally in the context of a clinical trial. This should include study of complete remission rates after induction, as in future this may allow omission of radiotherapy boosts. In addition, it should be noted that any potential reduction in therapy for cancer could be associated with a theoretical increase in relapse risk. Consequently, prior to implementation, it is important to understand how effective any treatment for potential relapse is. Due to the effectiveness of existing therapies, relapsed intracranial germinoma is rare and data are relatively sparse. However, evidence to date shows that patients with relapsed germinoma can be successfully cured, even following the intensity of current first-line therapy.<sup>28–30</sup>

In summary, patients with intracranial germinoma have excellent outcomes and reduction of treatment effects remains a priority. The chemosensitivity of germinoma and description of vinblastine monotherapy in these two cases, along with our previous report,<sup>20</sup> warrant further exploration.

## ACKNOWLEDGMENTS

We thank the patients, their families, and the clinical teams who, after discussion, consented to nonstandard treatment with vinblastine as part of the management of intracranial germinoma during the COVID-19 pandemic and consented to publication. We thank Dr Richard Gagan, Neuroradiology Department, Birmingham Children’s Hospital for assistance in provision of the representative images for Case 2.

## CONFLICT OF INTEREST

The authors declare that there is no conflict of interest.

## AUTHOR CONTRIBUTIONS

Study concept: Matthew J. Murray and James C. Nicholson. Clinical input: Matthew J. Murray, Rafael Moleron, Jennifer Adamski, Martin English, G. A. Amos Burke, Justin Cross, Thankamma Ajithkumar, Sara Stoneham, and James C. Nicholson. Manuscript writing: Matthew J. Murray and James C. Nicholson. Manuscript revision and approval: Matthew J. Murray, Rafael Moleron, Jennifer Adamski, Martin English, G. A. Amos Burke, Justin Cross, Thankamma Ajithkumar, Sara Stoneham, and James C. Nicholson.

## DATA AVAILABILITY STATEMENT

The data that support the findings of this study are available from the corresponding author upon reasonable request.

## ORCID

Matthew J. Murray  <https://orcid.org/0000-0002-4480-1147>

Sara Stoneham  <https://orcid.org/0000-0001-5482-648X>

## REFERENCES

- Murray MJ, Nicholson JC. Germ cell tumours in children and adolescents. *Paediatr Child Health*. 2010;20(3):109–116.
- Murray MJ, Bartels U, Nishikawa R, Fangusaro J, Matsutani M, Nicholson JC. Consensus on the management of intracranial germ-cell tumours. *Lancet Oncol*. 2015;16(9):e470–e477.
- Sung DII, Harisiadis L, Chang CH. Midline pineal tumors and suprasellar germinomas: highly curable by irradiation. *Radiology*. 1978;128(3):745–751.
- Shibamoto Y, Abe M, Yamashita J, et al. Treatment results of intracranial germinoma as a function of the irradiated volume. *Int J Radiat Oncol Biol Phys*. 1988;15(2):285–290.
- Linstadt D, Wara WM, Edwards MSB, Hudgins RJ, Sheline GE. Radiotherapy of primary intracranial germinomas: the case against routine craniospinal irradiation. *Int J Radiat Oncol Biol Phys*. 1988;15(2):291–297.
- Kellie SJ, Boyce H, Dunkel IJ, et al. Intensive cisplatin and cyclophosphamide-based chemotherapy without radiotherapy for intracranial germinomas: failure of a primary chemotherapy approach. *Pediatr Blood Cancer*. 2004;43(2):126–133.
- Bouffet E, Baranzelli MC, Patte C, et al. Combined treatment modality for intracranial germinomas: results of a multicentre SFOP experience. Societe Francaise d’Oncologie Pediatrique. *Br J Cancer*. 1999;79(7–8):1199–1204.
- Calaminus G, Kortmann R, Worch J, et al. SIOP CNS GCT 96: final report of outcome of a prospective, multinational nonrandomized trial for children and adults with intracranial germinoma, comparing craniospinal irradiation alone with chemotherapy followed by focal

- primary site irradiation for patients with localized disease. *Neuro Oncol*. 2013;15(6):788-796.
9. Khatua S, Dhall G, O'Neil S, et al. Treatment of primary CNS germinomatous germ cell tumors with chemotherapy prior to reduced dose whole ventricular and local boost irradiation. *Pediatr Blood Cancer*. 2010;55(1):42-46.
  10. Afzal S, Wherrett D, Bartels U, et al. Challenges in management of patients with intracranial germ cell tumor and diabetes insipidus treated with cisplatin and/or ifosfamide based chemotherapy. *J Neurooncol*. 2010;97(3):393-399.
  11. Wong J, Goddard K, Laperriere N, et al. Long-term toxicity of intracranial germ cell tumor treatment in adolescents and young adults. *J Neurooncol*. 2020;149(3):523-532.
  12. Williams D, Crofton PM, Levitt G. Does ifosfamide affect gonadal function? Does ifosfamide affect gonadal function? *Pediatr Blood Cancer*. 2008;50(2):347-351.
  13. Medrano JV, Hervás D, Vilanova-Pérez T, et al. Histologic analysis of testes from prepubertal patients treated with chemotherapy associates impaired germ cell counts with cumulative doses of cyclophosphamide, ifosfamide, cytarabine, and asparaginase. *Reprod Sci*. 2021;28(2):603-613.
  14. Van Den Bosch CH, Van Der Bruggen JT, Frakking FJ, et al. Incidence, severity and outcome of central line related complications in pediatric oncology patients; a single-center study. *J Pediatr Surg*. 2019;54(9):1894-1900.
  15. Tian L, Li W, Su Y, et al. Risk factors for central venous access device-related thrombosis in hospitalized children: a systematic review and meta-analysis. *Thromb Haemost*. 2021;121(5):625-640.
  16. Kier MG, Hansen MK, Lauritsen J, et al. Second malignant neoplasms and cause of death in patients with germ cell cancer: a Danish nationwide cohort study. *JAMA Oncol*. 2016;2(12):1624-1627.
  17. Tookman L, Rashid S, Matakidou A, et al. Carboplatin AUC 10 for IGCCCG good prognosis metastatic seminoma. *Acta Oncol*. 2013;52(5):987-993.
  18. Alifrangis C, Sharma A, Chowdhury S, et al. Single-agent carboplatin AUC10 in metastatic seminoma: a multi-centre UK study of 216 patients. *Eur J Cancer*. 2020. <https://doi.org/10.1016/j.jejca.2020.08.031>
  19. Allen JC, DaRosso RC, Donahue B, Nirenberg A. A phase II trial of preirradiation carboplatin in newly diagnosed germinoma of the central nervous system. *Cancer*. 1994;74(3):940-944.
  20. Murray MJ, Ajithkumar T, Harris F, et al. Clinical utility of circulating miR-371a-3p for the management of patients with intracranial malignant germ cell tumors. *Neurooncol Adv*. 2020;2(1):vdaa048.
  21. Lafay-Cousin L, Holm S, Qaddoumi I, et al. Weekly vinblastine in pediatric low-grade glioma patients with carboplatin allergic reaction. *Cancer*. 2005;103(12):2636-2642.
  22. Lassaletta A, Scheinmann K, Zelcer SM, et al. Phase II weekly vinblastine for chemotherapy-naïve children with progressive low-grade glioma: a Canadian pediatric brain tumor consortium study. *J Clin Oncol*. 2016;34(29):3537-3543.
  23. Ataseven E, Goktepe SO, Kantar M. Ifosfamide-related encephalopathy with severe clinical presentations in children with cancer. *J Oncol Pharm Pract*. 2021:10781552211005533. <https://doi.org/10.1177/10781552211005533>
  24. Ichimura K, Fukushima S, Totoki Y, et al. Recurrent neomorphic mutations of MTOR in central nervous system and testicular germ cell tumors may be targeted for therapy. *Acta Neuropathol*. 2016;131(6):889-901.
  25. Matsukado Y, Abe H, Tanaka R, et al. [Cisplatin, vinblastine and bleomycin (PVB) combination chemotherapy in the treatment of intracranial malignant germ cell tumors—a preliminary report of a phase II study—the Japanese Intracranial Germ Cell Tumor Study Group]. *Gan No Rinsho*. 1986;32(11):1387-1393.
  26. Ng Wing Tin S, Martin-Duverneuil N, Idbaih A, et al. Efficacy of vinblastine in central nervous system Langerhans cell histiocytosis: a nationwide retrospective study. *Orphanet J Rare Dis*. 2011;6:83.
  27. The UK top research priorities for living with and beyond cancer. NCRI. 2019. Accessed May 17, 2021. <https://www.ncri.org.uk/the-uk-top-10-research-priorities-for-living-with-and-beyond-cancer/>
  28. Modak S, Gardner S, Dunkel IJ, et al. Thiotepa-based high-dose chemotherapy with autologous stem-cell rescue in patients with recurrent or progressive CNS germ cell tumors. *J Clin Oncol*. 2004;22(10):1934-1943.
  29. Murray MJ, Bailey S, Heinemann K, et al. Treatment and outcomes of UK and German patients with relapsed intracranial germ cell tumors following uniform first-line therapy. *Int J Cancer*. 2017;141(3):621-635.
  30. Callec L, Lardy-Cleaud A, Guerrini-Rousseau L, et al. Relapsing intracranial germ cell tumours warrant retreatment. *Eur J Cancer*. 2020;136:186-194.

## SUPPORTING INFORMATION

Additional supporting information may be found in the online version of the article at the publisher's website.

**How to cite this article:** Murray MJ, Moleron R, Adamski J, et al. Vinblastine monotherapy induction prior to radiotherapy for patients with intracranial germinoma during the COVID-19 pandemic. *Pediatr Blood Cancer*. 2022;69:e29359. <https://doi.org/10.1002/pbc.29359>