

# Outcome-based Comparative Study to Examine the Correction of Columella Deformities following Rhinoplasty

Rajan Uppal, FRCS(Ed), MSc,  
FRCS(Plast)\*  
Ali H. Yousif, MRCS, MSc,  
FRCS(Plast)†  
Kavish Maheshwari, MRCS,  
MCh(Plast)†

**Background:** The columella is an underrepresented part of rhinoplasty. The objective of this study was to assess the outcome of columella correction following rhinoplasty and to assess any differences in the open and endonasal approach.

**Methods:** This is a retrospective study involving 65 rhinoplasty patients, who were divided into 2 groups depending on whether they had an open or endonasal approach. Fifteen patients underwent the open procedure, and 50 patients underwent the endonasal approach. Patients who underwent endonasal rhinoplasty were compared with open rhinoplasty patients in terms of their final outcome, with a focus on the columellar correction. The classification by Rohrich and Liu and Gunter's distance between the nasal axis and columella were used to assess the correction.

**Results:** The overall incidence of columellar correction was 90% in the endonasal group (45 of 50 patients) and 67% in the open approach group (10 of 15 patients); a comparison shows a *P* value of 0.043 (<0.05). An estimated 49 of 50 patients (98%) from the endonasal group saw a reduction in the nasal axis–columella distance when compared with the open rhinoplasty group, who saw a reduction in 12 of 15 patients (80%); statistical analysis shows a *P* value of 0.036 (<0.05). The quantitative reduction in this distance in all patients when compared between the 2 groups had a *P* value of <0.001, suggesting a greater overall reduction using the endonasal approach. This may be related to differences in distribution of the deformities within the 2 groups.

**Conclusions:** There is no standard way to correct the columella, but it is important to identify the deformity and the need to correct it. In our patients, we found comparable outcomes in achieving a satisfactory columella in the open and endonasal groups. (*Plast Reconstr Surg Glob Open* 2020;8:e3001; doi: 10.1097/GOX.0000000000003001; Published online 27 July 2020.)

## INTRODUCTION

Rhinoplasty is an art form. The modern rhinoplasty patient is the most informed and aware patient in plastic surgery. Patients have become discerning judges of what constitutes a good outcome from rhinoplasty<sup>1</sup>; the opinion of the surgeon may not always concur with this.

In current practice, this is a challenge that presents itself routinely in the office or clinic when talking to patients who are about to embark on this complex operation or who have undergone rhinoplasty.<sup>2</sup> There is no doubt that across the United States, Europe, Middle East, and South America, there is a huge variability in the tolerance of patients toward a poor outcome. It has become a fad to share rhinoplasty outcome images widely on social media.<sup>3</sup>

The complexity arises from the difference in shadows and variability in image that patients see. This is partly due to the fact that patients do not notice this area as an important aspect.<sup>3</sup> Patients rarely present to the surgeon with the columella as a primary concern. This all changes after surgery, however, when any anomaly is analyzed and amplified.

From the \*Department of Plastic and Reconstructive Surgery, Wexham Park Hospital and Uppal Plastic Surgery Clinic, London, United Kingdom; and †Department of Plastic and Reconstructive Surgery, Bedford Hospital NHS Trust, Bedford, United Kingdom.

Received for publication January 22, 2020; accepted June 3, 2020.

Presented at the Bergamo Open Rhinoplasty Course, March 15-19, 2016, Italy, and at the London Rhinoplasty Course, November 2, 2019.

Copyright © 2020 The Authors. Published by Wolters Kluwer Health, Inc. on behalf of The American Society of Plastic Surgeons. This is an open-access article distributed under the terms of the [Creative Commons Attribution-Non Commercial-No Derivatives License 4.0 \(CCBY-NC-ND\)](#), where it is permissible to download and share the work provided it is properly cited. The work cannot be changed in any way or used commercially without permission from the journal.

DOI: 10.1097/GOX.0000000000003001

**Disclosure:** The authors have no financial interest to declare in relation to the content of this article.

Related Digital Media are available in the full-text version of the article on [www.PRSGlobalOpen.com](http://www.PRSGlobalOpen.com).

**Table 1. Description of Classification of Columellar Deformities by Gunter et al<sup>5</sup> and Rohrich and Liu<sup>4</sup>**

| Type of Deformity                              | Description   |
|--|---|
| Classification by Gunter et al <sup>5</sup> ** |   |
| I  | Hanging columella (columella to long axis distance of >2mm) |
| II   | Retracted ala (alar rim to long axis distance of >2mm)      |
| III  | Combination of I and II                                     |
| IV   | Hanging ala (alar rim to long axis distance <1 mm)          |
| V  | Retracted columella (columella to long axis distance <1 mm) |
| VI   | Combination of IV and V                                     |
| Classification by Rohrich and Liu <sup>4</sup> |   |
| I  | Middle crus too long  |
| II   | Middle crus too wide  |
| III  | Lower lateral malposition/asymmetry                         |
| IV   | Combination of I-III  |
| V  | Extrinsic: prominent caudal septum/angle                    |

\*Normal relationship of ala-columella: distance of 1-2mm between long axis of nostril and either columella or alar rim.

We present a series of 65 patients who have had a detailed assessment of their columella and grading according to the classification by Rohrich and Liu<sup>4</sup> and Gunter’s distance<sup>5</sup> (Table 1) measured between the columella and long nasal axis, both before surgery and afterward. The open method of rhinoplasty is compared with the endonasal approach.

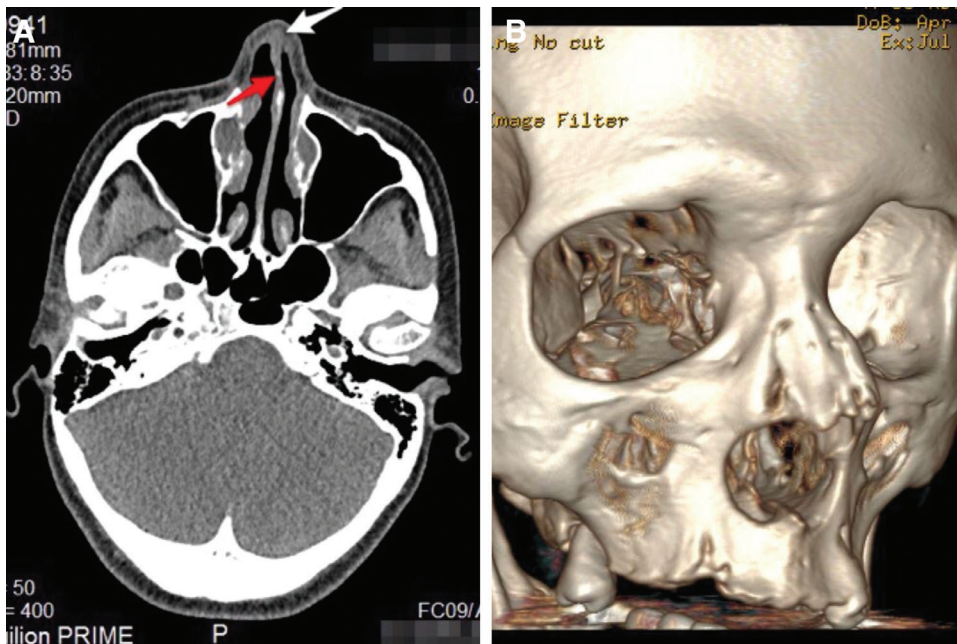
**PATIENTS AND METHODS**

We did a retrospective study on 65 patients who underwent rhinoplasty to assess the correction of the columella. All patients underwent ≥2 detailed consultations,

morphing software to aid planning and detailed preoperative counseling with printed documents to manage expectations. The Plastic Surgery Simulator app was used for morphing. More accurate software was avoided to prevent unrealistic expectations from the patient. The morphing software was not used to promote the procedure but rather to demonstrate how minor changes to the nose can have a major impact on the outcome. Computed tomography scans were used for preoperative planning in cases that were thought to be complex for any reason, such as significant breathing issues or a history of sinus infection (Fig. 1). This imaging helps identify abnormalities and aids discussion in a multidisciplinary team.

Pre- and postoperative photographs were analyzed to assess the improvement in final columella using the classification by Rohrich and Liu<sup>4</sup> and the Gunter’s distance between the long axis of the nostril and columella. The 65 patients chosen for the study were consecutive patients of the senior author for each technique, and randomization was not possible. The minimum follow-up was 7 months with a mean of 9 months. A member of the team, who was not related to the surgery of these patients, performed these measurements to eliminate any bias. An absence of any aberrance of the columella (type 0) was considered the ideal postoperative result, and a reduction in Gunter’s distance was considered another parameter of improvement. A  $\chi^2$  test judging patients of endonasal approach versus open approach was done to assess patients in the postoperative period for the correction of their columellar deformity.

No conflict of interest is declared. All patients gave consent for use of their photographs for publication.



**Fig. 1.** CT head showing soft tissues. Patients with functional problems, or a history of sinus issues, underwent CT scanning to aid treatment planning. As well as bone images, soft-tissue sequences were requested to assess the nose cartilages and septum (A). The CT shows a bend in the septum (red arrow) and asymmetry of the lower laterals (white arrow), indicating a more complex operation. The 3D reconstruction aids classification of the severity of any abnormalities of structure and reveals any latent deformity caused by previous injury (B). 3D indicates 3-dimensional; CT, computed tomography.

The study followed ethical principles according to the Declaration of Helsinki.

### Surgical Technique

This procedure is performed under general anesthesia to maintain a safe airway in an operating theater. We are aware of this procedure being performed under the so-called “Twilight” anesthesia, in an office setting. However, we do not recommend any form of such benzodiazepine anesthesia because control of the airway can be lost. Moreover, any form of office-based rhinoplasty done under local anesthesia does not allow osteotomies to be performed.

Infiltration is performed using local anesthesia (lidocaine 1:200,000 with adrenaline) using a dental syringe. Hydrodissection of the mucosa, septum, and dorsum is performed. Skin markings are then placed at the midline, at the mid pupil lines, and at the alar base line. Intracartilagenous incisions are formed on both sides. For endonasal rhinoplasty, a cross-cartilaginous approach is used, as described in the senior author’s previous publication.<sup>6</sup> In the open rhinoplasty group, a step incision is used to lift the columella.

For the endonasal approach, dissection then proceeds along a submucosal plane (Fig. 2). This continues along a subperichondrial and subperiosteal dissection plane along the dorsum of the nose to radix. Many publications and surgeons maintain that this plane is straightforward. However, in the senior author’s experience, this plane is difficult to maintain for even the most experienced surgeon. There are often adhesions along the way, and the tissues themselves can be tenuous, making them prone to puncture. Diligent dissection to maintain this plane will reduce excessive bleeding and bruising.

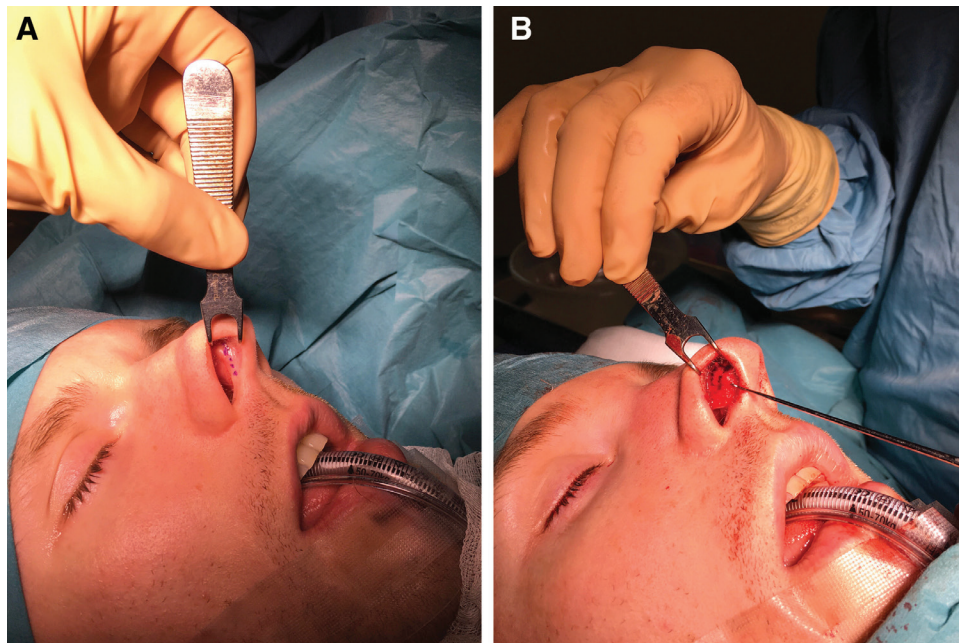
Dissection proceeds to maintain the soft-tissue structures by performing a sub-superficial muscular aponeurotic system (SMAS) dissection. This minimizes bruising and swelling of the soft-tissue envelope, which in turn is likely to reduce secondary long-term fibrosis and contractures.

The septum is examined in detail. Any airway obstruction by septum is identified and noted. It is important to differentiate the exact shape and size of the septum. It is important also to note down whether the obstruction is high or low. Following a thorough intraoperative assessment, an appropriate surgical plan can be executed.

Submucosal dissection is performed on both sides. Mucosal flaps are raised on either side of the septum to expose its structure. Diligence in dissection is required here to avoid perforation of the mucosa, which can cause secondary changes and fibrosis. Damage to this mucosa can also result in crusting such that patients feel that their airway is affected due to the dryness of the mucosa.

The inferior attachment of the septum is mobilized off the nasal spine, if required. Any deviation of the septum is corrected. The septum is then fixed in position on the nasal spine, with polydioxanone 5-0 sutures (PDS).

The septal cartilage is identified to the vomer. A resection of the septal cartilage (measuring 3-mm wide by 10-mm long) is performed. This allows harvest of a septal cartilage graft for a columellar strut as well as improving any deviation in the septum. If there is inadequate septum for a columellar strut or the quality of the cartilage is not strong enough for a strut support, then cartilage graft harvest is performed from an alternative site. It is important to avoid a septal perforation. Polyglactin 5-0 sutures are placed at the site to close any dead space between the mucosa of the septum.



**Fig. 2.** Intraoperative endonasal rhinoplasty access. Good access and visibility are possible, allowing access to the lower lateral and upper lateral cartilages. A, Before incision. B, After dissection in submucous plane.

A functional assessment of the airway is essential. It will include assessment of the inferior turbinates. If there is excess mucosa or prominence of the inferior turbinates that is reducing the airway, these are treated at this time. It is possible to undertake an out-fracture of the inferior turbinates, if needed. A further functional assessment is performed at the end of this procedure to ensure that there is a good airway on both sides. Contrary to popular belief, spreader grafts are not always needed. In fact, the senior author only uses them in a minority of cases where airway compromise is detected or considered likely.

It is important to maintain sufficient support of the nose with an appropriate L-shaped septal support of 11–12 mm in width. A curve is added at the inner angle of the L-shaped support, to avoid fracture of this structure. A hemitransfixion incision is performed, which is also called a Killian incision. The septal angle is dissected and exposed in a submucosal plane. The height of the septal angle is reduced by 3 mm. A slight supratip break allows for any tip retraction. The caudal end of the septal angle is reduced by 2 mm to reduce columella show. Columellar dissection of the medial crura of lower laterals is performed to improve columellar show and to create a pocket for a graft. (See Video [online], which displays how access is gained via a hemitransfixion incision. A pocket is created in between the medial crura and up to the domes. Care must be taken not to puncture the thin skin at this site. The strut is inserted, and the outcome is measured in real time. If the strut is too long or visible through the skin, it is shortened by 1 mm at a time. It is then fixed in place with interrupted 5/0 PDS.)

The bony vault is treated next to remove any bony hump. An oscillating saw is used where required. Excess cartilage is also removed at this time to reduce height as appropriate and to create the desired dorsal line. The height reduction is checked laterally at all times to ensure a good outcome and avoid over resection. Osteotomies are then performed using a guarded osteotome with an endonasal technique. An in-fracture is performed to close the open roof after the bony bump removal and then a rasp is used to smooth any irregularities. The upper lateral cartilages are not disarticulated from the septum to avoid compromise of the internal valve. They are turned in as flaps where needed to maintain the internal valve.

A medial crural suspension suture is then applied to the septum (polydioxanone 5-0) to reduce tip retraction and maintain tip support. A tongue in groove approach

aids stability and improvement in the columella outcome. A release of the depressor nasi septi is performed.

The lower lateral cartilages are identified, and a conservative cephalic trim is performed measuring 2–4 mm in width. A rim of support of 6 mm in width is left behind. The vestibular mucosa is preserved to protect the internal valve. These measurements need to be accurately documented for any future surgery if needed and for medico-legal record keeping. A delivery technique is used to apply interdomal sutures using polydioxanone 5-0 for support and tip definition.

A columellar strut is then prepared by cutting the graft to the correct shape and to a length of approximately 11 mm. This is inserted into a pocket in between the medial crura. The strut is fixed to the septum via a hemitransfixion incision using polydioxanone 5-0. Good tip support is achieved. A septal extension graft is also acceptable for this purpose, but the senior author prefers a central strut to support the tip. A final assessment is made, and dissection performed to smooth the outline and remove any irregularities. The mucosa is closed using rapidly absorbing polyglactin 5-0. Wound closure strips are used to mould the shape and a thermoplastic splint is applied as standard. The technique for the open approach is as standard as and similar to the above description, except that spreader grafts are necessary in 3 patients, where airway compromise is a risk and the aesthetic lines demanded them.

## RESULTS

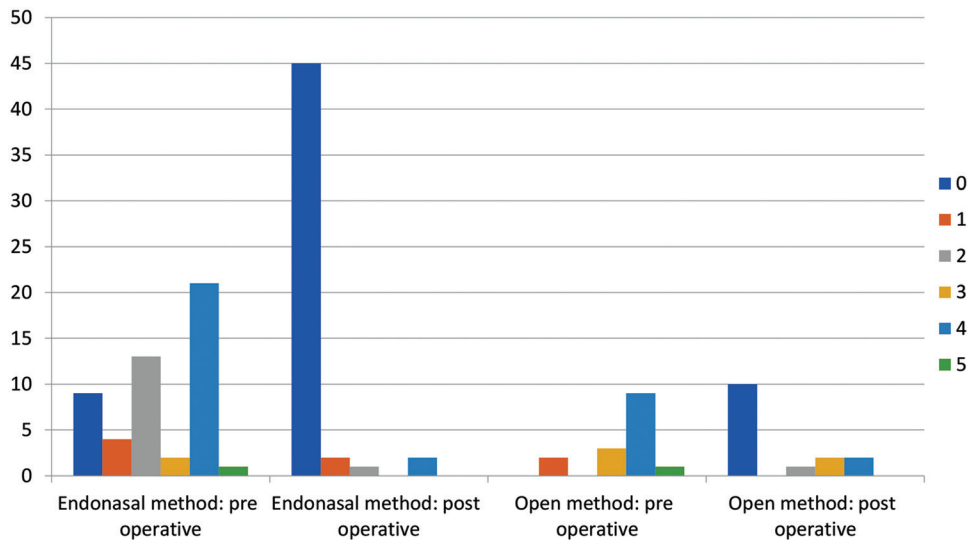
The study enrolled 65 patients who underwent rhinoplasty performed by the senior author in all patients. Fifteen patients underwent the open procedure, and 50 patients underwent the endonasal approach. These constituted our control and study groups, respectively. In our study, there were 7 men and 58 women, with age ranging from 22 to 38 years (average age: 28.55 years). Forty-five of these women and 5 men underwent endonasal rhinoplasty, whereas 13 women and 2 men underwent open procedure. When compared for sex and age, both the groups were comparable with nonsignificant *P* values, 0.721 and 0.073, respectively, and thus signifying an equitable distribution. The distribution of the classification types of the columella before surgery by Rohrich and Liu<sup>4</sup> is described in Table 2 and Figure 3.

The incidence of this correction was found greater in the endonasal approach group (45 of 50 patients), with a *P* value of 0.043 (<0.05) when compared with the open approach group (10 of 15 patients). Then 9 patients, who

**Table 2. Distribution of Types of Columella Aberrancies Using the Classification by Rohrich and Liu<sup>4</sup>**

| Type of Deformity by Rohrich and Liu <sup>4</sup> | 0          | 1         | 2        | 3         | 4         | 5        | Total |
|---|------------|-----------|----------|-----------|-----------|----------|-------|
| Endonasal method                                  |            |           |          |           |           |          |       |
| Preoperative                                      | 9 (18%)    | 4 (8%)    | 13 (26%) | 2 (4%)    | 21 (42%)  | 1 (2%)   | 50    |
| Postoperative                                     | 45 (90%)   | 2 (4%)    | 1 (2%)   | 0         | 2 (4%)    | 0        | 50    |
| Open method                                       |            |           |          |           |           |          |       |
| Preoperative                                      | 0          | 2 (13.3%) | 0        | 3 (20%)   | 9 (60%)   | 1 (6.7%) | 15    |
| Postoperative                                     | 10 (66.7%) | 0         | 1 (6.7%) | 2 (13.3%) | 2 (13.3%) | 0        | 15    |

The data show our patients pre- and postoperatively in both the open and endonasal groups. The hanging columella type IV was the most common aberrancy in all groups. A good improvement was demonstrated in both the open and endonasal rhinoplasty groups although the endonasal approach had a slightly higher frequency of good outcome.



**Fig. 3.** Distribution of type of columellar deformity. The graph shows good improvement in the columella in both groups. The most common aberrancy is type IV in each group. The endonasal approach showed a more frequent improvement, but this may be due to a larger number which is a confounding variable (n = 15 open and n = 37 endonasal approach).

did not have the deformity to begin with, were removed, and the same analysis was performed (Table 3); the endonasal approach group (37 of 41 patients) fared better with a *P* value of 0.048 (<0.05). This suggests that the endonasal approach has better chances of correcting a visible columellar deformity. We note however that the open group (15) is smaller than the endonasal group (50). This difference is because patients underwent open rhinoplasty in our practice before 2015 and closed after that. Because we enrolled consecutive patients from our practice for the study, randomization was not possible. These may be confounding factors in this study and also a weakness of the study; however, the operating surgeon was the same in all patients.

We also measured Gunter’s distance for our patients both preoperatively and postoperatively as shown in Figure 4 (for both open and endonasal groups). The range of columellar aberrancies in the endonasal group was 1–3.1 mm, giving a mean of 1.55 mm, and the range in the open group was 0.9–2.9 mm, giving a mean of 1.67 mm. Preoperatively, there was no statistical difference

in the Gunter’s distances between the 2 groups. This suggested that there was an even distribution of aberrancies and elimination of bias (*P* = 0.311). A reduction in this distance was considered an improvement in the final outcome, and this was compared both qualitatively and quantitatively in both groups. Forty-nine of 50 patients from the endonasal approach group saw a reduction in this distance when compared with the open method, which saw a reduction in 12 of 15 patients (*P* = 0.036, <0.05). This suggested a better outcome among the endonasal group. The quantitative reduction in this distance when compared in patients between the 2 groups had a *P* value of <0.001, suggesting a greater overall reduction with the endonasal technique of rhinoplasty. The difference in the final postoperative Gunter’s distance was also statistically significant between the 2 groups (*P* = 0.031), favoring the endonasal technique. Figures 5 and 6 show correction of a class I aberrance with an 8-month postoperative images alongside. Figures 7 and 8 show a class IV aberration correction in another patient of ours.

Our study and analysis show a better columellar correction, and a higher reduction in the Gunter’s distance was achieved using the endonasal approach of rhinoplasty and our technique, over the standard open procedure being commonly used.

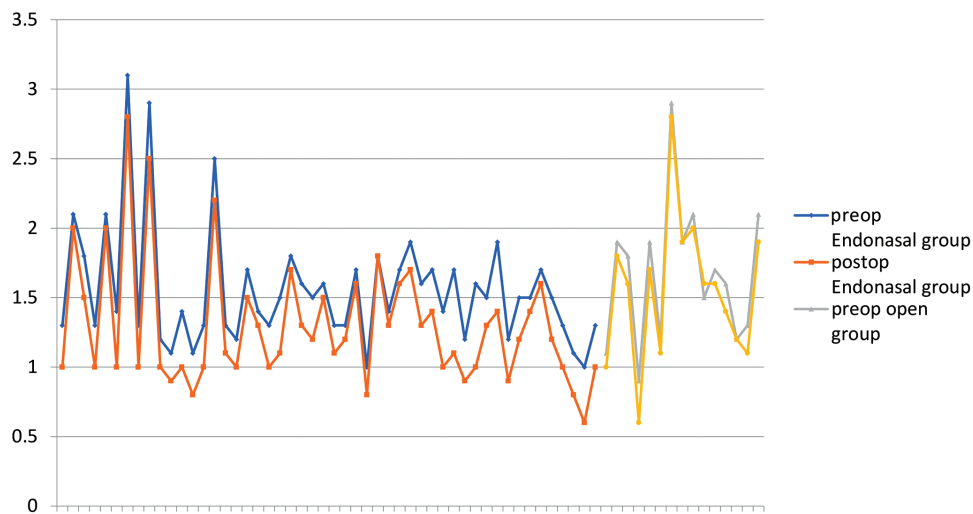
**Table 3. Rate of Successful Correction of the Columella after Surgery as per Classification by Rohrich and Liu<sup>4</sup>**

|                  | Corrected Columella after Surgery | Uncorrected Columella after Surgery | Total |
|------------------|-----------------------------------|-------------------------------------|-------|
| Endonasal method | 37                                | 5                                   | 41    |
| Open method      | 10                                | 5                                   | 15    |
| Total            | 46                                | 10                                  | 56    |

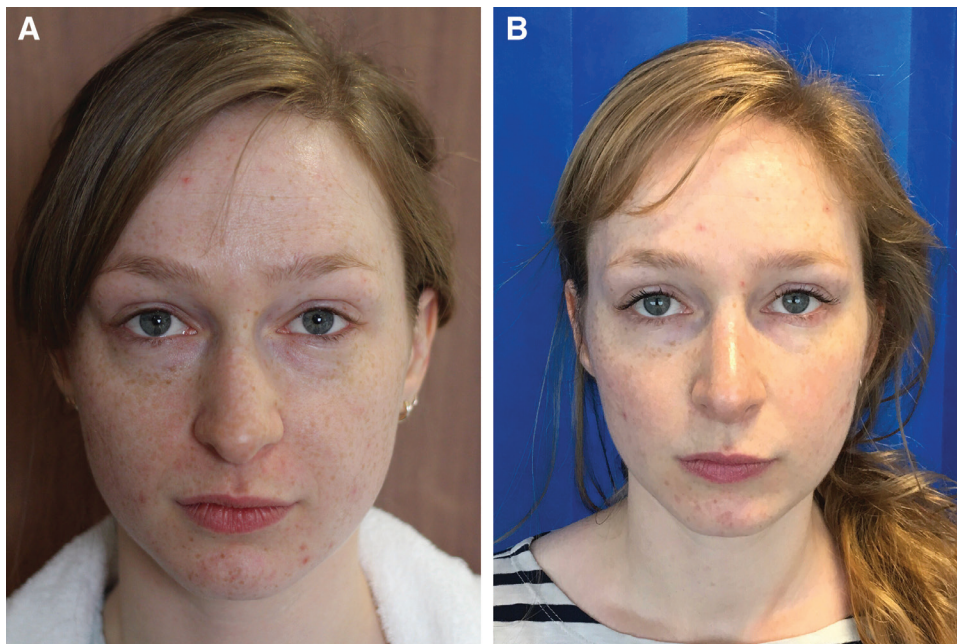
The data show that an improvement in the columella was achieved in 90% of the endonasal approach group and 50% of the open rhinoplasty group. The confounding variables are that surgery in the open group was performed at the earlier years of practice by the senior author and the endonasal approach was done by the same author after acquiring many years of experience. The endonasal approach group (37 of 41 patients) fared better with a *P* value of 0.048 (<0.05).

## DISCUSSION

A full assessment of the columella is an integral part of all rhinoplasty planning. Our study investigated the correction of the columella in absolute terms using a standardized classification. It also compared the efficacy of endonasal approach with the standard open technique. The debate of endonasal versus open rhinoplasty is an age old one with proponents of each technique preferring and promoting one over the other and recognizing at the same time the utility of both endonasal and



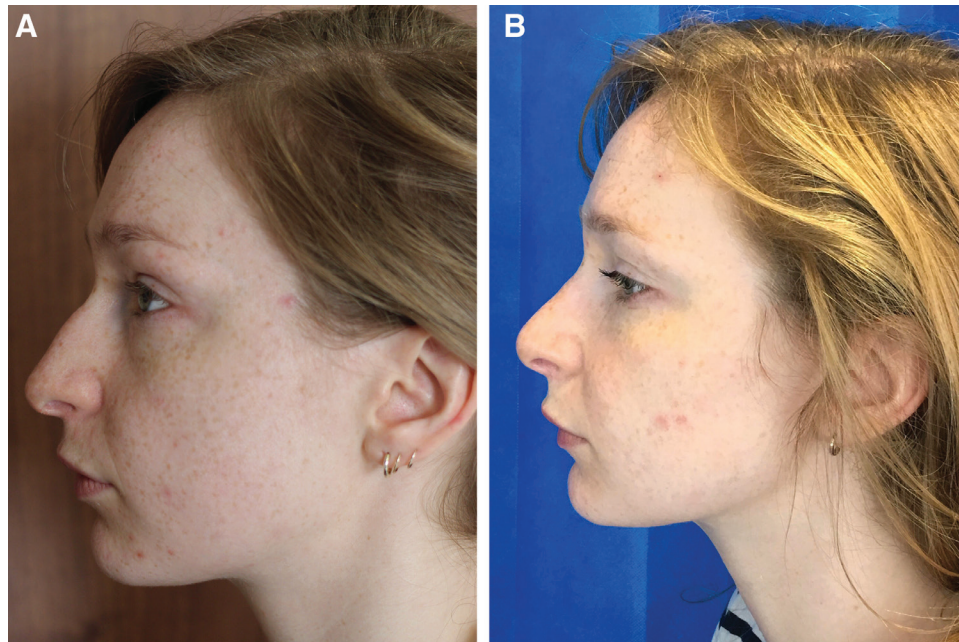
**Fig. 4.** Graph showing improvements in Gunter's distance in both the endonasal approach and the open rhinoplasty groups. This correlated well with the rates of patient satisfaction. Although the 4 dissatisfied patients had a significant improvement of their Gunter's distance, they were still unhappy. This may be related to significant postoperative swelling or scar tissue masking a good result. Alternatively, dissatisfaction was related to high patient requirements and inadequate preoperative counseling to manage expectations.



**Fig. 5.** Frontal view [preoperative (A) and postoperative (B)]. A 33-year-old woman presented for correction of a dorsal bump and narrowing of a broad tip (A). We noted a class I aberrance. She did not comment on her abnormal columella till this was assessed and explained to her. Photographic morphing software showed her the benefits of correcting the columella to enhance the final outcome. This was agreed before any surgery to ensure patient ownership of planning. The results 8 months after endonasal approach indicate appropriate correction of the issues and a satisfied patient (B).

external approaches.<sup>7</sup> It is generally accepted that there is however no ideal approach, and each surgeon develops an approach they are most comfortable with, based on their training, experience, and results.<sup>8</sup> To reference Tebbets, one must agree that any surgeon who is exclusively undertaking one or the other technique may not be giving patients the broad analysis that is required.<sup>9</sup>

The idea of a functional tripod was described in 1969 with the medial crus together forming 1 limb and the 2 lateral crus forming the remaining 2 limbs (Fig. 9). This has been the foundation of tip dynamics.<sup>10</sup> Tardy<sup>11</sup> has described 3 major and 6 minor tip supporting mechanisms, which has been developed over years of work by Anderson<sup>10</sup> and Janeke and Wright.<sup>12,13</sup> Gunter<sup>14</sup> described



**Fig. 6.** Lateral view of patient discussed in Figure 4. A, Preoperative view. B, Postoperative view.



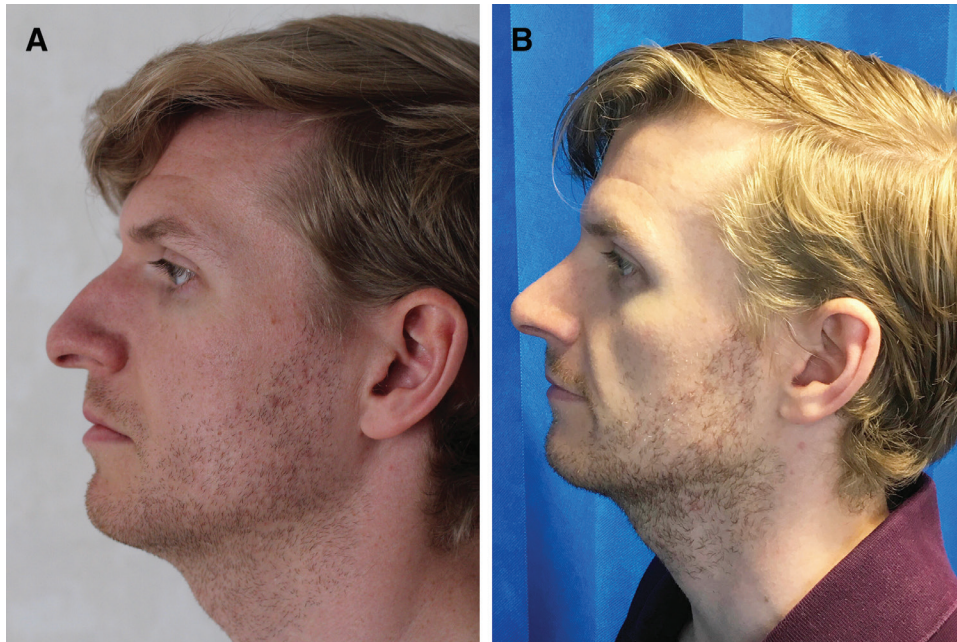**Fig. 7.** Frontal view [preoperative (A) and postoperative (B)]. A 28-year-old man presented for correction of a dorsal bump and narrowing of a broad tip (A). He had a class IV abnormality. He had thick skin at the tip, so an open approach was used. Correction required a tongue-in-groove technique. Detailed planning was demonstrated to him beforehand because patient satisfaction is closely related to the quality of the preoperative counseling. The results 9 months after endonasal approach indicate appropriate correction of the issues and a satisfied patient (B).

the dynamic changes in the tip projection by modification in the various limbs of the tripod, which forms the basis of the various maneuvers done during rhinoplasty.

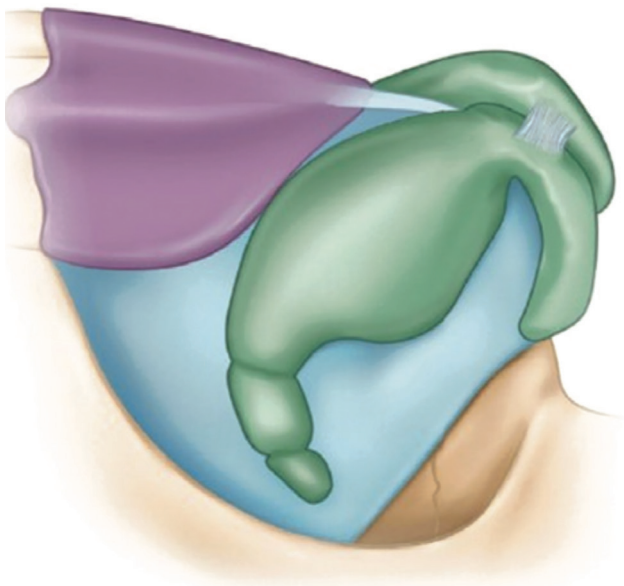
The columella is the convergence of not only cartilage and ligaments,<sup>15–17</sup> but also skin and muscle.<sup>13,14</sup> The importance of the columellar aesthetics in the final rhinoplasty outcome is increasingly being acknowledged. Surgeons

are increasingly recognizing the need to address the columella as an integral part of a rhinoplasty to achieve good results and happy patients.<sup>18–20</sup> It forms the most important support of the nasal tripod.<sup>14,18</sup>

As described by Sheen,<sup>19–21</sup> the columella and alae are a seagull in gentle flight, which is suggestive of the gentle arching of the nasal alae. It plays a key role in nasal



**Fig. 8.** Lateral view of patient discussed in Figure 6 [preoperative (A) and postoperative (B)].



**Fig. 9.** The Pitanguy ligament, interdomal ligament, and the support structures of the tip are shown.<sup>26</sup> This complex can be preserved with the endonasal approach to avoid the swelling and long-term sequelae of the open approach. However, the control of the tripod may in fact be preferable using the open approach.

support and positioning by means of its role in tip support and aesthetics, nasolabial angle, and columellar lobular angle.<sup>19</sup> Abundant or malpositioned medial crura, deviation of the caudal septum, or abnormality of the soft tissue in terms of excess or deficiency gives rise to columellar deformities.<sup>18,22</sup> The importance of its role in final nasal aesthetics thus cannot be ignored.

Various surgeons have described different treatment algorithms for alar–columellar deformities. Gunter et al<sup>5</sup>

classified the aberrancies into 6 types, where the issue primarily originated from an abnormality of the alar rims, as in type II and IV, or from the columella, as in types I, II, and VI. He defined the distance between the long nasal axis and the columella as a good measure to identify deformity of the columella and found that when this distance was  $<1$  mm, it suggested a retracted columella, and when this distance was  $>1$  mm, a hanging columella.<sup>5</sup> In our study, all but 1 patient had a preoperative Gunter's distance of  $\geq 1$  mm; this is defined as a hanging columella. One patient had a distance of 0.9 mm. We judged any reduction in this distance as an improvement because it created better aesthetics and balance according to the algorithm Gunter et al.<sup>5</sup>

Many authors have over the years described various algorithms to tackle the columella during rhinoplasty surgeries.<sup>5,19–21,23</sup> Gunter et al<sup>5</sup> suggested excision of the cartilage of the caudal septum in most instances of hanging columella. This recommendation stemmed from his classification of the columellar and alar deformities according to the distance from the long nasal axis. They also suggested an occasional need for excision of the caudal margin of the medial crura,<sup>5</sup> which was a refinement on a more aggressive route taken by Armstrong<sup>24</sup> who suggested complete excision of the medial crura. This is not practiced now because of the risk of subsequent collapse of the columella. For a retracted columella, the strategy used by Gunter et al<sup>5</sup> was to augment the columella using a columellar strut. They suggested that the ideal distance between a good columella and the long axis of the nose was between 1 and 2 mm.<sup>5</sup> As per the classification, most of our patients had a hanging columella, and in our study, they benefited from a cartilage strut for support. In our series, the strut is combined with a tongue-in-groove approach to improve the columella and also aid support.<sup>25</sup> Gunter et al<sup>5</sup> in contrast mostly used a strut for a retracted



columella. This demonstrates the constant evolution of the field of rhinoplasty in an effort to achieve better results, as patients become more demanding.

We found an elongation of the long axis of the nostril resulted in reduction of the distance from it to the columella. The nostrils developed a more aesthetically pleasing oval appearance, as opposed to the usual rounded one with a hanging columella. We found that there was reduction in columella to nasal axis distance in most of our patients (93.8%). When we compared open rhinoplasty with the endonasal technique, this improvement was statistically significant, suggesting a better improvement in the endonasal group. This may be related to the fact that in the endonasal approach, there is no division of Pitanguy ligament and consequently there is less scar tissue and edema, as opposed to the open approach, where scar tissue contracts around the site of the skin incision.<sup>26</sup>

Guyuron<sup>23</sup> resected the caudal septum without the need for any excision of the medial crura; we applied the same maneuver in our study. He used a cartilage strut for tip support and columellar advancement. Another maneuver suggested by him was to suture the footplates together to further project the columella. We also use this technique with good effect in some patients, although not performed in patients included in this study. As with Gunter et al,<sup>5</sup> the technique used by Guyuron<sup>23</sup> would be a direct technique for columella correction as suggested by Matarasso et al.<sup>20</sup> They divided this columellar correction into direct, indirect, and aggressive approaches. The direct approach being one where the correction in the columella is brought about by excision of tissue from the medial crura and an indirect approach would be the one where the caudal septal cartilage is excised.<sup>20</sup> Matarasso et al<sup>20</sup> excised the cranial portion of the medial caudal when compared with other groups who excised the caudal portion, which has earlier been described by Brown<sup>27</sup> and Gruber<sup>28</sup> in their patients. We used placement of a strut in the columella in our correction of the columellar deformity and found this approach to obtain good results without the need for a medial crura resection. The added strut, along with intact medial crura, gives good support to the nasal tip to improve the longevity of the rhinoplasty. Thus, the columella shape and columella-labial angle are maintained in the long term, reducing revision rates.

A detailed analysis of the columella and an algorithm to correct it was also proposed by Rohrich and Afrooz<sup>19</sup> and Rohrich et al,<sup>29</sup> who used an open technique as opposed to our predominantly endonasal technique. They suggested that 6 elements need to be addressed while correcting the columella. The first among these is the caudal septum, which needs to be exposed and incrementally reduced along with the membranous septum, which can sometimes need trimming when redundant.<sup>19</sup>

The other elements discussed by Rohrich and Afrooz<sup>19</sup> include columellar skin (which may need trimming of an extra edge), anterior nasal spine, depressor septi nasi (whose insertion needs to be released), and the medial crus (which can mostly be handled with a fixation stitch

or strut). They also judiciously use excision of the medial crura for refinement.<sup>19</sup> However, when it comes to excision of the lateral crus, Rohrich and Afrooz<sup>30</sup> advised caution, as this can lead to rolling of the alae or the long-term contraction of scar tissue, which may raise the alae more than intended. Where elongation of a retracted columella is required, most surgeons advocate the use of septal extension grafts, onlay grafts, or a columellar strut. They provide reliable stability for the tip.<sup>31</sup> Our study used a columellar strut with reliable outcomes, which can be applied using an endonasal or open approach with satisfactory results.<sup>30</sup> Beaty et al<sup>32</sup> also demonstrated reproducible results with reconstruction of the ligamentous attachment between the lateral crura and the conservative resection of lower lateral cartilages.

Additional measures that are relevant include release of the depressor septi nasi (which we found to be useful in our patients), reduction of any negative vectors on smiling, and the use of a fixation stitch to the columella for a long-term stability. This was accomplished satisfactorily through either the open or endonasal technique, as both allow direct vision.

## CONCLUSIONS

Correction of the columella needs several maneuvers during a rhinoplasty, which have become established. Surgeons may choose different approaches to the same problems according to their experience and preference. There is no standard way to correct the columella, but it is important to identify the potential deformity and the need to correct it. In our patients, we could address the columella correction satisfactorily using either an open or the endonasal approach.

*Rajan Uppal, FRCS(Ed), MSC, FRCS (Plast)*

Department of Plastic and Reconstructive Surgery  
Frimley Park NHS Trust  
Wexham Street  
Berkshire  
SL2 4HL  
London, United Kingdom  
E-mail: rajan@rajanuppal.com

## PATIENT CONSENT

*Patients provided written consent for the use of their images.*

## REFERENCES

- Weeks DM, Thomas JR. Beauty in a multicultural world. *Facial Plast Surg Clin North Am.* 2014;22:337–341.
- Ferreira MG, Santos M, Carmo DOE, et al. Rhinoplasty-do patients and surgeons see the same? A double-blind study with 100 randomized patients. *Facial Plast Surg.* 2018;34:356–362.
- Khansa I, Khansa L, Pearson GD. Patient satisfaction after rhinoplasty: a social media analysis. *Aesthet Surg J.* 2016;36:NP1–NP5.
- Rohrich RJ, Liu JH. Defining the infratip lobule in rhinoplasty: anatomy, pathogenesis of abnormalities, and correction using an algorithmic approach. *Plast Reconstr Surg.* 2012;130:1148–1158.
- Gunter JP, Rohrich RJ, Friedman RM. Classification and correction of alar-columellar discrepancies in rhinoplasty. *Plast Reconstr Surg.* 1996;97:643–648.

6. Chin KY, Uppal R. Improved access in endonasal rhinoplasty: the cross cartilaginous approach. *J Plast Reconstr Aesthet Surg*. 2014;67:781–788.
7. Cafferty A, Becker DG. Open and closed rhinoplasty. *Clin Plast Surg*. 2016;43:17–27.
8. Adamson PA. Nasal tip surgery in open rhinoplasty. *Facial Plast Surg Clin North Am*. 1993;1:39–52.
9. Tebbetts JB. Secondary tip modification: shaping and positioning the nasal tip using nondestructive techniques. In: Tebbetts JB, ed. *Primary Rhinoplasty: A New Approach to the Logic and the Techniques*. St. Louis, Mo.: Mosby; 1998:261–440.
10. Anderson JR. The dynamics of rhinoplasty. In: Proceedings of the Ninth International Congress of Otolaryngology. Amsterdam, The Netherlands: Excerpta Medica. International Congress; 1969:series 206.
11. Tardy ME. *Rhinoplasty: The Art and Science*. Philadelphia, Pa.: W.B. Saunders; 1997:4.
12. Janeke JB, Wright WK. Studies on the support of the nasal tip. *Arch Otolaryngol*. 1971;93:458–464.
13. Schinkel ML, Nayak LM. Nasal tip modifications. *Oral Maxillofac Surg Clin North Am*. 2012;24:67–74.
14. Gunter JP. Anatomical observations of the lower lateral cartilages. *Arch Otolaryngol*. 1969;89:599–601.
15. Rohrich RJ, Hoxworth RE, Thornton JF, et al. The pyriform ligament. *Plast Reconstr Surg*. 2008;121:277–281.
16. Pitanguy I. Surgical importance of a dermocarilaginous ligament in bulbous noses. *Plast Reconstr Surg*. 1965;36:247–253.
17. Pitanguy I, Salgado F, Radwanski HN, et al. The surgical importance of the dermocarilaginous ligament of the nose. *Plast Reconstr Surg*. 1995;95:790–794.
18. Lee MR, Malafa M, Roostaeian J, et al. Soft-tissue composition of the columella and potential relevance in rhinoplasty. *Plast Reconstr Surg*. 2014;134:621–625.
19. Rohrich RJ, Afroz PN. Components of the hanging columella: strategies for refinement. *Plast Reconstr Surg*. 2018;141:46e–54e.
20. Matarasso A, Greer SE, Longaker MT. The true hanging columella: simplified diagnosis and treatment using a modified direct approach. *Plast Reconstr Surg*. 2000;106:469–474.
21. Sheen JH. *Aesthetic Rhinoplasty*. St. Louis, Mo.: Mosby; 1978:210.
22. Guyuron B. Footplates of the medial crura. *Plast Reconstr Surg*. 1998;101:1359–1363.
23. Guyuron B. Dynamics of rhinoplasty. *Aesthetic Plast Surg*. 2002;26(suppl 1):S10.
24. Armstrong DP. Aggressive management of the hanging columella. *Plast Reconstr Surg*. 1980;65:513–516.
25. Kridel RW, Scott BA, Foda HM. The tongue-in-groove technique in septorhinoplasty. A 10-year experience. *Arch Facial Plast Surg*. 1999;1:246–256; discussion 257.
26. Daniel RK, Palhazi P. The nasal ligaments and tip support in rhinoplasty: an anatomical study. *Aesthet Surg J*. 2018;38:357–368.
27. Brown JB. Miscellaneous adjustments. In: Brown JB, McDowell F, eds. *Plastic Surgery of the Nose*. St. Louis, Mo.: Mosby; 1951:145–152.
28. Gruber RP. Treating the hanging columella: no single technique prevails. *Aesthetic Surg J*. 1999;19:81.
29. Rohrich RJ. Personal approaches and philosophies. In: Rohrich RJ, Adams WP, Ahmad J, et al, eds. *Dallas Rhinoplasty: Nasal Surgery by the Masters*. 3rd ed. St Louis, Mo.: Quality Medical Publishing; 2014:1417–1458.
30. Rohrich RJ, Afroz PN. Revisiting the alar-columellar relationship: classification and correction. *Plast Reconstr Surg*. 2019;144:340–346.
31. Dobratz EJ, Tran V, Hilger PA. Comparison of techniques used to support the nasal tip and their long-term effects on tip position. *Arch Facial Plast Surg*. 2010;12:172–179.
32. Beaty MM, Dyer WK II, Shawl MW. The quantification of surgical changes in nasal tip support. *Arch Facial Plast Surg*. 2002;4:82–91.