


Prostate Cancer Detected by Choroidal Tumor and Complete Response to Hormonal Therapy: Case Report and Literature Review of 24 Patients With Choroidal Metastasis From Prostate Cancer

Journal of Investigative Medicine High
Impact Case Reports
Volume 9: 1–8
© 2021 American Federation for
Medical Research
DOI: 10.1177/23247096211026471
journals.sagepub.com/home/hic


Toshihiko Matsuo, MD, PhD^{1,2}, Takehiro Tanaka, MD, PhD³,
Aya Nakamura, MD, PhD⁴, and Koichiro Wada, MD, PhD⁵

Abstract

Metastatic choroidal tumors derived from prostate cancer are rare. In this study, we report a patient who manifested a choroidal tumor as the initial presenting sign of prostate cancer and review 23 patients with choroidal metastasis of prostate cancer in the literature to answer a clinical question how the choroidal metastases would respond to hormonal therapy. A 73-year-old man presented with a choroidal tumor in the right eye. He was in good health and had no previous history except for current hemodialysis in 3 years due to chronic renal failure as a sequel to glomerulonephritis. With the diagnosis of a probable metastatic tumor, positron emission tomography was performed to disclose high-uptake sites in multiple bones, lymph nodes, and the prostate, together with multiple nodular lesions in bilateral lungs on computed tomography (CT) scan. Serum prostate-specific antigen (PSA) was elevated to 541 ng/mL, which supported prostate cancer as the primary site. He had degarelix injection, and the choroidal tumor resolved rapidly and became flat degeneration in a month. Prostate biopsy showed poorly differentiated adenocarcinoma, and he underwent surgical castration. He had no medication until 3 years later when he showed gradual increase of serum PSA up to 6.05 ng/mL and multiple bony metastases on CT scan. Bicalutamide, switched to enzalutamide and then to abiraterone, led to the undetectable level of serum PSA until the last visit with no relapse of the choroidal metastasis, 6.8 years after the initial visit. In the literature review of 24 patients with choroidal metastasis of prostate cancer, including this patient, 8 patients presented a choroidal tumor as the initial sign and the choroidal lesions mostly showed complete response to hormonal therapy. Among 13 patients who were frequently in the course of hormonal therapy, choroidal metastases showed complete or partial response to external beam radiation to the eye in 11 patients and episcleral plaque radiotherapy in 2 patients. In conclusion, metastatic choroidal tumors of prostate cancer would show good response to hormonal therapy when the therapy has not been initiated. Hormone-resistant choroidal metastases in the therapeutic course of prostate cancer could be managed successfully by external beam radiation to the eye.

Keywords

prostate cancer, choroidal/uveal tumor, choroidal/uveal metastasis, radiation, surgical castration, complete remission, hormonal therapy, literature review, prostate-specific antigen, PSA, positron emission tomography, PET

Background

Choroidal tumors are rare and have to be diagnosed differentially in the list of primary tumors and metastatic tumors. Malignant melanoma is a predominant primary tumor that arises in the choroid in all populations,¹ including the Japanese,² even though the incidence varies from population to population. Among metastatic choroidal tumors, lung cancer and breast cancer have been well known to present metastatic lesions in the choroid.^{3,4} Prostate cancer metastatic to the uvea or choroid is extremely rare and has been described

by the limited number of case reports since the earlier years of the twentieth century.⁵ Prostate cancer tends to metastasize to bones and lungs. Serum prostate-specific antigen (PSA) is a reliable clinical marker to monitor prostatic diseases including not only prostate cancer but also prostatic hyperplasia and inflammation. In the field of ophthalmology, prostate cancer also makes iris metastases,⁶ as part of the uvea, and orbital metastases.⁷

In this study, we report a patient who presented with a choroidal tumor as the initial sign. He was diagnosed as choroidal



metastasis of prostate cancer by systemic evaluation including positron emission tomography (PET) and serum PSA measurement. The choroidal tumor showed and maintained complete response to surgical castration and hormonal therapy. In the review of literature,⁸⁻³⁰ 23 patients with metastasis of prostate cancer in the choroid were retrieved to answer a clinical question to what extent choroidal metastasis of prostate cancer would show response to hormonal therapy.

Case Report

A 73-year-old man noticed that he could not chase a golf ball 2 months previously, and also became aware of narrow field of vision and metamorphopsia in the right eye. At the visit to an ophthalmologist, he was found to have a large nonpigmented dome-shaped choroidal mass in the superotemporal quadrant of the midperipheral fundus of the right eye, associated with serous subretinal fluid, which extended to the macular area and inferior to the choroidal mass (Figure 1A and B). The vitreous and anterior chamber in the right eye had no pigments or cells. The left eye had nothing particular. The best-corrected visual acuity in decimals was 0.4 in the right eye and 1.2 in the left eye. The intraocular pressure was 15 mm Hg in the right eye and 17 mm Hg in the left eye. He had been undergoing hemodialysis 3 times a week for 3 years due to chronic renal failure from glomerulonephritis. He had no systemic symptoms and was well with daily medications of amlodipine 10 mg, benidipine 4 mg, clopidogrel 75 mg, lansoprazole 15 mg, precipitated calcium carbonate 1000 mg, cinacalcet hydrochloride 25 mg, and pantethine 300 mg. He also took intravenous injection of maxacalcitol 5 μ g 3 times a week at the time of hemodialysis and subcutaneous injection of darbepoetin alfa 40 μ g once a week.

With the diagnosis of metastatic choroidal tumor, primary and other metastatic sites were searched for by whole-body 2-^[18F]fluoro-2-deoxy-D-glucose PET (FDG-PET). Abnormal uptake was found in the prostate (standardized uptake value [SUV_{max}] = 4.75; Figure 2C), vertebral bones (SUV_{max} = 8.01; Figure 2D), bilateral hilar and mediastinal lymph nodes (SUV_{max} = 5.77; Figure 2E), and bilateral lung fields, in addition to the right eye (SUV_{max} = 3.31; Figure 2B). The combined computed tomography (CT) scan showed multiple lung-field nodular

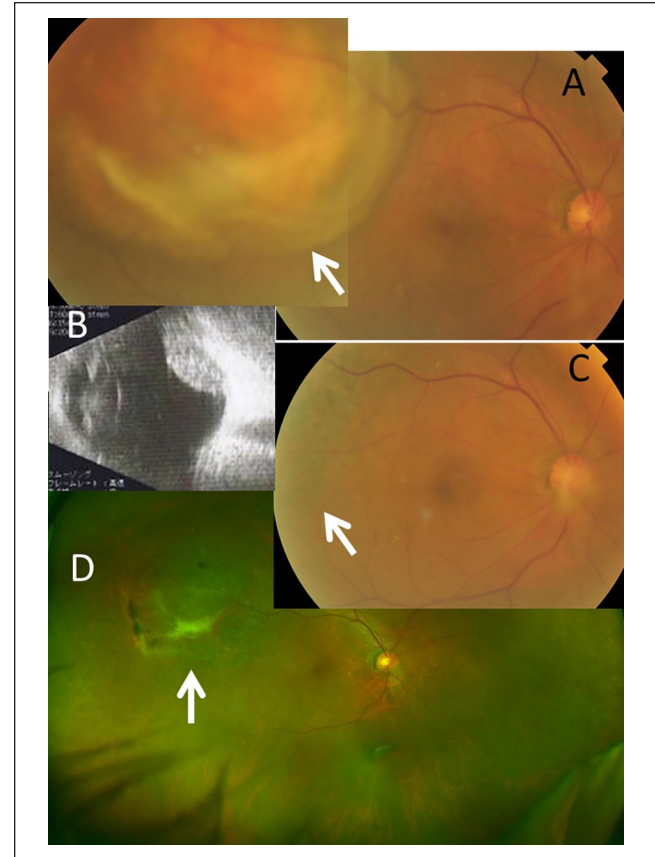


Figure 1. Fundus photograph (arrow in A) and ultrasonography (B) of a large choroidal tumor in the right eye of a 73-year-old man at the initial visit. The tumor has regressed rapidly to become flat retinal degeneration (arrow in C) in response to 1-month hormonal therapy with degarelix. No relapse (arrow in D) in the right eye 3 years after the initial visit.

lesions on both sides (Figure 2F), indicative of metastatic lesions in the lung. Head magnetic resonance imaging showed an intraocular mass with mildly high T1-weighted signal, mildly low T2-weighted signal, and high diffusion-weighted signal in the right eye (Figure 2A), but no intracranial abnormalities. He was referred to a urologist for prostate cancer as the primary site. Serum PSA was extremely elevated to 541 ng/mL, which supported prostate cancer as the primary site. He began to receive

¹Okayama University, Graduate School of Interdisciplinary Science and Engineering in Health Systems, Okayama City, Japan

²Ophthalmology, Okayama University Hospital, Okayama City, Japan

³Pathology, Okayama University Graduate School of Medicine, Dentistry, and Pharmaceutical Sciences, Okayama City, Japan

⁴Urology, Okayama Saiseikai General Hospital, Okayama City, Japan

⁵Urology, Okayama University Hospital, Okayama City, Japan

Received May 11, 2021. Revised May 21, 2021. Accepted June 1, 2021.

Corresponding Author:

Toshihiko Matsuo, MD, PhD, Regenerative and Reconstructive Medicine (Ophthalmology), Okayama University Graduate School of Interdisciplinary Science and Engineering in Health Systems, 2-5-1 Shikata-cho, Okayama City 700-8558, Japan.

Email: matsuo@cc.okayama-u.ac.jp

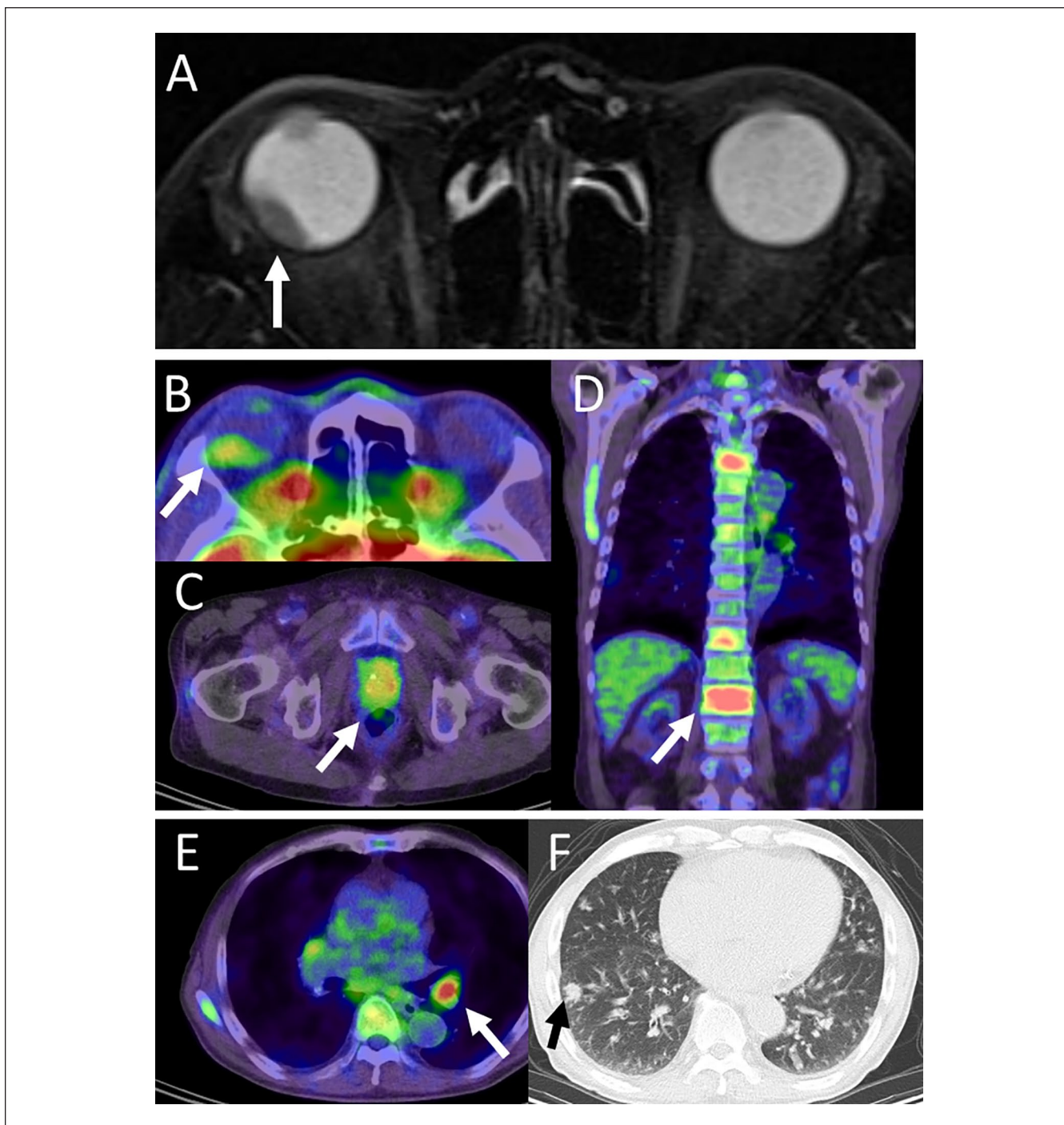


Figure 2. An intraocular mass (arrow in A) in the right eye with mildly low T2-weighted signal in magnetic resonance image in a 73-year-old man at the initial visit. Abnormal uptake in the right eye (arrow in B, standardized uptake value $SUV_{max} = 3.31$), prostate (arrow in C, $SUV_{max} = 4.75$), vertebral bones (arrow in D, $SUV_{max} = 8.01$), and mediastinal lymph node (arrow in E, $SUV_{max} = 5.77$) in whole-body 2- ^{18}F fluoro-2-deoxy-D-glucose positron emission tomography (FDG-PET) at the initial visit. Note multiple lung-field lesions (arrow in F) in computed tomography scan combined with PET.

subcutaneous injection of degarelix acetate at the initial dose of 240 mg, followed by 80 mg every 4 weeks. One month after the initial visit, the choroidal tumor resolved rapidly and became flat degeneration in response to the

initial dose of hormonal therapy (Figure 1C). Two months after the initial visit, needle biopsy of the prostate showed poorly differentiated adenocarcinoma with Gleason score of $4 + 4 = 8$ (Figure 3A and B), which was indeed a

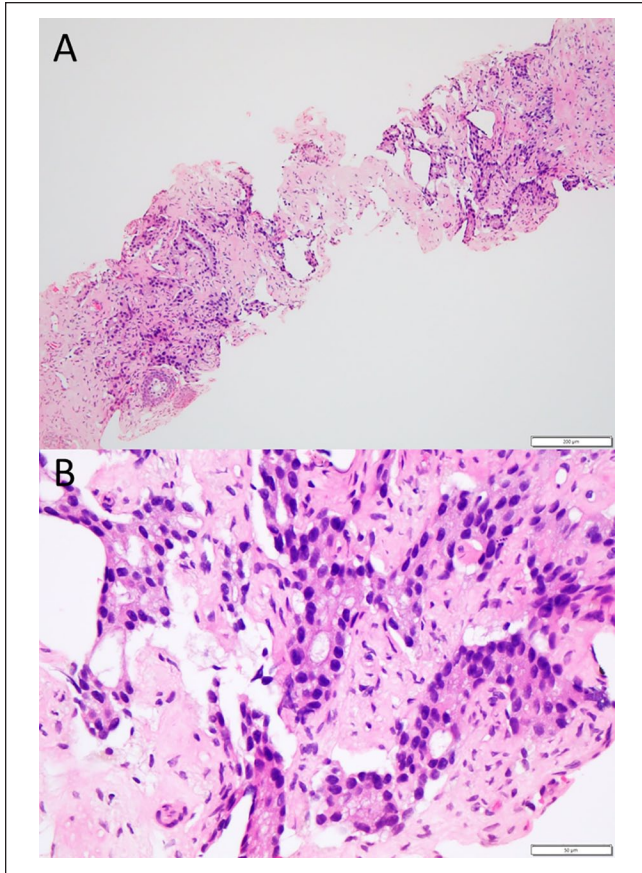


Figure 3. Needle biopsy specimen (A in low magnification and B in high magnification) of the prostate 2 months after the initial visit. Note irregular arrangement of fused glands. Gleason score, which was a presumed value since the patient was under hormonal therapy, was designated $4 + 4 = 8$, indicative of poorly differentiated adenocarcinoma. Bar = 200 μm in A and 50 μm in B.

presumed value as he was under hormonal therapy. He immediately underwent surgical castration, and degarelix was discontinued.

One year after the initial visit, the serum PSA in the patient with no medication remained at the low level of 0.48 ng/mL. The serum PSA was gradually elevated to 2.34 ng/mL 2 years after the initial visit, further elevated to 3.56 ng/mL 3 years after the initial visit, and to 6.05 ng/mL in the following 3 months. CT scan demonstrated multiple bony osteosclerotic metastases in thoracic and lumbar vertebrae but no metastasis in the liver or lymph nodes. At this time point, therefore, he began to take oral bicalutamide 8 mg daily, and in 1 month, the serum PSA decreased to 0.61 ng/mL. The serum PSA was elevated again to 1.22 ng/mL 5 years after the initial visit, and thus, bicalutamide was replaced with enzalutamide at a full dose, 160 mg daily, leading to the decrease of serum PSA to 0.38 ng/mL in 2 weeks. In a month, however, because of hypertension, the administration of enzalutamide was reduced to

half a dose 80 mg daily, and in another month, was replaced with abiraterone acetate at half a dose, 500 mg daily in combination with prednisolone 10 mg daily. The serum PSA became an undetectable level (<0.009 ng/mL) in 2 weeks. The patient was well with hemodialysis and maintained the undetectable PSA level with continuous abiraterone until the latest follow-up 6.8 years after the initial visit. Throughout the course, the right eye showed flat retinal regeneration corresponding to the area of the previous choroidal tumor (Figure 1D). The best-corrected visual acuity was 1.0 in both eyes.

Methods

To analyze historical cases from the literature, the Japanese literature was searched for the key words “prostate cancer (in Japanese)” and “choroidal/uveal metastasis (in Japanese)” in the bibliographic database of medical literature in Japanese (Igak Chu Zasshi, Japana Centra Revuo Medicina, Ichushi-Web), published by the Japan Medical Abstracts Society (JAMAS, Tokyo, Japan). Old literatures were further collected from references cited in the articles identified during the literature search. PubMed was also searched for the key words “prostate cancer” and “choroidal/uveal metastasis.” The sufficient description was found in 23 patients who showed choroidal metastasis from prostate cancer (Table 1).⁸⁻³⁰

Results

In review of the literature, 24 patients with choroidal metastasis of prostate cancer, including the present patient, were all men with the age at the presentation of choroidal tumors ranging from 49 to 77 years (median = 68 years). Choroidal metastasis was found in both eyes of 4 patients, in the right eye of 9 patients, and in the left eye of 11 patients. Prostate cancer had been diagnosed in the range from 1 month to 13 years (median = 3.5 years) before the detection of the choroidal metastasis in 14 patients, while the choroidal tumor, as the first presenting sign, led to the diagnosis of prostate cancer as the primary malignancy by systemic evaluation in 8 patients. In the remaining 2 patients (Case 2 and Case 6), systemic evaluation could not detect the primary site and the eyes with choroidal tumor were extirpated, and the pathological examination led to the diagnosis of prostate cancer 4 months and 1 year later, respectively.

Prostate cancer was diagnosed pathologically by prostatectomy or prostate biopsy in all patients except for 2 patients (Case 2 and Case 6) who were diagnosed as metastatic prostate cancer by pathological examinations of the extirpated eyes. Serum PSA at the presentation of choroidal metastasis was elevated in all 19 patients who had the description of measurements, except for one (Case 22). Multiple bone metastases were noted in 20 patients, lung nodular metastases in 7, liver

Table 1. Review of 24 Patients With Choroidal Metastasis of Prostate Cancer Including the Present Patient^{a,b}.

| Case no./eye/age at onset | Location of choroidal metastasis | Timing of choroidal metastasis relative to diagnosis of prostate cancer | Systemic symptoms at initial visit | Serum PSA at the time of eye symptoms (ng/mL) | Other metastases | Prostate cancer diagnosis Prostate therapy | Eye therapy Local response | Outcome | Author |
|---------------------------|---|---|--|---|--|--|---|---|-----------------------------------|
| 1/right/56 | A mass in inferotemporal area and macula | 11 months later | Urinary symptoms Back pain Weight loss | Not described | Multiple bones | Prostate biopsy Prostate radiation Radon seeds implant | Enucleation | Dead in 1 month | Kulvin ⁸ |
| 2/left/61 | Optic nerve and surrounding choroid | 4 months earlier | Lower back pain Weight loss, nausea | Not described | Skin metastasis in left shoulder | Prostate biopsy Surgical castration | Prostate cancer diagnosed by enucleation | Not described | Zappia et al ⁹ |
| 3/left/54 | A large mass in temporal area and macula | Concurrent | Sacral pain Urinary frequency | Not described | Bilateral lung nodules Multiple bones | Prostatectomy Surgical castration Bones radiation Diethylstilbestrol | None Complete response to hormonal therapy | Alive in 1 year | Dieckert and Berger ¹⁰ |
| 4/left/69 | A large scleral and choroidal mass in inferonasal area | 4 years later | Not described | 74 | Multiple bones | Prostate biopsy Surgical castration Flutamide | Scleral nodule excisional biopsy Eye Radiation Partial response | Not described | Liu et al ¹¹ |
| 5/bilateral/65 | A mass in RE A large mass in superotemporal area and macula (LE) | 4 years later | Not described | 91.4 | Sacropelvic metastasis | Intravenous strontium Prostatectomy with lymph node dissection Flutamide Leuprolide | None Complete response to hormonal therapy | Alive in 1 year | Keizur et al ¹² |
| 6/right/74 | A large mass in inferotemporal area | 1 year earlier | None | 640 | Lung nodules Multiple bones | Prostate biopsy Nilutamide Leuprolide | Prostate cancer diagnosed by enucleation | Alive in 8 months Response to hormonal therapy | Hill et al ¹³ |
| 7/right/61 | A large mass in posterior pole | 3 years later | Not described | Not described | Multiple bones Liver and lung nodules | Prostate biopsy Surgical castration Bones radiation | Eye radiation (40 Gy) Partial response | Dead in 4 months | Wiegel et al ¹⁴ |
| 8/right/49 | Two masses | Concurrent | None | 124 | Multiple mediastinal lymph nodes Multiple bones | Prostate biopsy Flutamide LH-RH agonist | Eye radiation (35 Gy) Complete response | Dead in 32 months | Obek et al ¹⁵ |
| 9/right/52 | A large mass in superior area and macula | Concurrent | Low back pain Nocturia Right calf pain | 104 | Multiple mediastinal lymph nodes Multiple bones Multiple bones | Prostate biopsy Total androgen blockade Bone and pelvic radiation | Eye radiation (30 Gy) Partial response | Not described | Connell et al ¹⁶ |
| 10/left/72 | A large mass in superonasal area | Concurrent | None | 6.42 | Multiple bones | Prostate biopsy Prostatectomy Chemotherapy (hormonal therapy) | Episcleral plaque brachytherapy Partial response | Not described | Frota et al ¹⁷ |
| 11/left/74 | A large mass in temporal area and macula | Concurrent | Left mild hemiparesis | 483 | Right parietal nodule Multiple bones | Prostate biopsy Bicalutamide LH-RH agonist | None Complete response to hormonal therapy | Alive in 14 months | Barbon et al ¹⁸ |
| 12/bilateral/54 | A mass in superonasal area (RE) A mass in posterior pole (LE) | Concurrent | None | Elevated (not specified) | Lung nodules Multiple bones | Prostate biopsy Bicalutamide Triptorelin | None Partial response to hormonal therapy | Not described | Primavera et al ¹⁹ |
| 13/left/68 | A large mass in posterior pole | Concurrent | None | 5.6 | Multiple bones | Prostate biopsy Antandrogen treatment | L-125 plaque radiotherapy Complete response | Alive in 1 year | Kancherla et al ²⁰ |
| 14/left/68 | A large mass in inferonasal area | 14 months later | Not described | 304 | Left: orbital and middle cranial fossa masses Multiple bones | Prostate biopsy Estramustine, Fosfestrol Leuprolerin, Docetaxel | Eye, orbital, and cranial radiation (39 Gy) Partial response | Alive in 13 months | Ueki et al ²¹ |

(continued)

Table 1. (continued)

| Case no./eye/age at onset | Location of choroidal metastasis | Timing of choroidal metastasis relative to diagnosis of prostate cancer | Systemic symptoms at initial visit | Serum PSA at the time of eye symptoms (ng/mL) | Other metastases | Prostate cancer diagnosis | Eye therapy | Outcome | Author |
|---------------------------|--|---|---|---|---|---|---|--|--------------------------------|
| 15/right/57 | A flat mass in superotemporal area | 1 month later | Bilateral lower limb weakness Voiding difficulty | 399 | Lung nodules Multiple bones Mediastinal and abdominal lymph nodes | Prostate biopsy Bicalutamide Leuprorelin | Eye radiation (40 Gy) Complete response | Alive in 6 months | Iwasaki et al ²² |
| 16/right/60 | A large mass in superonasal area and macula | 5 years later | Not described | 3.5 | Lung nodules Multiple bones | Prostatectomy with lymph node dissection Androgen deprivation Pelvic radiation Docetaxel | Eye radiation (30 Gy) Complete response | Alive in 2.5 years | Ermoian et al ²³ |
| 17/left/70 | A large mass in choroid and iris | 8 years later | Not described | 25.22 | None | Prostate biopsy Prostate radiation Flutamide, leuprolide | Eye radiation No response and Enucleation | Alive in 1 year No systemic metastasis on PET | Walavalkar et al ²⁴ |
| 18/left/71 | A large mass in superotemporal area and macula | 7 years later | Not described | 5.6 | Lung nodules Mediastinal lymph nodes | Prostatectomy Ketoconazole Leuprolide | None Partial response to hormonal therapy | Alive in 5 years | Ameri et al ²⁵ |
| 19/left/62 | A large mass in nasal area | 6 months later | Urinary symptoms Bone pain | 270 | Multiple bones | Prostate biopsy Bicalutamide, triptorelin Surgical castration | Eye radiation (30 Gy) Complete response | Alive in 14 months | Albadainah et al ²⁶ |
| 20/bilateral/77 | A mass in posterior pole (RE) A mass in posterior pole (LE) | 13 years later | Not described | 895 | Multiple bones | Prostatectomy with lymph node dissection Pelvic radiation Hormonal therapy Docetaxel, cabazitaxel Abiraterone | None | Dead in 3 months | Kourie et al ²⁷ |
| 21/bilateral/77 | An iris mass (RE) A large mass in inferior area (LE) | 2 months later | Not described | Not described | Multiple bones | Prostate biopsy Surgical castration | None (both eyes radiation planned but not done) | Lost follow-up | Saadi et al ²⁸ |
| 22/right/76 | Multiple lesions in posterior pole | 4 years later | Not described | 0.16 | None | Prostatectomy Pelvic radiation Androgen deprivation | Chorioretinal biopsy by vitrectomy Eye radiation (40 Gy) Partial response | Alive in 6 months | Cheung et al ²⁹ |
| 23/left/75 | A large mass in superotemporal area | 2 years later | Lumbago | 199.8 | Multiple bones Multiple lymph nodes | Prostate biopsy Bicalutamide, degarelix Estramustine Docetaxel, Enzalutamide | Eye radiation (30 Gy) Complete response | Liver, spleen, and brain metastasis Whole brain radiation (35 Gy) | Yoneyama et al ³⁰ |
| 24/right/73 | A large mass in superotemporal area | Concurrent | None | 541 | Multiple bones Multiple lung nodules | Prostate biopsy Surgical castration Degarelix, Bicalutamide Enzalutamide Abiraterone | None Complete response to hormonal therapy | Dead in 9 months Alive in 6.8 years | This study |

Abbreviations: PSA, prostate-specific antigen; RE, right eye; LE, left eye; LH-RH, luteinizing hormone-releasing hormone; PET, positron emission tomography.

^aDegarelix is Gn-RH (gonadotropin-releasing hormone) antagonist; leuprorelin, leuprolide, and triptorelin are Gn-RH agonists.

^bSurgical castration indicates bilateral orchiectomy (orchidectomy) and radiation indicates external beam radiation.

metastases in 2 (Case 7 and Case 23), and brain metastasis in 2 (Case 11 and Case 23). The outcome was not mentioned in 5 patients, and death was described in 5 patients in the follow-up period ranging from 1 month to 32 months (median = 4 months), while 13 patients were described alive in the follow-up period ranging from 6 months to 6.8 years (Case 24, the present case) with the median = 1 year. The remaining 1 patient (Case 21) was lost to the follow-up at the stage of planning external beam radiation to both eyes and hormonal therapy.

As for the local treatment for choroidal metastasis, 3 patients underwent enucleation, 11 patients underwent external beam radiation to the eyeballs, and 2 patients had episcleral plaque radiotherapy. No local treatment was done in the remaining 8 patients including 1 patient who was lost at the planning stage (Case 21). As for the systemic treatment, surgical castration (bilateral orchiectomy) was done in 7 patients: castration only in 3 patients and castration combined with hormonal therapy in 4 patients. Overall, hormonal therapy was done in 19 patients.

Regarding the therapeutic response of choroidal metastases, complete response to the eye radiation was described in 5 patients, response which was designated as partial response in Table 1 to the eye radiation was described in 5 patients, no response to the eye radiation in the remaining 1 patient (Case 17) who finally underwent the enucleation. Episcleral plaque radiotherapy in 2 patients (Case 10 and Case 13) showed partial response and complete response, respectively. In the 7 patients with no local treatment who were under hormonal therapy, 4 patients showed complete response, 2 patients partial response, and 1 patient (Case 20) no response from the standpoint of choroidal tumor regression.

Discussion

The present patient is unique at the points that choroidal metastasis, together with multiple bone and lung nodular metastases at the initial presentation, showed rapid complete response to hormonal therapy, which was followed by surgical castration, and that he maintained the remission in the long-term period up to 6.8 years. He had been healthy and active in daily life even with hemodialysis. Surgical castration was chosen because poorly differentiated adenocarcinoma was detected by prostate biopsy even after the initiation of degarelix. In the course of the follow-up at the Urology Clinic, antiandrogen drugs have been switched from one to another, based on their effect and adverse event. Monthly serum PSA has been measured as a marker to monitor the relapse of prostate cancer and maintained at undetectable levels until the final visit when the patient is alive in healthy condition in the preparation of this article. Ophthalmologically, he was followed-up every 3 months to check the visual acuity and fundus status in both eyes.

In the literature review, it should be noted that metastatic choroidal lesions were the first presenting signs of prostate cancer in one third of the cases (8 of 24 patients). These 8

patients had multiple bone metastases at the initial presentation and mostly showed good response to standard hormonal therapy with regard to choroidal and bone metastases. In patients who were detected to have choroidal metastases in the course of hormonal treatment toward prostate cancer, which had been diagnosed earlier, external beam radiation to the eyeballs was often chosen and the choroidal metastases mostly showed the complete response.

With regard to the clinical question in this study, the choroidal metastasis of prostate cancer could show good response to hormonal therapy, especially at the initial presentation when the hormonal therapy has not yet been instituted. When choroidal metastasis was detected in the course of hormonal treatment for prostate cancer, switching of antiandrogen drugs or surgical castration, if has not yet been done, would be a therapeutic strategy for the choroidal metastasis. External beam radiation to the whole eye is a local therapy, which would be chosen as a last resort when hormonal therapy would not have an effect on the choroidal metastasis.

In conclusion, prostate cancer should be considered in the differential diagnosis of a choroidal tumor. The measurement of serum PSA, as a reliable clinical marker for prostatic diseases, would be included in blood examinations at the initial presentation. Choroidal metastatic lesions of prostate cancer would have a high chance of showing complete response to hormonal therapy, and thus would be considered as curable from the ophthalmological point of view. In the case of limited response to hormonal therapy, external beam radiation to the eyeball remains as a therapeutic option in choroidal metastases of prostate cancer.

Authors' Note

Data are available on reasonable request to the corresponding author.

Author Contributions

TM, as an ophthalmologist, followed the patient; TT, as a pathologist, made the pathological diagnosis; AN and KW, as urologists, treated and followed the patient. TM wrote the manuscript, and TT, AN, and KW did critical review of the manuscript, and all authors approved the final version of the manuscript.

Declaration of Conflicting Interests

The author(s) declared no potential conflicts of interest with respect to the research, authorship, and/or publication of this article.

Funding

The author(s) received no financial support for the research, authorship, and/or publication of this article.


Ethics Approval

Ethics committee review was not applicable to case reports, based on the Ethical Guidelines for Medical and Health Research Involving Human Subjects, issued by the Government of Japan.

Informed Consent

Verbal informed consent was obtained from the patient for his anonymized information to be published in this article.

ORCID iD

Toshihiko Matsuo  <https://orcid.org/0000-0001-6570-0030>

References

- Singh A, Turell ME, Topham AK. Uveal melanoma: trends in incidence, treatment, and survival. *Ophthalmology*. 2011;118:1881-1885.
- Matsuo T, Ogino Y, Ichimura K, Tanaka T, Kaji M. Clinicopathological correlation for the role of fluorodeoxyglucose positron emission tomography computed tomography in detection of choroidal malignant melanoma. *Int J Clin Oncol*. 2014;19:230-239.
- Shields CL, Shields JA, Gross NE, Schwartz GP, Lally SE. Survey of 520 eyes with uveal metastases. *Ophthalmology*. 1997;104:1265-1276.
- Shields CL, Acaba-Berrolca LA, Selzer EB, et al. Uveal metastasis based on patient age in 1,111 patients: comparison of clinical features and outcomes per age category. *Retina*. 2020;40:204-213.
- De Potter P, Shields CL, Shields JA, Tardio DJ. Uveal metastasis from prostate carcinoma. *Cancer*. 1993;71:2791-2796.
- Martin V, Cuenca X, Lopez S, et al. Iris metastasis from prostate carcinoma: a case report and review of the literature. *Cancer Radiother*. 2015;19:331-333.
- Boldt HC, Nerad JA. Orbital metastases from prostate carcinoma. *Arch Ophthalmol*. 1988;106:1403-1408.
- Kulvin MM. Metastatic carcinoma of choroid with primary focus in the prostate gland. *Am J Ophthalmol*. 1940;23:892-899.
- Zappia RJ, Smith ME, Gay AJ. Prostatic carcinoma metastatic to optic nerve and choroid: association with changes resembling papilledema. *Arch Ophthalmol*. 1972;87:642-645.
- Dieckert JP, Berger BB. Prostatic carcinoma metastatic to choroid. *Br J Ophthalmol*. 1982;66:234-239.
- Liu S, Christmas TJ, Kirby RS. Combined scleroidal and choroidal metastasis from prostatic carcinoma. *Br J Urol*. 1992;70:689-690.
- Keizur JJ, Kane CJ, North R, Leidich RB. Adenocarcinoma of the prostate metastatic to the choroid of the eye. *Prostate*. 1995;27:336-339.
- Hill VE, Brownstein S, Leonard BC, Jordan DR. Prostate adenocarcinoma presenting as a solitary choroidal metastasis. *Can J Ophthalmol*. 1998;33:276-279.
- Wiegel T, Kreusel KM, Heicapell R, Foerster MH, Hinkelbein W. Metastatic adenocarcinoma of the prostate to the choroid with loss of visual acuity as a presenting symptom. *J Urol*. 1998;160(6 pt 1):2158-2159.
- Obek C, Kural AR, Yaycioglu O, Kendiroglu G, Solok V. Metastatic adenocarcinoma of the prostate to the uvea as the initial presenting symptom in a 49-year-old man. *Urology*. 2001;58:106.
- Connell PP, Fennessy K, Elfiki T, Bogue C, O'Reilly S, Fenton S. Decreased vision as the initial presenting symptom of disseminated prostatic disease. *Eye (Lond)*. 2006;20:1116-1118.
- de Arantes Frota AC, Bakalian S, Gregoire FJ, Fernandes BF, Burnier MN Jr. Pseudomelanoma in a patient with prostate adenocarcinoma. *Can J Ophthalmol*. 2007;42:305-306.
- Barbon JJ, Gonzalez-Tuero J, Gay LL, Pérez-García FJ, Sampedro A. Regression of a choroidal metastasis from prostate adenocarcinoma after hormonal therapy [in Spanish]. *Arch Soc Esp Ophthalmol*. 2007;82:715-717.
- Primavera V, Querques G, Guigui B, et al. Choroidal metastasis from clinically regressed prostate adenocarcinoma: imaging of a rare case [in French]. *J Fr Ophtalmol*. 2008;31:877-882.
- Kancherla S, Bianciotto CG, Shields CL. Prostate carcinoma, a common cancer in men, rarely metastasizes to the eye. *Retina Today*. Published January/February 2011. Accessed June 8, 2021. https://retinatoday.com/pdfs/0111RT_Oncology.pdf
- Ueki S, Takagi M, Murakami K, et al. A case of orbital and choroidal metastases from prostate cancer [in Japanese]. *Shinkei Ganka*. 2011;28:320-325.
- Iwasaki M, Hayashi N, Ueno D, et al. A case of prostate adenocarcinoma with a choroidal metastasis [in Japanese]. *Hinyoki Geka*. 2011;24:1537-1540.
- Ermoian R, Kalina R, Yu EY, Parvathaneni U. Ocular prostate cancer metastasis treated with external beam radiation. *Retin Cases Brief Rep*. 2011;5:306-308.
- Walavalkar V, Said B, Dacosta-Iyer M, Ouyang Y. Prostatic adenocarcinoma with solitary metastasis to the uvea. *Pathology*. 2012;44:476-479.
- Ameri H, Araujo JC, Gombos DS. Leuprolide monotherapy for choroidal metastasis from prostate adenocarcinoma. *Arch Ophthalmol*. 2012;130:1225-1226.
- Albadainah F, Khader J, Salah S, Salem A. Choroidal metastasis secondary to prostatic adenocarcinoma: case report and review of literature. *Hematol Oncol Stem Cell Ther*. 2015;8:34-37.
- Kourie HR, Antoun J, Bteich F, Jalkh A, Ghosn M. Bilateral choroidal metastases from prostate cancer revealed in a patient under abiraterone: fourteen years after diagnosis. *Gulf J Oncolog*. 2016;1:67-69.
- Saadi A, Kerkeni W, Bouzouita A, et al. Bilateral orbital metastasis of prostatic adenocarcinoma. *Urology*. 2016;94:e3-e4.
- Cheung AY, Yonekawa Y, Balaraman S, et al. Multimodal imaging and histologic correlation of isolated metastasis of prostate adenocarcinoma to the choroid. *Retin Cases Brief Rep*. 2017;11:166-170.
- Yoneyama S, Watanabe T, Onuki T, Yabuki K, Suzuki K. A case of choroidal and brain metastases from castration-resistant prostate cancer [in Japanese]. *Hinyokika Kyo*. 2018;64:181-186.