



Imaging pediatric acute appendicitis during the coronavirus disease 2019 (COVID-19) pandemic: collateral damage is variable

Kelly K. Horst¹ · Amy B. Kolbe¹ · Jennifer S. McDonald¹ · Adam T. Froemming¹ · Ahmad Parvinian¹ · Denise B. Klinkner² · Larry A. Binkovitz¹

Received: 15 February 2021 / Revised: 17 May 2021 / Accepted: 10 June 2021 / Published online: 17 August 2021
© The Author(s), under exclusive licence to Springer-Verlag GmbH Germany, part of Springer Nature 2021

Abstract

Background Since coronavirus disease 2019 (COVID-19) was declared a worldwide pandemic in March 2020, many authors have noted the collateral damage on non-COVID-19-related illnesses. These indirect effects of the pandemic have resulted in people presenting later and with more severe stages of disease, even if their diagnoses are not directly related to SARS-CoV-2, the virus that causes COVID-19.

Objective We studied these indirect effects of COVID-19 on the imaging workup and outcomes for pediatric patients at our center who had acute appendicitis during the pandemic.

Materials and methods We performed a retrospective review of cases in children ≤ 18 years who were evaluated for acute appendicitis during the same period, March 1 to May 31, in both 2019 and 2020. We compared demographic and clinical data as well as surgical and pathological findings, and we graded imaging findings according to severity. Differences in patient outcomes were assessed using the Wilcoxon rank sum test and the Pearson chi-square test.

Results The total number of pediatric patients evaluated with imaging for acute appendicitis dropped by 43% between 2019 and 2020 (298 vs. 169), but the total number of children treated remained similar (59 vs. 51). There was proportionate use of US and CT in each timeframe but a higher percentage of positive imaging findings in 2020 (50/169, 29.6% vs. 56/298, 18.7% in 2019, $P=0.04$). There were more imaging examinations with features of complicated appendicitis among positive cases (9/51, 18% vs. 5/59, 8% in 2019, $P=0.08$) and more pathologically proven perforated cases during the pandemic (14/51, 27% vs. 6/59, 10% in 2019, $P=0.11$), although these results did not reach statistical significance. There were no changes in surgical management, vital signs, laboratory values, length of stay or complication rates.

Conclusion There was a large drop in the number of pediatric patients imaged for acute appendicitis during the acute phase of the COVID-19 pandemic despite similar numbers of patients treated. The utilization trends of US vs. CT remained stable between time periods. The differences in imaging findings and perforation rates were less pronounced compared to other published studies.

Keywords Appendicitis · Children · Computed tomography · Coronavirus disease 2019 · Pediatric radiology · Perforation · Ultrasound

Introduction

Studies have shown a reduced number and delayed presentation of people with life-threatening conditions during the

coronavirus disease 2019 (COVID-19) pandemic. The delays in seeking care for conditions such as myocardial infarction, stroke and malignancy have resulted in higher morbidity and mortality from these conditions [1–6]. These negative indirect effects of the virus have been referred to as the “collateral damage” of the pandemic. To study the indirect effects of COVID-19 on children, a few authors have focused on the most common cause of emergent surgery in the pediatric population, acute appendicitis. The results have been somewhat inconsistent. Some studies have shown no change in the incidence of pediatric appendicitis during this timeframe [7–10], but other studies have shown a reduction in pediatric cases compared to adults [11]. Many authors have also documented increased

✉ Kelly K. Horst
Horst.Kelly@mayo.edu

¹ Department of Radiology, Mayo Clinic,
200 1st St. SW, Rochester, MN 55905, USA

² Department of Pediatric Surgery,
Mayo Clinic, Rochester, MN, USA

rates of perforated appendicitis during the pandemic [7, 8, 10, 12–14], including two studies from New York City that correlated this finding with delayed presentation [7, 8]. However, this trend was also inconsistent, with a few large retrospective studies showing no change in perforation rates among pediatric patients during the pandemic time period [9, 11, 15].

Imaging trends in acute appendicitis have not been as thoroughly studied. A few authors have reported decreased numbers of emergent CTs ordered out of the emergency department (ED) during the pandemic but with a higher proportion of positive findings and more advanced stages of disease [16–18]. A study by Romero et al. [19] is the only one in the radiology literature to focus on imaging trends in acute appendicitis during the COVID-19 pandemic. Romero et al. documented an increased reliance on CT imaging to diagnose acute appendicitis, with an increased incidence of more severe CT findings among these cases [19]. Among pediatric patients, the two studies from New York City documented an increased percentage of imaging examinations suspicious for perforation during the pandemic [7, 8], but they did not discuss US vs. CT ordering trends and variably reported findings among different imaging modalities. In our study, we sought to assess the degree of collateral damage from COVID-19 at our center to gain insight into radiology utilization and health care deferral in our location compared to other published studies during the pandemic. We sought to do so specifically from the pediatric radiologist's perspective.

Materials and methods

Study population

This retrospective observational cohort study complied with the Health Insurance Portability and Accountability Act and was approved by our institutional review board. Only subjects whose guardians had consented to inclusion in research were included in this study. We searched the electronic medical record for pediatric patients ≤ 18 years old who were worked up for acute appendicitis at our main campus and site of the Mayo Eugenio Litta Children's Hospital, and surrounding health system locations between March 1 and May 31, 2020, and during the same time period in 2019. These dates were chosen based on the timeline along which the pandemic and its reponse evolved in the region.

We searched the International Classification of Diseases, 10th revision (ICD-10) code for "acute appendicitis" (K35.x) to capture any cases managed either operatively or nonoperatively. We also searched the term "appendicitis" in the imaging reports from this time period and compared those reports to notes in the medical record to include children worked up with imaging who did not undergo appendectomy.

Institutional acute appendicitis protocols

Our standard protocol for diagnosing and treating acute appendicitis was maintained throughout the pandemic. Pediatric cases clinically suspicious for appendicitis are typically evaluated with imaging. There is a preference for US as the first-line modality, with recommendations put forth by the American College of Radiology (ACR) appropriateness criteria for the workup of appendicitis. In cases where the clinical diagnosis remains in question, CT is often used for further evaluation. Nonoperative therapy (antibiotics only) versus surgery might be recommended for children with symptoms < 24 h and no fecalith. Positive complicated and uncomplicated cases diagnosed within 7 days of symptoms undergo urgent operative treatment with laparoscopic appendectomy. Antibiotic treatment and percutaneous drainage are administered if an abscess is found at imaging, followed by delayed appendectomy.

Prospective imaging review and grading

All US and CT imaging examinations in children who underwent appendectomy or had positive imaging findings at presentation ($n=59$ in 2019, $n=51$ in 2020) were categorically graded according to severity by two fellowship-trained pediatric radiologists (K.K.H. and A.B.K., each with 8 years of experience). US and CT examinations were graded on the following scale: 0 = appendix not seen, 1 = normal appendix, 2 = equivocal for appendicitis, 3 = acute appendicitis, 4 = complicated appendicitis suspicious for rupture. CT grading grouped "0 = appendix not seen" into the "1 = normal appendix" category. Disparate results were reconciled by a third fellowship-trained pediatric radiologist (L.A.B., with 26 years of experience). The appendix was considered "normal" if the diameter was 6 mm or less and without periappendiceal inflammation. The imaging findings were graded as "acute appendicitis" if the diameter was greater than 6 mm and demonstrated periappendiceal inflammation. The 6-mm diameter was not a strict cut-off but was considered in the context of periappendiceal inflammation and used as a guide. The imaging findings were considered "complicated" in the presence of phlegmon or abscess, discontinuity of the appendiceal wall, or diffuse peritonitis with dilated bowel loops. If the appendix was not seen on CT but there was an otherwise normal appearance of the right lower quadrant, this was graded as a normal appendix.

Clinical data retrieval

We also analyzed and compared the duration of symptoms, vital signs, laboratory values, surgical findings, surgical pathology, length of hospital stay, and postoperative complications. Vital signs and laboratory results were obtained on the

day of presentation. COVID-19 test results performed on the day of presentation were also retrieved in 2020. The symptom duration was recorded to the nearest day. If children presented the same day as symptoms began, this was recorded as 0.5 days. If symptoms began the day before presentation, it was recorded as symptoms for 1 day, etc.

Statistical analysis

All statistical analyses were performed using JMP (version 14; SAS Institute, Cary, NC). Continuous results are presented as median and interquartile range (IQR). Categorical results are presented as number and percentage. Differences in patient demographics, vital signs, laboratory results and outcomes between the 2019 and 2020 timeframes were assessed using the Wilcoxon rank sum test for continuous variables and the Pearson chi-square test for categorical variables. Significance was assigned to differences of $P < 0.05$.

Results

Patient characteristics

There were no differences in patient vital signs or laboratory values between the pre-pandemic and pandemic time periods within the appendicitis-positive cohort (Table 1). There were no differences in patient age or gender between years. There was a statistically significant prolongation of symptom duration in 2020 among positive cases: 1 day (0.5–1 days) in 2019 vs. 1 day (0.5–2 days) in 2020 ($P = 0.03$).

Imaging ordering trends

The imaging results are summarized in Table 2. A total of 169 patients were imaged for suspicion of acute appendicitis during the study period in 2020 at the main campus and surrounding health system sites. This represents a 43% decrease when compared to the same time period in 2019, $n = 298$. This was mirrored by the overall 44% decrease in the ED pediatric patient volumes at these sites during this time period, which went from 15,514 in 2019 to 8,703 in 2020. Despite the decreased numbers of children imaged for acute appendicitis in 2020, imaging ordering trends remained stable with respect to the total proportion of patients ($P = 0.30$): US only, 183/298 (61.4%) in 2019 vs. 93/169 (55%) in 2020; CT only, 98/298 (33%) in 2019 vs. 61/169 (36%) in 2020; and US and CT, 16/298 (5.3%) in 2019 vs. 15/169 (9%) in 2020 (Table 3).

Imaging findings of disease severity

During the pandemic, a greater percentage of the children worked up for acute appendicitis with imaging were positive: 56/298 (18.7%, 51 positive and 5 complicated) in 2019 vs. 50/169 (29.6%, 41 positive and 9 complicated) in 2020, ($P = 0.04$) (Table 2). In absolute terms, more imaging exams in 2020 had features of complicated appendicitis compared to 2019. The increased frequency of complicated imaging findings in 2020 was not statistically significant among positive cases: 5/59 (8.5%) in 2019 vs. 9/51 (18%) in 2020, ($P = 0.08$), but it was statistically significant when taken in the context of the total cohort of children worked up for acute appendicitis with imaging: 5/298 (1.7%) in 2019 vs. 9/169 (5.3%) in 2020, ($P = 0.04$) (Table 2). There were more severe findings on US in 2020

Table 1 Cohort demographics, vitals and laboratory results, positive cases

Cohort variables	2019 timeframe	2020 timeframe	<i>P</i> -value ^a
Patients (<i>n</i>)	59	51	
Age in years, median (IQR)	12 (9–15)	12 (10–14)	0.79
Female (%)	26 (44%)	22 (43%)	0.92
Presentation, median (IQR)			
Highest temperature (°C)	37 (37–37)	37 (37–37)	0.79
Highest heart rate	99 (87–115)	103 (94–115)	0.34
Leukocytes	15 (12–19)	14 (11–16)	0.08
Neutrophils	13 (10–16)	11 (8–14)	0.08
Platelets	285 (258–326)	269 (227–314)	0.21
Erythrocyte sedimentation rate	23 (3.7–84)	14 (2.9–25)	0.41
Length of symptoms for pathologically confirmed positive cases, days (IQR)	1 (0.5–1)	1 (0.5–2)	0.03
Length of symptoms for pathologically complicated cases, days (IQR)	5 (3–7)	2 (1–4)	0.17

C Celsius, IQR interquartile range

^a Statistically significant results are $P < 0.05$ (bold)

Table 2 Acute appendicitis workup

Cohort variables	Positive cases			Total cases		
	2019 timeframe	2020 timeframe	<i>P</i> -value ^a	2019 timeframe	2020 timeframe	<i>P</i> -value ^a
Patients (<i>n</i>)	59	51		298	169	
Total ED patient census ≤18 yrs				15,514	8,703	
Imaging findings at presentation			0.08			0.04
Negative				151 (50.7%)	83 (49.1%)	
Positive	51 (86.4%)	41 (80.4%)		51 (17.1%)	41 (24.3%)	
Complicated	5 (8.5%)	9 (17.6%)		5 (1.7%)	9 (5.3%)	
Equivocal	0	1 (2.0%)		3 (1.0%)	2 (1.2%)	
Appendix not seen	2 (3.4%)	0		87 (29.2%)	34 (20.1%)	
Imaging not performed	1 (1.7%)	0		1 (0.3%)	0	
Taken to surgery			0.98			0.044
No	1 (1.7%)	1 (2.0%)		240 (80.5%)	119 (70.4%)	
Yes, at presentation	56 (94.9%) ^b	48 (94.1%)		56 (18.8%) ^b	48 (28.4%)	
Yes, delayed	2 (3.4%)	2 (3.9%)		2 (0.7%)	2 (1.2%)	
Surgery findings			0.10			0.006
No surgery performed/outside surgery	3 (5.1%) ^b	1 (2.0%)		242 (81.2%) ^b	119 (70.4%)	
Normal	2 (3.4%)	1 (2.0%)		2 (0.7%)	1 (0.6%)	
Positive	49 (83.0%)	35 (68.6%)		49 (16.4%)	35 (20.7%)	
Complicated	5 (8.5%)	13 (25.5%)		5 (1.7%)	13 (7.8%)	
Equivocal	0	1 (2.0%)		0	1 (0.6%)	
Pathology findings			0.11			0.005
No surgery performed/outside surgery	3 (5.1%) ^b	1 (2.0%)		242 (81.2%) ^b	119 (70.4%)	
Normal	3 (5.1%)	2 (3.9%)		3 (1.0%)	2 (1.2%)	
Positive	47 (79.7%)	34 (66.7%)		47 (15.8%)	34 (20.1%)	
Complicated	6 (10.2%)	14 (27.5%)		6 (2.0%)	14 (8.3%)	

ED emergency department, yrs years

^a Statistically significant results are $P < 0.05$ (bold)

^b Includes two cases where the child was immediately transferred to another center for surgery

Table 3 Rates of imaging work-up by modality

Imaging variables	2019 timeframe	2020 timeframe	<i>P</i> -value ^a
Modality performed, all cases (<i>n</i>)	298	169	0.30
US only	183 (61.4%)	93 (55.0%)	
CT only	98 (32.9%)	61 (36.1%)	
US and CT	16 (5.4%)	15 (8.9%)	
Imaging not performed	1 (0.3%)	0	
Modality performed, negative cases (<i>n</i>)	239	118	0.34
US only	161 (67.4%)	71 (60.2%)	
CT only	67 (28.0%)	42 (35.6%)	
US and CT	11 (4.6%)	5 (4.2%)	
Modality performed, positive cases (<i>n</i>)	59	51	0.17
US only	22 (37.3%)	22 (43.1%)	
CT only	31 (52.5%)	19 (37.3%)	
US and CT	5 (8.5%)	10 (19.6%)	
Imaging not performed	1 (1.7%)	0	

^a Statistically significant results are $P < 0.05$

compared to 2019 ($P=0.39$) (Fig. 1), but these changes did not reach statistical significance. There were no differences in graded CT findings between the years ($P=0.40$) (Fig. 2).

Only 17/124 graded imaging examinations were disparate between the initial reviewers and differed by only 1 point. These discrepancies were reconciled by a third reviewer. Only two US exams were graded as complicated (score 4) that the other reviewer graded as positive (score 3). One was scored complicated (score 4) and one was scored positive (score 3) by the third reviewer. Six CT exams were graded as complicated (score 4) that the other reviewer graded as positive (score 3). Three were scored complicated (score 4) and three were scored positive (score 3) by the third reviewer.

Surgical and pathological outcomes

There was a similar number of children treated for appendicitis in each year (59 in 2019 vs. 51 in 2020) (Table 2). There was no difference in acute appendicitis management during

the pandemic. One child with positive imaging findings was managed nonoperatively with antibiotics in each time period (Table 2). Of the 58 children who underwent appendectomy in 2019 (at presentation and delayed surgery), 55 were positive for acute appendicitis on imaging at initial presentation, 2 were operated on based on clinical assessment alone because the appendix was not seen on US, and 1 patient underwent appendectomy without imaging. Two of the 58 patients were transferred to an outside hospital for surgery and no surgical or pathological report was available. Only 3 cases in 2019 demonstrated normal pathology despite positive imaging findings at presentation. One of these negative cases was also called “mildly positive” at surgery.

Of the 50 children taken to the OR in 2020 (at presentation and delayed surgery), 49 were positive for acute appendicitis on imaging at initial presentation and 1 child underwent appendectomy with equivocal imaging findings.

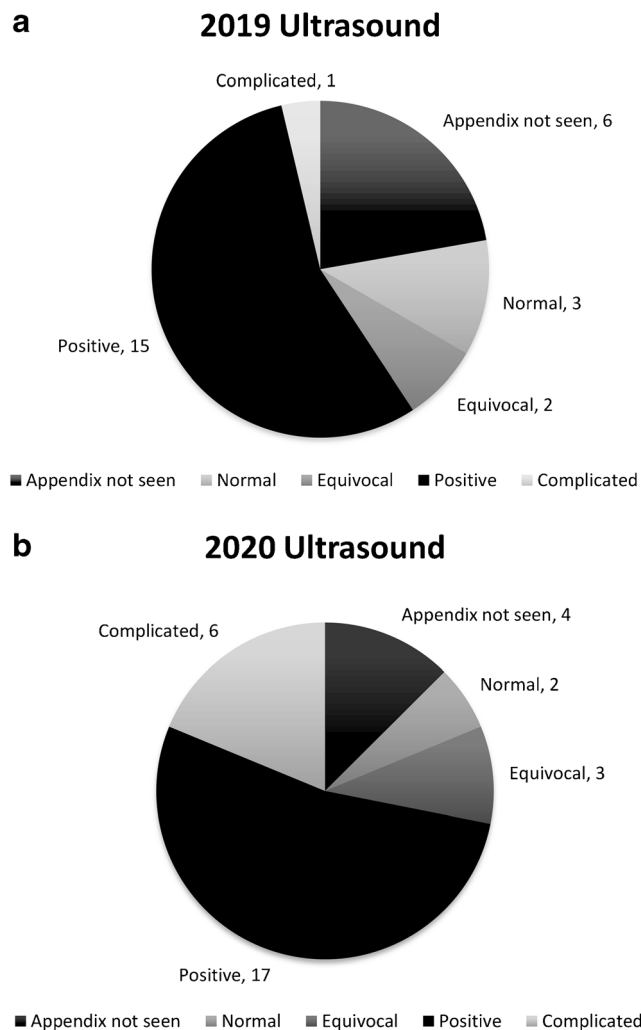


Fig. 1 Pie charts show prospective grading of US from 2019 (a) and 2020 (b). Counts are shown outside the circles

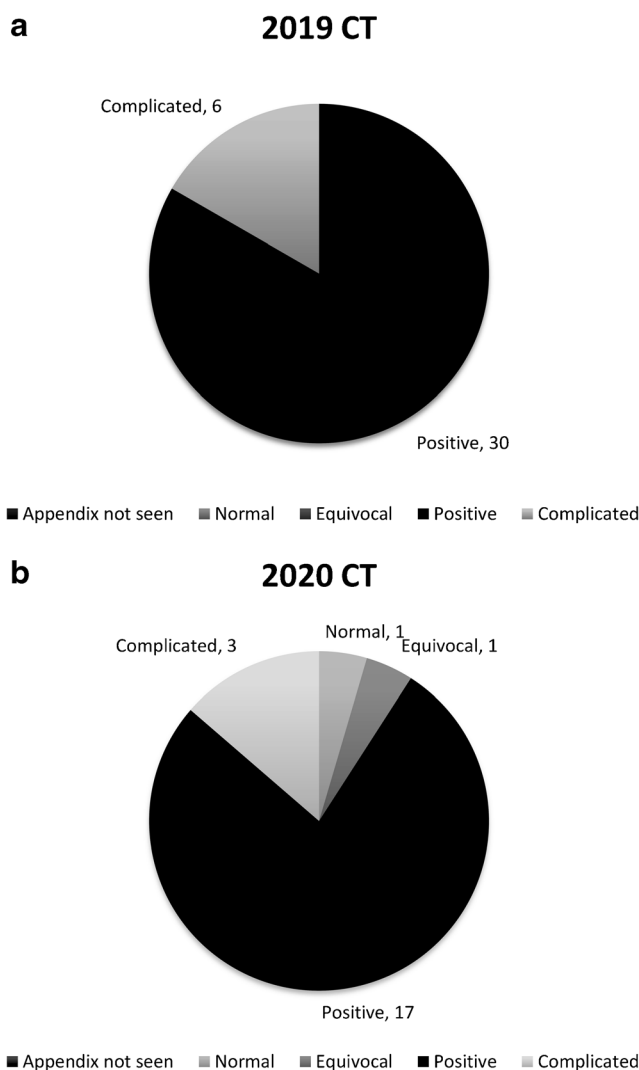


Fig. 2 Pie charts show prospective grading of CT from 2019 (a) and 2020 (b). Counts are shown outside the circles. The category “appendix not seen” was incorporated into “negative” for CT image scoring

The increased percentage of pathologically proven perforation in 2020 was not statistically significant among positive cases: 6/59 (10%) in 2019 vs. 14/51 (27%) in 2020, ($P=0.11$), but it was statistically significant when taken in the context of the total cohort of children worked up for acute appendicitis with imaging: 6/298 (2.0%) in 2019 vs. 14/169 (8.4%) in 2020 ($P=0.005$; Table 2).

Patient complications

Two patients in each year underwent percutaneous drainage of abscesses and antibiotic treatment with interval appendectomy (Table 4). There were more total abscesses in 2019 than 2020, but this difference was not statistically significant ($P=0.23$). There were two postoperative abscesses in 2020 and none in 2019 ($P=0.12$). One child had a prolonged hospital stay for postoperative ileus in each year. The overall length of hospital stay did not change between the pre-pandemic and pandemic years among positive cases ($P=0.25$).

Prevalence of coronavirus disease 2019 (COVID-19) in the study population

Only one child in the appendicitis-positive cohort tested positive for COVID-19 at presentation. This child was one of two in the 2020 imaging-positive cohort who had negative pathological findings for appendicitis. Thirty-three of the total 169 children in 2020 were tested for COVID-19. Twelve children tested positive for COVID-19, but 11 of these children were in the appendicitis-negative cohort.

Exclusions

One child with positive imaging findings in 2019 was excluded from the cohort because of pathology of “follicular hyperplasia.” Two children with positive imaging findings in 2020 were excluded from the study because of appendix pathology containing “non-caseating granulomas” attributed to Crohn appendicitis.

Discussion

Our study demonstrated that children evaluated for acute appendicitis during the early phase of the COVID-19 pandemic presented later and had a higher incidence of positive imaging findings. Children treated for acute appendicitis during this time period also trended toward having more complicated imaging findings and higher perforation rates at presentation than a similar group of children seen during the control period 1 year earlier, although these results were only statistically significant when taken the context of the total cohort. We hypothesize that parents chose to delay seeking medical attention for their children in 2020 for fear of contracting COVID-19 or fear of overwhelming the health care system. In addition, the delayed time to presentation might have allowed for resolution of lower abdominal symptoms in many children who would have presented during a pre-pandemic time period.

Among the limitations of this study is its retrospective design. Additionally, we chose to exclude children whose clinical presentation did not warrant US or CT evaluation. Presumably, the suspicion for acute appendicitis for these cases would have been low and, if positive, most probably would have been captured at re-presentation within our health system.

Although our cases trended toward a higher rate of complicated appendicitis during the pandemic, the numbers themselves were not statistically significant in the context of positive cases. Our study demonstrated over twice the rate of pathologically proven perforation in 2020, (27% vs. 10%, $P=0.11$). This compares to Snapiri et al. [12] (22% vs. 11%, $P=0.06$), Gerall et al. [7] (19.4% vs. 10%, $P=0.332$), Fisher et al. [8] (45% vs. 27%, odds ratio 2.23) and Lee-Archer et al. [10] (60.5% vs. 30.4%, $P=0.006$), who also demonstrated a doubling of the perforation rate at pathology. It is worth pointing out that the numbers from the study by Gerall et al. [7] included the rate of complicated appendicitis on pathology, but approximately 25% of their patients were managed nonoperatively at initial presentation. Of these patients, 2/3 required drain placement and antibiotics, implying that at least an additional 17% of the total cohort was perforated, bringing

Table 4 Complications, positive cases

Complications	2019 timeframe	2020 timeframe	<i>P</i> -value ^a
Total patients (<i>n</i>)	59	51	
Abscess drained in OR (not amendable to percutaneous drainage)	4 (6.8%)	1 (2.0%)	0.23
Delayed appendectomy after percutaneous drainage	2 (3.4%)	2 (3.9%)	0.88
Postoperative abscess	0	2 (3.9%)	0.12
Postoperative ileus	1 (1.7%)	1 (2.0%)	0.92
Length of stay, days (IQR)	1 (1–2)	1 (0.5–1)	0.25

IQR interquartile range, OR operating room

^a Statistically significant results are $P<0.05$

the total percentage of perforated appendicitis up to 36%, more than 3.5 times the perforation rate of the year before when the pandemic was at its peak in New York City. Unlike the aforementioned pediatric studies, our increase in perforated cases was not statistically significant when only positive cases were compared, although our case numbers of acute appendicitis were similar over similar time periods [7, 8, 10]. These comparisons suggest that our location did not suffer the same degree of collateral damage from the pandemic. We note that the study by Lee-Archer et al. [10] defined “complicated cases” more broadly as “free pus, gangrene or perforation at histopathology,” which increased the percentages in both non-pandemic and pandemic time periods.

Our study also showed less increase in symptom duration prior to presentation during the pandemic period for positive cases: 1 day (IQR 0.5–2 days) in 2020 vs. 1 day (IQR 0.5–1 days) in 2019 compared to 2 days (2–4 days) vs. 1 day (1–2 days) in Gerall et al. [7] and 71 h (\pm 39 h) vs. 47 h (\pm 27 h) in Fisher et al. [8]. Our delays were similar to those published by Kvasnovsky et al.’s [9], 22.5 h (16.1–29.5 h) in 2020 vs. 11.1 h (6.9–17.4 h) in 2019; Kvasnovsky et al. also noted no statistical significance in the rate of complicated acute appendicitis. Comparing these studies emphasizes that even subtle time differences in symptom duration can significantly affect perforation rates. A linear relationship has been shown between perforation rates and symptom duration in pediatric appendicitis, with substantial risks in perforation within 24 h and 48 h [20]. The increased duration of symptoms in 2020 supports the hypothesis that fear of seeking treatment during the early phase of the pandemic resulted in delayed presentation.

The increased severity of pathology in our study was mirrored by more severe imaging findings, but to a much lesser degree compared to other published studies. Gerall et al. [7] noted complicated imaging findings in more than 40% of pediatric cases. Romero et al. [19] also noted complicated features in more than 40% of CTs performed on all people with acute appendicitis. This compares to only 18% in our study. Because the numbers of appendicitis cases and timeframes were similar between these studies and ours, this again emphasizes that our population did not suffer the same degree of collateral damage from the pandemic as children in other geographic locations.

Thirty-three of 169 pediatric patients worked up for acute appendicitis within our hospital system in 2020 were tested for COVID-19. COVID-19 can present with abdominal symptoms [21, 22]. There are case reports in the literature of COVID-19 symptoms specifically mimicking acute appendicitis [23, 24]. Eleven of the 12 children in our study who tested positive for COVID-19 and were worked up for acute appendicitis had negative imaging. It is interesting to note that the only child in the positive appendicitis cohort who tested positive for COVID-19 was a false-positive for acute appendicitis. In this child, US showed a borderline-dilated appendix diameter of

7 mm and multiple fecaliths, and focal tenderness over the appendix was noted by the technologist during scanning. There were no peri-appendiceal inflammatory changes. This examination was called “positive for appendicitis” at presentation and was graded as “equivocal” by both reviewers. The child had a fever of 39.5 °C and tachycardia. There were negative surgical and pathological findings. It is reasonable to question whether the COVID-19-related symptoms in this child influenced the decision to perform appendectomy despite the somewhat equivocal imaging findings. Nevertheless, none of our patients with positive COVID-19 tests who were worked up for acute appendicitis with negative imaging findings underwent appendectomy, suggesting that although COVID-19 can mimic symptoms of appendicitis, negative imaging effectively excluded this diagnosis in our patient population.

Imaging ordering trends in our study were similar to those in others that reported overall decreased imaging utilization mirroring decreased patient census [16, 18]. However, we did not find any increase in the utilization of CT to diagnose acute appendicitis during the pandemic, as was reported by Romero et al. [19], whose study included adult and pediatric patients. Romero et al. also reported significantly more severe findings on CT in 2020. Only our US findings trended more severely in 2020, although these differences were not statistically significant. We suspect that this conclusion is limited by sample size and the relatively small number of perforated appendicitis cases diagnosed by US. There were no differences in the rates of complicated features seen on CT. This is probably partly from selection bias. US is typically performed prior to CT in the workup for pediatric patients and CT is often used as a trouble-shooting tool when US is inconclusive. A higher percentage of positive cases in the cohort means that a higher percentage of positive and complicated cases would be diagnosed on US as the first-line modality.

Our overall utilization of US as a first-line modality to diagnose acute appendicitis in pediatric patients (199/298 [66.7%] in 2019 vs. 108/169 [64%] in 2020) was similar to other pediatric hospitals, but our CT use as a first-line modality was somewhat higher (98/298 [33%] in 2019 vs. 61/169 [36%] in 2020) [25]. This study included both our main campus, the Mayo Clinic Children’s Center and Mayo Eugenio Liitta Children’s Hospital, as well as surrounding health system sites. The higher CT percentages are skewed by its utilization at health system sites. A similar proportion of children presented to our main campus compared to the health system sites between the time periods. Our cohort also includes patients through 18 years old, who are less likely to undergo US than younger children. During the pandemic, Fisher et al. [8] demonstrated an even distribution between US and CT use among positive pediatric acute appendicitis cases (44% each), with a small percentage of MR utilization.

Some of the most interesting observations and questions that arose from this study relate to imaging utilization in the

workup of acute appendicitis. The ordering patterns of our physicians between US only, CT only, and US and CT were consistent across cohorts. If nearly half the children who presented in 2019 and were imaged stayed home with mild symptoms in 2020 that resolved without workup, how can we use this knowledge to learn how not to over-image this group if they return to our hospital system in the future? Are there characteristics of the negative cohort in 2019 that can be studied to draw conclusions about which children might not require imaging in their workup for appendicitis moving forward? This is an intriguing question for follow-up research.

Conclusion

A markedly decreased number of pediatric patients were worked up with imaging for acute appendicitis during the acute phase of the pandemic at our main campus pediatric center and surrounding health system sites, but similar numbers of cases were diagnosed and treated. Imaging modality ordering trends and management strategies remained consistent. A higher percentage of imaging examinations was positive during the pandemic. We observed a trend toward more severe imaging features and higher rates of perforation on pathology. Our results are limited by sample size. The fact that these trends did not reach statistical significance within the positive cohort, in contrast to other studies in the literature with similar case numbers over similar time frames, indicates that children in our location did not suffer the same degree of collateral damage as those in other regions studied. The wider application of these results is that the collateral damage of the pandemic is perhaps very location-specific, a significant conclusion to keep in mind, particularly for the leadership of our medical societies and governments who are typically charged with implementing policies to help manage these public health risks. The higher rate of perforation in 2020 was probably related to a delay in presentation and longer symptom duration, and our data corroborate evidence that even small delays in presentation within the first 48 h of symptom onset contribute to perforation rates among pediatric patients.

Declarations

Conflicts of interest None

References

- Lange SJ, Ritchey MD, Goodman AB et al (2020) Potential indirect effects of the COVID-19 pandemic on use of emergency departments for acute life-threatening conditions — United States, January–May 2020. *MMWR Morb Mortal Wkly Rep* 69:795–800
- Parasole R, Stellato P, Conter V et al (2020) Collateral effects of COVID-19 pandemic in pediatric hematooncology: fatalities caused by diagnostic delay. *Pediatr Blood Cancer* 67:e28482
- Chiaravalli S, Ferrari A, Sironi G et al (2020) A collateral effect of the COVID-19 pandemic: delayed diagnosis in pediatric solid tumors. *Pediatr Blood Cancer* 67:e28640
- Reinstadler SJ, Reindl M, Lechner I et al (2020) Effect of the COVID-19 pandemic on treatment delays in patients with ST-segment elevation myocardial infarction. *J Clin Med* 9:2183
- Masroor S (2020) Collateral damage of COVID-19 pandemic: delayed medical care. *J Card Surg* 35:1345–1347
- Rose DZ, Burgin WS, Renati S (2020) Untreated stroke as collateral damage of COVID-19: "time is brain" versus "stay at home." *Neurohospitalist* 10:291–292
- Gerall CD, DeFazio JR, Kahan AM et al (2020) Delayed presentation and sub-optimal outcomes of pediatric patients with acute appendicitis during the COVID-19 pandemic. *J Pediatr Surg* 56:905–910
- Fisher JC, Tomita SS, Ginsburg HB et al (2020) Increase in pediatric perforated appendicitis in the New York City metropolitan region at the epicenter of the COVID-19 outbreak. *Ann Surg* 273:410–415
- Kvasnovsky CL, Shi Y, Rich BS et al (2020) Limiting hospital resources for acute appendicitis in children: lessons learned from the U.S. epicenter of the COVID-19 pandemic. *J Pediatr Surg* 56:900–904
- Lee-Archer P, Blackall S, Campbell H et al (2020) Increased incidence of complicated appendicitis during the COVID-19 pandemic. *J Paediatr Child Health* 56:1313–1314
- Maneck M, Gunster C, Meyer HJ et al (2020) Influence of COVID-19 confinement measures on appendectomies in Germany — a claims data analysis of 9,797 patients. *Langenbecks Arch Surg* 406:385–391
- Snapiri O, Rosenberg Danziger C, Krause I et al (2020) Delayed diagnosis of paediatric appendicitis during the COVID-19 pandemic. *Acta Paediatr* 109:1672–1676
- Saleem A, Sajid MI, Arshad M (2020) Acute appendicitis during SARS-CoV-2: a brief communication of patients and changes in clinical practice from a single institute in Pakistan. *J Pediatr Surg* 55:2844–2845
- Montalva L, Haffreingue A, Ali L et al (2020) The role of a pediatric tertiary care center in avoiding collateral damage for children with acute appendicitis during the COVID-19 outbreak. *Pediatr Surg Int* 36:1397–1405
- La Pergola E, Sgro A, Rebosio F et al (2020) Appendicitis in children in a large Italian COVID-19 pandemic area. *Front Pediatr* 8:600320
- O'Brien CM, Jung K, Dang W et al (2020) Collateral damage: the impact of the COVID-19 pandemic on acute abdominal emergency presentations. *J Am Coll Radiol* 17:1443–1449
- Bhambhani HP, Rodrigues AJ, Yu JS et al (2020) Hospital volumes of 5 medical emergencies in the COVID-19 pandemic in 2 US medical centers. *JAMA Intern Med* 181:272–274
- Gibson AL, Chen BY, Rosen MP et al (2020) Impact of the COVID-19 pandemic on emergency department CT for suspected diverticulitis. *Emerg Radiol* 27:773–780
- Romero J, Valencia S, Guerrero A (2020) Acute appendicitis during coronavirus disease 2019 (COVID-19): changes in clinical presentation and CT findings. *J Am Coll Radiol* 17:1011–1013
- Narsule CK, Kahle EJ, Kim DS et al (2011) Effect of delay in presentation on rate of perforation in children with appendicitis. *Am J Emerg Med* 29:890–893
- Zhai LL, Wang W, Wu L, Tang ZG (2020) COVID-19 with abdominal symptoms and acute abdominal pain: a guide to identification for general practice. *Br J Gen Pract* 70:358–359

22. Saeed U, Sellevoll HB, Young VS et al (2020) Covid-19 may present with acute abdominal pain. *Br J Surg* 107:e186–e187
23. Suwanwongse K, Shabarek N (2020) Pseudo-appendicitis in an adolescent with COVID-19. *Cureus* 12:e9394
24. Ahmed AOE, Badawi M, Ahmed K, Mohamed MFH (2020) Case report: COVID-19 masquerading as an acute surgical abdomen. *Am J Trop Med Hyg* 103:841–843
25. Hayatghaibi SE, Trout AT, Dillman JR (2020) Value assessment of evolving pediatric appendicitis imaging strategies between 2004 and 2018. *J Am Coll Radiol* 17:1549–1554

Publisher's note Springer Nature remains neutral with regard to jurisdictional claims in published maps and institutional affiliations.