



Technical Note

Resection osteotomy for calcaneus flattening after micro-surgical flap: technical note[☆]



Mário Yoshihide Kuwae, Edegmar Nunes Costa, Ricardo Pereira da Silva, Alexandre Daher Albieri, Frederico Barra de Moraes*

Universidade Federal de Goiás (UFG), Faculdade de Medicina, Goiânia, GO, Brazil

ARTICLE INFO

Article history:

Received 21 February 2016

Accepted 18 March 2016

Available online 1 December 2016

Keywords:

Fractures, open

Calcaneus

Orthopedic procedures/methods

Surgical flaps

Osteotomy/methods

ABSTRACT

An open fracture of the calcaneus with loss of substance is a challenging injury and requires specialized care, involves high costs, and demands attention despite its lower incidence. The main complications are osteomyelitis, pressure ulcers, and fistulas, as well as pain conditions in the lateral, medial, and plantar regions. This is due to the wide loss of tissue and the change in anatomical conformation of the calcaneus in some cases. However, in cases of flattening of the calcaneus bone, these complications may be prevented or treated successfully. This technical note describes the resection osteotomy technique for calcaneus flattening to prevent and treat complications after micro-surgical flap in cases of open fracture or loss of substance.

© 2016 Sociedade Brasileira de Ortopedia e Traumatologia. Published by Elsevier Editora Ltda. This is an open access article under the CC BY-NC-ND license (<http://creativecommons.org/licenses/by-nc-nd/4.0/>).

Osteotomia de ressecção para aplainamento do calcâneo após retalho microcirúrgico: nota técnica

RESUMO

A fratura exposta do calcâneo com perda de substância é uma lesão desafiadora, demanda cuidados especializados, envolve elevados custos e exige atenção, apesar de sua menor incidência. As principais complicações são osteomielite, úlceras de pressão, fistulas, além de quadros algícos nas regiões lateral, medial e plantar. Essa relação se deve à grande perda de tecido e à mudança da conformação anatômica do calcâneo em alguns casos. Porém, quando ocorre uma modelação do formato ósseo do calcâneo com seu aplainamento, essas

Palavras-chave:

Fraturas expostas

Calcâneo

Procedimentos

ortopédicos/métodos

Retalhos cirúrgicos

Osteotomia/métodos

[☆] Study conducted at the Universidade Federal de Goiás, Faculdade de Medicina, Hospital das Clínicas, Departamento de Ortopedia e Traumatologia, Goiânia, GO, Brazil.

* Corresponding author.

E-mail: frederico.barra@yahoo.com.br (F.B. Moraes).

<http://dx.doi.org/10.1016/j.rboe.2016.11.003>

2255-4971/© 2016 Sociedade Brasileira de Ortopedia e Traumatologia. Published by Elsevier Editora Ltda. This is an open access article under the CC BY-NC-ND license (<http://creativecommons.org/licenses/by-nc-nd/4.0/>).

complicações podem ser prevenidas ou tratadas com sucesso. O objetivo desta nota técnica é descrever a técnica de osteotomia de ressecção para aplainamento do calcâneo na prevenção e no tratamento de complicações após retalho microcirúrgico em casos de fratura exposta ou perda de substância.

© 2016 Sociedade Brasileira de Ortopedia e Traumatologia. Publicado por Elsevier Editora Ltda. Este é um artigo Open Access sob uma licença CC BY-NC-ND (<http://creativecommons.org/licenses/by-nc-nd/4.0/>).

Introduction

Open fractures of the calcaneus classified as Gustilo and Anderson type III¹⁻⁴ are associated with short- and long-term complications. The main complications are infections, pain and fistulas or pressure ulcers in the topography of the lower calcaneal tuberosity, even after myocutaneous covering with vascularized flaps, which can be observed in up to one-third of cases.⁵⁻¹¹

This is due to the extensive tissue loss and to changes in the shape of the calcaneus in some cases. However, in cases of flattening of the calcaneus bone, these complications may be successfully prevented or treated.

The purpose of this note is to describe a resection osteotomy technique for calcaneus flattening, aiming to prevent and treat complications after microsurgical flap in cases of open fracture or tissue loss.

Technical note

The steps of the proposed surgery are:

- (1) Resection of ulcers and fistulas in the calcaneal region under the existing microsurgical flap; or preparation of the area for the flap that will be made (Fig. 1);
- (2) Resection osteotomy for calcaneus flattening in the posteroinferior tuberosity, avoiding areas of overpressure on the old or the new flap (Fig. 2);
- (3) Coverage with a microsurgical flap (Fig. 3).

Discussion

Open calcaneal fractures with loss of substance are challenging injuries that require specialized care, involve high costs,

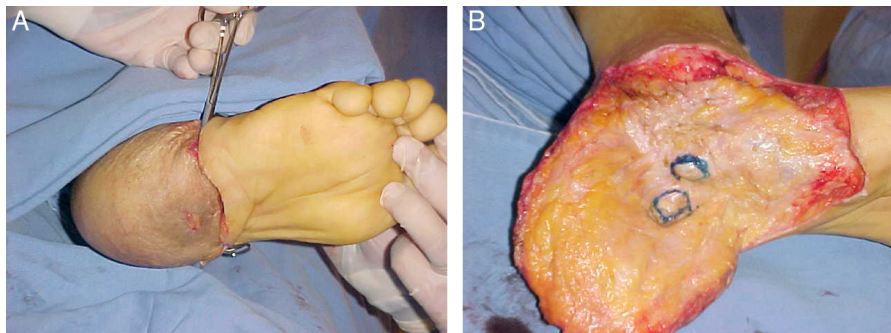


Fig. 1 – (A) Complication of calcaneal flap with plantar ulcer and fistula and (B) debridement of devitalized tissue and local preparation.

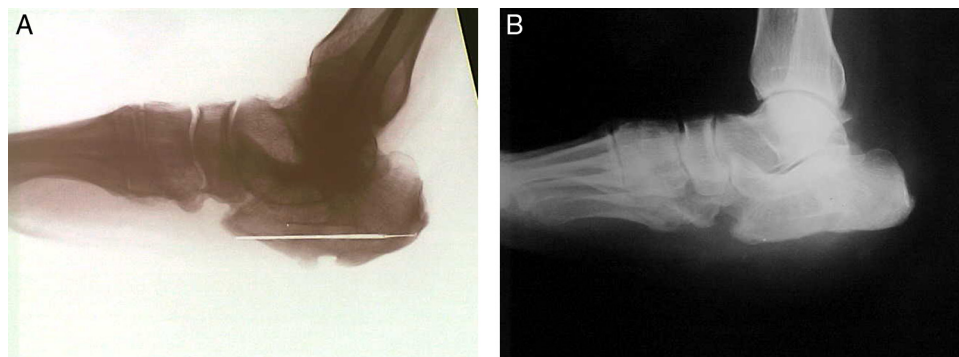


Fig. 2 – Lateral radiographs of the calcaneus. (A) Preoperative, with no evidence of osteomyelitis and areas of overpressure and (B) postoperative, highlighting the resection of the posteroinferior calcaneal tuberosity, correcting the deformities.

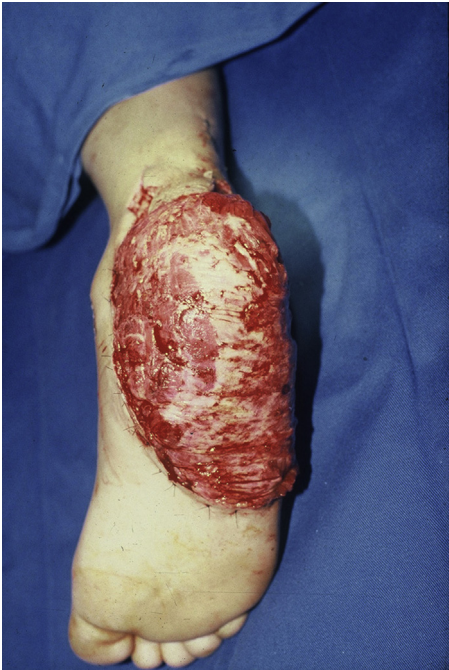

Fig. 3 – Post-operative aspect of the latissimus dorsi microsurgical flap.

and demand attention, despite their low incidence. The main complications are osteomyelitis, pressure ulcers and fistulas, as well as pain conditions in the lateral, medial, and plantar regions.⁵⁻¹¹

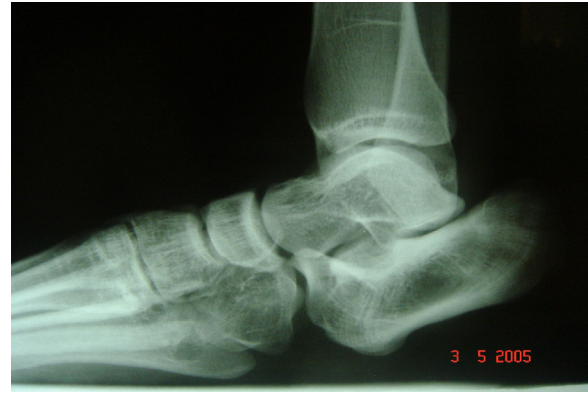

Fig. 6 – Lateral radiograph of the calcaneus, with no evidence of osteomyelitis and natural flattening of posteroinferior calcaneal tuberosity.

This new technique was designed after following-up a teenage patient (Fig. 4) who had had a calcaneal injury, healed by second intention and then developed ulcers and fistulas due to the presence of increased pressure points. The lesion was resected and a microsurgical flap of the latissimus dorsi was made for better coverage of the area (Fig. 5), but the calcaneus was left unapproached.

After approximately ten years, the patient suffered an ankle sprain during a soccer game; when the ankle radiographs were assessed (Fig. 6), a natural flattening of the plantar portion of the calcaneus was observed, without complications such as ulcers, fistulas, or pain (Fig. 7).

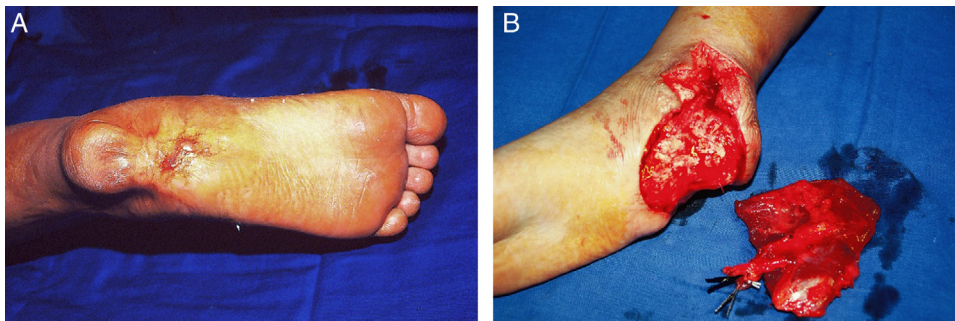


Fig. 4 – (A) Preoperative clinical aspect of a patient with ulcer and active fistula in pressure areas in the calcaneal region and (B) intraoperative image of lesion resection and microsurgical flap transplantation.

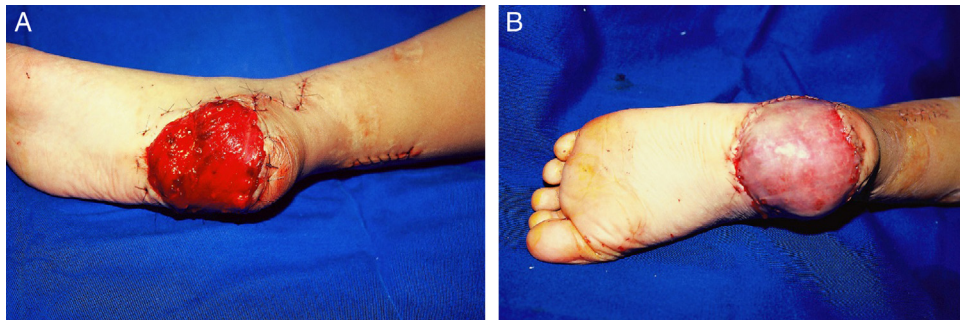

Fig. 5 – (A) Postoperative clinical aspect of a patient with microsurgical flap in the calcaneus and (B) with bone graft.

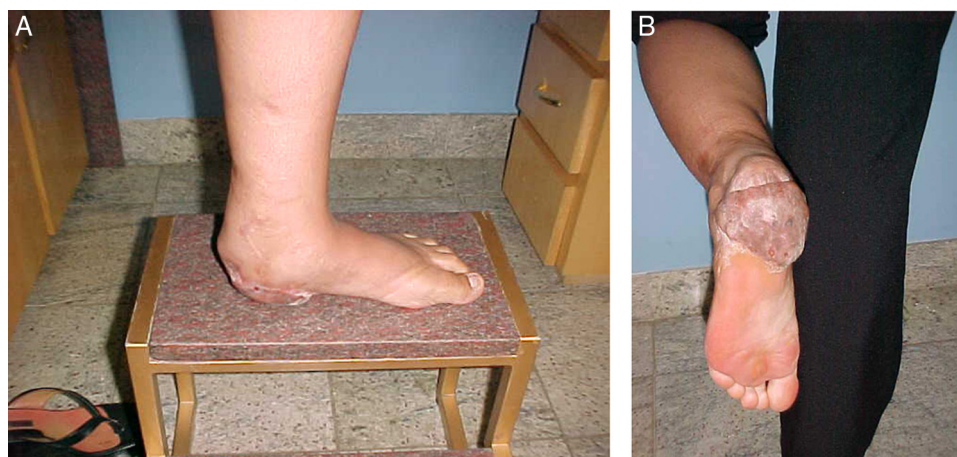


Fig. 7 – Clinical aspect of the microsurgical flap and graft on the calcaneus (A and B) after ten years, without the presence of ulcers, fistulae, or regional pain.

Final considerations

The resection osteotomy technique for flattening the calcaneus can be used for the prevention or treatment of complications after a microsurgical flap in the region. Clinical and surgical studies with a larger number of cases should be performed for better evaluation of the technique.

Conflicts of interest

The authors declare no conflicts of interest.

REFERENCES

- Gustilo RB, Mendoza RM, Williams DN. Problems in the management of type III (severe) open fractures: a new classification of type III open fractures. *J Trauma*. 1984;24(8):742-6.
- Acello AN, Wallace GF, Pachuda NM. Treatment of open fractures of the foot and ankle: a preliminary report. *J Foot Ankle Surg*. 1995;34(4):329-46.
- Gustilo RB. Current concepts in the management of open fractures. *Instr Course Lect*. 1987;36:359-66.
- Gustilo RB, Anderson JT. Prevention of infection in the treatment of one thousand and twenty-five open fractures of long bones: retrospective and prospective analyses. *J Bone Joint Surg Am*. 1976;58(4):453-8.
- Siebert CH, Hansen M, Wolter D. Follow-up evaluation of open intra-articular fractures of the calcaneus. *Arch Orthop Trauma Surg*. 1998;117(8):442-7.
- Heier KA, Infante AF, Walling AK, Sanders RW. Open fractures of the calcaneus: soft-tissue injury determines outcome. *J Bone Joint Surg Am*. 2003;85-A(12):2276-82.
- Aldridge JM 3rd, Easley M, Nunley JA. Open calcaneal fractures: results of operative treatment. *J Orthop Trauma*. 2004;18(1):7-11.
- Berry GK, Stevens DG, Kreder HJ, McKee M, Schemitsch E, Stephen DJ. Open fractures of the calcaneus: a review of treatment and outcome. *J Orthop Trauma*. 2004;18(4):202-6.
- Benirschke SK, Kramer PA. Wound healing complications in closed and open calcaneal fractures. *J Orthop Trauma*. 2004;18(1):1-6.
- Abidi NA, Dhawan S, Gruen GS, Vogt MT, Conti SF. Wound-healing risk factors after open reduction and internal fixation of calcaneal fractures. *Foot Ankle Int*. 1998;19(12):856-61.
- Levin LS, Nunley JA. The management of soft-tissue problems associated with calcaneal fractures. *Clin Orthop Relat Res*. 1993;(290):151-6.