

## CLINICAL AND CEPHALOMETRIC ANALYSIS OF THREE CASES WITH PYCNODYSOSTOSIS: CASE REPORTS\*

### *Piknodizostozisli Üç Olgunun Klinik ve Sefalometrik Analizi: Olgu Sunumu*

Eser ÇAPAN<sup>1</sup>, Serap TURAN<sup>2</sup>, Hülya KILIÇOĞLU<sup>3</sup>

Received: 06/04/2014

Accepted: 19/06/2014

#### ABSTRACT

The aim of this article is to present intra- and extra-oral and cephalometric findings of three patients with a rare disease: the pycnodysostosis. Two cases had skeletal Class III malocclusion due to maxillary retrognathia and one had bimaxillary retrusion with Class I relationship. Total circular crossbite, increased gonial angle and vertical facial proportions, deep-narrow palates and retruded upper lip were found in all cases. Maxillary expansion, face mask treatment or/and orthognathic surgery are treatment alternatives, considering the growth and development. Bone fragility and the risk of osteomyelitis after extractions should be considered in such cases before orthodontic treatment and orthognathic surgery.

**Keywords:** Pycnodysostosis, clinical evaluation, cephalometric evaluation

#### ÖZ

Bu çalışma ender rastlanan piknodizostozisli üç olgunun ağız dışı ve içi bulguları ile sefalometrik değerlendirmesini sunmaktadır. Piknodizostozisli üç olgunun ağız dışı ve ağız içi bulguları klinik olarak değerlendirilmiş, hastalardan alınan lateral sefalometrik radyografiler üzerinde iskeletsel ve dişsel ölçümler gerçekleştirilmiştir. Olguların ikisinde maksiller retrognatiye bağlı iskeletsel sınıf III yapı, diğesinde ise bimaxiller retrüzyon ile beraber sınıf I yapı mevcuttur. Tüm hastalarda total sirküler çapraz kapanış, artmış gonial açı ve dik yön yüz boyutları, derin damak kubbesi ile üst dudakta retrüzyon gözlenmiştir. Bu tip olguların tedavisinde büyüme-gelişme dönemi de göz önünde bulundurularak maksiller genişletme, yüz maskesi veya ortognatik cerrahi tedavi alternatifleri arasındadır. Piknodizostozisli hastalarda kemik kırılabilirliği ve diş çekimlerinden sonra osteomyelit riskinin yüksek olması nedeniyle yapılacak ortodontik tedavi ve ortognatik cerrahi müdahalelerde bu durum gözönüne alınarak hastaya yaklaşımda bulunulmalıdır.

**Anahtar kelimeler:** Piknodizostozis, klinik değerlendirme, sefalometrik değerlendirme

<sup>1</sup> Private practice

<sup>2</sup> Department of Pediatric Endocrinology Faculty Medicine Marmara University

<sup>3</sup> Department of Orthodontics Faculty of Dentistry Istanbul University

\* Presented in the 6th International Scientific I.U.D.H. F. Congress.

21-23 November 2013 I.U. Beyazıt Campus, New Convention Center, Istanbul



## Introduction

Pycnodysostosis (PCND) is an autosomal genetic disorder which was first described in 1962 by Maroteaux and Lamy (1) under the name of 'diastrophic dwarfism' and has been distinguished from osteopetrosis and cleidocranial dysostosis. Authors have chosen the name pycnodysostosis by considering the density and skeletal dysplasia in radiographs. The term is derived from the Greek words pycnos (dense), dys (defective), and ostosis (bone). Mutations in the cathepsin K encoding gene are thought to cause PCND. This gene is responsible for degradation of type 1 collagen that forms 95 % of the organic bone matrix and its mutation causes a decrease in the bone turnover and deterioration of the bone structure. This disorder is therefore characterized by generalized bony sclerosis and bone fragility (2, 3). Pycnodysostosis is a rare disorder (incidence: 1.7 per 1 million birth) (4). 30 % of the cases are offsprings of consanguineous unions. Patients with PCND usually have normal intelligence, sexual development and life spans (5). Main features of PCND are osteosclerosis, cranial dysplasia, clavicular dysplasia, dolichocephaly, obtused mandibular gonial angle, blue sclera, open cranial sutures, midface retrusion or hypoplasia and micrognathia. Clinical features include peculiar face, prominent forehead, beaked nose, receding jaw and total/partial dysplasia of the terminal phalanges. The extremities are stunted and height at adult age can vary from 134 cm to 152 cm (6, 7). Intraoral features include anterior crossbite, posterior open bite, persistence of deciduous teeth with premature or delayed eruption of the permanent teeth, which can cause crowding. In addition, poor oral hygiene, periodontal disease, dental caries and a grooved palate have been observed. Patients are susceptible to pathological fractures and mandibular osteomyelitis due to the disorders in the blood vessels of sclerotic bones (8, 9). Pharyngeal constriction and obstructive sleep apnea are common in patients with PCND because of the long soft palate and mandibular hypoplasia (10).

The aim of this article is to describe clinical and radiographic findings of three cases referred to our clinic with the diagnosis of PCND.

## Case series

### Case 1

The first case was a 15-year-old (chronological and skeletal) girl, who was in the post peak stage of growth. She had completed 99 % of her skeletal maturity and was a mouth and nasal breather. Her medical history revealed

adenotonsillectomy at the age of five. Oral hygiene status was subjectively classified as moderate.

She had skeletal class III malocclusion due to the maxillary retrognathia and hyperdivergent vertical growth pattern (Table 1). Molar and canine relationship were Class III with -5 mm overjet and 3 mm overbite. According to McNamara analysis, the transpalatal width was 7,9 mm. The teeth numbered according to the FDI 2-digit system as 15,17,18,25,27,28 and 34 have not yet erupted whereas those numbered 65,74 and 84 have been observed to persist. Patient had a straight profile (Figure 1 and 2).

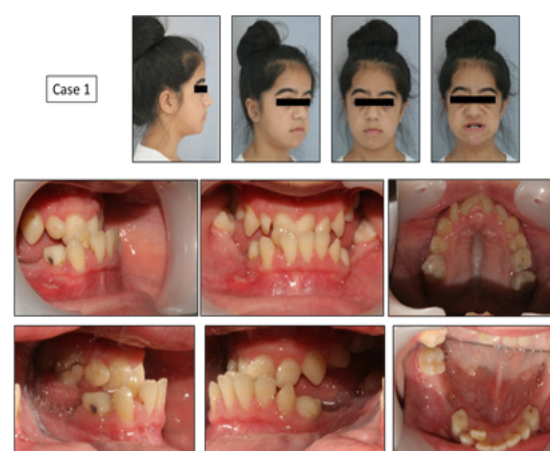


Figure 1. Intra- and extra-oral photographs of case 1.

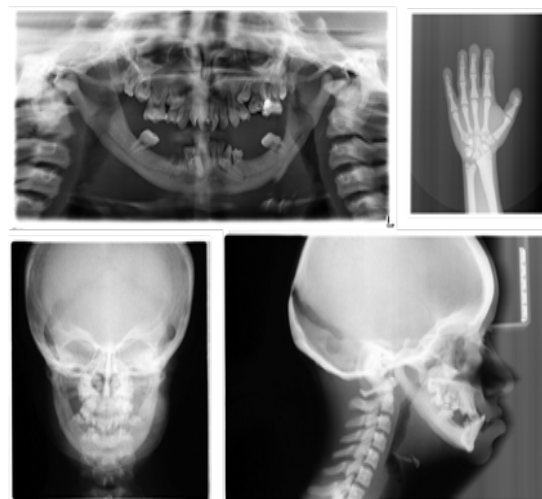

Figure 2. Radiographs of case 1.

### Case 2

Chronological age of the second case was 13 years and 4 months and his skeletal age was 15 years. He was in the post peak stage of growth and has completed 95 % of his skeletal maturity. He was a mouth and nasal breather. Oral

hygiene status was subjectively classified as moderate.

He had skeletal class I malocclusion, bimaxillary retrusion and hyper divergent vertical growth pattern (Table 1).

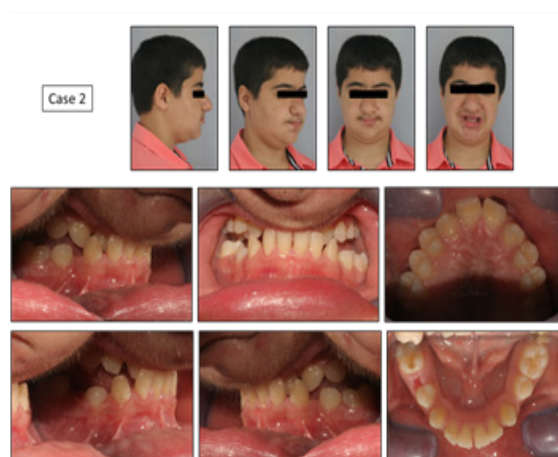Class I molar and Class II canine relationships were observed on the right side. Left side presented Class III

molar Class II canine relationships. Overjet and overbite were, respectively, -4 mm and 3 mm. According to McNamara analysis, the transpalatal width was 3,5 mm.

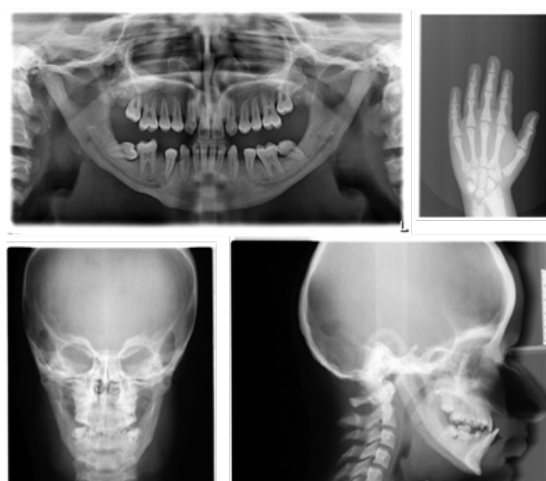The teeth numbered 12 and 22 were congenitally missing, whereas those numbered 34 and 35 have been extracted. Patient had a straight profile (Figure 3 and 4).

**Table 1.** Cephalometric analysis of three cases with pycnodysostosis.

Measurement	Case 1	Case 2	Case 3
SNA angle	74°	77°	74°
SNB angle	79°	76°	80°
ANB angle	-5°	1°	-6°
Wits	-14 mm	-0,7 mm	-8 mm
SN/GoMe angle	44°	43°	44°
N-S-Gn (Y axis) angle	70°	68°	65°
S-Go/N-Me angle	57 %	%59	%64
Ar-Go-Me(Gonial angle)	153°	147°	145°
Interincisal angle	129°	121°	127°
UI/NA angle	26°	24°	23°
L1/NB angle	29°	33°	35°
IMPA angle	85°	95°	100°
Holdaway Difference	8 mm	10 mm	7 mm
Overjet	-5 mm	-4 mm	-7 mm
Overbite	3 mm	3 mm	3 mm
N-A-Pg angle	175°	176°	170°
S line- lips U/L	-3mm/+5 mm	-5mm/-1 mm	-4mm/+1 mm



**Figure 3.** Intra- and extra-oral photographs of case 2



**Figure 4.** Radiographs of case 2.

### Case 3

Chronological age of the third case was 14 years and 10 months and his skeletal age was 18 years. She had completed her growth and was skeletally mature. Her medical history revealed adenotonsillectomy at the age of three. She was a mouth and nasal breather. Oral hygiene status was subjectively classified as moderate.

She had skeletal class III malocclusion due to maxillary retrognathia and hyper divergent vertical growth pattern (Table 1). There was Class III molar relationship on the right side. Class III molar and canine relationships were observed on the left side. Overjet and overbite were, respectively, -7 mm and 3 mm.

According to McNamara analysis, the transpalatal width was 2,3 mm. The teeth numbered 17,18,27 and 28 have not yet erupted, whereas those numbered 35,43,45 have been lost. Patient had a skeletally concave profile but it was balanced by the soft tissue (Figure 5 and 6).

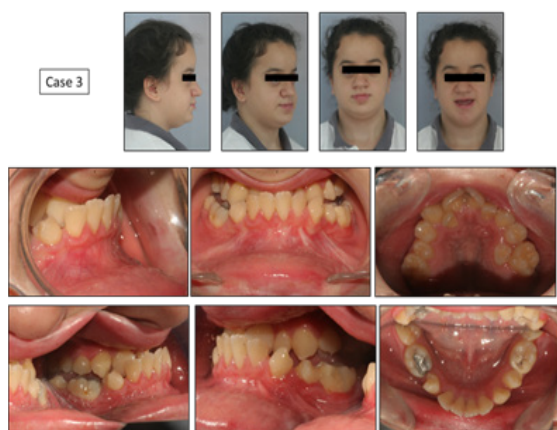

Figure 5. Intra- and extra-oral photographs of case 3.

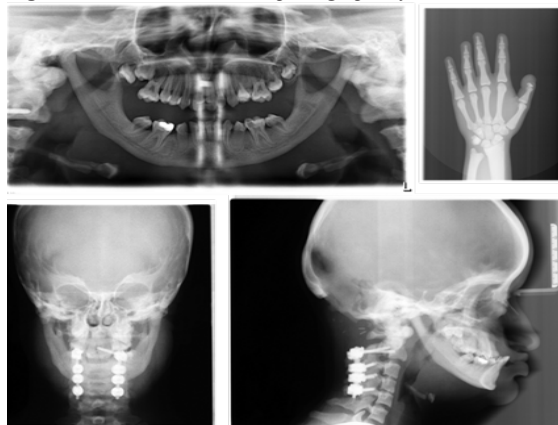

Figure 6. Radiographs of case 3.

### Discussion

Two cases had skeletal Class III pattern due to maxillary retrognathia, and other had bimaxillary retrusion with skeletal Class I pattern. Increased gonial angle and vertical proportions, flattened mandibular angle, peculiar face and retrochelic superior have been observed in all patients. Furthermore, all patients showed total circular crossbite, grooved plate and congenitally missing teeth. Skeletal ages of second and third cases were found to be older than their chronological ages.

All cases showed similar intra- and extra-oral features as reported before. Considering their growth and development as well as the presence of maxillary expansion; face mask appliance or orthognatic surgery are viable treatment options. However, no published article in the current literature could be found about orthodontic or orthopedic treatment of PKND. Ortegosa *et al.* (11) reported that in such cases, maxillary removable appliance with springs associated with serial extractions could be safe for teeth movement.

There are very few reports concerning surgical management of these patients. Long-term stability of the midface is one of the primary concerns among craniofacial surgeons. Although midface advancement would serve as an effective solution to this problem, there has been apprehension surrounding the technique's potential morbidity when used on bone that is already dysvascular, fragile, and considered unlikely to consolidate appropriately (12, 13). Procedures such as bone grafting, fixation screws and bone plates could increase the risk of infection in these patients. Therefore, aside from the speculation of potential morbidity, midface advancement with distraction osteogenesis would seem to be the optimal surgical approach for midface retrusion and exorbitism associated with this particular disease (13, 14).

### Conclusion

PKND is a very rare disease. Therefore, further studies are required to investigate the impacts of orthodontic procedures on the osteoclastic activity, bone metabolism and tissue recovery.

### Source of funding

None declared

### Conflict of interest

None declared



## References

1. Maroteaux P, Lamy M. [Pyknodysostosis]. *Presse Med* 1962;70:999-1002.
2. Norholt SE, Bjerregaard J, Mosekilde L. Maxillary distraction osteogenesis in a patient with pycnodysostosis: a case report. *J Oral Maxillofac Surg* 2004;62(8):1037-1040.
3. Alves Pereira D, Berini Aytés L, Gay Escoda C. Pycnodysostosis. A report of 3 clinical cases. *Med Oral Patol Oral Cir Bucal* 2008;13(10):633-635.
4. Bathi RJ, Masur VN. Pycnodysostosis--a report of two cases with a brief review of the literature. *Int J Oral Maxillofac Surg* 2000;29(6):439-442.
5. O'Connell AC, Brennan MT, Francomano CA. Pycnodysostosis: orofacial manifestations in two pediatric patients. *Pediatr Dent* 1998;20(3):204-207.
6. Fonteles CS, Chaves CM Jr, Da Silveira A, Soares EC, Couto JL, de Azevedo Mde F. Cephalometric characteristics and dentofacial abnormalities of pycnodysostosis: report of four cases from Brazil. *Oral Surg Oral Med Oral Pathol Oral Radiol Endod* 2007;104(4):83-90.
7. Sedano H., Gorlin RJ, Andersen VE. Pycnodysostosis. Clinical and genetic considerations *Am J Dis Child* 1968;116(1):70-77.
8. Hunt NP, Cunningham SJ, Adnan N, Harris M. The dental, craniofacial, and biochemical features of pyknodysostosis: a report of three new cases. *J Oral Maxillofac Surg* 1998;56(4):497-504.
9. Kamak H, Kamak G, Yavuz I. Clinical, radiographic, diagnostic and cephalometric features of pycnodysostosis in comparison with Turkish cephalometric norms: A case report *Eur J Dent* 2012;6(4):454-459.
10. Muto T, Yamazaki A, Takeda S, Tsuji Y, Shibata T. Pharyngeal narrowing as a common feature in pycnodysostosis--a cephalometric study. *Int J Oral Maxillofac Surg* 2005;34(6):680-685.
11. Ortegosa MV, Bertola DR, Agüena M, Passos-Bueno MR, Kim CA, de Faria ME. Challenges in the orthodontic treatment of a patient with pycnodysostosis. *Cleft Palate Craniofac J* 2013;51(6):735-739.
12. Hernandez-Alfaro F, Arenaz Bua J, Serra Serrat M, Mareque Bueno J. Orthognathic surgery in pycnodysostosis: a case report. *Int J Oral Maxillofac Surg* 2011;40(1):110-113.
13. Raposo-Amaral CE, Tong A, Denadai R, Yalom A, Raposo-Amaral CA, Bertola D, Li A, Jarrahy R. A subcranial Le Fort III advancement with distraction osteogenesis as a clinical strategy to approach pycnodysostosis with midface retrusion and exorbitism. *J Craniofac Surg* 2013;24(4):1327-1330.
14. Varol A, Sabuncuoglu FA, Sencimen M, Akcam T, Olmez H, Basa S. Rigid external maxillary distraction and rhinoplasty for pyknodysostosis. *J Craniofac Surg* 2011;22(3):901-904.

### Corresponding Author:

#### Eser ÇAPAN

Teşvikiye Caddesi Aydın Apartmanı No:51  
Kat 2 Daire 4 Nişantaşı/İstanbul TURKEY  
Phone: 0 212 231 13 15  
e-mail: esercapan@hotmail.com