

Mature oocyte retrieval during laparotomic debulking surgery following random-start controlled ovarian stimulation for fertility preservation in a patient with suspected ovarian cancer

Seul Ki Kim^{1,2*}, Myo Sun Kim^{1*}, Hoon Kim², Sun Mie Kim^{2,3}, Jung Ryeol Lee^{1,2}, Chang Suk Suh^{1,2},
Seok Hyun Kim²

Department of Obstetrics and Gynecology, ¹Seoul National University Bundang Hospital, Seongnam; ²Seoul National University College of Medicine, Seoul; ³Healthcare System Gangnam Center, Seoul National University Hospital, Seoul, Korea

Herein, we report a case of successful mature oocyte retrieval during laparotomy after random-start controlled ovarian stimulation (COS) in a 21-year-old nulliparous woman with suspected recurrent ovarian immature teratoma. The patient had been diagnosed with stage IIIC immature teratoma two years earlier following a staging operation, including right oophorectomy and left ovarian cystectomy. And she had subsequently undergone four rounds of postoperative adjuvant chemotherapy with bleomycin, etoposide, and cisplatin. Approximately two years after the initial surgery, she was strongly suspected of having recurrent ovarian immature teratoma on radiologic follow-up. We performed random-start COS and *in vivo* oocyte retrieval during laparotomic debulking surgery including left oophorectomy. Eight mature oocytes were successfully retrieved and vitrified for fertility preservation. The final pathologic diagnosis was mature cystic teratoma of the ovary and peritoneal implants consistent with gliomatosis peritonei. This is the first case report in which random-start COS and *in vivo* oocyte retrieval were performed.

Keywords: Fertility preservation; Laparotomy; Oocyte retrieval; Ovarian neoplasms

Introduction

Currently, available options for preserving fertility are cryopreservation of embryos, oocytes, ovarian tissue and treatment with gonadotropin-releasing hormone (GnRH) analogs [1]. However, ovarian tissue cryopreservation and subsequent transplantation should be avoided owing to the risk of cancer reimplantation, and GnRH analogs can only be used in cases where at least one ovary remains. Therefore, the only option for patients with ovarian cancer who require oophorectomy is oocyte or embryo cryopreservation.

Transvaginal ultrasound-guided oocyte retrieval for oocyte or embryo cryopreservation has limitations. There is a potential risk of malignant spread secondary to cancer cell spillage by puncture of the tumor mass. The tumor can obscure the view of normal follicles, thereby preventing optimal oocyte retrieval. There are cases where the follicle is near the tumor making

aspiration difficult, or where the tumor mass is near the vagina in the way of aspiration. In contrast, during a debulking operation for ovarian cancer, careful oocyte retrieval using a laparotomic approach can be performed without penetrating

Received: 2015.4.20. Revised: 2015.6.3. Accepted: 2015.6.10.

Corresponding author: Jung Ryeol Lee
Department of Obstetrics and Gynecology, Seoul National University Bundang Hospital, 82 Gumi-ro 173beon-gil, Bundang-gu, Seongnam 13620, Korea
Tel: +82-31-787-7257 Fax: +82-31-787-4054
E-mail: leejrmd@snu.ac.kr

*These two authors contributed equally to this work.

Articles published in *Obstet Gynecol Sci* are open-access, distributed under the terms of the Creative Commons Attribution Non-Commercial License (<http://creativecommons.org/licenses/by-nc/3.0/>) which permits unrestricted non-commercial use, distribution, and reproduction in any medium, provided the original work is properly cited.

Copyright © 2015 Korean Society of Obstetrics and Gynecology

Table 1. Main results of the literature concerning oocyte retrieval from tumor affected ovary during laparotomic oophorectomy and the present study

Diagnosis	Operation	COH or IVM	Oocyte retrieval	IVF outcome			No. of embryo transferred	Preg-nancy outcome
				Retrieval	Culture	Cryopreservation		
Huang et al. (2007) [2]	LSO + ROC	IVM	Ex vivo	4 GV	2 Mature oocytes	2 Mature oocytes	NA	NA
Fatemi et al. (2011) [5]	RSO	COH (conventional GnRH antagonist protocol)	Ex vivo	11 Mature oocytes		7 Zygotes	NA	NA
Bocca et al. (2011) [6]	RSO	COH (conventional GnRH antagonist protocol)	Ex vivo	14 Mature oocytes		14 mature oocytes	NA	NA
Fadini et al. (2012) [4]	RSO + LOC	IVM	In vivo	3 GV	3 Mature oocytes	3 Mature oocytes	1	No pregnancy
Prasath et al. (2014) [3]	LO	IVM	Ex vivo	4 GV	4 Mature oocytes	3 Embryos	2	Live birth
Present case	LSO	Random start COH	In vivo	8 Mature oocytes + 1 immature oocyte		8 Mature oocytes	NA	NA

COH, controlled ovarian hyperstimulation; IVM, *in vitro* maturation; IVF, *in vitro* fertilization; LSO, left salpingo-oophorectomy; ROC, right ovarian cystectomy; GV, germinal vesicle; RSO, right salpingo-oophorectomy; GnRH, gonadotropin-releasing hormone; LOC, left ovarian cystectomy; LO, left oophorectomy.

the tumor and without causing cancer cell spillage [2-6].

In this report, we outline a successful case of oocyte retrieval performed via laparotomy during debulking surgery, to prevent the possibility of rupture and cancer cell spillage that is associated with transvaginal oocyte retrieval.

Case report

In May 2014, a 21-year-old nulliparous woman was referred by her gynecologic oncologist for fertility preservation prior to a second debulking surgery. Two years earlier (October 2012), she had undergone a fertility-sparing operation including right salpingo-oophorectomy, left ovarian tumorectomy, omentectomy, total splenectomy, cholecystectomy, appendectomy, and diaphragmatic peritonectomy. Pathologic findings indicated an immature teratoma in the right ovary and the fallopian tube, as well as teratoma implants with gliomatosis peritonei in the left ovarian mass, uterine wall, peritoneum, omentum, appendix, spleen, gallbladder, and diaphragm. The residual tumor size after the initial staging operation was <0.1 cm. The final diagnosis was immature teratoma of the ovary classified as stage IIIC according to the International Federation of Gynecology and Obstetrics. The patient underwent four rounds of adjuvant gonadotoxic chemotherapy (bleomycin, etoposide, and cisplatin) up to March 2013. During the chemotherapy, a GnRH agonist (leuprorelin acetate; Leuplin, 3.75 mg; Takeda Chemical Industries, Osaka, Japan) was administered monthly to minimize chemotherapy-induced gonadotoxicity. A follow-up computed tomography was performed at six monthly intervals. Approximately two years after the initial surgery, the patient was strongly suspected of having a recurrent ovarian immature teratoma following identification of a 4-cm multicystic lesion by using computed tomography and magnetic resonance imaging. Her CA-125 level was normal (13 U/mL). The gynecologic oncologist and reproductive specialist concluded that the optimal treatment option for the patient was oocyte cryopreservation and removal of the remaining ovary. At every step of the decision-making process, the patient received expert counseling and was given the opportunity to make active decisions about preserving her fertility.

Upon her first visit to the fertility preservation clinic, the patient was on day 25 of her menstrual cycle. Ultrasonography examination showed the left ovary with five antral follicles and an ovarian tumor. Basal hormone levels were measured on

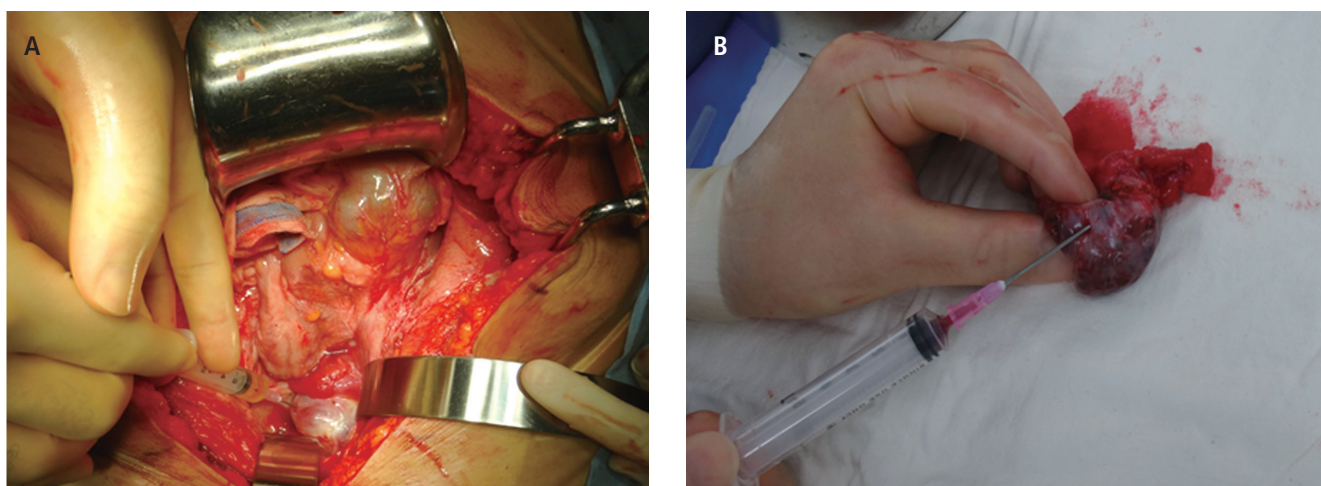


Fig. 1. (A) *In vivo* oocyte retrieval via laparotomy after controlled ovarian stimulation of the cancer-affected ovary. (B) *Ex vivo* oocyte retrieval from the excised ovary after oophorectomy.

the same day: luteinizing hormone, 2.83 mIU/mL; follicle-stimulating hormone, 2.52 mIU/mL; progesterone, 3.25 ng/mL; estradiol, 64 pg/mL; and anti-Müllerian hormone, 1.46 ng/mL. Although the patient was in the luteal phase, ovarian stimulation was initiated that evening with gonadotropin (Gonal-F; Merck Serono, Rockland, MA, USA) at a dose of 300 IU/day; a total of 2,400 IU was administered over eight days. Despite the controlled ovarian stimulation (COS), the patient's next menstrual cycle began on stimulation day 4. A GnRH antagonist (Cetrotide, Merck Serono) was administered four times on stimulation days 6 to 9. Oocyte maturation was induced with 250 µg of recombinant human chorionic gonadotropin (hCG) (Ovidrel; EMD Serono, Rockland, MA, USA) after the mean diameter of the leading follicle had reached 18 mm. The patients' hormone levels were determined on the hCG triggering day: estradiol, 439 pg/mL; and progesterone, 0.86 ng/mL. The operation was scheduled for 36 hours after triggering oocyte maturation by hCG.

Laparotomy showed that the stimulated enlarged left ovary was intact with no rupture. We had planned to perform oocyte retrieval within a pouch; however, this was not possible because of adhesion around the ovary. Therefore, we performed oocyte retrieval carefully without a pouch in the operation field. All visible follicles were aspirated using a 5-mL syringe with an 18-gauge needle before starting the surgical procedure (Fig. 1A). After aspiration, buffer solution including Ham's F-10 nutrient mixture (Gibco Life Technologies, Breda, The Netherlands) and 40 IU/mL of heparin was supplemented. And then, we immediately performed *ex vivo* oocyte retrieval

on the excised ovary to obtain additional oocytes using syringe prefilled with 1 mL of buffer solution (Fig. 1B); however, only a small amount of blood was obtained. Before oocyte retrieval, 10 follicles had been observed on ultrasonography; nine oocytes were obtained including eight mature (metaphase II) oocytes and one oocyte in metaphase I. For oocyte cryopreservation, oocytes were denuded from cumulus cells using hyaluronidase. After denudation, the oocytes were washed several times to eliminate hyaluronidase or other cell fragmentations. After preparation, the eight mature oocytes were cryopreserved by performing vitrification.

A complete debulking surgery was performed including left oophorectomy and multiple peritoneal seeding nodule resections on the uterine serosa, mesentery, and bowel serosa. The final pathology confirmed mature cystic teratoma of the left ovary, and multiple seeding nodules showed teratoma with gliomatosis peritonei. Follow-up imaging six months after the debulking surgery without additional chemotherapy showed no recurrence of the tumor as compared with immediate postoperative imaging. It was the patient's intention to try to become pregnant using the cryopreserved mature oocytes in the future.

Discussion

To date, five case reports of oocyte retrieval from a tumor-affected ovary during laparotomic oophorectomy have been published [2-6]. However, this is the first case in which a

random-start COS protocol was applied in an ovarian cancer patient who required debulking surgery (Table 1) [2-6].

Among the previous case reports, immature oocytes were retrieved from tumor-affected ovaries in three patients, after which *in vitro* maturation was performed [2-4]. *In vitro* maturation without COS has some benefits, because the safety of ovarian stimulation in a patient suspected of ovarian cancer prior to surgery has not been fully established; however, few oocytes are aspirated from unstimulated ovaries, and immature oocytes at germinal vesicle stage frequently fail to complete maturation *in vitro*.

In the other two reports, patients had undergone oocyte retrieval after a conventional COS protocol [5,6]. Because conventional COS protocols require 2 to 5 weeks depending on the patients' menstrual cycle, conventional COS is not optimal for emergency fertility preservation in cancer patients. Several recent studies have shown that a random-start protocol has a comparable outcome to a conventional protocol [7,8]. Using a random-start stimulation protocol, a sufficient number of mature oocytes can be retrieved within two weeks. Therefore, if a gynecologic oncologist makes an early referral to a reproductive specialist and if fertility preservation is discussed at the time of planning the cancer treatment, young women with ovarian cancer who require oophorectomy could have an opportunity to achieve parenthood.

Only one out of five patients in the previous case reports had undergone *in vivo*, rather than *ex vivo*, oocyte retrieval. *Ex vivo* retrieval has the benefit of minimizing possible spillage of cancer cells. However, the interruption of blood supply to resected ovaries could cause cell injury and deteriorate the quality of retrieved oocytes even if the time between oophorectomy and *ex vivo* oocyte retrieval is short. Therefore, we assumed that *in vivo* oocyte retrieval was optimal for minimizing oocyte damage, and hence attempted to retrieve as many oocytes as possible using this method.

We planned to perform oocyte retrieval within a pouch, but this procedure was not possible due to the adhesion around the ovary. Although we performed oocyte retrieval carefully without a pouch in the operation field with no spillage of fluid grossly into the abdominal cavity or elsewhere, we could not be confident that there was no microspillage of follicular fluid or cancer cell adjacent to the follicles. According to a previous study comparing patients with ovarian cancer stage IA to those with IC associated with intraoperative gross rupture of ovarian capsule, the difference in survival was not significant

[9]; therefore, we can speculate that possible microscopic spillage has no significant influence on the prognosis of disease. However, there is no doubt that the utmost effort should be made to prevent spillage during aspiration.

Great reproductive outcomes for ovarian cancer survivors have been reported in the literature [10,11]. Early counseling, a collaboration between the oncologist and fertility specialist regarding fertility preservation, and prompt initiation of treatment are important for achieving successful outcomes. Furthermore, a cautious approach with individualized treatment and counseling about pregnancy outcome, disease outcome, survival rate, and life expectancy are necessary.

In summary, we report a case of successful random-start COS and *in vivo* oocyte retrieval from a tumor-affected ovary during the laparotomic oophorectomy. This is the first case study in which random-start COS and *in vivo* oocyte retrieval were performed. Our study provides hope for patients with ovarian cancer and encourages health care providers to consider oocyte cryopreservation from tumor-affected ovaries as a feasible and safe procedure.

Conflict of interest

No potential conflict of interest relevant to this article was reported.

References

1. Loren AW, Mangu PB, Beck LN, Brennan L, Magdalinski AJ, Partridge AH, et al. Fertility preservation for patients with cancer: American Society of Clinical Oncology clinical practice guideline update. *J Clin Oncol* 2013;31:2500-10.
2. Huang JY, Buckett WM, Gilbert L, Tan SL, Chian RC. Retrieval of immature oocytes followed by *in vitro* maturation and vitrification: a case report on a new strategy of fertility preservation in women with borderline ovarian malignancy. *Gynecol Oncol* 2007;105:542-4.
3. Prasath EB, Chan ML, Wong WH, Lim CJ, Tharmalingam MD, Hendricks M, et al. First pregnancy and live birth resulting from cryopreserved embryos obtained from *in vitro* matured oocytes after oophorectomy in an ovarian cancer patient. *Hum Reprod* 2014;29:276-8.

4. Fadini R, Dal Canto M, Mignini Renzini M, Milani R, Fruscio R, Cantu MG, et al. Embryo transfer following in vitro maturation and cryopreservation of oocytes recovered from antral follicles during conservative surgery for ovarian cancer. *J Assist Reprod Genet* 2012;29:779-81.
5. Fatemi HM, Kyrrou D, Al-Azemi M, Stoop D, De Sutter P, Bourgain C, et al. Ex-vivo oocyte retrieval for fertility preservation. *Fertil Steril* 2011;95:1787.e15-7.
6. Bocca S, Dedmond D, Jones E, Stadtmayer L, Oehninger S. Successful extracorporeal mature oocyte harvesting after laparoscopic oophorectomy following controlled ovarian hyperstimulation for the purpose of fertility preservation in a patient with borderline ovarian tumor. *J Assist Reprod Genet* 2011;28:771-2.
7. Cakmak H, Katz A, Cedars MI, Rosen MP. Effective method for emergency fertility preservation: random-start controlled ovarian stimulation. *Fertil Steril* 2013;100:1673-80.
8. Kim JH, Kim SK, Lee HJ, Lee JR, Jee BC, Suh CS, et al. Efficacy of random-start controlled ovarian stimulation in cancer patients. *J Korean Med Sci* 2015;30:290-5.
9. Higashi M, Kajiyama H, Shibata K, Mizuno M, Mizuno K, Hosono S, et al. Survival impact of capsule rupture in stage I clear cell carcinoma of the ovary in comparison with other histological types. *Gynecol Oncol* 2011;123:474-8.
10. Park JY, Kim DY, Suh DS, Kim JH, Kim YM, Kim YT, et al. Outcomes of fertility-sparing surgery for invasive epithelial ovarian cancer: oncologic safety and reproductive outcomes. *Gynecol Oncol* 2008;110:345-53.
11. Darai E, Fauvet R, Uzan C, Gouy S, Duvillard P, Morice P. Fertility and borderline ovarian tumor: a systematic review of conservative management, risk of recurrence and alternative options. *Hum Reprod Update* 2013;19:151-66.