

Neonatal corneal ulcer secondary to congenital entropion

Travis K. Redd^{a,b}, Robert C. Kersten^a, Davin Ashraf^a, Lauren Hennein^a,
Gerami D. Seitzman^{a,b,*}

^a Department of Ophthalmology, University of California San Francisco, CA, USA

^b Francis I. Proctor Foundation for Research in Ophthalmology, San Francisco, CA, USA

ARTICLE INFO

Keywords:

Pediatric corneal ulcer
Infectious keratitis
Congenital entropion

ABSTRACT

Purpose: To describe a case of central corneal ulceration in a newborn secondary to congenital entropion.

Observations: Corneal ulcers during infancy are rare and may occur secondary to congenital structural anomalies, including congenital entropion. Correct anatomic eyelid position in newborns is challenging to determine with closed eyelids, and eyelid squeezing during crying and discomfort adds to this challenge.

Conclusions and Importance: This report reinforces the importance of careful examination of the adnexa in infants with corneal ulcers while they are most comfortable, usually after topical anesthesia and prior to placement of eyelid speculum. Ophthalmologists caring for infants must be able to detect this condition because prompt entropion repair is necessary for corneal ulcer resolution and prevention of permanent vision loss.

1. Introduction

Corneal ulcers are a rare but important cause of vision loss in children.¹ This condition presents particular challenges to clinicians due to the difficulty of timely diagnosis, appropriate management, and identification of the underlying etiology. The following case illustrates several salient points of value to ophthalmologists caring for pediatric patients.

2. Case report

A 3-week-old otherwise healthy girl born full term via vaginal delivery presented with discomfort, light sensitivity, and mild discharge from the right eye. Her mother noted immediately from birth the baby had appeared uncomfortable with frequent tight eyelid squeezing. The baby had been previously examined by a pediatric ophthalmologist, diagnosed with bacterial conjunctivitis, and treated with topical tobramycin 0.3% and moxifloxacin 0.5% with no improvement. A culture of the discharge from her eye was read as "normal skin flora" without further specification. After one week of therapy, a corneal epithelial defect with possible underlying stromal infiltrate was noted, prompting referral to our academic medical center. Of note, the mother had vaginal colonization with Group B *Streptococcus* diagnosed during pregnancy and was treated with IV penicillin during labor. There was no maternal history of genital herpes, and vaginal swabs for gonorrhea and chlamydia were negative.

On initial examination, the baby could blink to light in both eyes and was noted to be photophobic in the right eye. Anterior segment examination revealed prominent inferior conjunctival injection and ciliary flush. There was a 2 × 3 mm oval-shaped inferior peripheral corneal epithelial defect with mild underlying stromal infiltrate and no significant corneal thinning (Fig. 1a). No anterior chamber cell was noted on bedside handheld slit lamp examination, and the posterior segment exam was unremarkable. Corneal cultures were directly plated on agar and swabs for herpes simplex and varicella zoster PCR were obtained. Concern for unsuccessful home administration of drops led to inpatient admission with administration of hourly topical fortified vancomycin 50mg/mL and tobramycin 40mg/mL. Cultures and viral PCR testing were negative on two separate occasions. After three days on this regimen the baby appeared less photophobic and the infiltrate had almost completely cleared. However, the corneal epithelial defect remained entirely unchanged (Fig. 1b). Medication toxicity was considered as a potential explanation and she was transitioned back to moxifloxacin 0.3% six times daily and discharged from the hospital.

Over the ensuing week the corneal stroma remained clear, but there was no improvement of the epithelial defect. Addition of lubrication with erythromycin ointment every 2 hours and cautious fluorometholone three times daily, added because of corneal neovascularization, did not affect corneal epithelial healing. 18 days after her initial presentation, following instillation of topical anesthetic and before placement of an eyelid speculum, right lower eyelid entropion

* Corresponding author. Department of Ophthalmology, University of California San Francisco 490 Illinois Street, San Francisco, CA, 94158, USA.

E-mail address: Gerami.seitzman@ucsf.edu (G.D. Seitzman).

<https://doi.org/10.1016/j.ajoc.2022.101371>

Received 8 December 2020; Received in revised form 20 January 2022; Accepted 24 January 2022

Available online 29 January 2022

2451-9936/© 2022 Published by Elsevier Inc. This is an open access article under the CC BY-NC-ND license (<http://creativecommons.org/licenses/by-nc-nd/4.0/>).

was noted (Fig. 1c). This likely was not previously recognized due to tight squeezing of her eyelids secondary to photophobia and discomfort. Upon manual eversion of the lower eyelid, it folded back inward to an entropic position after several blinks. The eyelid position was deemed the likely cause of the corneal ulcer and the primary factor limiting corneal re-epithelialization. She was promptly referred to an oculoplastic surgeon, who administered 5 units of botulinum toxin to the pretarsal orbicularis muscle of the right lower eyelid resulting in normalization of the lid position (Fig. 1d). After one week her corneal epithelial defect had markedly improved (Fig. 1e). Two weeks after the botulinum eyelid injection, the corneal epithelial defect completely resolved and the mother reported a comfortable happy baby (Fig. 1f). At last examination five months after botulinum toxin injection the eyelids remained perfectly positioned with clear corneas bilaterally. She has normal visual behaviors, no significant astigmatism on retinoscopy, and is central, steady, and maintained in both eyes with no objection to occlusion of either eye.

3. Discussion

Corneal ulceration in the neonatal period is exceedingly rare.¹ Potential visual sequelae can be severe and include deprivation amblyopia from corneal scarring, refractive amblyopia from induced irregular astigmatism, and corneal perforation with potential loss of the eye. Prompt detection is of paramount importance because early treatment reduces the need for corneal transplantation, which has a high failure risk in infants and may be associated with impaired cognitive development due to repeated general anesthesia.^{2,3} Unfortunately, diagnosis is often delayed due to the difficulty of obtaining a thorough corneal exam in an infant and because typical symptoms of tearing, discharge, and photophobia are often less pronounced than in adults.⁴ The underlying etiologies of corneal infection also differ in this young age group (Table 1).^{4,5}

Congenital entropion is also rare, and can be categorized as involutional, spastic, or cicatricial.⁶ Involutional has been suggested to be the most common, but we feel it is more likely a vicious cycle of traumatic passage through the birth canal initiating spastic overriding of the orbicularis, which causes corneal trauma, promoting further spasticity

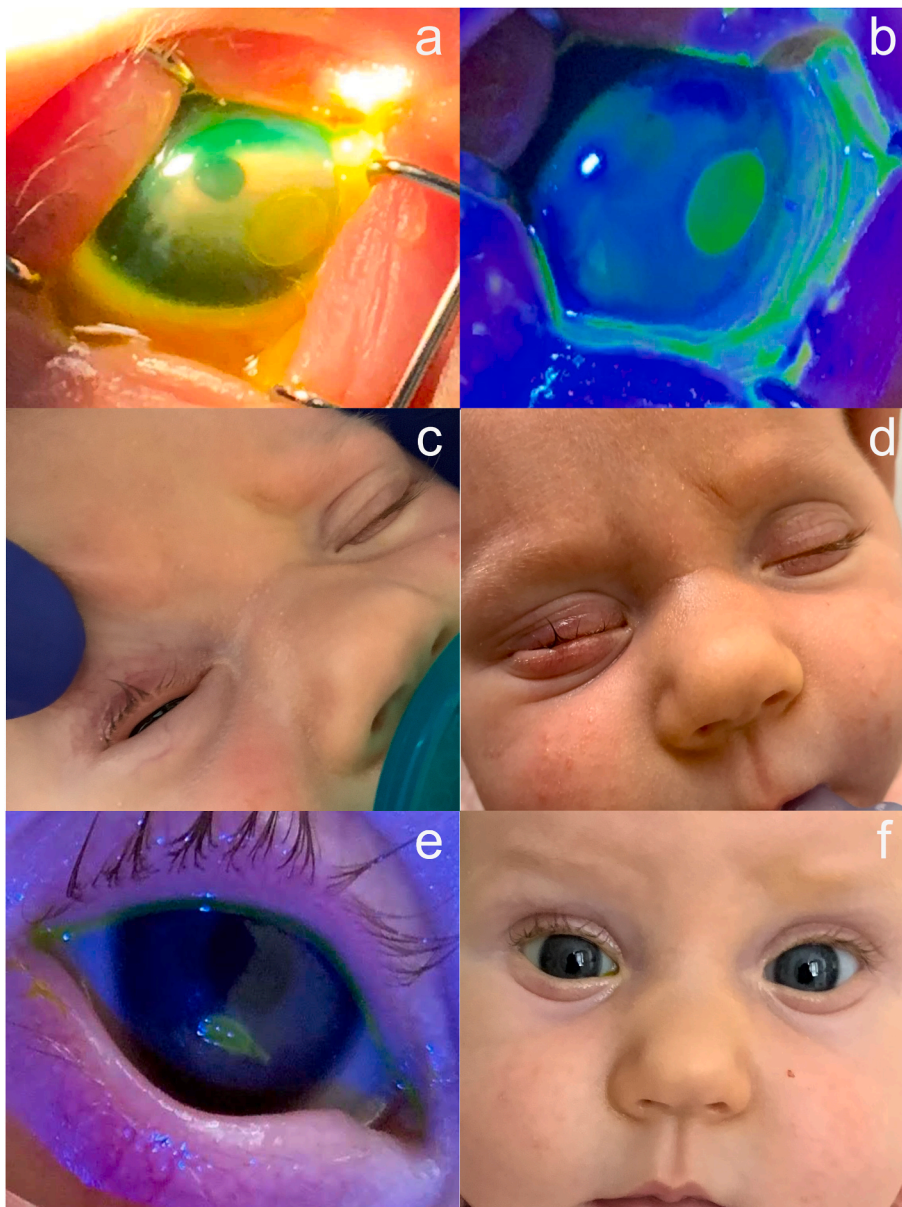


Fig. 1. Serial photography of an infant with congenital entropion and corneal ulcer. At presentation this 3-week-old girl demonstrated an inferior peripheral corneal ulcer in the right eye (a). Frequent application of broad spectrum topical antibiotic therapy resulted in clearing of the stromal infiltrate, but no change in the epithelial defect after two weeks (b). At a subsequent visit entropion of the right lower eyelid was identified (c) after instillation of topical proparacaine. Botulinum toxin was administered to the pretarsal orbicularis muscle, with resolution of entropion (d) and improvement of the corneal epithelial defect (e) after one week. Five months after botulinum toxin injection (f) the eyelid remains in excellent position and the cornea is clear.

Table 1
Etiologies of neonatal corneal ulceration.

Neurotrophic keratopathy
• Following viral infection, particularly herpes simplex
• Congenital anesthesia (familial or sporadic)
Trauma
• Birth canal trauma
• Forceps delivery
• Lid speculum placement during retinopathy of prematurity examinations
Congenital eyelid anomalies
• Entropion
• Eyelid coloboma
• Tarsal kink syndrome
Vertical transmission of virulent pathogens
• Neisseria gonorrhoea
• Herpes simplex virus
• Syphilis
Exposure keratopathy
• Craniosynostosis syndromes or other causes of dysmorphic facial structures
• Severe prematurity with prolonged NICU stay
Keratomalacia
• Severe maternal vitamin A deficiency

with resulting entropion. Management options for involuntional congenital entropion include Quicker-Rathbun sutures, horizontal eyelid tightening, fixation of the eyelid retractors, and botulinum toxin injection.⁷

While rare, several cases of congenital entropion precipitating corneal ulceration have been reported. Luchs et al. described three cases of corneal ulceration secondary to congenital entropion, two with lower eyelid entropion and one with upper eyelid entropion.⁸ Cultures from these ulcers grew *Staphylococcus aureus* in one case, coagulase negative *Staphylococcus* in another, and no growth in the third. In these three cases, as in our case, the entropion was unrecognized at the time of initial examination. All of these corneal ulcers healed rapidly after entropion repair. Yang et al. described one case of a three-week-old boy with corneal ulceration from coagulase negative *Staphylococcus* due to lower eyelid entropion.⁹ The entropion resolved with a Quicker suture, but unfortunately central corneal scarring and secondary amblyopia resulted in permanent limitation of vision. Christiansen et al. described a three-week-old female with unilateral corneal ulceration secondary to involuntional congenital entropion which resolved within 4 days of botulinum toxin injection and remained cured after 7 months.⁷ While botulinum toxin has an estimated duration of action of only 12 weeks, it is our impression that paralysis of the overriding orbicularis allows healing of the corneal epithelium and relief of the spastic stimulus. Thus, in our case the lid position remained normal even after the medication effect waned.

In summary, corneal ulcers are a rare but important cause of vision loss in the neonatal period and can be difficult to diagnose due to their relatively indolent presentation. A thorough history should evaluate the pregnancy, delivery, any preceding trauma, and potential for vertical transmission of infection. Critical components of the examination include bilateral corneal sensation testing and thorough inspection of the ocular adnexa. Entropion is an important potential precipitator of corneal trauma and secondary infection, typically with *Staphylococcus* species, but can be challenging to recognize in a crying child with

eyelids tightly closed. Observation of the eyelid position when the child is at rest, after instillation of topical anesthetic, aids the diagnosis and facilitates prompt intervention to prevent permanent visual impairment.

Patient consent

Consent to publish this case report has been obtained from the patient's parents in writing.

Institution at which the study was conducted

University of California San Francisco.

Funding

This work was made possible in part by NIH-NEI EY002162 - Core Grant for Vision Research and by unrestricted departmental funding from Research to Prevent Blindness.

Authorship

All authors attest that they meet the current ICMJE criteria for Authorship.

Declaration of competing interest

The following authors have no financial disclosures: TR, RK, DA, LH, GS.

Acknowledgements

None.

References

- Lee YS, Tan HY, Yeh LK, et al. Pediatric microbial keratitis in Taiwan: clinical and microbiological profiles, 1998-2002 versus 2008-2012. *Am J Ophthalmol.* 2014;157(5):1090-1096. <https://doi.org/10.1016/j.ajo.2014.01.013>. e1.
- Yang LLH, Lambert SR, Drews-Botsch C, Stulting RD. Long-term visual outcome of penetrating keratoplasty in infants and children with Peters anomaly. *J AAPOS.* 2009;13(2):175-180. <https://doi.org/10.1016/j.jaapos.2008.10.007>.
- Schneuer FJ, Bentley JP, Davidson AJ, et al. The impact of general anesthesia on child development and school performance: a population-based study. *Paediatr Anaesth.* 2018;28(6):528-536. <https://doi.org/10.1111/pan.13390>.
- Chaurasia S, Ramappa M, Ashar J, Sharma S. Neonatal infectious keratitis. *Cornea.* 2014;33(7):673-676. <https://doi.org/10.1097/ICO.000000000000138>.
- Moein HR, Saeed HN, Jacobs DS, et al. Exposure, entropion, and bilateral corneal ulceration in a newborn as a manifestation of chromosome 22 q11.2 duplication syndrome. *Am J Ophthalmol Case Reports.* 2019;13(October 2018):16-19. <https://doi.org/10.1016/j.ajoc.2018.11.001>.
- Maman DY, Taub PJ. Congenital entropion. *Ann Plast Surg.* 2011;66(4):351-353. <https://doi.org/10.1097/SAP.0b013e3181e56e69>.
- Christiansen G, Mohny BG, Baratz KH, Bradley EA. Botulinum toxin for the treatment of congenital entropion. *Am J Ophthalmol.* 2004;138(1):153-155. <https://doi.org/10.1016/j.ajo.2004.02.023>.
- Luchs JI, Laibson PR, Stefanyshyn MA, et al. Infantile ulcerative keratitis secondary to congenital entropion. *Cornea.* 1997;16(1):32-34.
- Yang LLH, Lambert SR, Chapman J, Stulting RD. Congenital entropion and congenital corneal ulcer. *Am J Ophthalmol.* 1996;121(3):329-331. [https://doi.org/10.1016/S0002-9394\(14\)70288-0](https://doi.org/10.1016/S0002-9394(14)70288-0).