

# Clinical value of perilesional perfusion deficit measured by Technetium-99m-ECD single-photon emission computed tomography in hypertensive intracerebral hemorrhage

## ABSTRACT

Pathological and experimental studies indicate the existence of a “penumbra” of progressive tissue damage and edema in regions immediately surrounding a hematoma in patients of intracerebral hemorrhage (ICH). This zone of oligemia surrounding ICH has a potential for perfusion recovery. Improved understanding of the pathophysiology of perilesional blood flow changes and brain injury after ICH may result in improved treatment strategies. The aim was to study perilesional blood flow changes in ICH by perfusion deficit (PD) measured by single-photon emission computed tomography (SPECT) and to correlate it with the severity of ICH and outcome. Forty-four patients of computed tomography (CT) documented nonlobar deep ICH suggestive of hypertensive hematoma of <7 days duration were subjected to <sup>99m</sup>Tc-ethylene diacetate SPECT scans of the brain. Patients with significant midline shift (0.5 cm) or global blood flow reduction were excluded from the analysis. SPECT scan of the brain was analyzed by segmental analysis, a semi-quantitative method of cerebral blood flow. A difference of radiotracer uptake of >10% between the region of interest of ICH cases and the ratio between the two ROI below 0.9 was taken as a significant PD. A correlation of PD was analyzed with that of various parameters such as the severity of stroke, duration from onset of ictus, and imaging including CT scan of the brain and SPECT scan. A statistically significant difference in the percentage of radiotracer uptake on comparison of ipsilateral and contralateral to ICH ( $P < 0.001$ ) was observed, suggesting a significant hypoperfusion in the perilesional area in patients with ICH. A statistically significant correlation was noted between the severity of stroke and PD indicated by various parameters such as the National Institutes of Health Stroke Scale (NIHSS) score at admission ( $r = 0.328$ ,  $P = 0.016$ ), Glasgow Coma Scale (GCS) score at admission ( $r = 0.388$ ,  $P = 0.005$ ), and ICH score at admission ( $r = 0.314$ ,  $P = 0.020$ ). This study demonstrated more severe hypoperfusion in clinically severe ICH which is a possible explanation of poor outcomes in severe ICH cases. We observed hypoperfusion on SPECT study in 25 of 34 (73.5%) patients with subacute ICH and 5 of 10 patients (50%) with acute ICH. The mean time from the onset of ictus to SPECT scan done was  $5.04 \pm 1.75$  days with a range of 1–7 days, suggesting the persistence of hypoperfusion in subacute stages too. This finding may be of clinical importance for identifying the salvageable area surrounding ICH for any possible intervention in future to improve the outcome. This study demonstrates that perilesional PD occurs in acute and subacute cases of ICH. This hypoperfusion is possibly time related and appears to be more severe in patients having major ICH with poor clinical and imaging parameters. This area of hypoperfusion or ischemic penumbra is a potential site for perfusion recovery to improve clinical outcomes and to reduce long-term neurological deficits.

**Keywords:** Cerebral blood flow, intracerebral hemorrhage, ischemic penumbra, perilesional perfusion deficit, single-photon emission tomography, stroke

## INTRODUCTION

Stroke is the second leading cause of death and one of the leading causes of disability. Intracerebral hemorrhage (ICH) is the second most common subtype of the stroke, accounting for approximately 10%–20% of all cases of strokes,<sup>[1]</sup> with hypertension being the most common risk factor. ICH is associated with higher mortality and morbidity than any other stroke subtypes.<sup>[2,3]</sup> Patients of ICH deteriorate

**MAYUR DEEPAK THAKKAR, ABDUL QAVI, AJAI KUMAR SINGH, PRADEEP KUMAR MAURYA, DINKAR KULSHRESHTHA, ANUP KUMAR THACKER, SATYAWATI DESWAL**

Department of Neurology, Dr. Ram Manohar Lohia Institute of Medical Sciences, Lucknow, Uttar Pradesh, India

**Address for correspondence:** Dr. Abdul Qavi, Department of Neurology, Dr. Ram Manohar Lohia Institute of Medical Sciences, Gomti Nagar, Lucknow - 223 006, Uttar Pradesh, India.  
E-mail: drqavi2008@gmail.com

**Submission:** 18-Oct-19, **Accepted:** 29-Jan-20, **Published:** 11-Jul-20

This is an open access journal, and articles are distributed under the terms of the Creative Commons Attribution-NonCommercial-ShareAlike 4.0 License, which allows others to remix, tweak, and build upon the work non-commercially, as long as appropriate credit is given and the new creations are licensed under the identical terms.

**For reprints contact:** WKHLRPMedknow\_reprints@wolterskluwer.com

**How to cite this article:** Thakkar MD, Qavi A, Singh AK, Maurya PK, Kulshreshtha D, Thacker AK, *et al.* Clinical value of perilesional perfusion deficit measured by Technetium-99m-ECD single-photon emission computed tomography in hypertensive intracerebral hemorrhage. *World J Nucl Med* 2020;19:246-54.

### Access this article online

#### Website:

www.wjnm.org

#### DOI:

10.4103/wjnm.WJNM\_76\_19

#### Quick Response Code



raised intracranial pressure, brainstem compression, and herniation or late due to secondary complications.<sup>[4]</sup> Despite all the advances, no effective treatment has been shown to improve the outcome in ICH and available treatment is generally supportive. Several randomized trials based on therapies aimed at reducing intracranial pressure and/or surgical evacuation of hematoma failed to show the desired outcome.<sup>[5]</sup> On the other hand, acute management of ischemic stroke and subarachnoid hemorrhage, based either on pharmacological or interventional therapies, is showing promising results due to a better understanding of underlying pathophysiology and mechanism of tissue injury.

Various animal models have shown the poor outcome of ICH secondary to cerebral ischemia of tissue surrounding intracerebral hematoma.<sup>[6-10]</sup> The concept of “a zone of cerebral oligemia” or “penumbra” that develops and progresses, followed by edema formation around hematoma, is pathologically and experimentally stated.<sup>[6-10]</sup> This form of secondary injury around hematoma occurs due to factors such as mechanical injury due to raised local tissue pressures,<sup>[6]</sup> reduced cerebral blood flow (CBF),<sup>[10]</sup> neuronal cell death, apoptosis, and local inflammation with oxidative stress due to blood-derived factors and iron released during hemorrhage,<sup>[5]</sup> simultaneously potentiating immune activation.<sup>[7-9]</sup> This process occurs during the first few hours (<6 h) from the onset of the hemorrhage. Secretion of cytokines, chemokines, activation of the complement cascade, and the release of matrix metalloproteinases causing blood–brain barrier disruption with the recruitment of leucocytes contribute to secondary injury in the perihematomal region.<sup>[8,9]</sup> Several studies have demonstrated such secondary injury in the perihematomal region associated with hypoperfusion in that region.<sup>[10]</sup> Improved understanding of the pathophysiology and brain tissue injury surrounding hematoma may help in finding out improved treatment modalities. The demonstration of perihematomal hypoperfusion in humans has been done using single-photon emission computed tomography (SPECT)<sup>[11,12]</sup> and positron-emission tomography<sup>[13]</sup> both during the early and late phases of ICH. The present study aimed to document any perilesional blood flow changes in acute to subacute cases of ICH and correlate of perilesional blood flow changes if any with various factors such as the severity of ICH, disability, and effect of the passage of time from the onset of ICH to the performance of perfusion study.

## MATERIALS AND METHODS

The present observational study was conducted in the Department of Neurology, in collaboration with the Department of Nuclear Medicine at Dr. Ram Manohar

Lohia Institute of Medical Sciences, Lucknow, India. The ethical approval was obtained from the Institutional Ethics Committee (IEC). IEC reviewed the article (IEC no. 1/15) and approved it vide letter no. 40/Re Cell/RMLIMS/2015. Written informed consent was obtained from all the cases or from their legal guardians regarding the study, their participation, regarding publication, and the use of study data for research purposes. Patients admitted in the Neurology Department from June 2015 to June 2016 were enrolled in the study.

### Inclusion criteria

All the patients of nontraumatic ICH admitted within 7 days of onset of the ictus were screened and assessed for the study. The patients satisfying the inclusion criteria were included in the study.

### Exclusion criteria

1. Deep coma (Glasgow Coma Scale score of  $\leq 5$ )
2. History of cerebral infarction or any evidence of silent infarction on computed tomography (CT) scan of the brain
3. Hemorrhage related to tumor, trauma, coagulopathy, or arteriovenous malformation
4. Pregnancy
5. Age <20 years
6. CT scan of the brain showing midline shift (>5 mm)
7. Patients with multi-organ failure.

### Patient evaluation

Of 168 patients admitted with nonlobar deep ICH, 44 patients satisfying the inclusion and exclusion criteria were enrolled in the study. Demographic information, past medical history, blood pressure, and medications received were recorded on admission and a detailed clinical evaluation was performed at admission. The severity of enrolled ICH patients was done by applying various scoring systems, i.e., Glasgow Coma Scale (GCS), National Institutes of Health Stroke Scale (NIHSS), and ICH score. These scores were reassessed again at discharge. Routine hemogram and metabolic profile were measured to avoid confounding factors. SPECT scan of the brain was performed in all enrolled patients in the department of nuclear medicine within 7 days of the onset of the ictus.

### Imaging protocol and acquisition

The study protocol included CT scan of the brain and <sup>99m</sup>Tc-Labelled Ethylene Dicycysteine Diethyl Ester (<sup>99m</sup>Tc-ECD) <sup>[14]</sup> SPECT scans of the brain performed in rapid succession for the patients presenting within 7 days of the event.

In all cases, the CT scan of the brain was obtained initially to confirm nonlobar deep ICH. Hematoma volume was calculated on CT scan of the brain by bedside ABC/2 ("A" is the

greatest hemorrhage diameter by CT, "B" is the diameter 90 degree to A, and "C" is the approximate number of CT slices with hemorrhage multiplied by slice thickness) method of calculation.<sup>[15]</sup> ICH volume helped in calculating the ICH score that allows risk stratification on presentation with ICH.<sup>[16,17]</sup> Grading of perilesional edema was done on CT scan of the brain blinded to other data by radiologists as 1, 2, and 3 by noting the extent of perilesional hypodensity, presence of midline shift, and mass effect. Intraventricular extension of hematoma was looked for in all the patients on CT scan of the brain. CT imaging was performed again on a 16-slice CT scanner from the same machine, in which SPECT scan was done later with 5-mm slices oriented parallel to the orbitomeatal line.

SPECT imaging was performed using Discovery NMCT670 dual-head rotating camera equipped with an ultra-high-resolution parallel hole collimator with image data processed by a GE Xcelris 3 workstation image processing software. The SPECT images were acquired 1–2 h after intravenous injection of 20–25 mCi of <sup>99m</sup>Tc-ECD with the patient at quiet rest.

#### Analysis of single-photon emission computed tomography and computed tomography scan of the head

SPECT scan of the brain was analyzed by segmental analysis method, a semi-quantitative analysis of CBF using transverse slices created by brain SPECT. The segmental analysis was configured via customization to run in the "CBF and cerebellum mode." This mode provides CBF analysis of cortex, temporal, and basal ganglia regions of interest (ROIs) compared to the cerebellum.

The processing flow consisted of defining two regions on the temporal frame, four ROIs on the basal ganglia, two ROIs on the cerebellum, and up to four transverse slices divided into 16 cortex segments. Statistics of different regions was displayed in a continuous color scale.

Two ROIs were drawn to encompass the left and right cerebellum. The ROI type elliptical was determined by the initial ROI method, cerebellum parameter set via customization. If the process temporal frame flag was set via customization, a transverse slice that best shows the temporal lobe was selected. Then, two ROIs were drawn in such a manner that they encompass the left and right temporal lobes. The ROI type elliptical was determined by the initial ROI method, temporal parameter set via customization. If the process basal ganglia flag was set via customization, then transverse slice which best shows basal ganglia was selected. An enlarged image of that slice appeared at mid-right of the screen is overlaid by four circular ROIs. The

size and position of ROIs were adjusted to encompass the four basal ganglia.

The statistics of percentage of radiotracer uptake in comparison to the cerebellum was displayed on the screen. It displayed values in percentage of radiotracer uptake, under subheadings of right (R) and left (L) corresponding to the right and left hemispheres. The right/left ratio was displayed adjacent to each segment value of radiotracer uptake. The percentage radiotracer uptake adjacent to the perilesional area was marked as ROI for further analysis.

All parameters of SPECT scan were interpreted, considering the lesion side of the hemisphere as ipsilateral and hemisphere opposite to it as contralateral. The contralateral hemisphere was taken as a control or hemisphere with normal standard perfusion. Percentage of radiotracer uptake was a measure of the cerebral perfusion. The difference in percentage radiotracer uptake in the region of marked ROI (perilesional area of interest) on the ipsilateral cerebral hemisphere and its corresponding region on the contralateral cerebral hemisphere was measured. This was taken to avoid confounding of the widespread and remote CBF changes that is diaschisis.<sup>[12,18]</sup> A difference in uptake of  $\geq 10\%$  between the contralateral and ipsilateral was considered significant as decreased radiotracer uptake in the perilesional area suggestive of cerebral hypoperfusion.<sup>[11,16]</sup> The value of perfusion deficit (PD) was arbitrarily graded as Grade 0 (PD  $\leq 10$ ), Grade 1 (PD of 10–19), and Grade 2 ( $\geq 20$ ). Grade 1 and Grade 2 were assumed to be indicators of significant cerebral hypoperfusion. The ratio of ipsilateral-to-contralateral (I/C) radiotracer uptake was also calculated. The ratio of  $< 0.9$  was considered to be a significant indicator of cerebral hypoperfusion.<sup>[11]</sup> All the clinical and imaging parameters were compared with PD to observe any correlation.

#### Statistical analysis

Statistical analysis was done using SPSS version 16.0 version (Chicago, Inc., IL, USA). The results are presented as mean  $\pm$  standard deviation and percentages. The Chi-square test was used to compare the categorical variables. The unpaired *t*-test was used to compare discrete variables. The mean values for normally distributed data were compared using paired and unpaired two-tailed *t*-tests. Associations between normally distributed continuous variables were tested using Pearson's correlation coefficients. Values were considered to be significant at  $P < 0.05$ .

Regression analysis was done for all the parameters showing correlation using Pearson's correlation. Beta coefficient value with a 95% confidence interval was obtained showing the strength of association for all the parameters that were showing the significant correlation.

## RESULTS

In our study, 44 patients of nonlobar deep hypertensive ICH were included and analyzed for CBF changes. The baseline demographic and clinical profile of patients included in the study is shown in Table 1. Major clinical presentation of the patients was hemiparesis (100%), while other symptoms such as altered sensorium, giddiness, and headache were present in 14 patients (31.8%). Twenty-seven patients (61.4%) had a past history of hypertension, while the remaining 17 patients (38.63%) were diagnosed as *de novo* hypertension at admission. Thirty-two patients (72.7%) had putaminal ICH, while 12 patients (27.3%) had a thalamic bleed.

**Table 1: Demography and clinical parameters (n=44)**

Parameters	Proportions
Age (range)	58.09±12.05 (24-80)
Gender	
Male	59.1
Female	40.9
MAP (range)	123.14±11.39 (107-157)
GCS score admission (range)	13.06±2.36 (7-15)
NIHSS score admission (range)	10.88±5.23 (1-19)
ICH score admission (range)	0.81±0.84 (0-3)
ICH location, n (%)	
Putamen	32 (72.7)
Thalamic	12 (27.3)
Intraventricular extension	16 (36.4)

MAP: Mean arterial pressure; GCS: Glasgow Coma Scale; NIHSS: National Institutes of Health Stroke Scale; ICH: Intracerebral haemorrhage

**Table 2: Data of computed tomography scan and single-photon emission computed tomography scan of the brain (n=44)**

Parameters	Proportions
Time to CT scan brain (h)	20.97±30.99
ICH volume on CT scan of the brain (cc)	20.36±18.41
Time to SPECT scan of the brain (days)	5.04±1.75
Radiotracer uptake	
Ipsilateral	109.11±22.22
Contralateral	134.32±58.07
I/C ratio	0.86±0.07
I/C ratio of <0.9 (decreased perfusion in lesional hemisphere) (%)	63.6
Perfusion defect	15.84±8.18
Perfusion defect of >10 (significant PD in lesional hemisphere) (%)	68.2

CT: Computed tomography; SPECT: Single-photon emission CT; ICH: Intracerebral hemorrhage; PD: Perfusion deficit; I/C: Ipsilateral/contralateral

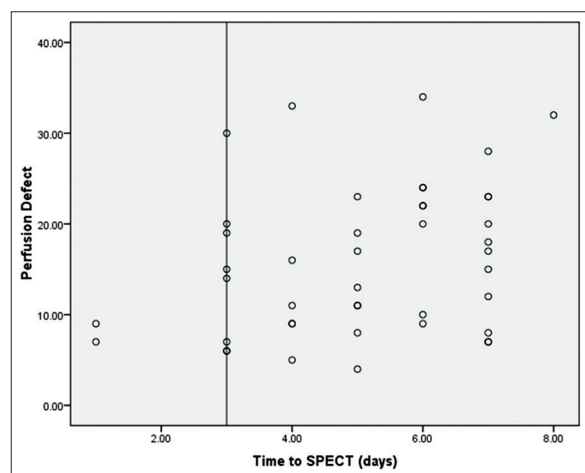
Imaging data of CT scan of the brain and SPECT scan of the brain are shown in Table 2. The mean duration for getting CT scan of the brain done from the onset of the ictus was 20.97 ± 30.99 h, minimum being 1 h and maximum being 144 h (6 days). The mean ICH volume as calculated by the standard method (ABC/2 method) was 20.36 ± 18.41 cm<sup>3</sup> with a range of 3–60 cm<sup>3</sup>. Forty-two patients had perilesional edema as assessed on CT scan of the brain. The time interval of CT scan of the brain from the onset of ictus was compared with a grade of edema; it did not show any statistical significance with *P* value of 0.82. Sixteen patients (36.4%) had an intraventricular hemorrhage on CT scan of the brain. The mean time from the onset of ictus to SPECT scans brain was 5.04 ± 1.75 days. Ten patients (22.3%) got their SPECT scan of the brain done within 3 days of onset of symptoms, rest 34 (77.3%) patients after 3 days of onset of symptoms due to unstable general condition. The mean radiotracer uptake in percentage in hemisphere where bleed has occurred, i.e., ipsilateral side, was 109.11 ± 22.22, whereas in the contralateral hemisphere was 134.32 ± 58.07. A comparison between the radiotracer uptakes on both sides of hemispheres was found to be statistically significant with *P* < 0.01. The mean ratio of I/C hemisphere radiotracer uptake was 0.86 ± 0.07; however, 28 patients (63.6%) had I/C ratio of <0.9, suggesting decreased perfusion in the lesional hemisphere. The mean PD in our study was 15.84 ± 8.18. PD of >10 was considered as significantly decreased perfusion in the ipsilateral hemisphere. Thirty patients (68.2%) had PD of >10%.

PD was compared with various parameters to find any significant association using Spearman's correlation coefficient, as seen in Table 3. It showed significant correlation with time to SPECT scan from the onset of ictus (*P* = 0.024), GCS score at admission (*P* = 0.005), NIHSS score at admission (*P* = 0.01), and ICH score at admission (*P* = 0.02), suggesting its direct correlation with the severity of stroke, i.e., more severe the stroke clinically, more is the PD. However, the strength of correlation was significant between the times to SPECT scan of the brain to the onset of ictus, with a beta coefficient of 1.079. Figure 1 clearly shows the relation of time to SPECT scan brain with PD, as the time to SPECT scan brain increases, the PD also increases Figure 2: (a) explains the SPECT study report of a 65 yrs old lady. She was newly detected hypertensive and had developed left putaminal bleed with NIHSS score of 19, intra cerebral hemorrhage score of 2, intra cerebral hemorrhage volume (60 cc) having Grade 3 perilesional edema on computed tomography scan brain and perfusion deficit of 23%. Single-photon emission computed tomography study image zoomed of the same patient can be seen in. (b) where segment 9 when compared to segment 4 shows a difference in radiotracer uptake of 23%.

**Table 3: Correlation and regression analysis of various parameters with perfusion deficit**

Parameters	Mean±SD	Pearson's correlation coefficient	P	Beta coefficient	P	Confidence interval	
						Upper bound	Lower bound
Age	58.09±12.05	-0.243	0.045	-0.070	0.374	-0.229	0.089
MAP	123.14±11.39	-0.087	0.289	-0.299	0.353	-0.950	0.351
SBP	168.60±15.30	0.033	0.417	0.087	0.464	-0.153	0.321
DBP	100.84±10.35	-0.188	0.114	0.158	0.532	-0.355	0.672
Hospital stay	12.06±4.84	0.205	0.094	0.281	0.248	-0.207	0.770
GCS score at admission	13.06±2.36	-0.388	0.005	-0.646	0.451	-2.379	1.087
GCS score at discharge	13.86±1.76	-0.267	0.042	0.488	0.680	-1.916	2.893
NIHSS score at admission	10.88±5.23	0.328	0.016	0.098	0.810	-0.732	0.929
NIHSS score at discharge	8.09±4.59	0.353	0.010	0.153	0.753	-0.833	1.139
ICH score at admission	0.81±0.85	0.314	0.020	1.133	0.706	-4.972	7.237
ICH score at discharge	0.72±0.82	0.213	0.085	-2.231	0.506	-9.018	4.557
Time to CT scan	20.97±30.99	0.191	0.110	-0.005	0.863	-0.061	0.052
ICH volume	20.36±18.41	0.249	0.054	-0.029	0.641	-0.156	0.098
Time to SPECT	5.04±1.75	0.302	0.024	1.079	0.049	-0.19	2.178
I/C ratio	0.86±0.07	-0.861	0.0001	-83.943	0.001	-109.846	-58.039

MAP: Mean arterial pressure; SBP: Systolic blood pressure; DBP: Diastolic blood pressure; GCS: Glasgow Coma Scale; NIHSS: National Institutes of Health Stroke Scale; ICH: Intracerebral haemorrhage; CT: Computed tomography; SPECT: Single-photon emission CT; SD: Standard deviation; I/C: Ipsilateral/contralateral



**Figure 1: Scatter plot of time to single-photon emission computed tomography scan of the brain from symptom onset to perfusion deficit**

## DISCUSSION

ICH is often the lethal form of stroke carrying high mortality (30%–55%) and morbidity.<sup>[19]</sup> This poor outcome in ICH is due to lack of any specific treatment, in contrast to ischemic stroke where newer treatment modalities are emerging day by day with improvement in the overall outcome.<sup>[5]</sup> Attention has been drawn recently to the perilesional brain injury in ICH similar to that of penumbra in ischemic stroke as a potential target for therapy. The present study aimed to show the presence of perihematoma hypoperfusion – a zone of ischemia surrounding ICH. Several experimental and pathological studies have indicated that a region does exist immediately surrounding the hematoma where the progressive tissue damage and edema develop,<sup>[6-8]</sup> with secondary neuronal injury.<sup>[9,10]</sup> Kingman *et al.*<sup>[20]</sup>

demonstrated hypoperfusion around a balloon placed in the caudate nucleus of rats, demonstrating reduced CBF. However, whether clinical and neurological deterioration noted in one-third of ICH patients is a direct consequence of this process or indirect consequence of hematoma expansion or cerebral herniation is still debated.<sup>[21]</sup>

### Zone of hypoperfusion around intracerebral hemorrhage

In our study, we observed the presence of perilesional hypoperfusion on <sup>99m</sup>Tc-Ethylene Diacetate (ECD) SPECT scans of the brain. It has been observed that <sup>99m</sup>Tc-Ethylene Diacetate (ECD) in SPECT is more useful in the assessment of regional CBF<sup>[14]</sup> than <sup>99m</sup>Tc-HMPAO (99mTc-Labelled Hexa Methyl Propylene Amine Oxime) used in earlier studies. SPECT scan of the brain was analyzed by segmental analysis method, a semi-quantitative analysis of CBF using transverse slices created by brain SPECT.

We found a significant statistical difference in the percentage radiotracer uptake on comparison of I/C marked ROI ( $P < 0.001$ ), suggesting a significant hypoperfusion in the perilesional area in patients with ICH. Hypoperfusion in ICH has also been described by Cynthia Sills *et al.*<sup>[11]</sup> where 20% reduction in counts on SPECT scan of the brain was established by phantom study measurements. They observed the existence of hypoperfusion around hematoma between 28 and 63 h from the ICH. Similar reductions of CBF for 3 h in white matter and cortex adjacent to a hematoma injected into the caudate of monkeys have been suggested.<sup>[10]</sup> Jenkins *et al.*<sup>[8]</sup> found that CBF reductions were proportional to the size of the clot and greater when the clot did not rupture out of the parenchyma and were greater after injections of blood

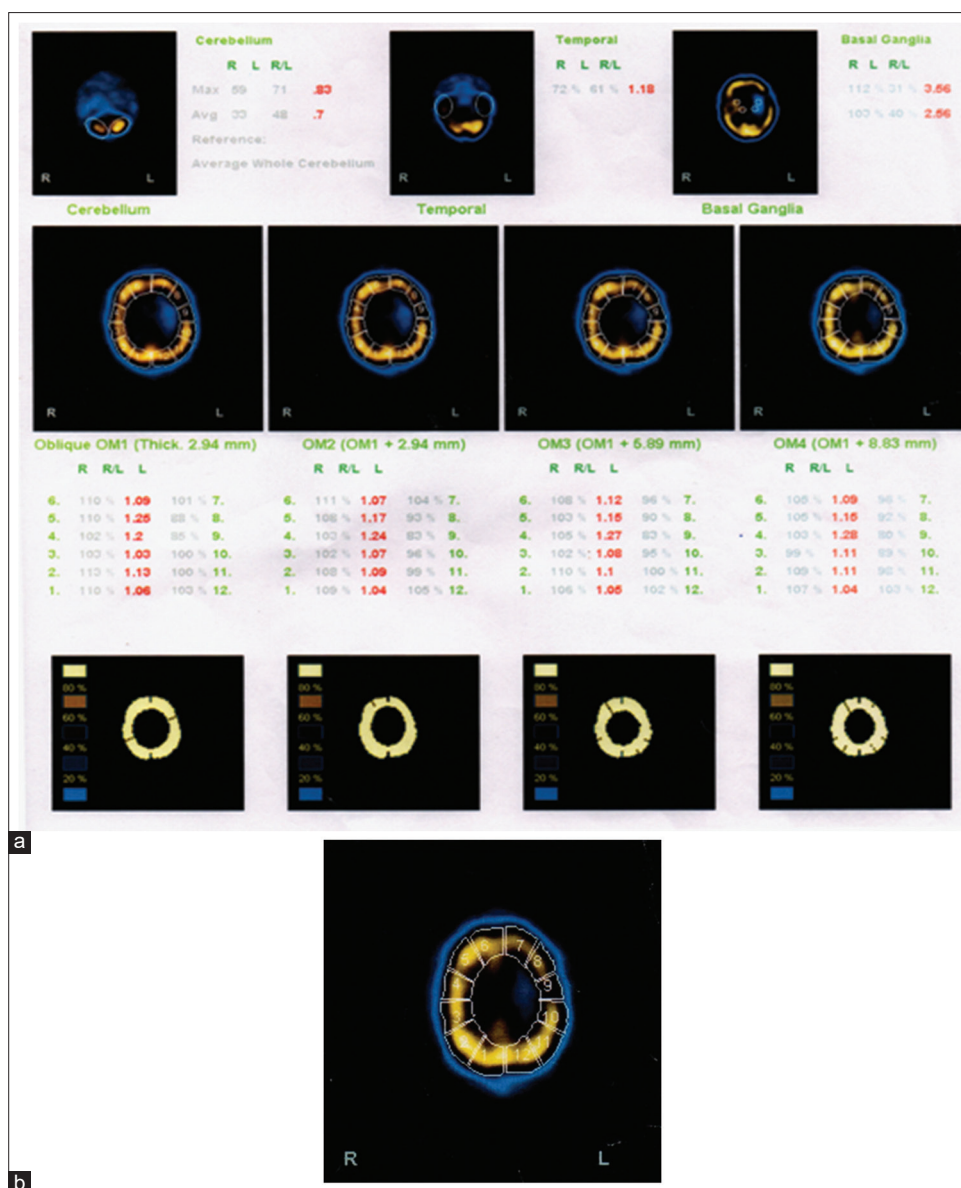


Figure 2: (a) explains the SPECT study report of a 65 yrs old lady. She was newly detected hypertensive and had developed left putaminal bleed with NIHSS score of 19, intra cerebral hemorrhage score of 2, intra cerebral hemorrhage volume (60 cc) having Grade 3 perilesional edema on computed tomography scan brain and perfusion deficit of 23%. Single-photon emission computed tomography study image zoomed of the same patient can be seen in. (b) where segment 9 when compared to segment 4 shows a difference in radiotracer uptake of 23%

compared with saline, oil, cerebrospinal fluid, or balloon inflation.<sup>[10]</sup> Rousseaux *et al.* analyzed the cerebral distribution of HMPAO by visual analysis of asymmetry index (AI) and they found consistent finding of reduced radiotracer activity and abnormal AI<sup>[12]</sup> on sequential studies done at 60, 150, and 300 min with a remarkably stable pattern.

### Relation of hypoperfusion with time to single-photon emission computed tomography

We observed hypoperfusion on SPECT study in 25 of 34 (73.5%) patients when the SPECT study was conducted between 3 and 7 days of the ictus, while it was noted in 5 of 10 patients (50%) when the SPECT study was carried

out within 72 h of the ictus. The time to SPECT scan of the brain among our study population was  $5.04 \pm 1.75$  days with a range of 1–7 days. It showed a statistically significant positive correlation with PD ( $r = 0.302, P = 0.020$ ) and I/C ratio ( $0.86 \pm 0.07$ ) ( $r = -0.861, P = 0.001$ ). This strength of association in our study was statistically significant (beta coefficient =  $1.079, P = 0.04$ ) for time to SPECT scan of the brain from the onset of ictus. These findings are contradictory to that observed by Mayer *et al.* who found that there is a decrease in perfusion defect from acute to subacute stages of ICH, but the study done by Siddique *et al.*<sup>[22]</sup> showed that this hypoperfusion present till the chronic phase along with some area of reperfusion around ICH and this area

was described by them as the area of ischemic penumbra around ICH. Mayer *et al.* also identified delayed cortical hyperemia in 4 of the 23 patients studied, including all three patients with lobar hemorrhage. These regions corresponded topographically to the normal-appearing brain on concurrent CT scans which suggest that this phenomenon is not a direct cause of edema formation after ICH. Such cortical hyperemia was not observed in our study possibly due to delay in SPECT study (34 patients scans were done after 72 h). Mayer *et al.* measured perilesional blood flow by a paired consecutive CT scans and SPECT scans during acute (mean 18 h) and subacute (mean 72 h) phases of ICH on SPECT scan-derived flow deficit volume (FDV) around hematoma and noted it maximum in acute phase but persisting though a lesser degree in the subacute phase also. Siddique *et al.* demonstrated reversible perilesional ischemic changes around supratentorial ICH by measuring CBF using  $^{99m}\text{Tc}$ -HMPAO SPECT in an acute stage that is on the day of ictus and at the second SPECT study in the chronic stage of ICH (6–9 months after ictus). They observed that all patients showed at least 15% improvement in tracer uptake or perfusion in late stages, suggesting the presence of hypoperfused area around ICH that exists till late stages too which reperfuses with time. The mean volume of the brain with 15% or more improvement in perfusion between two SPECT studies (acute and late study) was  $34 \text{ cm}^3$  (median  $(33.7 \text{ cm}^3, \text{ range } 7.2\text{--}71.3)$ ) in this study. These volumes represent under the perfused area of the brain in early-stage SPECT study suggesting a zone of penumbra around ICH that improved with time supporting the hypothesis of a reversible zone of ischemia in early stages of ICH that can be salvaged with early intervention. Many researchers have shown that regional CBF changes continue to occur for weeks following an ICH, as seen in our study. Siddique *et al.* showed that the zone of ischemic penumbra exists even late stages though it fades with time, which supports our observation of persistent PD in subacute cases and it possibly be explained by certain factors such as distortion of the brain with hematoma, extension of hematoma, progressive edema surrounding, clinico-radiological severity of the stroke cases, and possibility of remote CBF effects from the lesion. Another explanation to this could be delayed acquisition of SPECT scan in our patients due to unstable general condition in majority of the patients at the time of admission (mean time to perform SPECT from the onset of ictus was  $5.04 \pm 1.75$  days because SPECT scan of 34 patients of 44 was done in subacute stages only). Mayer *et al.* validated their findings of SPECT analysis by establishing calculated FDV independent of ROI shape or size; the main disadvantage of this technique has been a relative index of perfusion rather than direct measurement of CBF. However, their accuracy

can be approximated if the disease process does not affect the perfusion in the contralateral hemisphere and the disease process does not distort the anatomy of the brain. A further theoretical limitation may be an error introduced by Compton scatter and partial volume effect substantially in smaller lesions. These issues were addressed by the exclusion of patients with significant midline shift or those having intraventricular hemorrhage resulting in mild-to-severe global reduction of cerebral perfusion. In our study too, we excluded those patients who had a midline shift of more than 5 mm. However, patients with intraventricular hemorrhage were not excluded to correlate with the ICH score. The topography and timing of perihematoma reperfusion observed in our study suggest that normalization of regional blood flow occurs in regions previously affected by this hemorrhage-induced inflammatory response as studied by Meyer *et al.* Reperfusion of injured tissue in this fashion may contribute substantially to the formation of edema and suggests a possible role for neuroprotective therapy targeted either at the initial inflammatory response or at biochemical events associated with reperfusion injury.<sup>[23]</sup>

#### Correlation of hypoperfusion with clinico-radiological parameters

On the correlation of hypoperfusion with clinical parameters, we found a higher degree of hypoperfusion with more severe ICH. Thus, a statistically significant correlation was noted between the severity of stroke as assessed by NIHSS score at admission ( $10.88 \pm 5.23$ ) with PD ( $r = 0.328, P = 0.016$ ). Similarly, a negative correlation between GCS score at admission ( $13.06 \pm 2.36$ ) and PD ( $r = -0.388, P = 0.005$ ) and ICH score at admission ( $0.81 \pm 0.85$ ) also showed a statistically significant correlation with PD ( $r = 0.314, P = 0.020$ ). A clear link of hypoperfusion to the severity of ICH is thus substantiated in our study. Rousseaux *et al.* observed a significant correlation between the severity of clinical neurological deficit and cortical AI,<sup>[12]</sup> although they did not correlate the above-mentioned clinical parameters.

On imaging studies and correlation of PD, no significant correlation could be observed either with ICH volume or with a grade of edema on CT scan of the brain in our study. Such a correlation with radiological parameters was observed by Mayer *et al.*, who found moderate PD ( $r = -0.36, P = 0.01$ ) with ICH volume. However, certain PET-based studies, as done by Herweh,<sup>[24]</sup> and Zazulia,<sup>[25]</sup> showed reduced perfusion and edema formation surrounding ICH, as stated in our study and previous studies, but these studies failed to demonstrate any initial mismatch between edema around hematoma and PD and could not identify any tissue at risk of ischemia. These studies were based on oxygen extraction fraction

and evaluation of CBF and they concluded diaschisis<sup>[12,18]</sup> or autoregulatory hypoperfusion over ischemia as a probable cause of reduced cerebral perfusion.

### Limitations of our study

Measuring the size of any object in nuclear medicine is difficult due to error from the physics of the system, which includes partial volume averaging, Compton scatter, attenuation, and resolution.

The SPECT scans were being performed at different and wide time intervals (1–7 days); hence, it is difficult to interpret the variations in cerebral perfusion at a given specific time after the ictus. Other confounding factors for reduced perfusion on SPECT studies include diaschisis (deafferentation) and edema (increased interstitial volume), both of which occur in ICH and have shown to exist in various studies.<sup>[12,18]</sup> One of the ways to distinguish among these is to carry out simultaneous studies of tissue energy and perfusion reserve, both of which should be decreased with ischemia. Major limitation of such studies is that SPECT parameters provide only indirect assessment of CBF and thus do not give conclusive evidence in the reduction of CBF.

### CONCLUSION

Therefore to conclude, our study indicates a perilesional area of hypoperfusion in our patients, which is possibly time related and appears to be severe in patients having major ICH on clinical as well as radiological parameters. This study thus supports to the hypothesis of salvable brain tissue surrounding hematoma that lands to ischemic damage with the passage of time and resulting in poor clinical outcomes. Targeting this area of hypoperfusion, which is a potential site for perfusion recovery from initial neuronal insult, we can improve outcomes and can reduce long-term neurological deficit by possible therapeutic intervention in future. A detailed study without these limitations and avoidance of confounding factors, particularly cerebral edema, may provide a definite answer to this question.

### Declaration of patient consent

The authors certify that they have obtained all appropriate patient consent forms. In the form the patient(s) has/have given his/her/their consent for his/her/their images and other clinical information to be reported in the journal. The patients understand that their names and initials will not be published and due efforts will be made to conceal their identity, but anonymity cannot be guaranteed.

### Financial support and sponsorship

Nil.

### Conflicts of interest

There are no conflicts of interest.

### REFERENCES

1. Sacco RL, Mayer SA. Epidemiology of intracerebral hemorrhage. In: Feldmann E, editor. *Intracerebral Hemorrhage*. Mount Kisco, NY: Futura; 1994. p. 3-23.
2. Feigin VL. Stroke in developing countries: Can the epidemic be stopped and outcomes improved? *Lancet Neurol* 2007;6:94-7.
3. An SJ, Kim TJ, Yoon BW. Epidemiology, risk factors, and clinical features of intracerebral hemorrhage: An update. *J Stroke* 2017;19:3-10.
4. Mayer SA, Sacco RL, Shi T, Mohr JP. Neurologic deterioration in noncomatose patients with supratentorial intracerebral hemorrhage. *Neurology* 1994;44:1379-84.
5. Juvela S, Heiskanen O, Poranen A, Valtonen S, Kuurne T, Kaste M, *et al.* The treatment of spontaneous intracerebral hemorrhage. A prospective randomized trial of surgical and conservative treatment. *J Neurosurg* 1989;70:755-8.
6. Yang GY, Betz AL, Chenevert TL, Brunberg JA, Hoff JT. Experimental intracerebral hemorrhage: Relationship between brain edema, blood flow, and blood-brain barrier permeability in rats. *J Neurosurg* 1994;81:93-102.
7. Suzuki J, Ebina T. Sequential changes in tissue surrounding ICH. In: Pia HW, Longmaid C, Zierski J, editors. *Spontaneous Intracerebral Hematomas*. Berlin, Germany: Springer-Verlag; 1980. p. 121-8.
8. Jenkins A, Mendelow AD, Graham DI, Nath FP, Teasdale GM. Experimental intracerebral haematoma: The role of blood constituents in early ischaemia. *Br J Neurosurg* 1990;4:45-51.
9. Askenase MH, Sansing LH. Stages of the inflammatory response in pathology and tissue repair after intracerebral hemorrhage. *Semin Neurol* 2016;36:288-97.
10. Bullock R, Brock-Utne J, van Dellen J, Blake G. Intracerebral hemorrhage in a primate model: Effect on regional cerebral blood flow. *Surg Neurol* 1988;29:101-7.
11. Sills C, Villar-Cordova C, Pasteur W, Ramirez A, Lamki L, Barron B, *et al.* Demonstration of hypoperfusion surrounding intracerebral hematoma in humans. *J Stroke Cerebrovasc Dis* 1996;6:17-24.
12. Rousseaux M, Steinling M, Huglo D, Mazingue A, Barbaste P. Perfusion mapping with Tc-HMPAO in cerebral haematomas. *J Neurol Neurosurg Psychiatry* 1991;54:1040-3.
13. Villar-Cordova C, Krieger D, Mullani N, Grotta JC. Hypometabolism and ischemic penumbra surrounding intracerebral hemorrhage in humans demonstrated by positron emission tomography. *Stroke* 1997;28:254.
14. Garrett K, Villanueva J, Kuperus J, Giombetti R, Mena I. A comparison of regional cerebral blood flow with Xe-133 to SPECT Tc-99m-ECD. *J Nucl Med* 1988;29:913.
15. Kothari RU, Brott T, Broderick JP, Barsan WG, Sauerbeck LR, Zuccarello M, *et al.* The ABCs of measuring intracerebral hemorrhage volumes. *Stroke* 1996;27:1304-5.
16. Mayer SA, Lignelli A, Fink ME, Kessler DB, Thomas CE, Swarup R, *et al.* Perilesional blood flow and edema formation in acute intracerebral hemorrhage: A SPECT study. *Stroke* 1998;29:1791-8.
17. Hemphill JC 3<sup>rd</sup>, Bonovich DC, Besmertis L, Manley GT, Johnston SC. The ICH score: A simple, reliable grading scale for intracerebral hemorrhage. *Stroke* 2001;32:891-7.
18. Ogasawara K, Numagami Y, Kitahara M. Diaschisis in right putaminal hemorrhage: Correlation with motor function. *No Shinkei Geka* 1994;22:1123-9.
19. Marietta M, Pedrazzi P, Girardis M, Torelli G. Intracerebral haemorrhage: An often neglected medical emergency. *Intern Emerg Med* 2007;2:38-45.
20. Kingman TA, Mendelow AD, Graham DI, Teasdale GM. Experimental intracerebral mass: Time-related effects on local cerebral blood flow. *J Neurosurg* 1987;67:732-8.



21. Agnoli A, Fieschi C, Prencipe M, Bozzao L. Relationship between regional hemodynamics in acute cerebrovascular lesions and clinicopathologic aspects. In: Meyer JS, Reivich M, Lechner H, Eichhorn O, editors. *Research on the Cerebral Circulation. Fourth International Salzberg Conference*. Springfield, IL: Charles C. Thomas Co; 1970. P. 148-54.
22. Siddique MS, Fernandes HM, Wooldridge TD, Fenwick JD, Slomka P, Mendelow AD. Reversible ischemia around intracerebral hemorrhage: A single-photon emission computerized tomography study. *J Neurosurg* 2002;96:736-41.
23. Hallenbeck JM, Dutka AJ. Background review and current concepts of reperfusion injury. *Arch Neurol* 1990;47:1245-54.
24. Herweh C, Jüttler E, Schellinger PD, Klotz E, Jenetzky E, Orakcioglu B, *et al.* Evidence against a perihemorrhagic penumbra provided by perfusion computed tomography. *Stroke* 2007;38:2941-7.
25. Zazulia AR, Diringner MN, Videen TO, Adams RE, Yundt K, Aiyagari V, *et al.* Hypoperfusion without ischemia surrounding acute intracerebral hemorrhage. *J Cereb Blood Flow Metab* 2001;21:804-10.