



In vivo demonstration of microvascular thrombosis in severe COVID-19

Douglas Alexandre do Espírito Santo¹ · Anna Cristina Bertoldi Lemos¹ · Carlos Henrique Miranda¹

Accepted: 4 August 2020 / Published online: 13 August 2020
© Springer Science+Business Media, LLC, part of Springer Nature 2020

Abstract

Several autopsy studies showed microthrombi in pulmonary circulation of severe COVID-19 patients. The major limitation of these investigations is that the autopsy provided static information. Some of these alterations could be secondary to the disseminated intravascular coagulation (DIC) observed as the final standard route to the multisystem organ failure exhibited in critically ill patients. We report preliminary results of an *in vivo* evaluation of sublingual microcirculation in thirteen patients with severe COVID-19 requiring mechanical ventilation. We observed multiple filling defects moving within the microvessels indicative of thrombi in most of the cases 11/13 (85%). This is the first imaging documentation of microvascular thrombosis in living severe COVID-19 patients since the beginning of the hospitalization. The clinical relevance of microvascular thrombosis in this disease requires further research.

Keywords COVID-19 · Microvascular thrombosis · Sublingual microcirculation · Coagulopathy

Highlights

- Microthrombi in pulmonary circulation is a common finding in autopsies of severe COVID-19 patients.
- *In vivo* evaluation of sublingual microcirculation of severe COVID-19 patients showed multiple filling defects moving within the microvessels indicative of thrombi in most of the cases.
- This is the first imaging documentation of microvascular thrombosis in living severe COVID-19 patients.
- The clinical relevance of microvascular thrombosis in COVID-19 requires further research.

Introduction

The main clinical presentation of patients with severe coronavirus disease 2019 (COVID-19) is an acute respiratory failure with significant hypoxemia, which ultimately requires mechanical ventilation [1]. In addition to the gas exchange involved, recently published investigations described a high incidence of thrombotic events in these patients [2].

Several autopsy studies demonstrated microthrombi in pulmonary circulation [3–6]. The major limitation of these investigations is that the autopsy provided static information. Some of these alterations could be secondary to the disseminated intravascular coagulation (DIC) observed as the standard route to the multisystem organ failure exhibited in critically ill patients.

To support the importance of microvascular thrombosis in severe COVID-19 pathophysiology, we report preliminary results of an *in vivo* evaluation of sublingual microcirculation allowing the dynamic visualization of these microvessels.

Methods

We included adult patients with SARS-CoV-2 virus infection confirmed through reverse transcriptase polymerase chain reaction (RT-PCR) of nasopharyngeal swabs and

Electronic supplementary material The online version of this article (<https://doi.org/10.1007/s11239-020-02245-x>) contains supplementary material, which is available to authorized users.

✉ Carlos Henrique Miranda
chmiranda@fmrp.usp.br

¹ Division of Emergency Medicine, Department of Internal Medicine, Ribeirão Preto School of Medicine, São Paulo University, Rua Bernardino de Campos, 1000, Ribeirão Preto, SP 14020-670, Brazil

severe clinical presentation with respiratory failure requiring mechanical ventilation. The sublingual microcirculation visualization was performed with the patient in dorsal decubitus and with the headboard raised to 45 degrees. We used the Capiscope HVCS handheld video capillaroscopy system (KK Technology, Honiton, England, UK), and imaging was analyzed using the Glycocheck system (Microvascular health solution, American Fork, UT, USA). Protected with disposable tips and without being pressed, the camera was placed under the tongue in at least five different regions inside the mouth after the patient's admission into the intensive care unit.

The ethical board of our institution approved this investigation. Patients' relatives gave their written informed consent to participate in this research.

Results

We analyzed the imaging of the sublingual microcirculation of thirteen patients on the first day after hospital admission. The demographics, clinical, and laboratory characteristics of these patients are presented in Table 1. All the patients were on mechanical ventilation, and they did not have any evidence of circulatory shock. Six patients (46%) were using a low norepinephrine dose to support sedation and neuromuscular blocking agents, both of them with normal lactate. None of these patients met the criteria for DIC. Despite elevated D-dimer levels, prothrombin time and activated partial thromboplastin time (aPTT) were normal, fibrinogen levels were increased in all patients and mild thrombocytopenia was observed in only two of them.

We observed some evidence of microvascular thrombosis in 11 patients (85%). For comparison, an example of the normal sublingual microcirculation in a healthy individual is presented in Fig. 1a and b. The arrows in Fig. 1c–e illustrate filling defects moving within the microvessels indicative of thrombi, which were found in 11 patients (85%). Four patients (31%) exhibited complete stagnated capillaries. We observed microvessels with the interrupted flow and semi-oval imaging in its distal extremity suggesting acute thromboembolic occlusion (asterisk in Fig. 1f) in 5 patients (38%). An abrupt thromboembolic obstruction of a microvessel was registered during the evaluation in 3 patients (videos in supplementary material).

Discussion

Thrombus in small vessels of the pulmonary circulation is a common finding in autopsies of COVID-19 patients. Dolnikoff et al. [3] observed a variable number of small fibrinous thrombi in small pulmonary arterioles in areas of both

damaged and more preserved lung parenchyma in 8 out of 10 cases in the minimally invasive autopsy. Small fibrinous thrombi were rarely found in the glomeruli and superficial dermal vessels. Ackermann et al. [4] examined seven lungs obtained during the autopsy and found widespread pulmonary vessels' thrombosis. Fox et al. [5] observed the presence of thrombosis and microangiopathy in the lungs' small vessels and capillaries in autopsies of ten African American decedents. Carsana et al. [6] analyzed lung tissue samples of 38 patients, besides the diffuse alveolar damage, they observed fibrin thrombi in small arterial vessels in 87% of cases, around half of which had more involvement than 25% of the lung tissue.

Our investigation demonstrated thrombi in microcirculation since the beginning of the hospitalization and none of these patients had criteria for DIC. This finding reinforces that microvascular thrombosis is a hallmark of the COVID-19.

Another conclusion emphasized by our investigation is that microvascular thrombosis occurs systemically and it could affect different organs. Probably those organs with a high capillary density, such as the lungs, are the most compromised. In the lung, pulmonary microvascular thrombosis could lead to a dead-space effect (ventilated areas, but not perfused), contributing to the critical hypoxemia observed in these cases. However, microvascular thrombosis could compromise other areas such as the kidney, liver, and brain, contributing to multiple organ dysfunction, such as recent descriptions [7]. This mechanism could explain the findings of Tang et al. [8], who in a retrospective study achieved a low 28-day mortality in severe COVID-19 patients with the use of anticoagulant therapy for seven days or more, especially the ones with high sepsis-induced coagulopathy score (≥ 4) or high D-dimer levels (≥ 3.0 mg/l).

This virus causes an intense inflammatory response with massive pro-inflammatory cytokines release, such as interleukin (IL)-1, IL-6, IL-8, and interferon- γ , associated with endothelial vascular damage causing a hypercoagulable state, which leads to microvascular thrombosis [9, 10]. Some authors suggest using MicroCLOTS (microvascular COVID-19 lung vessels obstructive thromboinflammatory syndrome) as an adequate name for this severe pulmonary presentation [11]. As all these alterations are diffuse, we expected to find systemic microvascular thrombosis, as we described in the sublingual territory. Since the pulmonary capillaries assessment is challenging in living patients, we generalize that the same should happen in pulmonary microcirculation.

Quintana-Castenedo et al. [12] reported retinal vasculitis with perivascular infiltrate and retinal exudates in ocular fundus examination of a child with COVID-19, they did not describe vascular obstruction in the retinal vessels. Besides the clinical presentation in children is milder, we considered that sublingual evaluation provides a more

Table 1 Characteristics of the COVID-19 patients in whom sublingual microcirculation was assessed

Parameters	n = 13
Demographic	
Age (years), mean \pm sd	58 \pm 11
Male, n (%)	10 (77)
Clinical presentation	
Fever, n (%)	11 (85)
Cough, n (%)	12 (92)
Dyspnea, n (%)	13 (100)
Myalgia, n (%)	7 (54)
Duration of symptoms (days), median (IQR)	6 (4–9)
Risk factors	
Diabetes mellitus, n (%)	4 (31)
Hypertension, n (%)	4 (31)
Cardiovascular disease, n (%)	1 (08)
Immunocompromise, n (%)	1 (08)
BMI (Kg/m ²), mean \pm sd	34 \pm 9
Physical Examination	
Systolic blood pressure (mmHg), mean \pm sd	120 \pm 23
Diastolic blood pressure (mmHg), mean \pm sd	74 \pm 11
Heart rate (beats per minute), mean \pm sd	79 \pm 19
Mechanical ventilation, n (%)	13 (100)
Tidal volume (ml), mean \pm sd	374 \pm 66
PEEP (cm of water), mean \pm sd	12 \pm 3
Plateau pressure (cm of water), mean \pm sd	24 \pm 4
Static compliance (ml/cm of water), mean \pm sd	33 \pm 8
Respiratory rate (cycles/min), mean \pm sd	24 \pm 4
FiO ₂ (%), range (min-max)	0.55–1.00
Drugs	
Norepinephrine, n (%)	6 (46)
Midazolam, n (%)	13 (100)
Fentanyl, n (%)	13 (100)
Neuromuscular blocking agent, n (%)	13 (100)
Hydroxychloroquine, n (%)	3 (23)
Macrolide antibiotic, n (%)	13 (100)
Corticosteroids, n (%)	9 (69)
Antiplatelet agents, n (%)	0 (00)
Therapeutic LMWH, n (%)	6 (46)
Prophylactic LMWH, n (%)	7 (54)
Laboratory test	
Hemoglobin (g/dl), mean \pm sd	13 \pm 2
White-cell count (per microliter), mean \pm sd	8232 \pm 4149
Platelets count (per microliter), mean \pm sd	234,231 \pm 55,853
Creatinine clearance (ml/min), mean \pm sd	69 \pm 18
Creatinine (mg/dl), mean \pm sd	1.2 \pm 0.3
D-Dimer (μ g/L), median (IQR)	1830 (1120–2320)
Fibrinogen (mg/dl), median (IQR)	767 (672–843)
aPTT (Ratio), median (IQR)	1.16 (1.06–1.20)
Prothrombin time (INR), median (IQR)	1.06 (1.03–1.18)
C-reactive protein (mg/L), mean \pm sd	18 \pm 8
Lactate (mg/dl), mean \pm sd	1.7 \pm 0.4
PaO ₂ /FiO ₂ ratio, mean \pm sd	128 \pm 32
Chest radiography with bilateral opacities, n (%)	13 (100)

Table 1 (continued)

Parameters	n = 13
Scores, median (IQR)	
SOFA	10 (8–11)
SAPS 3	56 (49–68)
DIC score (ISTH)	2(2–3)
SIC score	2 (2–2)
ARDS classification	
Severe, n (%)	2 (15)
Moderate, n (%)	11 (85)

sd standard deviation, *IQR* interquartile range, *BMI* body mass index, *PEEP* positive end-expiratory pressure, *PaO2* partial pressure of arterial oxygen, *FiO2* fraction of inspired oxygen, *LMWH* low-molecular-weight heparin, *aPTT* activated partial thromboplastin time, *INR* international normalized ratio, *SOFA* sequential organ failure assessment score, *SAPS 3* simplified acute physiology score 3, *DIC* International Society of Thrombosis and Hemostasis criteria for disseminated intravascular coagulation, *SIC* sepsis-induced coagulopathy score, *ARDS* acute respiratory distress syndrome

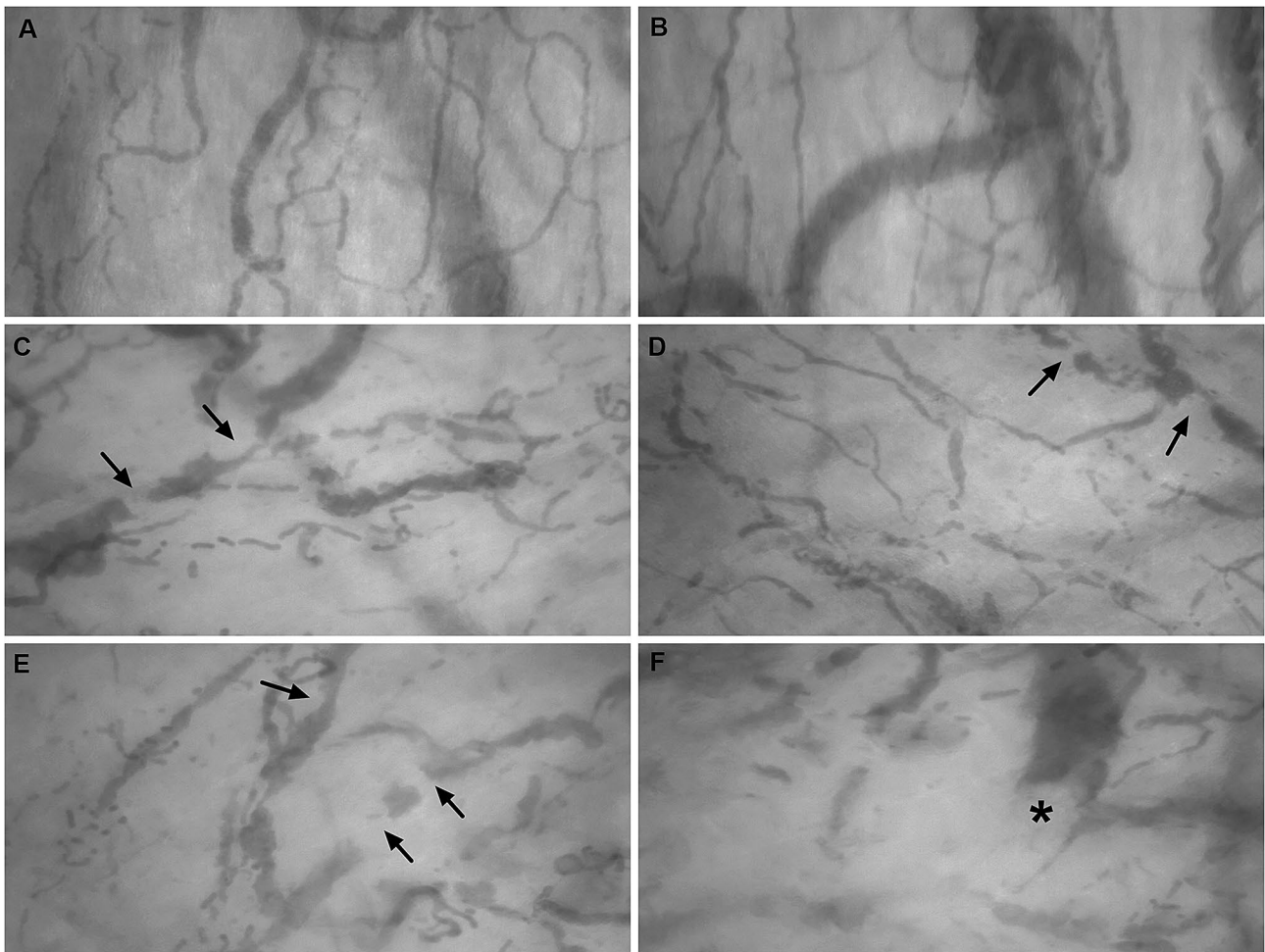


Fig. 1 Normal sublingual microcirculation in a healthy individual (a–b). Presence of several filling defects (arrows) moving inside the microvessels indicative of thrombi (c–e) in severe COVID-19

patients. Microvessel with interrupted flow showing semi-oval imaging (asterisk) in its distal extremity compatible with acute thromboembolic occlusion (f) in COVID-19 patient

detailed assessment of microcirculation than funduscopic examination.

This is a descriptive study of a small series of COVID-19 patients. There was no control group in this investigation. Despite the microcirculatory alterations are frequently observed in critically ill patients [13], especially in patients with sepsis, similar findings of multiple filling defects moving within the microvessels are not described in these patients. We considered that the endotracheal tube did not influence in sublingual microcirculation evaluation, because previous studies in mechanically ventilated patients did not observe this interference. In summary, this is the first imaging documentation of microvascular thrombosis in living severe COVID-19 patients since the beginning of the hospitalization. The clinical relevance of microvascular thrombosis in COVID-19 requires further research.

Author contribution DAES—acquisition of data, analysis and interpretation of data, draft the article, final approval of the last version. ACBL—acquisition of data, analysis and interpretation of data, draft the article, final approval of the last version. CHM—conception and design of the study, acquisition of data, analysis and interpretation of data, draft the article, final approval of the last version.

Funding This research was supported by grants of the Fundação de Amparo a Pesquisa do Estado de São Paulo (FAPESP), process number: 2019/06187-1.

Data availability The data used and/or analyzed during the current study are available from author corresponding author on reasonable request.

Compliance with ethical standards

Conflict of interest All authors declare no conflicts of interest.

Ethical approval The study was approved by the Research Ethics Committee of our institution and followed the Declaration of Helsinki.

Informed consent The subjects or their relatives gave their written informed consent to participate of this research.

References

- Berlin DA, Gulick RM, Martinez FJ (2020) Severe Covid-19. *N Engl J Med*. <https://doi.org/10.1056/NEJMc2009575>
- Klok FA, Kruip M, van der Meer NJM, Arbous MS, Gommers D, Kant KM, Kaptein FHJ, van Paassen J, Stals MAM, Huisman MV, Endeman H (2020) Incidence of thrombotic complications in critically ill ICU patients with COVID-19. *Thromb Res* 191:145–147. <https://doi.org/10.1016/j.thromres.2020.04.013>
- Dolhnikoff M, Duarte-Neto AN, de Almeida Monteiro RA, Ferraz da Silva LF, Pierre de Oliveira E, Nascimento Saldiva PH, Mauad T, Marcia Negri E (2020) Pathological evidence of pulmonary thrombotic phenomena in severe COVID-19. *J Thromb Haemost*. <https://doi.org/10.1111/jth.14844>
- Ackermann M, Verleden SE, Kuehnel M, Haverich A, Welte T, Laenger F, Vanstapel A, Werlein C, Stark H, Tzankov A, Li WW, Li VW, Mentzer SJ, Jonigk D (2020) Pulmonary vascular endothelialitis, thrombosis, and angiogenesis in Covid-19. *N Engl J Med*. <https://doi.org/10.1056/NEJMoa2015432>
- Fox SE, Akmatbekov A, Harbert JL, Li G, Quincy Brown J, Vander Heide RS (2020) Pulmonary and cardiac pathology in African American patients with COVID-19: an autopsy series from New Orleans. *Lancet Respir Med*. [https://doi.org/10.1016/S2213-2600\(20\)30243-5](https://doi.org/10.1016/S2213-2600(20)30243-5)
- Carsana L, Sonzogni A, Nasr A, Rossi RS, Pellegrinelli A, Zerbi P, Rech R, Colombo R, Antinori S, Corbellino M, Galli M, Catena E, Tosoni A, Gianatti A, Nebuloni M (2020) Pulmonary post-mortem findings in a series of COVID-19 cases from northern Italy: a two-centre descriptive study. *Lancet Infect Dis*. [https://doi.org/10.1016/S1473-3099\(20\)30434-5](https://doi.org/10.1016/S1473-3099(20)30434-5)
- Sise ME, Baggett MV, Shepard JO, Stevens JS, Rhee EP (2020) Case 17-2020: a 68-year-old man with Covid-19 and acute kidney injury. *N Engl J Med*. <https://doi.org/10.1056/NEJMcpc2002418>
- Tang N, Bai H, Chen X, Gong J, Li D, Sun Z (2020) Anticoagulant treatment is associated with decreased mortality in severe coronavirus disease 2019 patients with coagulopathy. *J Thromb Haemost* 18(5):1094–1099. <https://doi.org/10.1111/jth.14817>
- Iba T, Levy JH, Levi M, Thachil J (2020) Coagulopathy in COVID-19. *J Thromb Haemost*. <https://doi.org/10.1111/jth.14975>
- Tan CW, Low JGH, Wong WH, Chua YY, Goh SL, Ng HJ (2020) Critically ill COVID-19 infected patients exhibit increased clot waveform analysis parameters consistent with hypercoagulability. *Am J Hematol*. <https://doi.org/10.1002/ajh.25822>
- Ciceri F, Beretta L, Scandroglio AM, et al. (2020) Microvascular COVID-19 lung vessels obstructive thromboinflammatory syndrome (MicroCLOTS): An atypical acute respiratory distress syndrome working hypothesis. *Crit Care Resusc*. 22(2):95–97
- Quintana-Castanedo L, Feito-Rodríguez M, Fernández-Alcalde C, Granados-Fernández M, Montero-Vega D, Mayor-Ibarguren A, Lucas Laguna R (2020) Concurrent chilblains and retinal vasculitis in a child with COVID-19. *J Eur Acad Dermatol Venereol*. <https://doi.org/10.1111/jdv.16801>
- de Backer D, Ospina-Tascon G, Salgado D, Favory R, Creteur J, Vincent JL (2010) Monitoring the microcirculation in the critically ill patient: current methods and future approaches. *Intensive Care Med* 36:1813–1825. <https://doi.org/10.1007/s00134-010-2005-3>

Publisher's Note Springer Nature remains neutral with regard to jurisdictional claims in published maps and institutional affiliations.