

Severe coronavirus disease pneumonia in a pregnant woman at 25 weeks' gestation: A case report

Miyoko Waratani , Fumitake Ito, Yukiko Tanaka, Aki Mabuchi, Taisuke Mori and Jo Kitawaki

Department of Obstetrics and Gynecology, Kyoto Prefectural University of Medicine, Kyoto, Japan

Abstract

There are numerous reports on the effects of the coronavirus disease on mothers and fetuses during pregnancy. It is currently unknown whether pregnancy is associated with a high risk of severe coronavirus disease. We report a pregnant patient with coronavirus disease who underwent a cesarean section. A pregnant 39-year-old Japanese woman was diagnosed with coronavirus disease at 25 weeks of gestation. Her breathing condition worsened daily, and she required oxygen administration. On day 6 of her 26th week of gestation, she developed severe pneumonia and required tracheal intubation and artificial ventilation, and an emergency cesarean section was performed under general anesthesia. It is necessary to investigate the risk of increased coronavirus disease severity during pregnancy, the effects of coronavirus disease on perinatal prognosis, and the management of pregnancy with coronavirus disease.

Key words: COVID-19, fetus, perinatal care, pregnancy complications, tracheal intubation.

Introduction

In February 2020, a novel virus, called severe acute respiratory syndrome coronavirus 2 (SARS-CoV-2)¹ by the International Committee on Taxonomy of Viruses, was recognized by the World Health Organization as the causative agent of the coronavirus disease (COVID-19).² The disease has now spread globally. There are numerous reports on the effects of infection on mothers and fetuses during pregnancy, and many details are now understood about this disease, including associated complications and established treatment methods. However, much remains unknown regarding the relationship between COVID-19 and pregnancy, such as whether perinatal complication rates are increased by COVID-19 and whether pregnancy is a risk factor for increased COVID-19 severity. Additionally, there are restrictions on radiography and therapeutic drug use during pregnancy; thus, it can be expected that the treatment

of pregnant patients in case of increased COVID-19 severity may be more difficult than the treatment of non-pregnant patients.

In this study, we describe a case of a severe COVID-19 infection in a pregnant woman requiring tracheal intubation and artificial ventilation, and we also performed a cesarean section in the extremely preterm period.

Case Presentation

A 39-year-old multigravida uniparous Japanese woman with a history of gestational diabetes, obesity (body mass index [BMI]: 26.7), and bronchial asthma presented with a singleton pregnancy. On day 0 of week 25 of gestation, she developed a cough. Subsequently, she underwent a polymerase chain reaction (PCR) test by nasal swab as she had a possible contact with COVID-19-positive patients. Her cough

Received: October 15 2020.

Accepted: January 29 2021.

Correspondence: Miyoko Waratani, Department of Obstetrics and Gynecology, Kyoto Prefectural University of Medicine, 645 Kaiji-cho, Kamigyo-ku, Kyoto 602-8566, Japan. Email: mwara@koto.kpu-m.ac.jp

continued, and on day 2 of week 25 of gestation, she was diagnosed with COVID-19 and was transferred to our hospital. Her remaining family members tested negative for COVID-19. On admission, her only symptom was a cough; no respiratory distress or fever was reported, and her oxygen saturation (SpO_2 , 97%; room air) was mild (mild range: the SpO_2 value is 96% or higher and the patient has no respiratory symptoms). On days 3 and 5 of week 25 of gestation, she developed dysgeusia and dysosmia, and a fever, phlegm production, and decreased SpO_2 (95–96%; room air) were observed, respectively. On day 6 of week 25, her fever continued, and she developed respiratory distress. Chest computed tomography (CT) showed infiltrative opacities in the peripheral regions of the right lower and upper lobes, along with lung field volume loss. There were numerous areas of patchy and ground-glass opacities in both lungs (Figure 1a). These findings were consistent with COVID-19 pneumonia. On day 0 of week 26, supine SpO_2 was reduced (93–96%; room air); thus, transnasal oxygen was initiated at 1 L/min. Chest radiography showed decreased permeability (Figure 2a). On day 1 of week 26, antiviral chemotherapy (lopinavir + ritonavir combination therapy) was initiated at 800 mg/day orally. On day 2 of week 26, her SpO_2 had

deteriorated to 94–95%; thus, the transnasal oxygen flow rate was increased to 3–4 L/min. Chest radiography showed a greater decrease in permeability (Figure 2b). Moreover, insulin therapy was initiated for poor glycemic control. On day 3 of week 26, in conjunction with further SpO_2 deterioration, the transnasal oxygen flow was increased to 4–5 L/min. Due to asthma symptoms, we administered an inhaled steroidal anti-asthma agent (ciclesonide) and intravenous ceftriaxone sodium (2 g/24 h). On day 4 of week 26, the transnasal oxygen flow rate was increased to 5–6 L/min (SpO_2 , 95%), and 6 mg/day of intravenous dexamethasone was administered. On day 5 of week 26, her oxygenation had deteriorated further, and nasal-high-flow oxygen delivery was initiated. Arterial oxygen partial pressure was 89–96 mmHg under the conditions of nasal-high-flow oxygen rate; 40 L/min, and fraction of inspired oxygen; 50–60%. On day 6 of week 26, the patient's respiratory state deteriorated, and she developed severe pneumonia that necessitated tracheal intubation and artificial ventilation. Radiograph findings associated with pathological progression are shown in Figure 2c–e. The time course of changes in body temperature, heart rate, SpO_2 , and the transnasal oxygen flow rate from day 2 of week 25 to day 5 of week 26 are shown

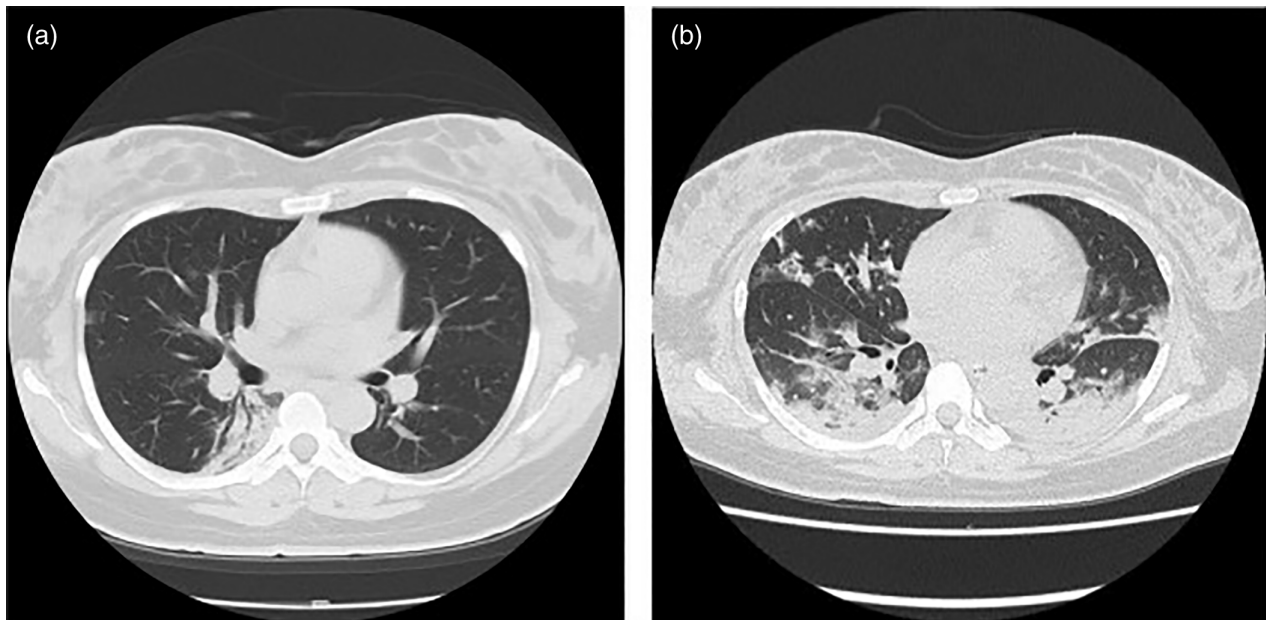


FIGURE 1 Chest computed tomography. (a) Image on day 6 of week 25. Infiltrative opacity can be seen in the peripheral regions of the right lower and upper lobes, along with lung field volume loss. (b) Image after completing surgery. Ground-glass opacity expansion in both lungs and abnormal opacity expansion can be seen, indicating that an air bronchogram is present in the left internal regions of the lower lobes of both lungs.

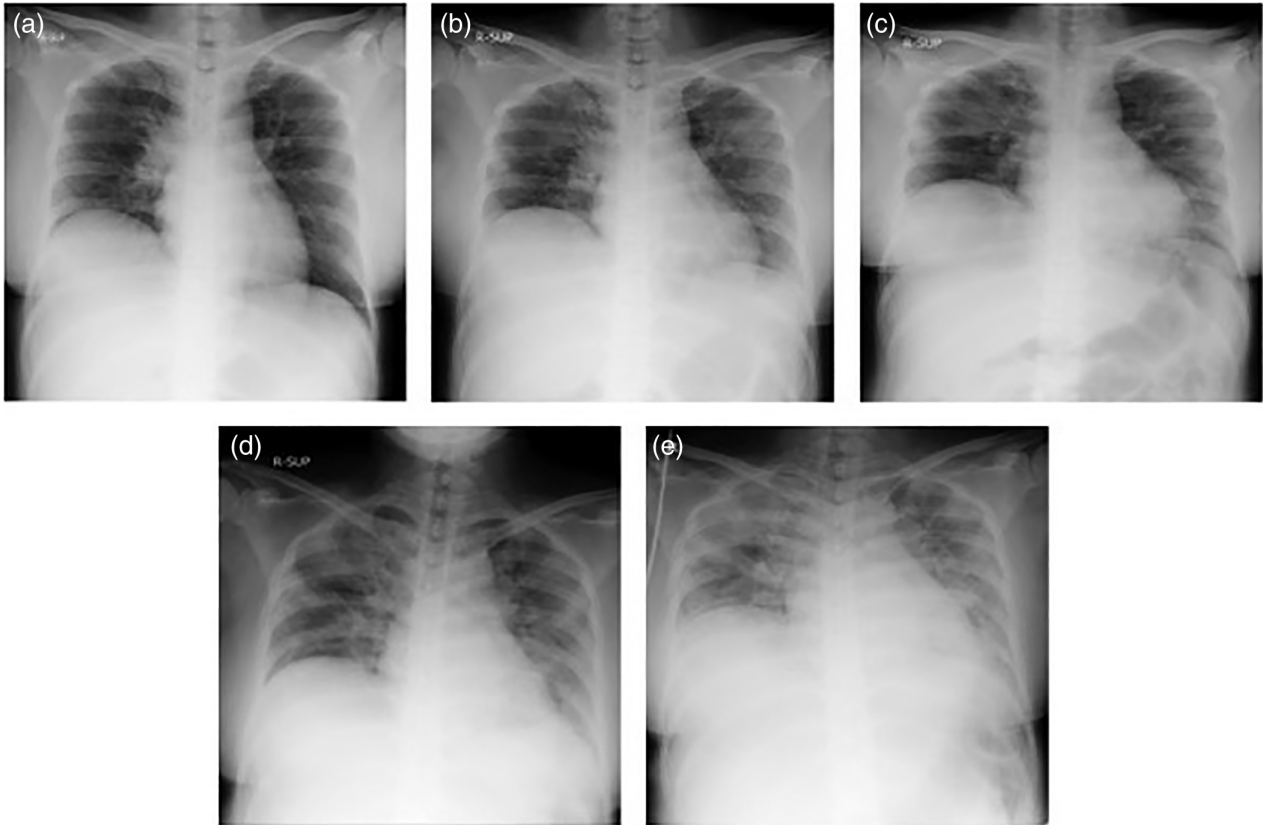


FIGURE 2 Chest radiograph. (a) Image on day 0 of week 26 showing a slight decrease in permeability. (b) Image on day 2 of week 26 showing a greater decrease in permeability than that in (a). (c) Image on day 4 of week 26. (d) Image on day 5 of week 26. (e) Image on day 6 of week 26 showing ground-glass shadows on both lung fields and a gradual decrease in permeability over time.

in Figure 3a. Blood pressure was normal during this entire period. The time course of changes in levels of serum lactate dehydrogenase (LDH), C-reactive protein (CRP), ferritin, and D-dimer markers of COVID-19 severity are shown in Figure 3b. LDH, CRP, and ferritin levels increased as the COVID-19 pneumonia became more severe. D-Dimer levels did not increase preoperatively. Deterioration in the patient's general condition threatened the continuation of pregnancy and we needed to increase maternal treatment option; thus, an emergency cesarean section was performed under general anesthesia on the same date that artificial ventilation was initiated. The amount of hemorrhage during surgery, including amniotic fluid, was 905 g, and no blood transfusion was performed. We confirmed that the fetal status was safe by a cardiotocogram from day 2 of week 25 to the operation date. The infant's birth weight, Apgar scores, and umbilical arterial blood pH were 998 g, 1/1 (at 1/5 min), and 7.263, respectively. Tracheal intubation for the infant was completed 16 min after birth, followed by his transfer to

the neonatal intensive care unit. After completing surgery, the mother's chest CT showed ground-glass opacity expansion in both lungs and abnormal opacity expansion, suggesting COVID-19 pneumonia. An air bronchogram was found in the left internal regions of the lower lobes of both lungs, but predominantly in the dependent lung, indicating respiratory distress syndrome (Figure 1b). We continued artificial ventilation, discontinued lopinavir + ritonavir antiviral combination therapy, and initiated intravenous remdesivir. On postoperative day (POD) 1, the antibiotic regimen was changed to sulbactam + ampicillin (3 g intravenously every 8 h), and enoxaparin sodium was initiated subcutaneously for thrombogenesis prophylaxis. On POD 3, dexamethasone was discontinued. On POD 4, a single 400 mg dose of tocilizumab was administered intravenously, and the antibiotic regimen was changed to cefepime (2 g intravenously every 12 h). Postoperatively, the patient's respiratory state was gradually restored. On POD 5, artificial ventilation was discontinued, extubation was performed, and artificial

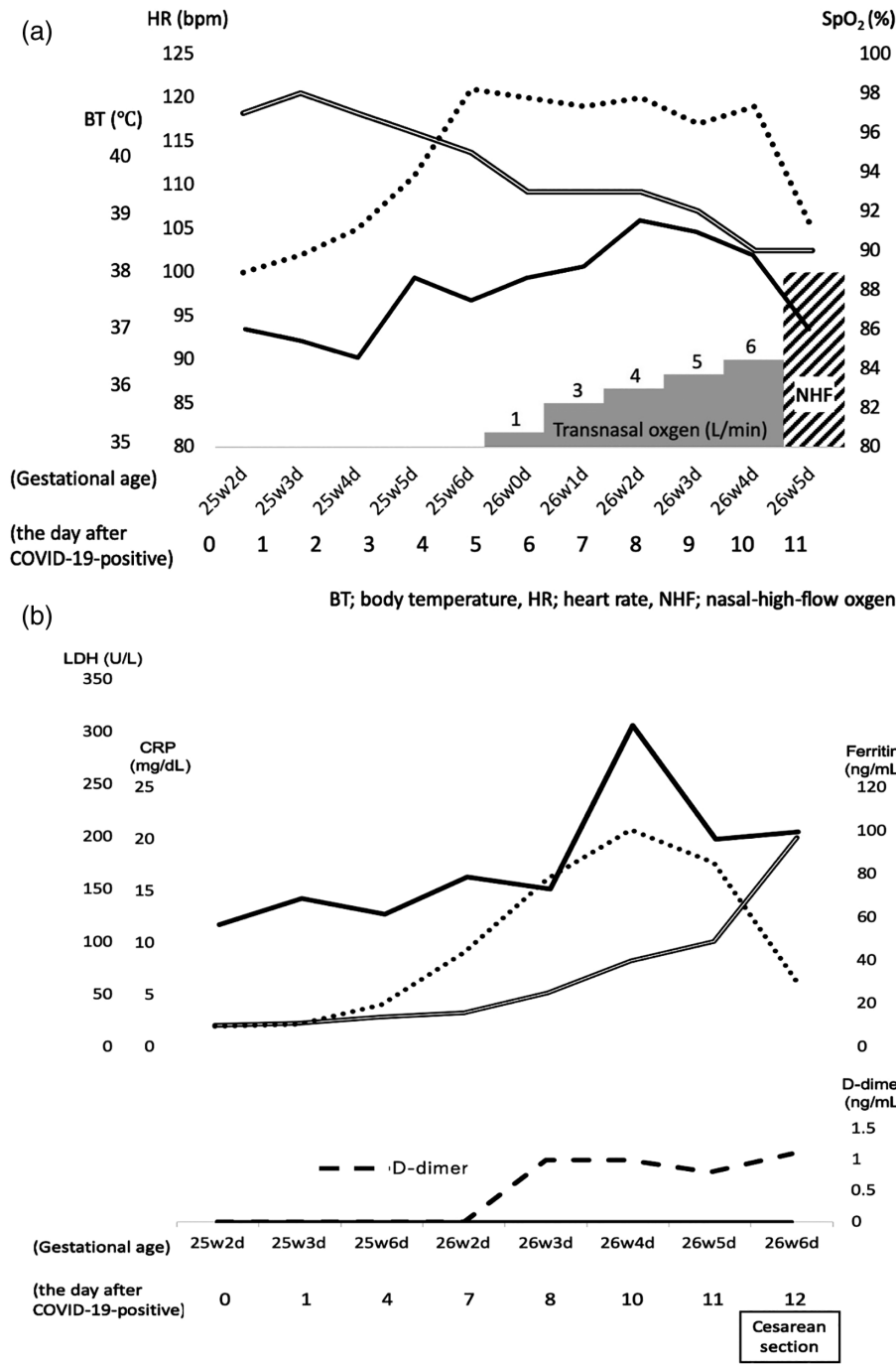


FIGURE 3 (a) Time course of changes in body temperature, heart rate, SpO₂, and the transnasal oxygen flow rate. (b) Time course of changes in lactate dehydrogenase, C-reactive protein, and ferritin levels (—, ·····, —, —, ·····, —).

ventilation was replaced with transnasal oxygen at 3 L/min. On POD 7 and 8, cefepime and oxygen delivery were discontinued, respectively. On POD 18, the patient was discharged with confirmed COVID-19-negative results. Nasal PCR tests were performed for the infant on days 1, 3, 7, 10, and 11; the results were consistently negative.

Discussion

Relationship between pregnancy and increased COVID-19 severity

If COVID-19 is contracted during pregnancy, the rate of increase in severity is likely similar to that in non-pregnancy.³ Coronaviruses are ribonucleic acid

(RNA) viruses enclosed in lipid-membrane envelopes. In the past, there were six known types: (1) four that cause the common cold; (2) Severe acute respiratory syndrome coronavirus (SARS-CoV), which caused an epidemic in 2003; and (3) Middle East respiratory syndrome coronavirus (MERS-CoV), which caused an epidemic in 2012. The increased coronavirus severity rates and resulting deaths during pregnancy are lower in COVID-19 than in SARS and MERS.⁴ In June 2020, the United States Centers for Disease Control and Prevention revised the guidelines regarding risk factors associated with an increase in COVID-19 severity to include pregnancy.⁵ However, a limited number of patient data are available; additional data must be collected and analyzed in the future.

Severity evaluation for COVID-19-complicated pregnancy

In this case, the patient had complications of gestational diabetes, obesity (BMI: 26.7), bronchial asthma, and pregnancy with COVID-19. The Centers for Disease Control and Prevention reported that pregnancy and type 2 diabetes mellitus place patients at increased risk for COVID-19, and asthma and overweight (BMI > 25 kg/m², but <30 kg/m²) patients might be at an increased risk for severe illnesses of COVID-19. It is unclear whether all the complications of this patient were mild, and which had the most important influence on severity.

The sequential organ failure assessment score is a quantitative index of damage to important organs and is also used for severity evaluation in COVID-19 cases,⁶ including cases involving pregnant women. However, although there is a correlation between COVID-19 severity and D-dimer levels, even in pregnant women without COVID-19, pregnancy D-dimer levels are often higher than those in non-pregnancy, and caution is needed when using the D-dimer level for severity evaluation.⁷ There are reports of other severity markers.⁶ Among these, CRP, LDH, and ferritin levels increase with respiratory state deterioration; thus, these parameters may suggest an increase in severity.

Effects of COVID-19 on perinatal prognosis

There are no published reports that clearly show increases in perinatal complications due to COVID-19 contraction during pregnancy.⁴ If severity increases, termination is sometimes selected at an early stage of pregnancy to prioritize the treatment of pregnant women. If the pregnancy continues, there are concerns regarding the effects of COVID-19 treatment on

the fetus, and the number of iatrogenic spontaneous abortions has increased.^{8, 9} Di Mascio et al. reported that COVID-19 infections at early gestational age were associated with maternal ventilatory supports and low birthweight.¹⁰ In contrast, there have been few reports of vertical transmission of COVID-19^{3, 4, 10}, and our case did not involve an infant that was infected with COVID-19.

Treatment of COVID-19 during pregnancy

The only antiviral agents that should be administered during pregnancy are those that are established as safe for pregnant women.¹¹ Currently, remdesivir can be administered to pregnant women.⁴ The anti-influenza antiviral agent favipiravir is converted in the body to the triphosphate form, T-705RTP, which selectively inhibits RNA polymerase, and may be effective against RNA viruses other than influenza. It is used to treat COVID-19, but is teratogenic and must not be administered during the early phase of pregnancy.¹² When dexamethasone is administered concomitantly with standard therapy for COVID-19 patients with moderate-to-severe acute respiratory distress syndrome, the number of days of artificial ventilation, up to day 28 of treatment (i.e., days in which the patient is alive and mechanical ventilation is not used), increases in comparison with standard therapy alone.¹³ Corticosteroids have anti-inflammatory effects and may prevent or suppress harmful inflammatory reactions that may lead to lung damage and/or multiple organ failure.¹⁴ Dexamethasone is safe and can be administered during pregnancy. Ciclesonide is an inhaled, steroidal anti-asthma agent that is indicated for bronchial asthma but may have specific antiviral effects against COVID-19.¹⁵ It is safe to administer during pregnancy; thus, it was administered in our case. Considering the potential for the concomitant development of bacterial and COVID-19 pneumonia, we administered ceftriaxone sodium, sulbactam + ampicillin, and cefepime during pregnancy and until after cesarean section was performed.

Termination criteria in pregnant women with COVID-19

No clear criteria have been defined for termination in cases of COVID-19 during pregnancy; therefore, considering the risk of increased severity and effects on perinatal prognosis, early selection of termination is currently avoided⁸ for the following reasons:

1. Limited data are available regarding the outcomes of pregnant women with COVID-19.

- Physicians hesitate to perform radiography during pregnancy, which can prevent accurate pathology evaluation.
- The number of agents permitted for use during pregnancy is limited; thus, COVID-19 treatment in ongoing pregnancies is restricted.

In this case, the most important factor was that the choice of treatment (drug and respiratory management) during pregnancy was limited, and we determined pregnancy termination at the preterm period. Future investigations should involve the collection of numerous data and the establishment of clear criteria for termination for definite decisions to be made about the feasibility of continuing pregnancy, which is essential for perinatal COVID-19 management.

Conclusions

The relationship between COVID-19 and pregnancy remains unknown; thus, continued data collection is necessary. It is important to investigate the risk of increased COVID-19 severity during pregnancy and the effects of COVID-19 on perinatal prognosis and COVID-19 treatment during pregnancy.

Acknowledgments

The authors would like to thank all members of the multidisciplinary team (Kasamatsu Y, Ito T, Fujita N, Ushigome E, Hamaguchi M, Yamazaki M, Hasegawa T, Iehara T), the patient involved in this study, and her family. We would like to thank Editage (www.editage.com) for English language editing.

Conflict of Interest

The authors declare that they have no competing interests and the results of this manuscript have not been distorted by research funding or conflicts of interest.

References

- Coronaviridae Study Group of the International Committee on Taxonomy of Viruses. The specific severe acute respiratory syndrome-related coronavirus: classifying 2019-nCoV and naming it SARS-CoV-2. *Nat Microbiol.* 2020;5:536–44.
- World Health Organization. Coronavirus disease 2019 (COVID-19) situation report – 54. 2020. World Health Organization. https://www.who.int/docs/default-source/coronaviruse/situation-reports/20200314-sitrep-54-covid-19.pdf?sfvrsn=dcd46351_8. Accessed 2020.
- Pettiroso E, Giles M, Cole S, Rees M. COVID-19 and pregnancy: a review of clinical characteristics, obstetric outcomes and vertical transmission. *Aust N Z J Obstet Gynaecol.* 2020;60:640–59.
- Dashraath P, Wong JLJ, Lim MX, Lim LM, Li S, Biswas A, et al. Coronavirus disease 2019 (COVID-19) pandemic and pregnancy. *Am J Obstet Gynecol.* 2020;222:521–31.
- Ellington S, Srid P, Tong VT, Woodworth K, Galang RR, Zambrano LD, et al. Characteristics of women of reproductive age with laboratory-confirmed SARS-CoV-2 infection by pregnancy status—United States, January 22–June 7, 2020. *MMWR Morb Mortal Wkly Rep.* 2020;69:769–75.
- Zhou F, Yu T, Du R, Fan G, Liu Y, Liu Z, et al. Clinical course and risk factors for mortality of adult inpatients with COVID-19 in Wuhan, China: a retrospective cohort study. *Lancet.* 2020;395:1054–62.
- Kovac M, Mikovic Z, Rakicevic L, Srzentic S, Mandic V, Djordjevic V, et al. The use of D-dimer with new cutoff can be useful in diagnosis of venous thromboembolism in pregnancy. *Eur J Obstet Gynecol Reprod Biol.* 2010;148:27–30.
- Turan O, Halim A, Dashraath P, Jeslyn WJL, Wright A, Abdul-Kadir R. Clinical characteristics, prognostic factors, and maternal and neonatal outcomes of SARS-CoV-2 infection among hospitalized pregnant women: a systematic review. *Int J Gynaecol Obstet.* 2020;151:7–16.
- Dana PM, Kolahdooz F, Saadoughi F, Moazzami B, Chaichian S, Asemi Z. COVID-19 and pregnancy: a review of current knowledge. *Infez Med.* 2020;28:46–51.
- Di Mascio D, Sen C, Saccone G, Galindo A, Grünebaum A, Yoshimatsu J, et al. Risk factors associated with adverse fetal outcomes in pregnancies affected by coronavirus disease 2019 (COVID-19): a secondary analysis of the WAPM study on COVID-19. *J Perinat Med.* 2020;48:950–8.
- Castro P, Matos AP, Werner H, Lopes FP, Tonni G, Araujo JE. Covid-19 and pregnancy: an overview. *Rev Bras Ginecol Obstet.* 2020;42:420–6.
- Coomes EA, Haghbayan H. Favipiravir, an antiviral for COVID-19? *J Antimicrob Chemother.* 2020;75:2013–4.
- Villar J, Añón JM, Ferrando C, Aguilar G, Muñoz T, Ferreres J, et al. Efficacy of dexamethasone treatment for patients with the acute respiratory distress syndrome caused by COVID-19: study protocol for a randomized controlled superiority trial. *Trials.* 2020;21:717.
- Matsuyama S, Kawase M, Nao N, Shirato K, Ujike M, Kamitani W, et al. The inhaled corticosteroid ciclesonide blocks coronavirus RNA replication by targeting viral NSP15. *BioRxiv.* 2020. <https://doi.org/10.1101/2020.03.11.987016>. Online ahead of print.
- RECOVERY Collaborative Group, Horby P, Lim WS, Emberson JR, Mafham M, Bell JL, et al. Dexamethasone in hospitalized patients with Covid-19 – preliminary report. *N Engl J Med.* 2020. <https://doi.org/10.1056/NEJMoa2021436>. Online ahead of print.