

Contents lists available at [ScienceDirect](http://www.sciencedirect.com)

International Journal of Surgery Case Reports

journal homepage: www.casereports.com

Breast lymphoma in a patient with B-cell Non Hodgkin Lymphoma: A case report study



Spyridon Marinopoulos^{a,*}, Panagiotis Safioleas^a, Lamprini Skorda^b, Eleni Vassilopoulou^a, Flora Zagouri^c, Maria Sotiropoulou^d, Peter Drakakis^a, Constantine Dimitrakakis^a

^a Breast Unit, 1st Ob/Gyn Department, Athens University Medical School, "Alexandra" Hospital, Greece

^b 1st Internal Medicine Clinic, Red Cross Hospital, Athens, Greece

^c Therapeutic Clinic, Athens University Medical School, "Alexandra" Hospital, Greece

^d Pathology Department, "Alexandra" Hospital, Athens, Greece

ARTICLE INFO

Article history:

Received 8 August 2017

Received in revised form 3 September 2017

Accepted 3 September 2017

Available online 7 September 2017

Keywords:

Non Hodgkin Lymphoma
Secondary breast lymphoma
Therapeutic approach
Case report

ABSTRACT

INTRODUCTION: Breast involvement in Non Hodgkin Lymphoma is a rare entity as it accounts for 2.2% of all extranodal lymphomas.

PRESENTATION OF CASE: A 59-year-old woman was referred to our Breast Unit because of two nodules of the right breast newly discovered during her annual mammography. Moreover, during the physical examination, a red-brown itchy lump of the scalp was discovered. The punch biopsies of the scalp lesion and ultrasound-guided core biopsies of both nodules of the right breast, revealed the presence of diffuse large B-cell Non Hodgkin Lymphoma in all tissue specimen sites.

DISCUSSION: Breast lymphomas represent an uncommon form of localized extranodal lymphomas that can be classified as Primary (PBL) or Secondary (SBL) breast lymphomas.

CONCLUSION: The value of preoperative diagnosis should be underlined as the patient avoids unnecessary surgical intervention and has earlier initiation of chemotherapy.

© 2017 Published by Elsevier Ltd on behalf of IJS Publishing Group Ltd. This is an open access article under the CC BY-NC-ND license (<http://creativecommons.org/licenses/by-nc-nd/4.0/>).

1. Introduction

Breast involvement in Non Hodgkin Lymphoma (NHL) is a very rare clinical entity, accounting for 2.2% of all extranodal lymphomas and from 0.04 to 0.5% of breast malignancies. It may present as a Primary Breast Lymphoma (PBL), indicating a primary extra lymph node involvement or as a Secondary Breast Lymphoma (SBL), a secondary infiltration of systematic disease.

In line with the SCARE criteria [1], we report a case of NHL that was diagnosed because of a breast lump and review the literature.

2. Case presentation

A 59-year-old woman was referred to our Breast Unit because of two nodules of the right breast newly discovered during her annual mammography. Her personal history reported a mild hypothyroidism under treatment with 75 µg sodium levothyroxine daily. Her psychosocial and family medical history was uneventful. She was a non-smoker.

During the physical examination we detected one slightly palpable, painless, mobile lump of the superior middle area of the right

breast and bulky lymphadenopathy of the left axilla. Macroscopically, no skin retraction of the breast, peau d'orange appearance or nipple discharge was observed. Moreover, a red-brown itchy lump of the scalp was discovered (Fig. 1). No other peripheral palpable lymph nodes were noted. The liver was palpated 1 cm below the pleural arc and nail dystrophy was detected. Digital mammography revealed a couple of radiopaque masses of the right breast without microcalcifications (Fig. 2) and left axillary lymphadenomegaly. Breast ultrasound confirmed the presence of two mixed composition lesions with irregular borders and increased vascularity. A chest and abdomen computerised tomography (CT) was performed, showing a mild hepatomegaly associated with fat infiltration. Gastroscopy and colonoscopy revealed mild gastritis and a remarkable number of diverticulums respectively. The patient did not complain about the typical lymphoma-associated symptoms: fever (temperature > 38 °C), profuse sweating and unexplained weight loss (>10% from baseline within 6 months). Laboratory studies were unremarkable with the exception of a slight increase of cancer antigen 15–3 of 33 U/mL. Specifically, complete blood count results, thyroid function lab results (TSH, T3, T4, anti-TPO), complement tests (C3, C4) and protein electrophoresis were normal. C-reactive protein (CRP), antinuclear antibody test (ANA), rheumatoid factor (RF) blood tests, virological tests, direct and indirect Coombs tests were negative. Uric acid level was 5.8 mg/dL and lactate dehydrogenase level (LDH) was 290 U/L, above normal range. Mantoux testing was

* Corresponding author at: Breast Unit, 1st Ob/Gyn Department, Athens University Medical School, "Alexandra" Hospital, V. Sofias 80 & Lourou 1, 11528, Athens, Greece.
E-mail address: smarinopoulos@outlook.com (S. Marinopoulos).

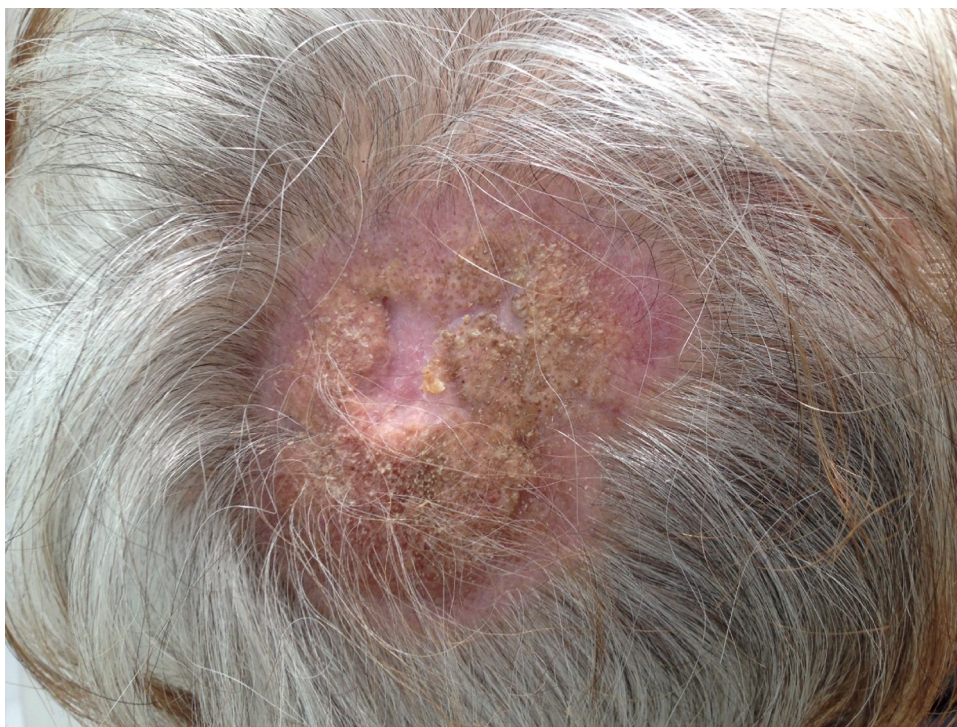

Fig. 1. Lump of the scalp after diagnostic biopsy.

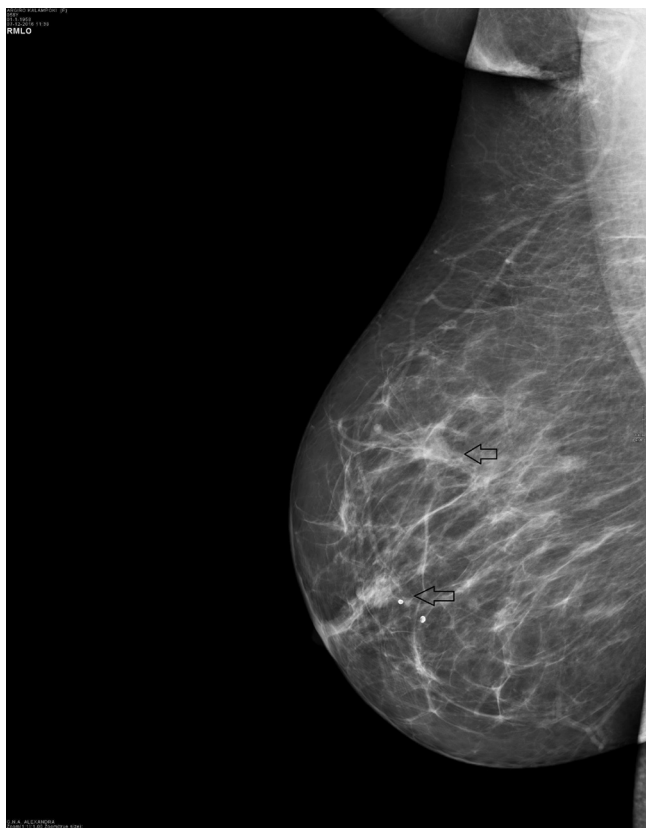


Fig. 2. Radiopaque densities of the right breast.

negative, hepatitis B virus surface antigen (HBsAg) and Anti-HBc IgG was negative.

The patient underwent punch biopsies of the scalp lesion by the breast unit resident and ultrasound-guided core biopsies of both

nodules of the right breast by a consultant radiologist of our hospital. Fine needle aspiration cytology was performed on the enlarged left axillary nodes: large, transformed B cells with prominent nucleoli and basophilic cytoplasm, a diffuse growth pattern and a high proliferation fraction were observed, expressing pan B cell antigens. Pathological examination of tissue samples demonstrated the presence of diffuse large B-cell Non Hodgkin Lymphoma in all tissue specimen sites, with immunohistochemical staining as follows: CD 20+, bcl-6+, CD 10-, MUM 1+ (40–50%), Sig/CIg+, CD 3-, CD 4-, CD 8-, CD 30+, CD 56- and Ki-67: 30–40% (Figs. 3 and 4). The patient expressed her appreciation for the successful minimally invasive diagnostic procedure, avoiding an open biopsy approach. Subsequently, the patient's CT scan of the head and neck revealed a well defined dermal mass of the parietal bone area (6 × 4.4 cm) and two smaller dermal masses of the occipital bone area, without infiltration of the bones. Moreover, a well-defined mass of the oropharynx resembling to an enlarged lymph node chain of the right jugular vein was pictured. Bone marrow aspiration and biopsy revealed marrow free of disease (confirmed with immunohistochemical types CD-20, CD79a-, PAX-5) and a few number of reactive T-lymphocytes (5–8%). Integrated computer tomography and positron emission tomographic scanning (PET/CT) characterized as malignant the following lesions: one left supraclavicular lymph node of few millimeters, a few left axillary lymph nodes of few millimeters and the already known dermal masses of the scalp (Fig. 5).

According to the Ann Arbor staging system, the patient was staged as IV E and was categorized as of high-intermediate risk (score 3) based on the International Prognostic Index.

On the basis of these findings, the Oncology Board of our Breast Unit referred the patient to chemotherapy. The patient received chemotherapy with RCHOP (R: Rituximab, C: Cyclophosphamide, H: Doxorubicin Hydrochloride, O: Vincristine Sulfate, P: Prednisone) and currently has no evidence of disease, immediately after completion of chemotherapy, 6 months after initial diagnosis. The patient was compliant with the therapeutic program which was well tolerated, with no significant side-effects or hospitaliza-

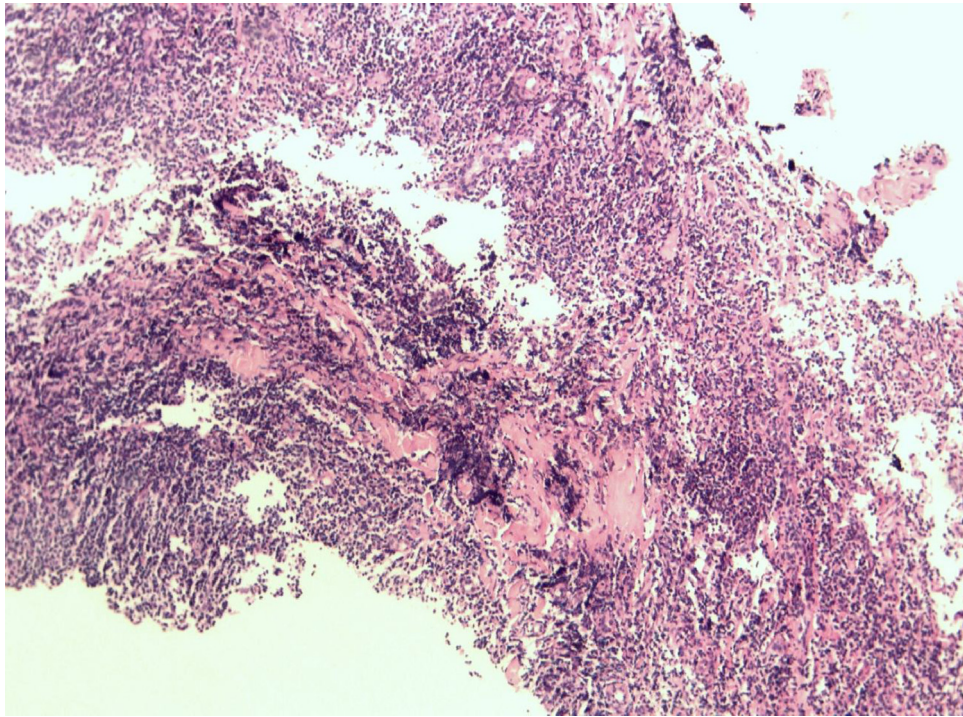


Fig. 3. Breast core biopsy with dense, diffuse neoplastic infiltration from non-Hodgkin lymphoma.

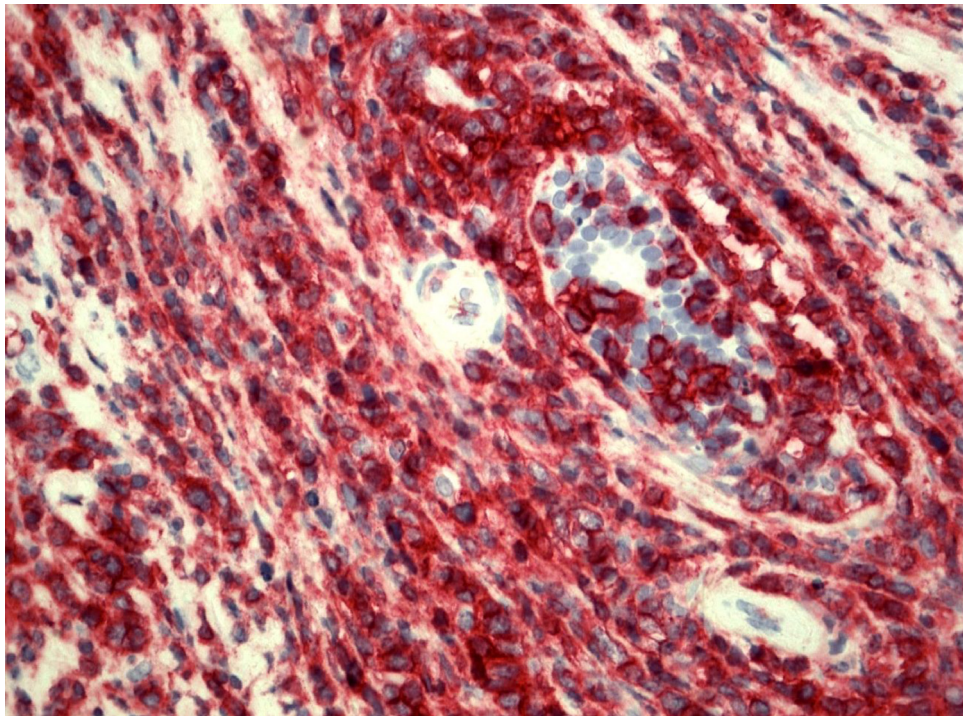


Fig. 4. Positive immunohistochemical stain CD20 certifies the B-cell lineage of Lymphoma.

tions. She remains in follow-up by the oncology department of our hospital.

3. Discussion

Breast lymphomas represent an uncommon form of localized extranodal lymphomas that can be classified as Primary (PBL) or Secondary (SBL) breast lymphomas.

Wiseman and Liao in 1972 first defined clinical criteria for the classification of PBL, including a) adequate pathologic evaluation, b) mammary tissue in close association with lymphomatous infiltrate, c) no evidence of disseminated lymphoma other than simultaneous ipsilateral lymph node involvement and d) no prior diagnosis of lymphoma [2]. All lymphomas involving the breast but not including these criteria are considered as SBL. Morphologically there are no differences between PBL and SBL. The incidence of

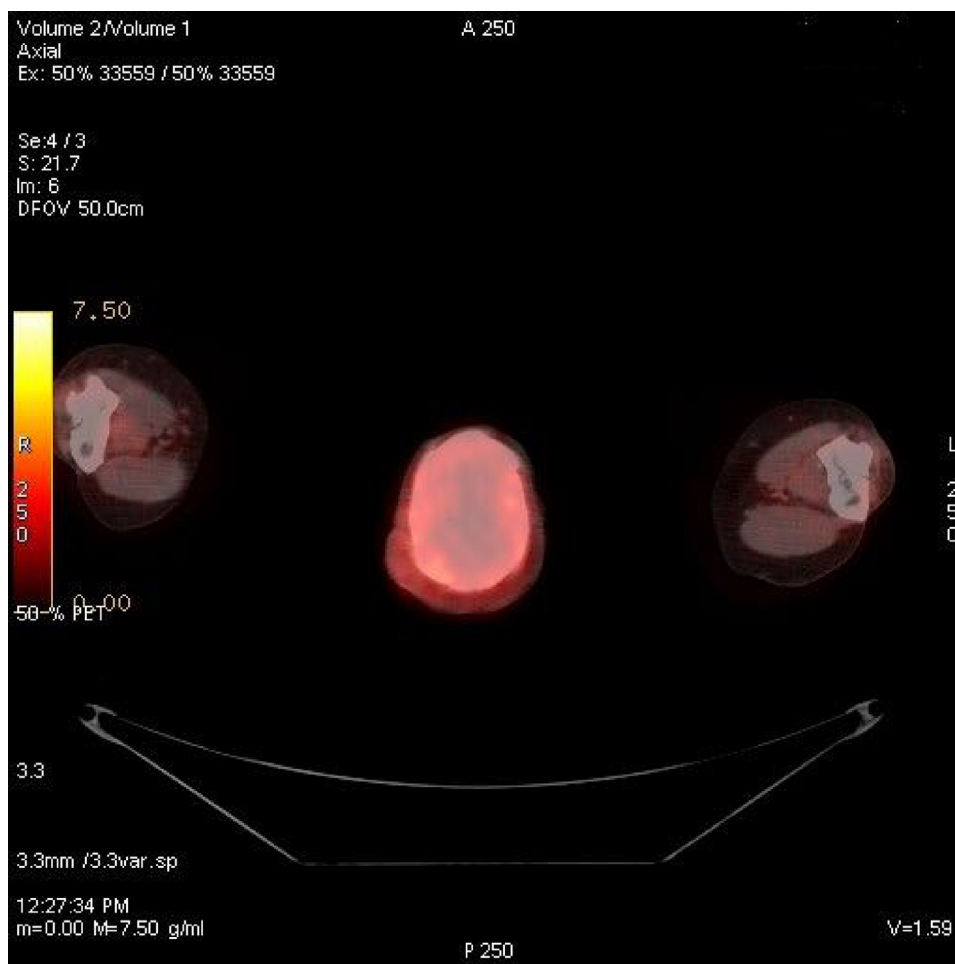


Fig. 5. Pathological absorption of 18FDG by left axillary lymph nodes in PET/CT.

PBL is extremely rare, accounting for 0.04–0.5% of all breast malignancies and approximately 1–2% of all extranodal lymphomas [3]. On the other hand, secondary involvement of the breast by lymphomas is less uncommon. The rarity of the breast lymphoma may be related to the relatively small amount of lymphoid tissue present in the breast as compared to the gut or lung in which primary lymphomas are much more frequent [4]. Most frequently the right breast is involved in both primary and secondary cases. This tendency remains an unexplained feature and is a common observational point in the literature [5]. There is preponderance in females than in males [6]. The median age of patients diagnosed with breast lymphoma either primary or secondary is between 40 and 67 years [7]. The most common mammographic appearance of BL is intramammary masses, round or oval in shape with circumscribed or microlobulated margins and no evidence of calcifications. Usually, lesions in cases of PBL tend to be solitary and larger while, in SBL are multiple and of smaller size. Less common mammographic pattern is architectural distortion of the breast. However, enlarged intramammary lymph nodes may be seen.

The ultrasound in most cases reveals homogeneously hypoechoic, round or oval lesions with hypervascularity, that lack significant posterior shadow [8].

Most commonly, breast lymphomas manifest as an enlarging, painless breast mass, mimicking a breast carcinoma [9], but they usually tend to be larger than epithelial cancers. Skin retraction, nipple discharge and peau d'orange appearance are infrequent signs of breast lymphomas, while a considerable proportion of

approximately 24% of these patients does not develop any signs or symptoms at the time of diagnosis [10].

The differential diagnosis comprises carcinoma, inflammatory carcinoma, sarcoma, fibroadenoma, mammary dysplasia, breast abscess and acute mastitis [11,12]. Since there is no single imaging finding considered pathognomonic of breast lymphoma, the diagnosis is established based on cytologic and histopathologic examination.

Fine needle aspiration cytology (FNA) and excisional biopsy or fine needle biopsy (FNB) represent the most common diagnostic procedures, with the biopsy procedures having greater diagnostic value, since the cytology may not be able to distinguish lymphoid cells from reactive lymphocytes [13].

The most frequent histological type of breast lymphoma is the B-cell lymphoma, while T-cell, Burkitt and mucosa-associated lymphoid tissue lymphoma (MALT) are less commonly met [14].

According to the international literature, treatment modalities of lymphomas involving the breast should not be different than of other lymphomas with the same stage and histological classification. Mastectomy and other wide excisional procedures should be avoided, as the definitive mode of treatment consists of systemic chemotherapy and/or radiation, as these malignancies are remarkably chemosensitive and radio sensitive.

The prognosis of the lymphomas involving the breast either primary or secondary is considered dismal with 5-year survival rates ranging from 9 to 85% [6,15–17]. The most important prognostic factor is the histologic subtype and the clinical stage at the time of diagnosis, according to the Ann Arbor system.

4. Conclusion

In conclusion, we report a case of Non Hodgkin lymphoma that was diagnosed after identifying a breast mass and a concomitant skin lesion. NHLs are tumors deriving from lymphoid tissue, mainly lymph nodes. Extranodal involvement is considered when there is proliferation of malignant cells elsewhere than lymphoid tissues. This uncommon form of lymphoma is presented in about one third of patients and most common sites are: gastrointestinal tract, head and neck (Waldeyer ring), skin, bone marrow and centralnervous system. Breast involvement is very rare. We would like to emphasize that breast lymphomas should always be considered in the differential diagnosis of breast neoplasms, as the treatment of this clinical entity differs greatly from breast carcinoma. Excisional biopsy or further radical operative approach is not recommended, since chemotherapy using various agents has been recognized as the preferred treatment. The value of preoperative diagnosis should be underlined as the patient avoids unnecessary surgical intervention and has earlier initiation of chemotherapy.

Conflicts of interest

None declared. The authors have no financial, consultative, institutional, and other relationships that might lead to bias or conflict of interest.

Sources of funding

The authors declare no sources of funding.

Ethical approval

This is not a research study, no ethical approval is required.

Consent

Written informed consent was obtained from the patient for publication of this case report and accompanying images. A copy of the written consent is available for review by the Editor-in-Chief of this journal on request.

Authors' contribution

Spyridon Marinopoulos: Editor/Breast Consultant
Panagiotis Safioleas: Writer/review of literature
Lamprini Skorda: Internal Medicine Consultant
Eleni Vassilopoulou: Writer/review of literature
Flora Zagouri: Oncologist
Maria Sotiropoulou: Pathology Consultant
Peter Drakakis: Reviewer
Constantine Dimitrakakis: Reviewer/Head of Unit

Registration of research studies

This is not a research study.

Guarantor

Spyridon Marinopoulos (Corresponding author).

References

- [1] R.A. Agha, A.J. Fowler, A. Saetta, I. Barai, S. Rajmohan, D.P. Orgill, the SCARE Group, The SCARE Statement: consensus-based surgical case report guidelines, *Int. J. Surg.* 34 (2016) 180–186.
- [2] C. Wiseman, K.T. Liao, Primary lymphoma of the breast, *Cancer* 29 (1972) 1705–1712.
- [3] E. Brogi, N.L. Harris, Lymphomas of the breast: pathology and clinical behavior, *Semin. Oncol.* 26 (1999) 357.
- [4] R.B. Mann, Are there site-specific differences among aggressive B-cell neoplasms? *Am. J. Clin. Pathol.* 111 (Suppl. 1) (1999) 144–150.
- [5] A.R. Mattia, J.A. Ferry, N.L. Harris, Breast lymphoma, a B-cell spectrum including the low grade B-cell lymphoma of mucosa associated lymphoid tissue, *Am. J. Surg. Pathol.* 17 (6) (1993) 574–587.
- [6] W.W. Wong, S.E. Schild, M.Y. Halyard, P.J. Schomberg, Primary non-Hodgkin lymphoma of the breast: the Mayo Clinic experience, *J. Surg. Oncol.* 80 (2002) 19–25.
- [7] J.S. Burke, Other extranodal lymphomas, in: *Neoplastic Hematopathology*, 2nd ed., Lippincott Williams and Wilkins, Philadelphia, 2001, pp. 1378–1380.
- [8] A. Surov, H.J. Holzhausen, A. Wienke, J. Schmidt, C. Thomssen, D. Arnold, K. Ruschke, R.P. Spielmann, Primary and secondary breast lymphoma: prevalence, clinical signs and radiological features, *Br. J. Radiol.* 85 (2012) e195–e205.
- [9] J.M. Sabate, A. Gomez, S. Torruja, A. Camins, N. Roson, P. De Las Heras, et al., Lymphoma of the breast: clinical and radiological features with pathologic correlation in 28 patients, *Breast J.* 8 (2002) 294–304.
- [10] K. Ganjoo, R. Advani, M.R. Mariappan, A. McMillan, S. Horning, Non-Hodgkin lymphoma of the breast, *Cancer* 110 (2007) 25–30.
- [11] M.P. Stanton, R. Cutress, G.T. Royle, Primary non-Hodgkin's lymphoma of the female breast masquerading as a breast abscess, *Eur. J. Surg. Oncol.* 26 (2000) 429.
- [12] A. Grubstein, O. Givon-Madhala, S. Morgenstern, M. Cohen, Extranodal primary B-cell non-Hodgkin lymphoma of the breast mimicking acute mastitis, *J. Clin. Ultrasound* 33 (2005) 140–142.
- [13] P.H. Levine, R. Zamuco, H. Yee, Role of fine-needle aspiration cytology in breast lymphoma, *Diagn. Cytopathol.* 30 (2004) 332–340.
- [14] P.J. DiPiro, S. Lester, J.E. Meyer, C.M. Denison, T. Takvorian, Non-Hodgkin lymphoma of the breast: clinical and radiological presentations, *Breast J.* 6 (1996) 380–384.
- [15] Y.H. Park, S.H. Kim, S.J. Choi, et al., Primary malignant lymphoma of the breast: clinicopathological study of nine cases, *Leuk. Lymphoma* 5 (2004) 327–330.
- [16] R. Giardini, C. Piccolo, F. Rilke, Primary non-Hodgkin's lymphomas of the female breast, *Cancer* 69 (1992) 725–735.
- [17] A. Misra, B.M. Kapur, G.K. Rath, Primary breast lymphoma, *J. Surg. Oncol.* 47 (1991) 265–270.

Open Access

This article is published Open Access at [sciencedirect.com](https://www.sciencedirect.com). It is distributed under the [IJSCR Supplemental terms and conditions](#), which permits unrestricted non commercial use, distribution, and reproduction in any medium, provided the original authors and source are credited.