

# Isolated Memory Loss in Anti-NMDAR Encephalitis

Raffaele Iorio, MD, PhD, Eleonora Sabatelli, MD, Lucia Campetella, MD, and Claudia Papi, MD

*Neurol Neuroimmunol Neuroinflamm* 2022;9:e1128. doi:10.1212/NXI.0000000000001128

## Correspondence

Dr. Iorio

raffaele.iorio@policlinicogemelli.it

## Abstract

### Background and Objectives

To report a case of anti-NMDAR encephalitis presenting with isolated memory dysfunction.

### Methods

A 29-year-old woman was admitted to the Neurology Department referring memory impairment with a subacute onset. The initial assessment included EEG, neuropsychological tests, and brain MRI. Serum and CSF samples were collected for immunologic studies. The diagnostic evaluation was completed with a total body PET scan.

### Results

Patient's neurologic examination was unremarkable apart from an episodic memory deficit, confirmed by neuropsychological examination. The EEG revealed epileptiform discharges in the temporal lobes, whereas brain MRI showed bilateral temporal lobes hyperintense lesions on fluid-attenuated inversion recovery images and T2-weighted images. NMDAR-IgG was detected in the patient's serum and CSF by cell-based assay confirming the diagnosis of definite anti-NMDAR encephalitis. The total body PET showed only a slight hypometabolism in the right temporal cortex and in the cerebellar hemispheres. After a course of IV immunoglobulin and corticosteroid therapy, a marked improvement of the memory deficit was observed.

### Discussion

This case shows that anti-NMDAR encephalitis can present with isolated memory loss. Neural antibody testing in these patients could play a pivotal role in early diagnosis and prompt treatment.

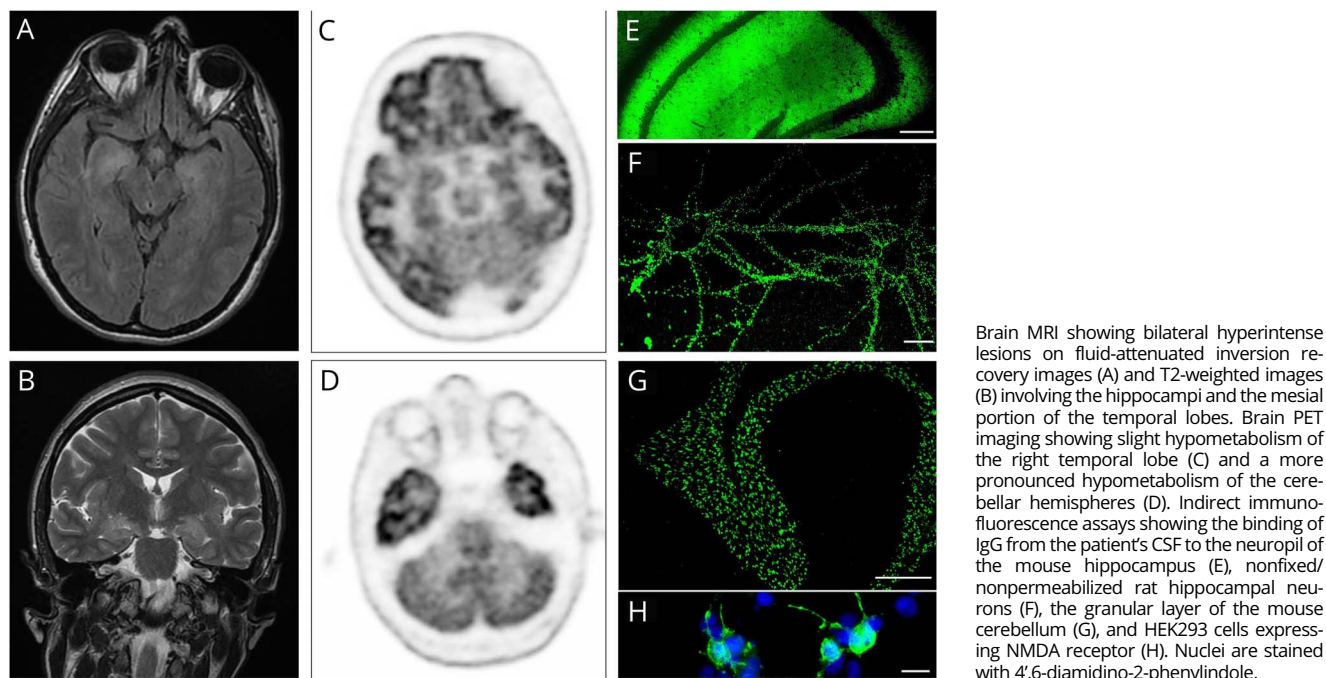
---

From the UOC Neurologia (R.I.), Fondazione Policlinico Universitario A. Gemelli IRCCS; and Università Cattolica del Sacro Cuore (R.I., E.S., L.C., C.P.), Rome, Italy.

Go to [Neurology.org/NN](https://www.neurology.org/NN) for full disclosures. Funding information is provided at the end of the article.

The Article Processing Charge was funded by the authors.

This is an open access article distributed under the terms of the Creative Commons Attribution-NonCommercial-NoDerivatives License 4.0 (CC BY-NC-ND), which permits downloading and sharing the work provided it is properly cited. The work cannot be changed in any way or used commercially without permission from the journal.



The clinical features of autoimmune encephalitis (AE) associated with immunoglobulin G (IgG) autoantibodies binding to NMDA receptor (NMDAR) usually differ from the classic limbic encephalitis and may vary among patients and age groups. Anti-NMDAR encephalitis is usually a multistage illness that progresses from psychosis, memory deficits, seizures, and speech dysfunction to movement disorders, coma, and central hypoventilation.<sup>1</sup> A monosymptomatic syndrome has been rarely described in patients with psychiatric symptoms, seizures,<sup>2</sup> or movement disorders.<sup>3</sup> We report a patient with anti-NMDAR encephalitis presenting with isolated memory impairment.

### Standard Protocol Approvals, Registrations, and Patient Consents

The study was approved by the UCSC Ethic Committee. A signed informed consent form was obtained from the patient's parents.

### Case Report

At the end of February 2021, a 29-year-old woman started to experience a decrease in job performance while working as remote employee 8 h/d. During that time, the patient's husband noticed that her ability of remembering new information was markedly impaired. In the following days, the memory disorder progressively worsened, with exacerbation in moments of emotional distress, in which she could not remember events occurred even in the previous minute. The patient was not aware of her amnesia. She lost her job and her social life. However, she did not experience anxiety, depression, or any

psychotic symptoms. One month after the onset of memory loss, the patient was admitted to our institution.

Eight years before admission, the patient underwent surgery for ovary mucinous cystadenoma. Her medical history was otherwise unremarkable. Neurologic examination revealed only an episodic memory deficit without other signs or symptoms. The Mini-Mental State Examination revealed an impaired delayed recall (final score: 27/30). Laboratory investigations on admission were normal. The EEG revealed epileptiform discharges in the temporal lobes, but the patient never experienced seizures. A 24-hour EEG did not reveal any seizure activity. Neuropsychological examination showed a severe isolated deficit of verbal and visual episodic memory. Brain MRI revealed hyperintense lesions on fluid-attenuated inversion recovery (FLAIR) and T2-weighted images involving both temporal lobes (Figure, A and B). CSF analysis showed mild pleocytosis and the presence of oligoclonal bands. NMDAR-IgG was detected in the patient's serum and CSF by cell-based assay and confirmed by other indirect immunofluorescence assays (Figure, E-H). Ultrasound and MRI of the pelvis were normal. A total body PET showed a slight hypometabolism in the right temporal cortex and in the cerebellar hemispheres (Figure, C and D).

The patient was treated with IV immunoglobulins 0.4 g/kg/d for 5 days and oral prednisone 25 mg/d. Another course of IVIG was administered to the patient after 3 months. A brain MRI performed 4 months after the admission showed the persistence of T2 hyperintense lesions in the temporal lobes. At the last follow-up, 7 months after the onset, the patient still

in therapy with prednisone 10 mg/d presented a marked improvement of the memory deficit (MMSE score: 30/30). The patient remembered most of the recent events occurred over the last 2 months, and she was aware of her improvement in everyday life. She had not returned to work yet, but she regained her social life.

## Discussion

This case with isolated memory impairment as an initial symptom highlights an unusual monosymptomatic presentation of anti-NMDAR encephalitis. In patients with AE associated with NMDAR-IgG, memory impairment usually occurs during the disease course, but, to the best of our knowledge, it has been reported in association with psychiatric disturbances, seizures, movement disorders, and/or impairment of other cognitive domains. We cannot exclude that the patient might have developed other neurologic symptoms if she had not received immunotherapy, but the persistence of the isolated memory deficit is noteworthy. The current diagnostic criteria for the AE diagnosis mostly rely on clinical characteristics and neuroimaging.<sup>4</sup> The patient herein described fulfilled the diagnostic criteria of limbic encephalitis, but before neural antibody testing, she could have not been diagnosed with anti-NMDAR encephalitis according to the current criteria. Anti-NMDAR encephalitis is a severe disease and may require an aggressive therapeutic approach. Early diagnosis and the prompt initiation of appropriate immunotherapy are critical for patients' outcome.<sup>5</sup> Of interest, PET imaging showed hypometabolism of the right temporal lobe and the cerebellar hemispheres. The patient did not have any signs or symptoms of cerebellar dysfunction, but the PET imaging findings suggest a possible cerebellar involvement. NMDAR-IgG binds to granular cells in the cerebellum,<sup>6</sup> but cerebellar ataxia has been rarely described in anti-NMDAR encephalitis.<sup>7</sup>

In sum, this case shows that anti-NMDAR encephalitis can present with isolated memory loss associated with neuroimaging and electroencephalographic features characteristic of limbic encephalitis. Neural antibody testing can be critical to perform an accurate diagnosis in patients with AE.

## Study Funding

No targeted funding reported.

## Disclosure

The authors have no conflicts of interest. Go to [Neurology.org/NN](https://www.neurology.org/NN) for full disclosures.

## Publication History

Received by *Neurology: Neuroimmunology & Neuroinflammation* September 17, 2021. Accepted in final form November 2, 2021.

## Appendix Authors

Name	Location	Contribution
<b>Raffaele Iorio, MD, PhD</b>	UOC Neurologia, Fondazione Policlinico Universitario A. Gemelli IRCCS, Rome, Italy; Università Cattolica del Sacro Cuore, Rome, Italy	Drafting/revision of the manuscript for content, including medical writing for content; major role in the acquisition of data; study concept or design; and analysis or interpretation of data
<b>Eleonora Sabatelli, MD</b>	Università Cattolica del Sacro Cuore, Rome, Italy	Major role in the acquisition of data
<b>Lucia Campetella, MD</b>	Università Cattolica del Sacro Cuore, Rome, Italy	Major role in the acquisition of data
<b>Claudia Papi, MD</b>	Università Cattolica del Sacro Cuore, Rome, Italy	Drafting/revision of the manuscript for content, including medical writing for content, and major role in the acquisition of data

## References

1. Dalmau J, Gleichman AJ, Hughes EG, et al. Anti-NMDA-receptor encephalitis: case series and analysis of the effects of antibodies. *Lancet Neurol*. 2008;7(12):1091-1098.
2. Niehusmann P, Dalmau J, Rudlowski C, et al. Diagnostic value of N-methyl-D-aspartate receptor antibodies in women with new-onset epilepsy. *Arch Neurol*. 2009;66(4):458-464.
3. Rubio-Agustí I, Dalmau J, Sevilla T, Bursal M, Beltrán E, Bataller L. Isolated hemidystonia associated with NMDA receptor antibodies. *Mov Disord*. 2011;26(2):351-352.
4. Graus F, Titulaer MJ, Balu R, et al. A clinical approach to diagnosis of autoimmune encephalitis. *Lancet Neurol*. 2016;15(4):391-404.
5. Iorio R, Damato V, Spagni G, et al. Clinical characteristics and outcome of patients with autoimmune encephalitis: clues for paraneoplastic aetiology. *Eur J Neurol*. 2020;27(10):2062-207.
6. Iorio R, Assenza G, Tombini M, et al. The detection of neural autoantibodies in patients with antiepileptic-drug-resistant epilepsy predicts response to immunotherapy. *Eur J Neurol*. 2015;22(1):70-78.
7. Poorthuis MHF, van Rooij JLM, Koch AH, Verdonkschot AEM, Leembruggen MM, Titulaer MJ. Cerebellar ataxia as a presenting symptom in a patient with anti-NMDA receptor encephalitis. *Neurol Neuroimmunol Neuroinflamm*. 2019;6(4):e579.